

## Trauma and Reconstruction

## Case Report: Vessel Injury During Suprapubic Catheter Placement and the Importance of Patient Positioning in Obese Patients



Veronica Demtchouk, Harneet Gujral, Tanaz R. Ferzandi\*

Department of Obstetrics &amp; Gynecology, Tufts Medical Center, Boston, MA 02111, USA

## ARTICLE INFO

## Article history:

Received 4 July 2016

Received in revised form

16 August 2016

Accepted 23 August 2016

## Keywords:

Suprapubic catheter

Suprapubic catheterization

Injury

## ABSTRACT

Obesity is a well-known risk factor for increased perioperative morbidity. As surgeons see higher volumes of obese patients, it is important to recognize how an elevated body mass index can impact even the most basic surgical steps, such as patient positioning. This case report describes an iatrogenic injury to the external iliac artery in a morbidly obese patient caused by an abdominal trocar during suprapubic catheter insertion secondary to malrotation of the bony pelvis. It highlights the importance of recognizing the impact of obesity on patient positioning.

© 2016 Published by Elsevier Inc. This is an open access article under the CC BY-NC-ND license (<http://creativecommons.org/licenses/by-nc-nd/4.0/>).

## Introduction

Suprapubic catheter (SPC) placement is a common urological procedure used for long-term bladder drainage in patients with voiding dysfunction secondary to neurogenic bladder or bladder outflow obstruction. This procedure has a low incidence of complications, which include hematuria, catheter blockage, and recurrent urinary tract infections. Among the 10% rate of intraoperative complications in this patient population, injury to abdominal contents is a rare occurrence and is more common when the bladder is not fully distended during trocar placement.<sup>1,2</sup> Fortunately, most serious complications are discovered shortly after initial placement and can be readily corrected.

While bowel injury has been a well-documented and feared complication of SPC placement, injury to abdominal vasculature has not been reported in the English literature. This case report describes an iatrogenic injury to the external iliac artery in a morbidly obese patient caused by placement of the abdominal trocar during SPC insertion.

## Case presentation

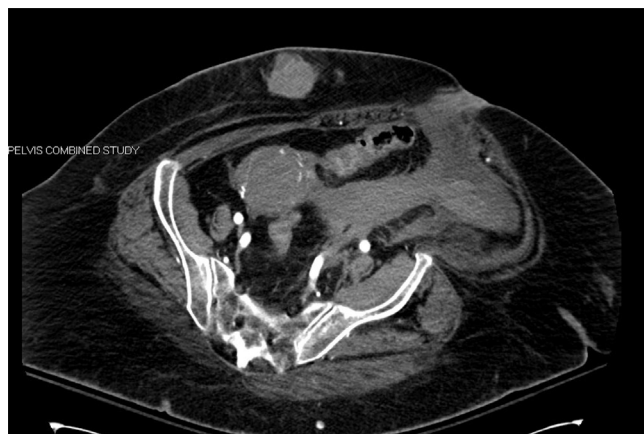An 84-year-old woman with history of overactive bladder with nocturia, incontinence, recurrent urinary tract infections and

urinary retention presented for SPC placement. She has multiple comorbidities, including diabetes, hypertension, hyperlipidemia, “super” obesity with a BMI of 45, pancreatitis, and chronic pain. She had a DVT following right knee replacement, requiring IVC filter placement, a pulmonary embolism, as well as multiple strokes. Her surgical history included an exploratory laparotomy and unilateral salpingo-oophorectomy for an ectopic pregnancy, partial colectomy for colon cancer, brain aneurysm repair, laparoscopic cholecystectomy, and hernia repair. Her extensive list of medications reflected all of the aforementioned medical problems, and notably included clopidogrel, aspirin, and coumadin, which were held prior to surgery. She was transitioned to Lovenox and received prophylactic Lovenox within 2 hours of surgery.

In the operating room, the patient was positioned in the dorsal supine position and appeared both flat and symmetric on the operating table. With monitored anesthesia care (intravenous), she was placed in trendelenburg. The surgery was performed in routine fashion. A 70-degree cystoscope was introduced into the bladder. Due to patient's severe detrusor overactivity and spillage of urine, it was difficult to keep the bladder distended. It was difficult to palpate the pubic symphysis secondary to the patient's body habitus, and the trocar was placed approximately 1.5 cm superior to the symphysis. However, the trocar was visualized via the cystoscope to be skiving along the bladder dome, in spite of the insertion being perpendicular to the skin. Ultimately, a second trocar incision was made distal to the first, hugging the pubic symphysis, and after several attempts, it was introduced into the bladder under direct visualization.

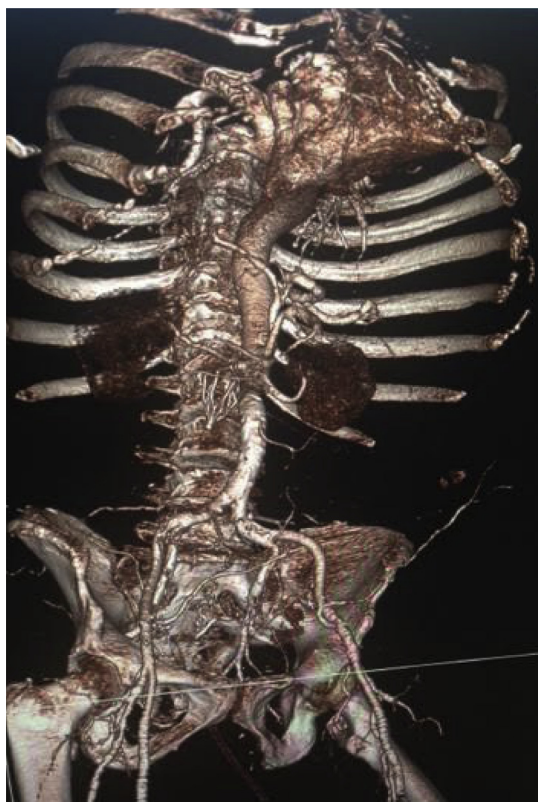
\* Corresponding author. 800 Washington Street, Box 232, Boston, MA 02111, USA. Fax: +1 617 636 3258.

E-mail address: [tanaz.ferzandi@tufts.edu](mailto:tanaz.ferzandi@tufts.edu) (T.R. Ferzandi).



**Figure 1.** Left external iliac artery pseudoaneurysm with active extravasation and moderate sized hematoma extending into extraperitoneal pelvis. Malrotation of the pelvis noted while patient was positioned flat on the table for CT imaging.

Within 30 minutes of arrival to the PACU, the patient became hypotensive requiring fluid resuscitation and vasopressors. In the 2 hours that followed, she remained hypotensive, tachycardic, oliguric, and became hypoxemic, requiring intubation. Hematocrit returned as 22%, and blood products were emergently ordered. A CT angiogram of abdomen and pelvis revealed left external iliac artery pseudoaneurysm with active extravasation of contrast and moderate sized hematoma extending into extraperitoneal pelvis, as shown in Fig. 1. A graft stent was promptly placed in the left external iliac artery by Interventional Radiology.



**Figure 2.** 3D CT volume rendered image demonstrates the apparent malrotation of the pelvis in relation to the vascular structures.

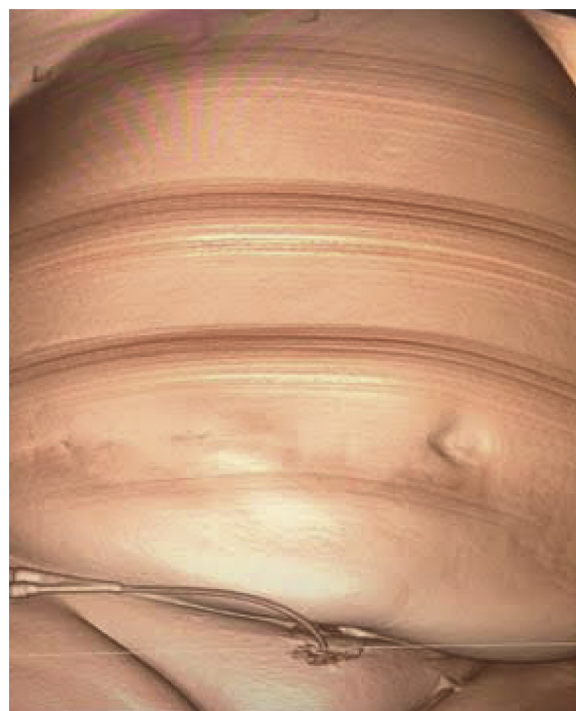
The patient was transferred to the SICU, where she remained stable, with no evidence of further bleeding. She was transferred to the floor on post-operative day 3 and discharged to a rehabilitation facility on post-operative day 8. The patient has done well subsequently.

## Discussion

Coinciding with the rise of obesity among American population is the increasing number of obese surgical patients. Bamgbade et al<sup>3</sup> compared the prevalence, pattern, and severity of postoperative complications in obese and non-obese surgical patients and concluded that obesity is an independent risk factor for perioperative morbidity, including myocardial infarction, peripheral nerve injury, wound infection, and urinary tract infection. Morbidly obese patients have a higher mortality rate of 2.2% compared with 1.2%.<sup>3</sup> Similarly, Ereksøn et al showed that morbid obesity (BMI > 40) was among the most significant predictors of 30-day major morbidity following benign gynecologic surgery, along with age >80, dependent functional status, diabetes mellitus, and a known bleeding disorder.<sup>4</sup>

While several case reports allude to bowel injury being the most feared complication of SPC insertion with reported 2.7% incidence,<sup>5</sup> obesity may be the most significant co-morbidity increasing the rate of complications, and making vascular injury an even more feared complication. Several retrospective studies of SPC placement produced the 30-day mortality rate ranging from 0.8% to 1.8%, emphasizing the need for careful pre-operative and intra-operative optimization and procedure performance by appropriate clinical staff.<sup>2,5</sup>

This case sheds light on the likely increased risk of iatrogenic injury to abdominal contents during suprapubic catheterization in morbidly obese patients. While proper positioning is a



**Figure 3.** 3D CT volume rendered image demonstrating the difficulty of locating normal anatomical landmarks in a morbidly obese patient that are otherwise used routinely during suprapubic catheter placement.

necessary part of all surgeries, it is even more crucial to ensure obese patients do not have malrotation of the pelvis as seen in the location of the bony pelvis in Fig. 1 and in the 3D CT volume rendered images in Figs. 2 and 3. Normal anatomical landmarks may not be readily visible, and visual inspection may not be enough to ensure proper pre-operative positioning. We recommend intra-operative use of imaging both to assess on-table positioning and to guide trocar and catheter insertion in morbidly obese patients.

#### Conflict of interest

The authors did not report any potential conflicts of interest.

#### References

1. Hasan AT, Fasihuddin Q, Sheikh MA. Suprapubic cystostomy: urinary tract infection and other short term complications. *J Pak Med Assoc.* 2002 Dec;52(12): 557–560.
2. Ahluwalia RS, Johal N, Kouriefs C, et al. The surgical risk of suprapubic catheter insertion and long-term sequelae. *Ann R Coll Surg Engl.* 2006 Mar;88(2): 210–213.
3. Bamgbade OA, Rutter TW, Nafiu OO, Dorje P. Postoperative complications in obese and nonobese patients. *World J Surg.* 2007 Mar;31(3):556–560. discussion 561.
4. Erekson EA, Yip SO, Ciarleglio MM, Fried TR. Postoperative complications after gynecologic surgery. *Obstet Gynecol.* 2011 Oct;118(4):785–793.
5. Sheriff MK, Foley S, McFarlane J, et al. Long-term suprapubic catheterisation: clinical outcome and satisfaction survey. *Spinal Cord.* 1998 Mar;36(3):171–176.