

CASE REPORT

NTRK3 mutation in secretory carcinoma of the parotid gland: A Case report

Fahad AlKaabba¹  | Abdurahman Alloghbi^{2,3}  | Yazeed Deajim² |
Mohamad W. Sukkari⁴  | Mir Yousufuddin Ali Khan⁵ | Ammar Sukari³

¹Department of Medicine, University of Maryland Medical Center, Baltimore, MD, USA

²College of Medicine, King Khalid University, Abha, Saudi Arabia

³Department of Oncology, Karmanos Cancer Institute, Wayne State University, Detroit, Michigan, USA

⁴Faculty of Medicine, University of Aleppo, Aleppo, Syria

⁵Department of Pathology, Detroit Medical Center, Wayne State University, Detroit, Michigan, USA

Correspondence

Ammar Sukari, Department of Oncology, Karmanos Cancer Institute, Wayne State University, Detroit, Michigan, USA.
Email: sukaria@karmanos.org

Abstract

Mammary analog secretory carcinoma (MASC) is a newly described carcinoma with a molecular hallmark of ETV6-NTRK3 fusion that promotes oncogenesis. While MASC histopathology was well-studied in the literature, clinical behavior remains unstudied. We present a 22-year-old man with painless parotid mass, which was diagnosed as salivary gland cancer, MASC subtype.

KEYWORDS

case report, mammary analog secretory carcinoma, salivary gland carcinoma

1 | INTRODUCTION

Skalova et al. first described secretory carcinoma of the salivary gland in 2010, as a mammary analog secretory carcinoma (MASC), based on the morphological and immunohistochemical features that resemble secretory carcinoma of the breast.¹

The unique features of MASC include the absence of zymogen granules, strong staining for mammaglobin, and the presence of abundant extracellular colloid-like material, which are common features of secretory breast carcinoma (SBC). In addition to sharing these morphological features with the SBC, both carcinomas commonly express ETV6-NTRK3 gene fusion,^{2,3} which is caused by

translocation breakpoints of the t(12;15)(p13;q25). The fusion results in a constitutively active chimeric tyrosine kinase and probable activation of the Ras-MAP kinase mitogenic pathway and the phosphatidylinositol-3-kinase-AKT pathway, which is believed to drive the oncogenesis process. We find a similar gene alteration in other tumors such as infantile fibrosarcoma, myelogenous leukemia, and congenital mesoblastic nephroma.^{4,5}

MASC commonly arises in the major salivary glands, among which the parotid gland is the most affected. The clinical behavior of MASC in the medical literature remains understudied. In this case report, we present a case of a MASC and we discuss the common clinical features of MASC found in the literature.

Institution: Karmanos Cancer Institute, Wayne State University, Detroit, MI, USA

This is an open access article under the terms of the [Creative Commons Attribution-NonCommercial](https://creativecommons.org/licenses/by-nc/4.0/) License, which permits use, distribution and reproduction in any medium, provided the original work is properly cited and is not used for commercial purposes.

© 2022 The Authors. *Clinical Case Reports* published by John Wiley & Sons Ltd.

2 | CASE PRESENTATION

A 22-year-old man presents with a one-year history of right-sided parotid mass and neck swelling. Initially, the parotid gland was painless with minimal discomfort, so he did not seek medical attention. However, when the neck swelling started to increase, he sought medical attention. The patient's family and social history was unremarkable. He had no prior radiation exposure. On examination, the parotid mass was visually noticeable, with palpable, non-tender, and non-fixable swelling located at the right mandible angle.

There was no other significant lymphadenopathy. The rest of the physical examination was unremarkable. Initial laboratory evaluation including complete metabolic panel and complete blood count was within normal limits. A neck CT scan was obtained and revealed 2.9×3.1 cm superficial hypo-enhancing mass involving the tail of the right parotid gland (see [Figure 1.1](#)) accompanied by ipsilateral cervical lymphadenopathy involving Ib and IIa lymphatic stations (see [Figure 1.2–1.4](#)). CT findings were consistent with primary parotid neoplasm with subsequent nodal metastasis. Consequently, we obtained a fine needle aspiration biopsy, which was suspicious for malignancy. He later underwent superficial parotidectomy along with modified radical lymph node dissection.

Gross examination of the parotidectomy specimen showed a single, well-circumscribed, soft to friable mass

within the parotid gland measuring 2.8 cm in maximum dimension. Microscopic analysis of the specimen revealed a non-encapsulated lesion with solid, microcytic, including papillary cystic growth of neoplastic cells. The tumor cells showed clear eosinophilic cytoplasm with multiple foamy to bubbly secretions with the cytoplasm. Colloid-type secretion was present within the cystic spaces and glandular lumen (see [Figure 2](#)). Immunohistochemical staining of the tumor cells showed tumor cells to stain-positive for mammaglobin, MUC4, SOX10, and S-100. The tumor cells showed weak staining with GATA-3, and no staining for DOG-1, p63. Pas-D stained the glandular secretions (see [Figure 3](#)). A diagnosis of secretory carcinoma, T2PN3BM0, stage II was rendered.

As part of the tumor evaluation, comprehensive molecular testing was performed on the tumor tissue. Immunohistochemical (IHC) staining was positive for MLH1, MSH2, MSH6, and PMS2, suggesting intact mismatch repair (MMR) machinery. Furthermore, IHC staining showed negative AR, ERBB2, and PDL1 staining. DNA mutation analysis showed that the tumor is MSI stable, has low TMB, and somatic mutations in *EML4* (c.1252C>T, H418Y), *EPHB4* (c.2324C>T, T775M), *ERCC5* (c.2911A>G, T971A), *GLI2* (c.649C>G, R217G), *HOOK3* (c.168T>G, N56K), *MLLT3* (c.1331G>A, R444K), *PCMI* (c.6033_6034delGA, E2011fs), *SMARC4* (c.220A>C, K74Q), and *ZFHX3* (c.2330_2347del18, V777_A782del). mRNA fusion analysis identified a pathogenic

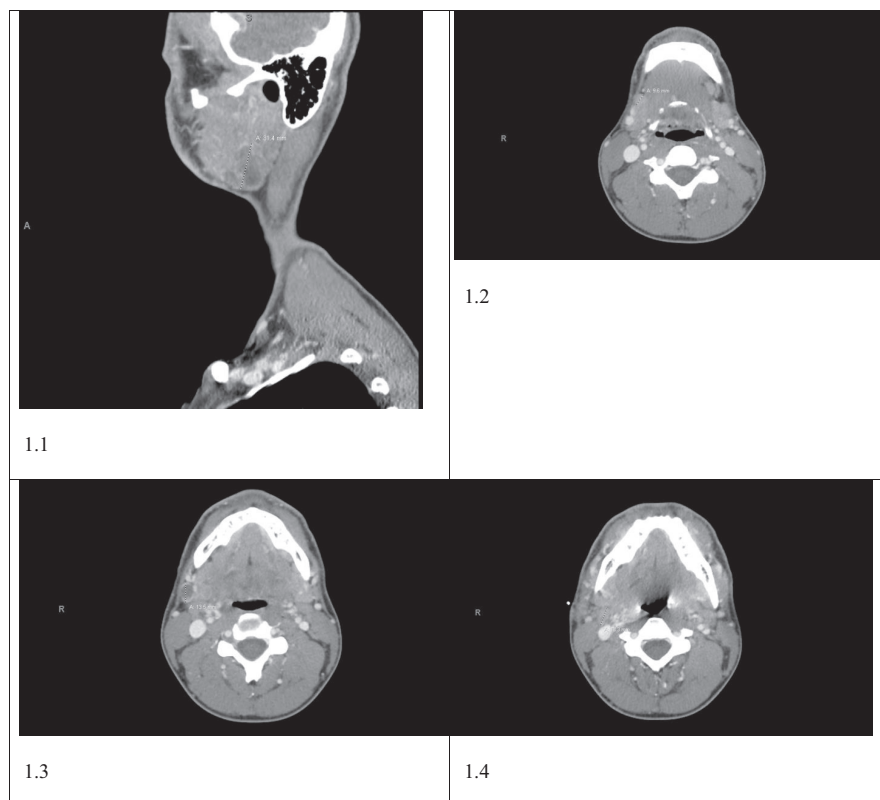
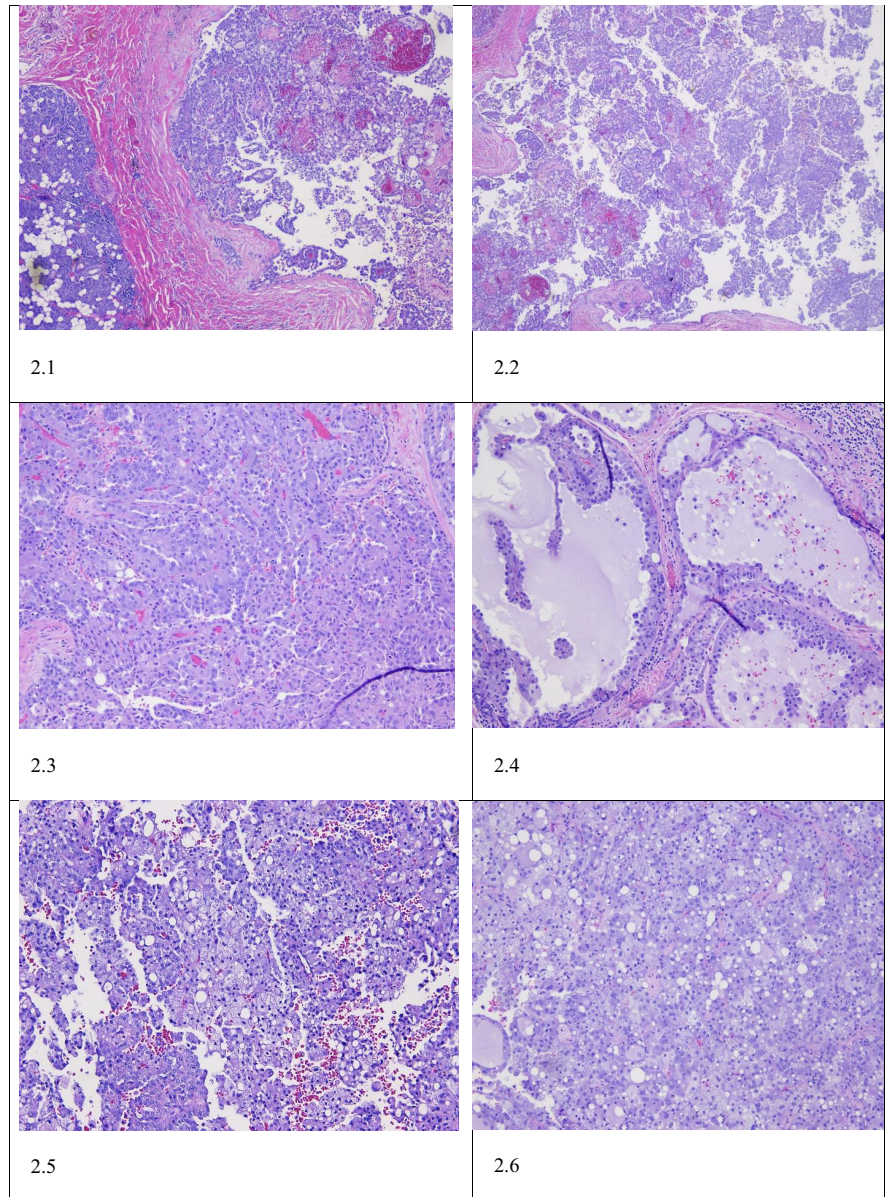


FIGURE 1 CT of the neck with contrast showing 1.1: 2.9×3.1 cm superficial hypo-enhancing mass involving the tail of the right parotid gland. 1.2–1.4: accompanying ipsilateral cervical lymphadenopathy involving Ib and IIa lymphatic stations

FIGURE 2 Microscopic analysis.

2.1—A non-encapsulated lesion within the parotid gland. 2.2—The microcystic and tubule-cystic histologic pattern. 2.3—A solid and glandular pattern. 2.4—Colloid secretions within the glandular lesion. 2.5 and 2.6—A clear to eosinophilic cytoplasm with vacuolated secretions in the cytoplasm to the neoplastic cells



ETV6:NTRK3 fusion that is typically identified in MASC tumors, with exon 5 of *ETV6* joined in-frame to exon 15 of *NTRK3*. Germline testing showed no clinically significant variants detected.

The patient then proceeded to receive post-surgical adjuvant chemo-radiotherapy (CRT) with weekly carboplatin and paclitaxel. The patient completed the prescribed CRT. A follow-up imaging study, after 12 weeks of completing CRT, revealed no evidence of disease.

3 | DISCUSSION

The neurotrophic tyrosine receptor kinase genes 1, 2, and 3 (*NTRK1*, *NTRK2*, and *NTRK3*) encodes the tropomyosin-related kinases. These receptors play a crucial role in the function of the peripheral and central

nervous systems, both physiologically and developmentally.^{6,7} When *NTRKs* are activated, they promote proliferation, differentiation, and survival of cells. The fusion of the transcriptional regulator gene *ETV6* and the membrane receptor kinase *NTRK3* results in a chimeric tyrosine kinase that continuously promotes cell proliferation and increases its survival playing a fundamental role as an oncogene.⁸

Approximately 90 cases of MASC have been reported. Among these cases, there is a notable male predominance.^{9,10} The most commonly affected gland is the parotid, accounting for two-thirds of the reported cases.¹¹ It usually presents as an enlarging non-tender mass that is detected incidentally on physical examination.¹² MASC normally does not have aggressive behavior, so it is considered a low-grade carcinoma with a favorable prognosis, with moderate risk for local recurrence (15%), lymph node

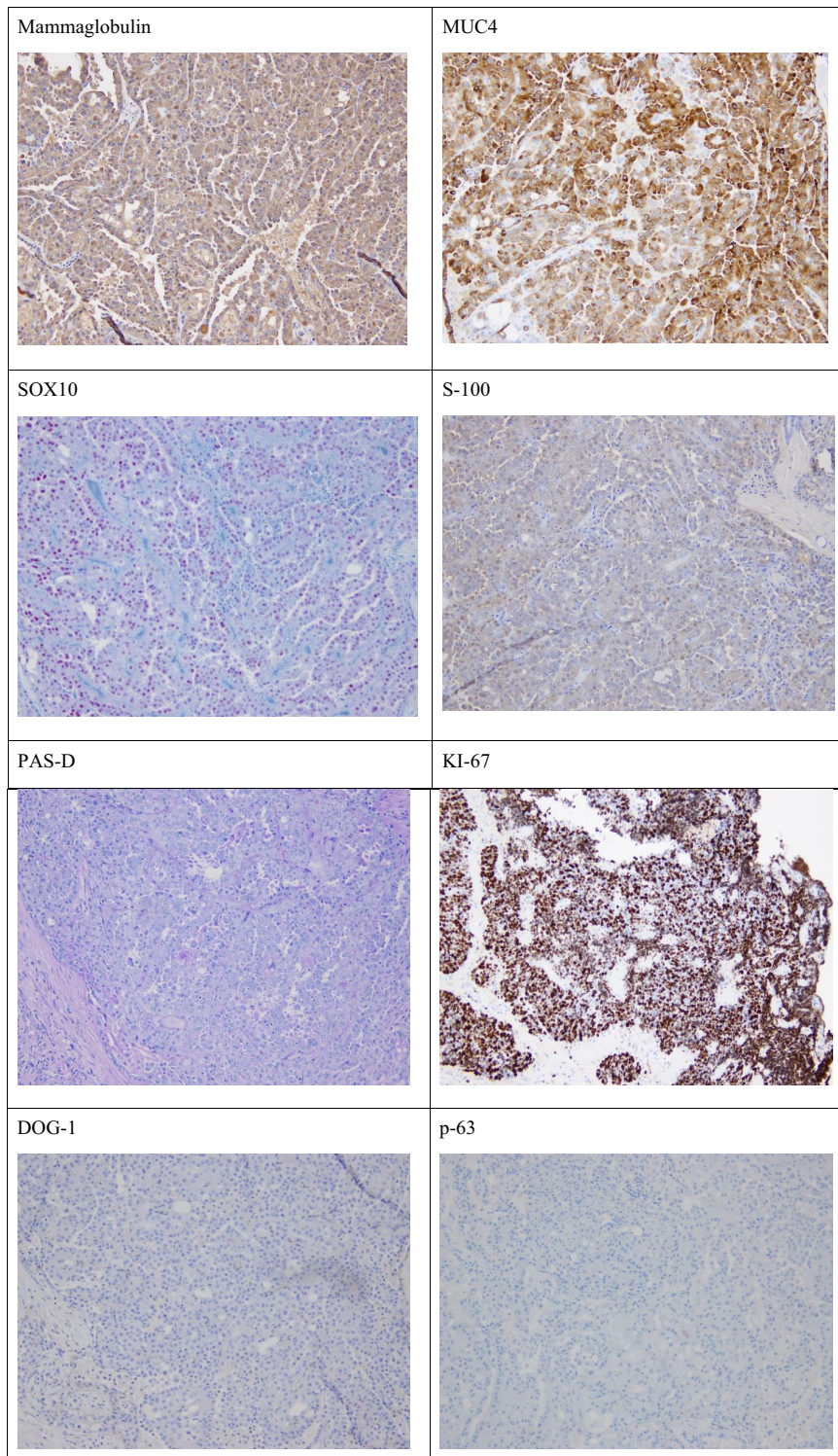


FIGURE 3 IHC staining Profile: Mammaglobin (+); MUC-4 (+); SOX10 (+); S-100 (+); PAS-D (+); KI-67 (>90%); DOG-1 (-); p63 (-)

metastases (20%), and a low risk for distant metastases (5%).¹⁰

MASC is commonly diagnosed by confirming the t(12;15) (p13;q25), this translocation, as stated above, results in the ETV6-NTRK3 gene fusion.¹³ Another approach is to confirm the presence of positive immunohistochemical studies for STAT5, mammaglobin, and S-100 protein.¹⁴ It should be noted that a negative test

for ETV6-NTRK3 gene fusion does not rule out the diagnosis of MASC. One of the main differential diagnoses to MASC is low-grade salivary duct carcinomas or acinic cell carcinomas (ACC). The characteristics of ACC are the presence of large, serous, acinar cells with cytoplasmic PAS-positive, zymogen-like granules, these are usually absent in MASC.¹⁵ Histologically, MASC is characterized by the proliferation of uniform eosinophilic

cells with a vacuolated cytoplasm, growing within a microcystic, macrocystic, and papillary architecture.¹⁶ The growth rate between MASC and ACC is similar; however, MASC is more likely to metastasize to the regional lymph nodes. Hence, MASC is more aggressive tumor. The disease-free period for MASC ranges from 71 to 115 months, which is shorter than ACC, which is 92–148 months.¹⁷

The treatment approach for MASC has not been well defined or standardized. The reason for this is that most studies in the literature have been retrospective.¹⁶ Various treatment approaches to manage MASC are usually dependent on the tumor grade and range of surgical resection, non-radical vs radical resection, radiotherapy to neck dissection or chemotherapy. The treatment of choice in high-grade transformation MASC has been radical surgery with neck dissection in addition to adjuvant radiotherapy.¹⁶ In the future, using ETV6-NTRK3 inhibitors might become a therapeutic target. The anti-tumor activity of tropomyosin receptor kinase (TRK) inhibitors has shown a robust response for patients with NTRK-rearranged tumors in clinical trials. Specifically, larotrectinib and entrectinib are very potent and promising TRK inhibitors. Targeting TKR proteins is a promising potential treatment option specifically for patients with unresectable MASC. The question is what is the value of TRK inhibitors in the adjuvant setting for a patient with no evidence of disease after surgery and post-surgical radiotherapy, as in our patient's case.

AUTHOR CONTRIBUTIONS

Fahad AlKaabba wrote the manuscript and coordinated to prepare the study. Abdurahman Alloghbi reviewed the manuscript, prepared the slides, and coordinated to prepare the study. Yazeed Deajim wrote the manuscript. Mohamad W Sukkari and Ammar Sukari reviewed the manuscript. Mir Yousufuddin Ali Khan reviewed the molecular studies and prepared the slides.

ACKNOWLEDGMENT

None.

FUNDING INFORMATION

This case report received no specific grant from any funding agency in the public, commercial, or not-for-profit sectors.

CONFLICTS OF INTEREST

None.

DATA AVAILABILITY STATEMENT

All data underlying the results are available as part of the article, and no additional source data are required.


CONSENT

Written informed consent was obtained from the patient to publish this report in accordance with the journal's patient consent policy.

ORCID

Fahad AlKaabba  <https://orcid.org/0000-0001-6622-9244>

Abdurahman Alloghbi  <https://orcid.org/0000-0002-1620-7853>

Mohamad W. Sukkari  <https://orcid.org/0000-0002-2545-0142>

REFERENCES

- Skálová A, Vanecek T, Sima R, et al. Mammary analogue secretory carcinoma of salivary glands, containing the ETV6-NTRK3 fusion gene: a hitherto undescribed salivary gland tumor entity. *Am J Surg Pathol*. 2010;34:599-608. doi:10.1097/PAS.0B013E3181D9EFCC
- Inaba, T., Fukumura, Y., Saito, T., Yokoyama, J., Ohba, S., Arakawa, A., & Yao, T. (2015). Cytological features of mammary analogue secretory carcinoma of the parotid gland in a 15-year-old girl: a case report with review of the literature. *Case Rep Pathol*, 2015, 656107, 1-6.
- Majewska H, Skálová A, Stodulski D, et al. Mammary analogue secretory carcinoma of salivary glands: a new entity associated with ETV6 gene rearrangement. *Virchows Arch*. 2015;466(3):245-254. doi:10.1007/s00428-014-1701-8
- Sethi R, Kozin E, Remenschneider A, et al. Mammary analogue secretory carcinoma: update on a new diagnosis of salivary gland malignancy: new diagnosis: MASC. *The Laryngoscope*. 2013;124(1):188-195. doi:10.1002/LARY.24254
- Connor A, Perez-Ordóñez B, Shago M, Skálová A, Weinreb I. Mammary analog secretory carcinoma of salivary gland origin with the ETV6 gene rearrangement by FISH: Expanded morphologic and immunohistochemical spectrum of a recently described entity. *Am J Surg Pathol*. 2012;36(1):27-34. doi:10.1097/pas.0b013e318231542a
- Kheder ES, Hong DS. Emerging targeted therapy for tumors with NTRK fusion proteins. *Clin Cancer Res*. 2018;24(23):5807-5814. doi:10.1158/1078-0432.ccr-18-1156
- Kaplan DR, Martin-Zanca D, Parada LF. Tyrosine phosphorylation and tyrosine kinase activity of the trk proto-oncogene product induced by NGF. *Nature*. 1991;350(6314):158-160. doi:10.1038/350158a0
- Knezevich SR, Garnett MJ, Pysker TJ, Beckwith JB, Grundy PE, Sorensen PH. ETV6-NTRK3 gene fusion and trisomy 11 establish a histogenetic link between mesoblastic nephroma and congenital fibrosarcoma. *Cancer Res*. 1998;58(22):5046-5048.
- Chiosea SI, Griffith C, Assaad A, Seethala RR. The profile of acinic cell carcinoma after recognition of mammary analogue secretory carcinoma. *Am J Surg Pathol*. 2012;36:343-350. [PubMed: 22301503]. doi:10.1097/PAS.0B013E318242A5B0
- Chiosea SI, Griffith C, Assaad A, Seethala RR. Clinicopathological characterization of mammary analogue secretory carcinoma of salivary glands. *Histopathology*. 2012;61:387-394. [PubMed: 22372712]. doi:10.1111/J.1365-2559.2012.04232.X

11. Min FH, Li J, Tao B-Q, et al. Parotid mammary analogue secretory carcinoma: a case report and review of literature. *World J Clin Cases*. 2021;9(16):4052-4062. doi:[10.12998/WJCC.V9.I16.4052](https://doi.org/10.12998/WJCC.V9.I16.4052)
12. Levine P, Fried K, Krevitt LD, Wang B, Wenig BM. Aspiration biopsy of mammary analogue secretory carcinoma of accessory parotid gland: another diagnostic dilemma in matrix-containing tumors of the salivary glands. *Diagn Cytopathol*. 2014;42(1):49-53. doi:[10.1002/DC.22886](https://doi.org/10.1002/DC.22886)
13. Hirokawa M, Sugihara K, Sai T, et al. Secretory carcinoma of the breast: a tumour analogous to salivary gland acinic cell carcinoma? *Histopathology*. 2002;40(3):223-229. doi:[10.1046/J.1365-2559.2002.01346.X](https://doi.org/10.1046/J.1365-2559.2002.01346.X)
14. Bishop JA, Yonescu R, Batista DAS, Westra WH, Ali SZ. Cytopathologic features of mammary analogue secretory carcinoma. *Cancer Cytopathol*. 2013;121(5):228-233. doi:[10.1002/cncy.21245](https://doi.org/10.1002/cncy.21245)
15. Hong DS, DuBois SG, Kummar S, et al. Larotrectinib in patients with TRK fusion-positive solid tumours: a pooled analysis of three phase 1/2 clinical trials. *Lancet Oncol*. 2020;21(4):531-540. doi:[10.1016/S1470-2045\(19\)30856-3](https://doi.org/10.1016/S1470-2045(19)30856-3)
16. Boon E, Valstar MH, van der Graaf WTA, et al. Clinicopathological characteristics and outcome of 31 patients with ETV6-NTRK3 fusion gene confirmed (mammary analogue) secretory carcinoma of salivary glands. *Oral Oncol*. 2018;82:29-33. doi:[10.1016/j.oraloncology.2018.04.022](https://doi.org/10.1016/j.oraloncology.2018.04.022) [PMID: 29909898].
17. Serrano-Arévalo ML, Mosqueda-Taylor A, Domínguez-Malagón H, Michal M. Mammary analogue secretory carcinoma (MASC) of salivary gland in four mexican patients, *Med Oral Patol Oral Cir Bucal* 2015;20(1):e23-e29. doi:[10.4317/medoral.19874](https://doi.org/10.4317/medoral.19874)

How to cite this article: AlKaabba F, Alloghbi A, Deajim Y, Sukkari MW, Khan MYA, Sukari A. NTRK3 mutation in secretory carcinoma of the parotid gland: A Case report. *Clin Case Rep*. 2022;10:e06243. doi: [10.1002/ccr3.6243](https://doi.org/10.1002/ccr3.6243)