

Case Report

Suspected Metal Allergy and Femoral Loosening After Total Knee Arthroplasty: A Diagnostic Dilemma

Elizabeth G. Lieberman, MD ^{a,*}, Robert L. Barrack, MD ^a, Thomas P. Schmalzried, MD ^b^a Department of Orthopaedics, Washington University in St. Louis, St. Louis, MO, USA^b Harbor-UCLA Department of Orthopaedic Surgery, Torrance, CA, USA

ARTICLE INFO

Article history:

Received 17 September 2020

Received in revised form

28 October 2020

Accepted 1 November 2020

Available online xxx

Keywords:

Metal allergy

Total knee arthroplasty

Total knee replacement

ABSTRACT

Metal sensitivity is increasingly prevalent and is associated with negative outcomes after total knee arthroplasty (TKA). Currently, there is no consensus on diagnostic criteria for TKA failure from immune reaction. We present a patient who had pain and aseptic effusion 2 years after TKA. Radiographs were concerning femoral loosening. Lymphocyte transformation testing showed nickel sensitivity. During revision surgery, the femoral component was loose. The histologic aseptic lymphocyte-dominated vasculitis-associated lesion score was 4 with elevated CD4+ lymphocytes, consistent with sensitization. Nickel-free revision implants were used. One year after surgery, the patient is symptom-free. This case has features suggestive of an immune reaction, with femoral loosening, and is illustrative of the diagnostic dilemma. Using a hypoallergenic knee eliminates future concern for nickel sensitivity.

© 2020 The Authors. Published by Elsevier Inc. on behalf of The American Association of Hip and Knee Surgeons. This is an open access article under the CC BY-NC-ND license (<http://creativecommons.org/licenses/by-nc-nd/4.0/>).

Introduction

Total knee arthroplasty (TKA) can provide pain relief and improve function in most patients with knee arthritis [1]. However, up to 20% of patients are dissatisfied after TKA, most commonly because of persistent pain and/or stiffness [2,3]. An allergic reaction to metal is a potential cause of TKA failure; however, controversy exists regarding diagnosis. In the study by Hallab et al, 25–60% of patients with well-functioning total hip arthroplasty or TKA had positive skin patch testing (SPT) for metal allergy [4,5]. Although patient-reported allergies, including patient-reported metal allergies, have been identified as negative prognostic indicators, there are currently no objective measures that have been shown to diagnose an immune reaction to a prosthetic joint or predict outcomes in patients with metal sensitivity [6,7].

Patients with a suspected allergic reaction after TKA may present with an eczematous dermatitis or persistent painful synovitis, effusion, and stiffness [7]. Symptoms typically present 2 months to 2 years after TKA and are more common in females [8]. Other causes for these symptoms such as infection, inflammatory

arthropathy, gout, component malposition, excessive polyethylene wear, subtle instability, and aseptic loosening must be ruled out as an allergic reaction to the implant is currently a diagnosis of exclusion.

In patients with suspected metal allergy, SPT and/or lymphocyte transformation testing (LTT) can be performed; however, SPT has no prognostic utility in joint arthroplasty, and the results of LTT are not correlated to periprosthetic tissue reactions or revision outcomes [5,9].

We present a case of a patient with chronic pain and effusion after TKA who had mixed findings of an allergic reaction and femoral loosening.

Case history

A 75-year-old male presented in February 2019 complaining of left knee pain and effusion after primary left TKA for osteoarthritis (March 2017). His history was significant for hypertension. He reported no known allergies and no history of cutaneous reactions to metals.

There were no wound healing problems after surgery. However, the patient described an erythematous, maculopapular rash on his anterior tibia, which was present for 6 weeks after surgery and resolved after application of a topical steroid. He also reported a knee effusion immediately after surgery, which was initially

* Corresponding author. Department of Orthopaedics, Washington University in St. Louis, 10000 SE Main St. Ste 226, Portland, OR 97216, USA. Tel.: +1-503-261-6961.

E-mail address: eglieberman@gmail.com

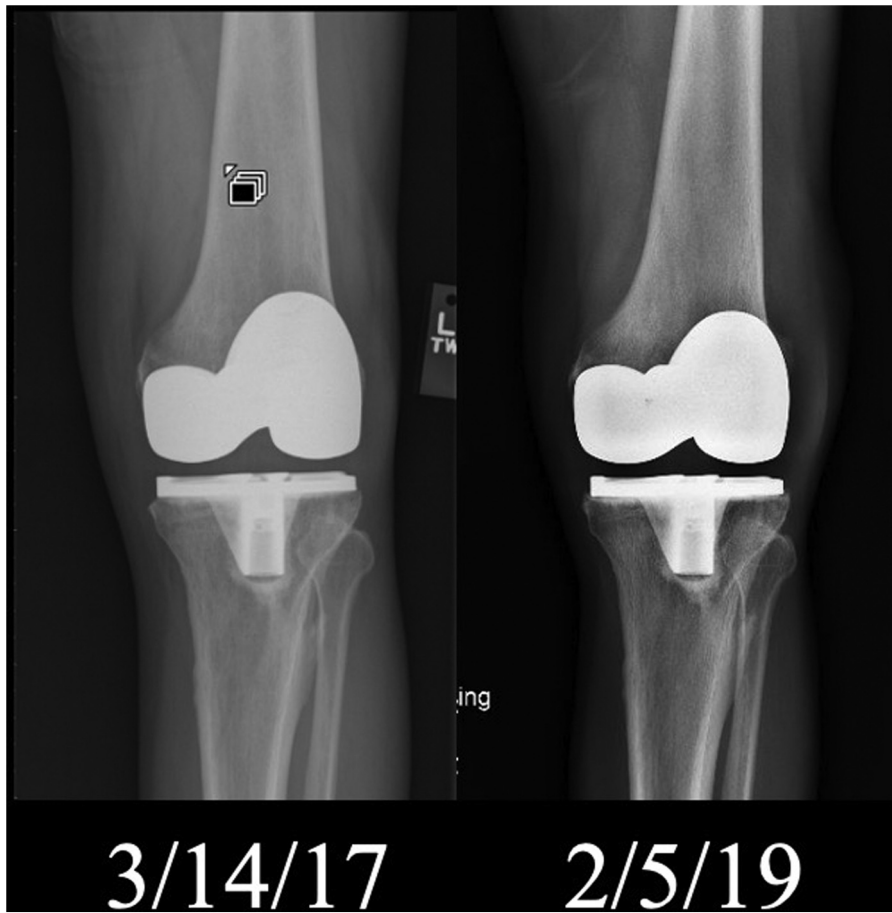

Figure 1. Anteroposterior radiograph of the left knee from post op (3/14/17) and 2 year follow up (2/5/19) after primary total knee arthroplasty.

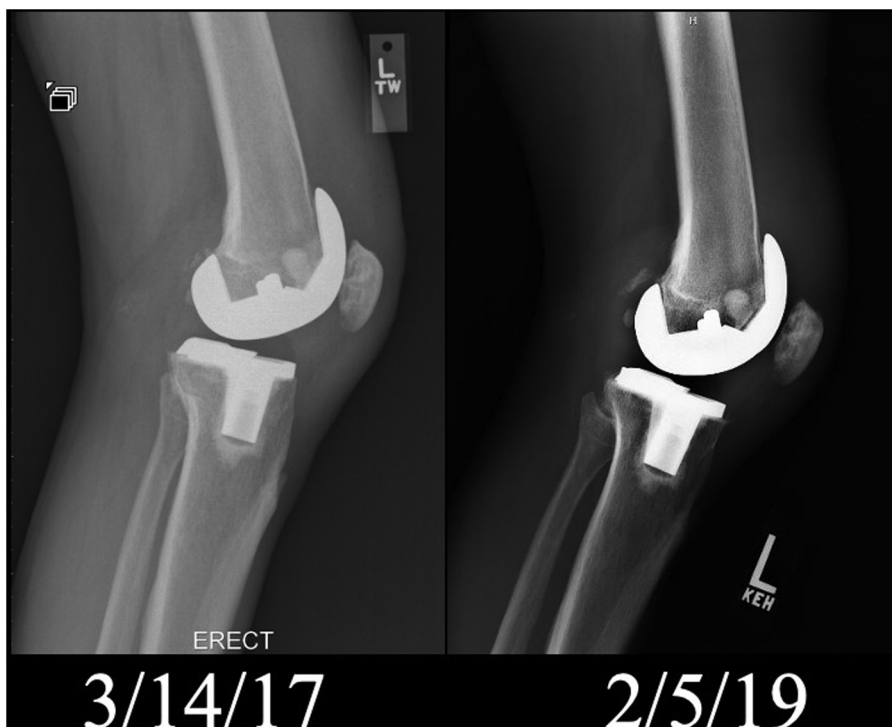


Figure 2. Lateral radiograph of the left knee from post op (3/14/17) and 2 year follow up (2/5/19) after primary total knee arthroplasty.

attributed to postoperative hematoma secondary to anti-coagulation. In the 2 years after surgery, symptoms included pain, stiffness, persistent effusion, and swelling, which were refractory to over-the-counter analgesics, activity modification, and physical therapy. He denied fevers, chills, or systemic infections.

The patient was healthy appearing with a body mass index of 20.6. He walked unassisted with a slightly antalgic gait. The surgical incision was well healed. There was a large effusion and tenderness with palpation at the medial and lateral joint lines. His range of motion was 0-100 degrees of flexion. The knee was stable to varus, valgus, and anterior-posterior stress, and there were no signs of midflexion instability. There were no motor, sensory, or vascular deficits.

Preoperative radiographs demonstrated varus alignment with advanced medial and patellofemoral degeneration. Initial postoperative images showed slight varus mechanical alignment of a cemented total knee with a cruciate-substituting, cobalt-chromium-molybdenum-nickel femoral component and a titanium alloy tibial component. At 2 years postoperatively, the lateral radiograph showed radiolucent lines at the anterior and posterior bone-implant interfaces of the cobalt-chromium-molybdenum-nickel femoral component, suspicious for implant loosening. The titanium tibial component appeared well fixed, and there was no evidence of abnormal polyethylene wear. Slight lateral tracking of the patella was seen on the sunrise view (Figs. 1-4).

The knee was aspirated, and 15 mL of red and cloudy synovial fluid was sent for analysis. Synovial fluid C-reactive protein was 1.2 mg/L, and alpha defensins negative. The red cell count was 23,812/mm³, and white cell count was 339/mcL (normal 0-149/mcL), with 32% neutrophils (normal 0-24%), 35% lymphocytes (normal 0-74%), 31% monocytes (normal 0-69%), and 2% eosinophils (normal 0%). LTT of the patient's blood was moderately positive for nickel and nonreactive to other metals and bone cement. The white blood count was 6.1, erythrocyte sedimentation rate was 15 (normal 1-20), and C-reactive protein was 3.9 (normal <10).

At revision surgery, 50 mL of blood-tinged synovial fluid was sent for analysis and culture. Periprosthetic tissue was normal in color, vascular, and healthy appearing. A specimen adjacent to the femoral component was sent for histology. The femoral component was loose and easily removed. The tibial component was well fixed and successfully removed. Both components were revised using stemmed, posterior-stabilized hypoallergenic implants (Fig. 5). There were no complications, and his postoperative course was uneventful.

Cultures were held for 14 days; there was no bacterial, acid-fast bacilli, or fungal growth. A musculoskeletal pathologist described the gross tissue as an "aggregate of tan-white rubbery fibrous tissue." Microscopic examination showed "very scant predominantly perivascular lymphocytic infiltrate." The specimen was graded by an independent pathologist according to the 10-point aseptic lymphocyte-dominated vasculitis-associated lesion (ALVAL) grading system [9]. The ALVAL score was 4 (synovial lining, 1; inflammatory infiltrate, 2; tissue organization, 1), which is considered low. Single-antibody

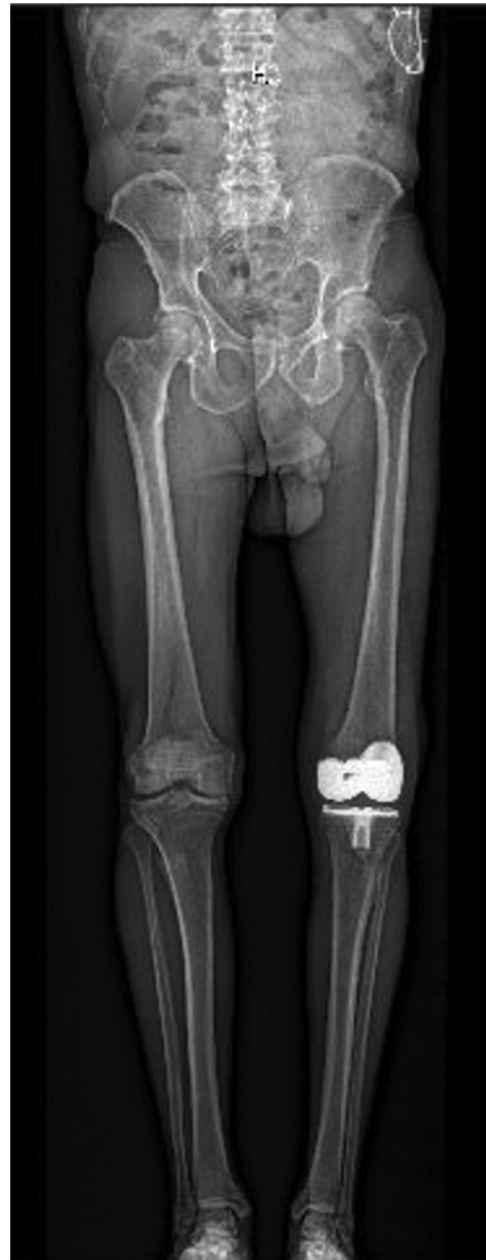

Figure 4. Anteroposterior alignment radiograph.

stains performed for CD4 and CD8 lymphocyte subsets showed a predominance of CD4-positive lymphocytes compared with CD8 lymphocytes (1.4 CD4⁺/CD8⁺, Fig. 6).



Figure 3. Sunrise radiograph from 2 year follow up (2/5/19) after primary left total knee arthroplasty.

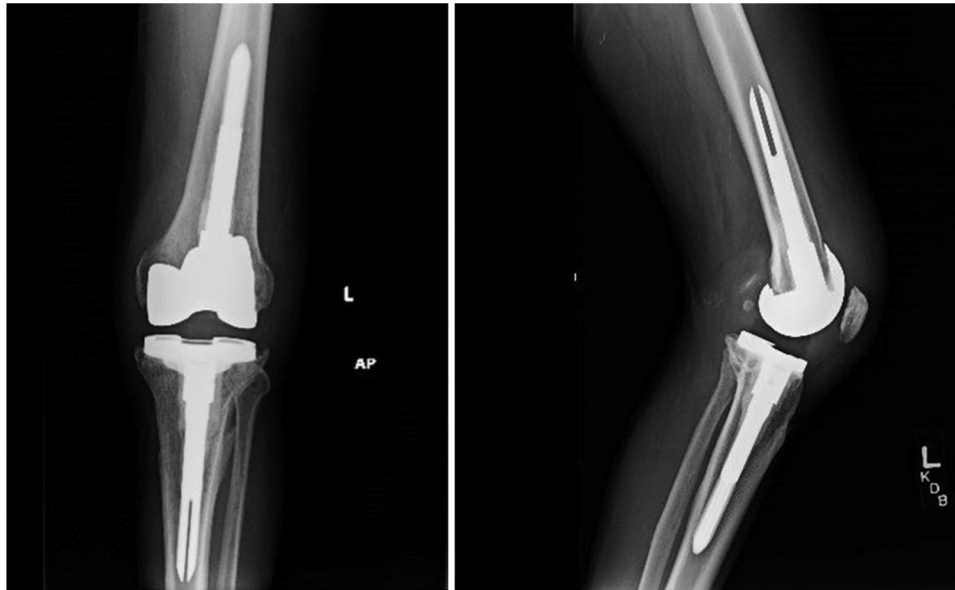


Figure 5. Anteroposterior and lateral radiographs following revision surgery.

At 6-month follow-up, the patient reported improvement in knee pain, function, and satisfaction and at 1-year follow-up, he reported no pain or other symptoms. His gait was normal, and the effusion resolved. His Knee Society Score improved from 70 pre-operatively to 87 at 1 year postoperatively. The patient was informed that data concerning the case would be submitted for publication and provided consent.

Discussion

This case illustrates an approach to diagnosing and managing a patient with a potential allergic reaction to TKA (Fig. 7). As illustrated by our inconclusive findings, metal allergy causing poor clinical results remains a diagnosis of exclusion. Any patient with a painful, stiff, or otherwise unsatisfactory TKA should be worked up

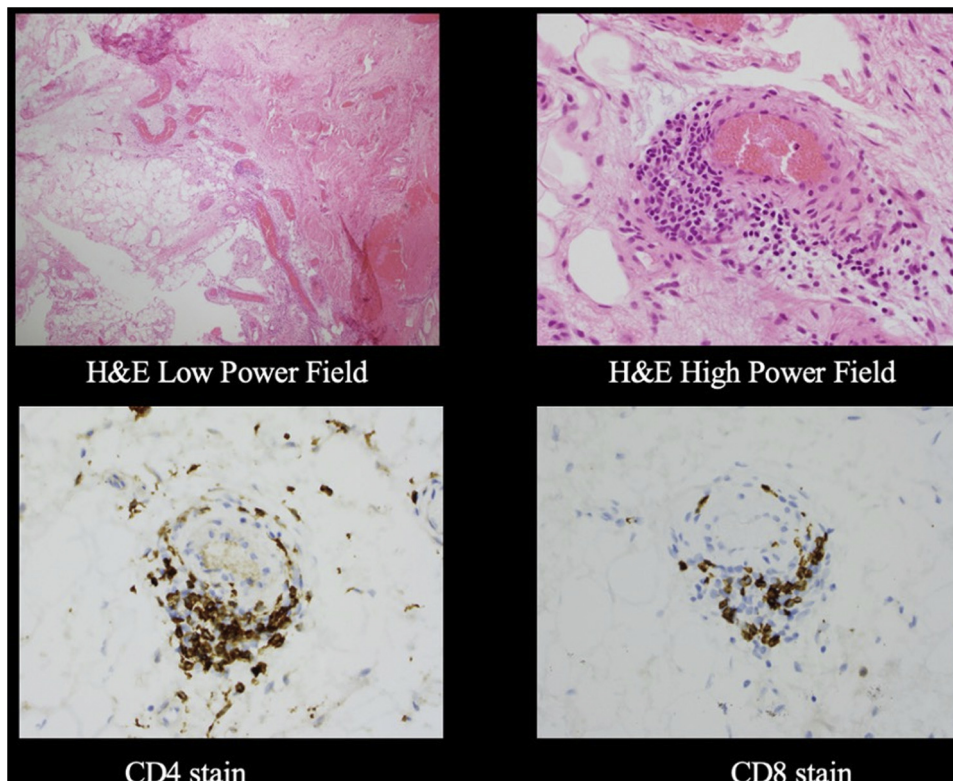


Figure 6. Tissue samples stained with hematoxylin and eosin (H&E) and CD4, CD8 specific stains.

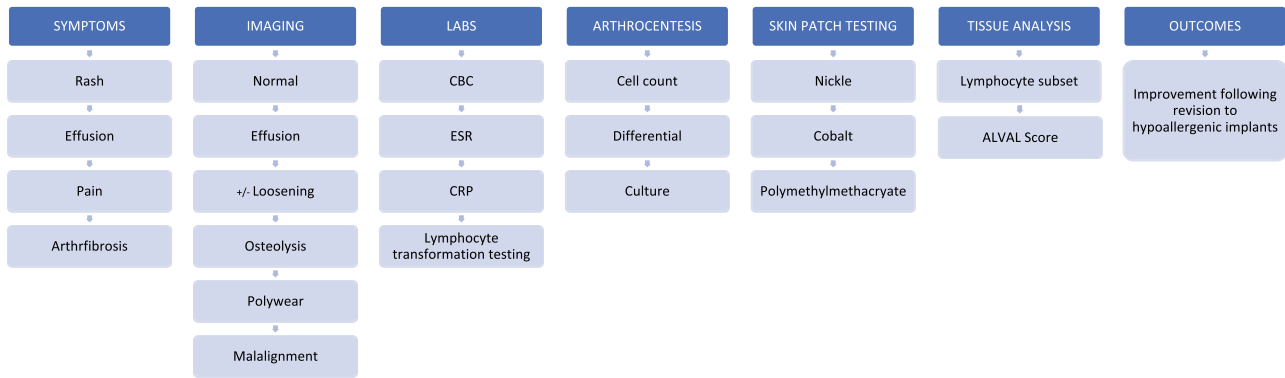


Figure 7. Algorithm for workup and diagnosis when metal allergy is suspected.

for infection. Absence of infection and mechanical factors such as loosening, misalignment, soft-tissue imbalance, and extensor mechanism dysfunction may be the cause of poor clinical results.

Preoperative studies including LTT and synovial fluid analysis may increase suspicion of an allergic reaction but are not diagnostic. Periprosthetic tissue analyses, including ALVAL scoring and staining for lymphocyte subsets, may support an immune reaction but have not shown sufficient sensitivity and specificity to be diagnostic. Available evidence for an allergic reaction should be weighed against other explanations for symptoms on an individual basis.

There was no evidence of infection in this case. Features suggesting allergic reaction to metal included a transient rash, persistent aseptic effusion with an elevated cell count, LTT positive for Ni, increased periprosthetic CD4⁺ lymphocytes, and improvement after revision with hypoallergenic implants. On the other hand, there was no history of cutaneous metal allergy, and the skin rash resolved while the original implants were in situ. In addition, males with unexplained joint pain after total joint arthroplasty exhibit lower rates and severity of sensitivity to implant metals compared with females [10]. Furthermore, LTT has not been shown to predict TKA outcomes [9].

A mechanical explanation was also considered. The knee was aligned in mechanical varus, which is associated with increased risk of failure [11]. Two-year radiographs demonstrated lucencies at femoral implant-bone interfaces, consistent with loosening. In addition, the sunrise view demonstrated slightly lateral patellar tracking, and the effusion was bloody. However, the histology did not show evidence of particulates and macrophages, the so-called cement disease. Revision with hypoallergenic implants led to resolution of this patient's symptoms. However, the varus alignment and loose component were also addressed. Patients with stiff and painful total knees can achieve similar clinical improvement as this case when revised with conventional cobalt-chromium-based components (Ni containing) [12].

Periprosthetic tissue analyses did not provide strong evidence for loosening, nor an immune reaction. An ALVAL score of 4 is considered low and not representing a hypersensitivity reaction [13]. Only one tissue sample was obtained, so characteristics of tissue from other locations are unknown. The increased number of CD4⁺ lymphocytes is consistent with nickel sensitization that may contribute to poor clinical results but has not been associated with loosening [14]. Additional research is needed on the role of lymphocyte subsets in TKA outcomes.

Femoral component loosening is less common than tibial component loosening. In this case, the tibial component was titanium alloy. Only the femoral component contained Ni, increasing consideration of immune reactions as the cause of femoral

loosening [4]. The critical management decision in cases with suspected allergic reaction to metal is whether to use hypoallergenic implants. On average, the cost of hypoallergenic revision implants is about 37% higher than conventional (Co, Cr, Mo, Ni containing) implants [9]. This case had some preoperative evidence suggestive of allergic reactions and some evidence for mechanical failure. We used hypoallergenic implants in the revision surgery. However, femoral loosening may have been purely mechanical, and the same improvement may have been achieved after revision with conventional implants. The use of a hypoallergenic knee in this scenario eliminates the concern that any future symptoms are due to nickel sensitivity.

Summary

As metal sensitization becomes more common because of increasing environmental exposure, such decision-making will be more common. This case report demonstrates an approach for assessing allergic reaction to metal and illustrates many of the considerations and difficulty in diagnosing immune failure. In this case, the patient had evidence of nickel sensitivity from the LTT and elevated CD4⁺ lymphocytes; however, the ALVAL score was within normal limits, and the femoral component was loose. There is no consensus on the diagnostic criteria for immune failure of a TKA. Absence of a validated test for immune failure of a TKA, diagnostic criteria similar to what have been established for prosthetic joint infection, would be helpful.

Conflict of interests

E.G. Lieberman receives research support from Smith & Nephew; R.L. Barrack receives research support from Zimmer Biomet, receives publishing royalties and financial or material support from the McGraw-Hill Companies Inc and publishing royalties from Wolters Kluwer Health–Lippincott Williams & Wilkins, is a member of the editorial or governing board of the *Journal of Bone and Joint Surgery*–British, and is a board or committee member of the Hip Society; and T.P. Schmalzried receives royalties from DePuy and Johnson and Johnson, holds stock ownership in VuMedi, and is a member of the editorial or governing board of *Orthopedics Today*.

References

- [1] Hawker G, Wright J, Coyte P, et al. Health-related quality of life after knee replacement. *J Bone Joint Surg Am* 1998;80(2):163.
- [2] Bourne RB, Chesworth BM, Davis AM, Mahomed NN, Charron KD. Patient satisfaction after total knee arthroplasty: who is satisfied and who is not? *Clin Orthop Relat Res* 2010;468(1):57.

- [3] Gibon E, Goodman MJ, Goodman SB. Patient satisfaction after total knee arthroplasty: a realistic or imaginary goal? *Orthop Clin North Am* 2017;48(4):421.
- [4] Hallab N, Merritt K, Jacobs JJ. Metal sensitivity in patients with orthopaedic implants. *J Bone Joint Surg Am* 2001;83(3):428.
- [5] Granchi D, Cenni E, Giunti A, Baldini N. Metal hypersensitivity testing in patients undergoing joint replacement: a systematic review. *J Bone Joint Surg Br* 2012;94(8):1126.
- [6] Nam D, Li K, Riegler V, Barrack RL. Patient-reported metal allergy: a risk factor for poor outcomes after total joint arthroplasty? *J Arthroplasty* 2016;31(9):1910.
- [7] Eftekhary N, Shepard N, Wiznia D, Iorio R, Long WJ, Vigdorchik J. Metal hypersensitivity in total joint arthroplasty. *JBJS Rev* 2018;6(12):e1.
- [8] Lachiewicz PF, Watters TS, Jacobs JJ. Metal hypersensitivity and total knee arthroplasty. *J Am Acad Orthop Surg* 2016;24(2):106.
- [9] Yang S, Dipane M, Lu CH, Schmalzried TP, McPherson EJ. Lymphocyte transformation testing (LTT) in cases of pain following total knee arthroplasty: little relationship to histopathologic findings and revision outcomes. *J Bone Joint Surg Am* 2019;101(3):257.
- [10] Caicedo MS, Solver E, Coleman L, Jacobs JJ, Hallab NJ. Females with unexplained joint pain following total joint arthroplasty exhibit a higher rate and severity of hypersensitivity to implant metals compared with males: implications of sex-based bioreactivity differences. *J Bone Joint Surg Am* 2017;99(8):621.
- [11] Ritter MA, Davis KE, Meding JB, Pierson JL, Berend ME, Malinzak RA. The effect of alignment and BMI on failure of total knee replacement. *J Bone Joint Surg Am* 2011;93(17):1588.
- [12] Moya-Angeler J, Bas MA, Cooper HJ, Hepinstall MS, Rodriguez JA, Scuderi GR. Revision arthroplasty for the management of stiffness after primary TKA. *J Arthroplasty* 2017;32(6):1935.
- [13] Campbell P, Ebramzadeh E, Nelson S, Takamura K, De Smet K, Amstutz HC. Histological features of pseudotumor-like tissues from metal-on-metal hips. *Clin Orthop Relat Res* 2010;468(9):2321.
- [14] Lionberger DR, Samorajski J, Wilson CD, Rivera A. What role does metal allergy sensitization play in total knee arthroplasty revision? *J Exp Orthop* 2018;5(1):30.