

Hinge Flap of Rectus Abdominis Muscle Combined with Component Separation Technique: Clinical Cases

Celso A. Aldana, MD, PhD*†
 Heidi Caceres, MD†‡
 Alejandro Gimenez, MD†‡
 Guillermo Saguier, MD†‡

Summary: Some techniques to reconstruct the abdominal wall have been published, including the component separation procedure. The contribution of the rectus abdominis flap in the reconstruction of a giant incisional hernia is reported. The authors report three clinical cases in which the component separation technique was insufficient to reconstruct a giant midline incisional hernia. As a salvage technique, the rectus abdominis flap was dissected in the form of a hinge. The postoperative period was successful in all patients, combining both techniques. The rectus abdominis hinge flap could be used as a complementary technique to component separation to reconstruct a giant midline incisional hernia. There are several options to reconstruct the abdominal wall, such as anterior transposition of the posterior rectus sheath,¹ or rotation of the anterior sheath toward the midline. This strategy is known as open book.² The rectus turnover flap is also used.³ The anterior component separation technique closes defects less than 20 cm width.⁴ If it is wider, the reconstruction is more difficult. When the operative plan fails in the operating room, an additional technique should be considered. We report on the cases in which we use the rectus abdominis hinge flap. (*Plast Reconstr Surg Glob Open* 2021;9:e3829; doi: 10.1097/GOX.0000000000003829; Published online 22 September 2021.)

PATIENTS AND METHODS

We retrospectively analyzed three patients with a giant midline incisional hernia who presented difficulties with the anterior component separation technique to close the abdominal wall. The patients enrolled and operated on with this technique comply with institutional rules and signed an informed consent.

Operative Technique

Weeks before surgery, the abdominal cavity was prepared with progressive preoperative pneumoperitoneum to facilitate closure of the defect and minimize the risk of increased intraabdominal pressure and postoperative ventilatory complications. The operative technique begins with the removal of the skin covering the incisional hernia, dissection of the sac, and lysis of the intraabdominal adhesions.

The full-thickness skin flap rises on each side, superficial to the fascia, from the inguinal ligament to the costal border, to the anterior axillary line. An incision is made lateral to rectus muscle. A dissection is performed between the external oblique muscle and the internal oblique muscle to the midaxillary line, from the inguinal region to the costal edge. This separation of components was insufficient to close the abdomen; for this reason, plastic surgeons proposed using the rectus abdominis muscle to improve the advancement of the tissues in a medial direction.

A flap of rectus muscle is designed, vascularized by the inferior epigastric pedicle. If this is not sufficient for closure, both rectus muscles are dissected. The dissection is performed from the lateral edge of the muscle, dissecting its posterior face in a lateral-to-medial direction, separating it from the posterior sheath up to 1 cm before reaching its medial edge. Inferiorly from the arcuate line the muscle is separated from the transversalis fascia. The rib insertions are detached, compromising the superior epigastric vessels and intercostal nerves. To turn 180 degrees toward midline, the flap hinges on the medial edge of the muscle that was preserved during dissection. (**See Video [online]**, which shows the association between the component separation procedure and the

From the *Department of Plastic Surgery, Hospital de Clinicas, San Lorenzo, Paraguay; †School of Medicine, National University of Asuncion, San Lorenzo, Paraguay; and ‡Department of General Surgery, Hospital de Clinicas, San Lorenzo, Paraguay.

Received for publication April 13, 2021; accepted July 28, 2021.

Copyright © 2021 The Authors. Published by Wolters Kluwer Health, Inc. on behalf of The American Society of Plastic Surgeons. This is an open-access article distributed under the terms of the [Creative Commons Attribution-Non Commercial-No Derivatives License 4.0 \(CCBY-NC-ND\)](https://creativecommons.org/licenses/by-nc-nd/4.0/), where it is permissible to download and share the work provided it is properly cited. The work cannot be changed in any way or used commercially without permission from the journal.

DOI: 10.1097/GOX.0000000000003829

Disclosure: The authors have no financial interest to declare in relation to the content of this article.

Related Digital Media are available in the full-text version of the article on www.PRSGlobalOpen.com.

rectus abdominis hinge flap to reconstruct a giant midline incisional hernia.)

When a single flap is used, it is sutured with the non-dissected rectus muscle on the opposite side. When both sides are dissected, the flaps are sutured to each other in the midline. A wide polypropylene mesh covers the muscular plane, anchored in the periosteum above and in the aponeurosis laterally. The subcutaneous plane is sutured in the midline and suction drains are placed.

RESULTS

Case Reports

The patient in the first case, a 53-year-old man, was operated on 3 years ago for complications from colon

surgery and postoperative peritonitis. Laparostomy and spontaneous healing resulted in a 20-cm wide midline incisional hernia. Reconstruction required a flap on the right side; follow-up was 1 year without complications.

In the second case, a 23-year-old man suffered a wound from an assault with a firearm in the abdomen 5 years ago, with complications that produced a midline incisional hernia of 21-cm wide. A single left flap was necessary (Fig. 1); there were no complications in 5 years of follow-up.

The third case was a 56-year-old man who had gastrectomy and evisceration a year ago. The evolution of the laparostomy caused a 25-cm wide incisional hernia in the midline. Two flaps were used, and a small seroma was drained postoperatively (Fig. 2). At the 4-year follow-up, there were no more complications. No patient had

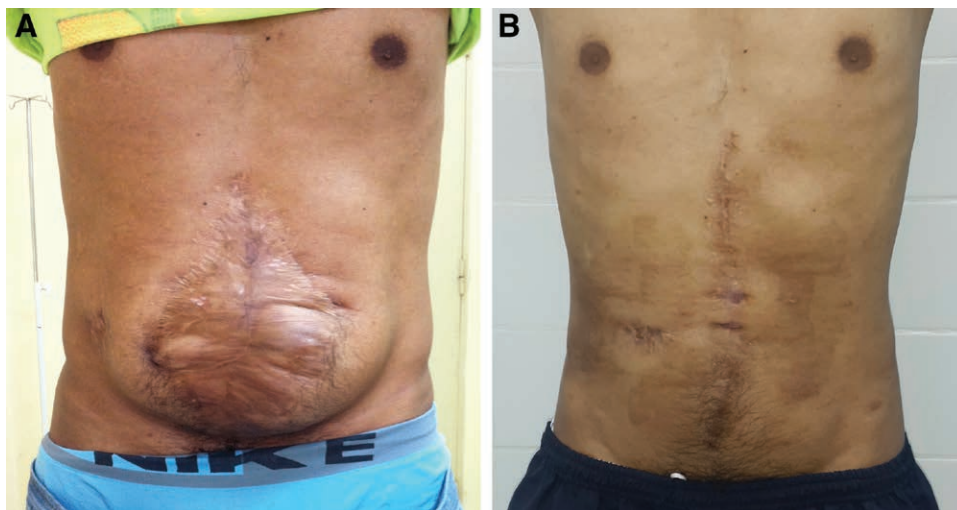


Fig. 1. A 23-year-old man with a 21-cm wide midline incisional hernia. The left rectus abdominis muscle flap was dissected. A, Preoperative image. B, Postoperative image.

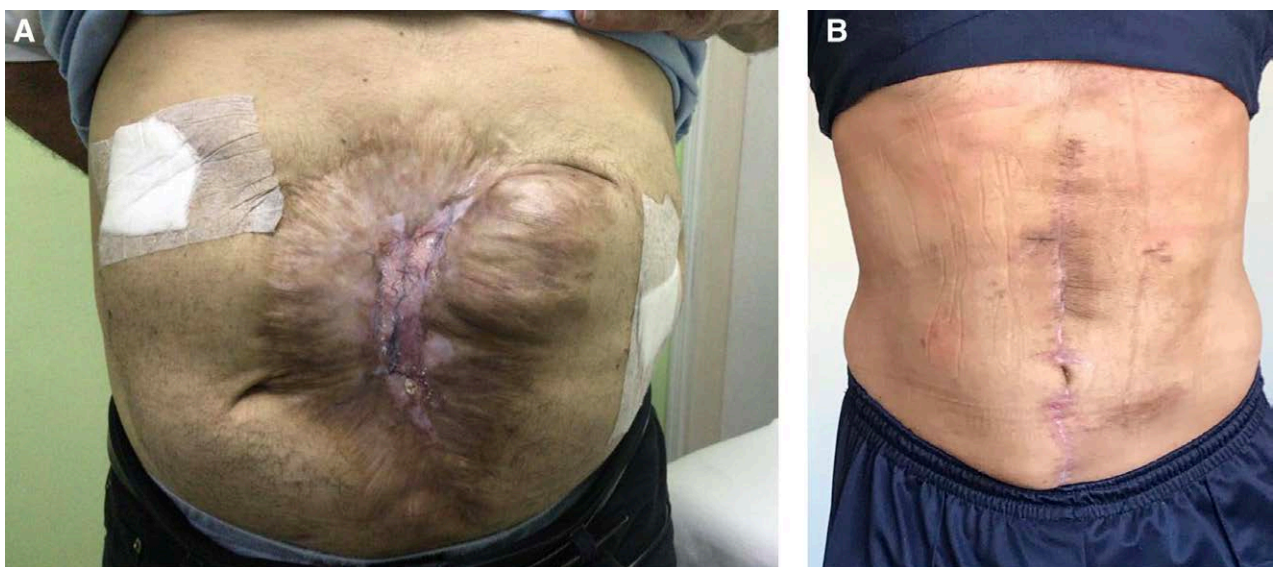

Fig. 2. A 56-year-old man with a 25-cm wide incisional hernia in the midline. Two flaps were dissected. A, Preoperative image. B, Postoperative image.

infection or ballooning effect on the abdominal wall during clinical follow-up.

DISCUSSION

Several techniques have been described to close a midline incisional hernia, but when the hernia is giant, the reconstruction is more difficult.⁵ Microsurgery is a good option, but sometimes it is not possible.

During surgery, the finding may force us to modify the preoperative plan.⁶ If the abdomen does not close, the surgeon should decide on a rescue plan that will allow him to solve the problem. The combination of component separation with a bipedicle rectus abdominis flap consists in dissection of the posterior rectus sheath, and then suturing the medial edge of that sheath with the lateral edge of the anterior sheath of the same muscle.⁶ For defects that exceed 20 cm at the umbilical level, we should consider another option. The rectus abdominis hinge flap has good midline mobilization because the muscle's costal attachments are disinserted. In the design of the flap, we consider that above the umbilicus the musculoaponeurotic transition of transversus abdominis is behind the rectus muscle,⁷ and the identification of the anatomical planes is easier between T12 and L2. It is a good region to begin the dissection and avoid technical errors. If we associate this flap with the component separation technique, defects greater than 20 cm wide can be reconstructed. We have not found in the literature the association of these techniques. This is especially interesting when the preoperative assessment is deceiving, if the perioperative period shows that the component separation is technically insufficient as a single reconstructive proposal, or if the patient's previous surgeries generated an abdominal wall with tissues of doubtful quality. This procedure is a good method for incision hernias that do not require skin reconstruction. A drawback of the technique is damage to innervation. In addition, careful dissection of the posterior sheath should be performed in the vicinity of the transverse and inner oblique muscles to avoid a future herniation.

We use a nonabsorbable mesh to reduce the risk of recurrence, the utility and technical care that the use of mesh requires has already been established.⁸ We contemplate this due to anatomical changes that can occur, such as atrophy of the rectus and external obliques, and compensatory hypertrophy of the internal and transverse oblique muscles.⁹ In the clinical follow-up, we did not observe complications such as those published by other authors¹⁰⁻¹²; however, we had a few clinical cases that should be studied in a larger series.

CONCLUSION

The rectus abdominis hinge flap associated with the component separation procedure can help resolve intraoperative difficulties in reconstructing a giant midline incisional hernia.

Celso A. Aldana, MD, PhD

Servicio de Cirugía Plástica, Hospital de Clínicas
Facultad de Ciencias Médicas, Universidad
Nacional de Asunción
Campus Universitario
San Lorenzo, Paraguay
E-mail: celso.aldana@gmail.com

REFERENCES

1. Fabian TC, Croce MA, Pritchard FE, et al. Planned ventral hernia. Staged management for acute abdominal wall defects. *Ann Surg.* 1994;219:643-50; discussion 651.
2. Ennis LS, Young JS, Gampper TJ, et al. The "open-book" variation of component separation for repair of massive midline abdominal wall hernia. *Am Surg.* 2003;69:733-42; discussion 742.
3. DeFranzo AJ, Kingman GJ, Sterchi JM, et al. Rectus turnover flaps for the reconstruction of large midline abdominal wall defects. *Ann Plast Surg.* 1996;37:18-23.
4. Ramirez OM, Ruas E, Dellon AL. "Components separation" method for closure of abdominal-wall defects: An anatomic and clinical study. *Plast Reconstr Surg.* 1990;86:519-526.
5. Picazo-Yeste J, Morandeira-Rivas A, Moreno-Sanz C. Multilayer myofascial-mesh repair for giant midline incisional hernias: A novel advantageous combination of old and new techniques. *J Gastrointest Surg.* 2013;17:1665-1672.
6. DiCocco JM, Fabian TC, Emmett KP, et al. Components separation for abdominal wall reconstruction: The Memphis modification. *Surgery.* 2012;151:118-125.
7. Puneekar IRA, Khouri JS, Catanzaro M, et al. Redefining the rectus sheath: Implications for abdominal wall repair. *Plast Reconstr Surg.* 2018;141:473-479.
8. Schneeberger SJ, Kraft CT, Janis JE. No-touch technique of mesh placement in ventral hernia repair: minimizing postoperative mesh infections. *Plast Reconstr Surg.* 2020;145:1288-1291.
9. Hicks CW, Krpata DM, Blatnik JA, et al. Long-term effect on donor sites after components separation: A radiographic analysis. *Plast Reconstr Surg.* 2012;130:354-359.
10. Khansa I, Janis JE. Complex open abdominal wall reconstruction: Management of the skin and subcutaneous tissue. *Plast Reconstr Surg.* 2018;142(suppl 3):125S-132S.
11. Ko JH, Wang EC, Salvay DM, et al. Abdominal wall reconstruction: Lessons learned from 200 "components separation" procedures. *Arch Surg.* 2009;144:1047-1055.
12. Kraft CT, Janis JE. Venous thromboembolism after abdominal wall reconstruction: A prospective analysis and review of the literature. *Plast Reconstr Surg.* 2019;143:1513-1520.