

Changes in radiographic parameters following chiropractic treatment in 10 patients with adolescent idiopathic scoliosis: A retrospective chart review

Eric Chun Pu Chu,¹ Diya Midhun Chakkaravarthy,² Kevin Hsu Kai Huang,¹ Vicky Wei Kye Ho,¹ Fa-Sain Lo,¹ Amiya Bhaumik²

¹New York Chiropractic and Physiotherapy Centre, Mongkok, Hong Kong, China; ²Lincoln University College, Jalan Kota Bharu-Pengkalan Kubor, Kota Bharu, Kelantan, Malaysia

Abstract

This retrospective chart review was undertaken to investigate the role of chiropractic intervention for patients with adolescent idiopathic scoliosis (AIS). Ten cases of patients with AIS, mean age 13.3 years, undergoing chiropractic adjustment were retrospectively evaluated. Chart review was performed to extract age, medical history and treatment intervention. The magnitude of scoliosis was quantified using the Cobb method on standing radiographs. A comparison of the measurements from pre- and post-treatment radiographs revealed that Cobb angle reduced from average 29.7° down to average 23.4° (average 21.2% correction). Improvements in spinal morphologies were observed in most curves (64%, n=9/14) and curve stabilization in the rest (36%, n=5/14). A better correction was obtained in cases of mild and moderate AIS. In terms of stabilizing progression ($\leq 5^\circ$ curve progression) or correcting curvatures ($\geq 6^\circ$ reduction), radiological changes were observed in all patients.

Introduction

Adolescent idiopathic scoliosis (AIS) is the most common form of scoliosis, affecting approximately 2% to 4% of the pediatric population.¹ Scoliosis is a three-dimensional deformity of the spine, but for practical purposes, scoliosis is defined as a lateral spinal curvature with a Cobb angle of $\geq 10^\circ$ measured on a standing coronal radiograph.² The pathogenesis of AIS is still unclear and the risk of curve progression in AIS remains a primary clinical concern in modern medicine. The progression of AIS has been linked to periods of rapid growth.

The Society on Scoliosis Orthopaedic and Rehabilitation Treatment (SOSORT) guidelines³ recommend stage-specific treatment strategies for the conservative treatment of AIS. Observation only is recommended for cases of mild scoliosis ($< 20^\circ$) and bracing is recommended for moderate scoliosis (20-40°). Surgical intervention may be required for correcting curves of more than 40°. There is growing evidence to suggest that non-operative treatments can stabilize curve progression and even correct degree of the scoliosis in some children.⁴⁻⁷ However, all previous studies were of low scientific quality, *i.e.* case reports, case series or pilot clinical trials with a small sample size and weak methodology did not allow drawing a clear conclusion about the effectiveness of manual therapy in the treatment of AIS.⁸ The present study reports the radiological changes observed following a treatment plan consisting of chiropractic treatment for AIS.

Materials and Methods

A retrospective chart review was conducted on all school children who were treated for scoliosis in our clinic from January 2015 to December 2018. They were found as having spinal deformities in school screenings and subsequently diagnosed with AIS by their primary care doctors. Scoliosis was defined by a Cobb angle above 10° .² In the SOSORT guidelines,³ a curve progression of $\leq 5^\circ$ (stabilization) or a curve decrease of $\geq 6^\circ$ (correction) is considered treatment success, while a curve deterioration of $\geq 6^\circ$ (progression) is considered treatment failure. Chiropractic sessions were rendered two to three times weekly and consisted of massage therapy, flexion distraction spinal traction and spinal manipulation. Treatment had been continued either until the maximum improvement was reached, or the patient's improvement plateaued. A 5-degree difference between two consecutive spine radiographs was interpreted as the threshold attributed to true change.

Radiography image analysis included various parameters on the initial evaluation and final radiographs taken one week after treatment completion. Assessment of skeletal maturation was performed using the Risser grading on the level of ossification and fusion of the iliac crest apophyses,⁹ and the cervical vertebral maturation (CVM) stages of Hassel & Farman.¹⁰ Radiography image measurements were used to quantitatively evaluate the spinal deformities and monitor changes over time. Coronal radiographic parameters included: i) Cobb

Correspondence: Eric Chun Pu Chu, New York Chiropractic and Physiotherapy Centre, 41/F Langham Place Office Tower, 8 Argyle Street, Hong Kong, China.
Tel.: +852.3594.7844 - Fax: +852.3594.6193.
E-mail: eric@nymg.com.hk

Key words: Adolescent idiopathic scoliosis; chiropractic treatment; Cobb angle; curve correction.

Contributions: EC delivered the treatment administration and wrote the manuscript. KH and VH provided the chiropractic treatment for patients and collected data. FL and AB reviewed and edited the manuscript critically. All authors have read and approved the final version.

Conflict of interests: the authors declare no potential conflict of interests.

Availability of data and materials: The data that support the findings of this study are available from the corresponding author, EC, upon reasonable request.

Ethics approval and consent to participate: This study was reviewed and deemed exempt by the Institutional Review Board of the Chiropractic Doctors Association of Hong Kong. Written informed consent was obtained from the guardians of all patients whose files were used in this study.

Received for publication: 23 April 2020.
Revision received: 24 August 2020.
Accepted for publication: 25 August 2020.

This work is licensed under a Creative Commons Attribution NonCommercial 4.0 License (CC BY-NC 4.0).

©Copyright: the Author(s), 2020
Licensee PAGEPress, Italy
Clinics and Practice 2020; 10:1258
doi:10.4081/cp.2020.1258

angle, the angle formed by the most tilted upper end vertebra (UEV) and the most tilted lower end vertebra (LEV); ii) LEV tilt, the angle formed by the lower endplate of the LEV and a horizontal line; iii) trunk shift, the deviation of C7 plumb line from the central sacral vertical line (CSVL); iv) apical vertebral translation (AVT), the horizontal distance from the C7 plumb line/CSVL to the midpoint of the apical vertebral body or disc for thoracic/lumbar curves; v) apical vertebral rotation (AVR), the rotation score of the apical vertebra according to the Nash-Moe grading; vi) pelvic obliquity, angle subtended by a line drawn between the most proximal points on the iliac crest and a horizontal line. The radiographic measurements are illustrated

in Figure 1. Descriptive statistics in terms of mean and standard deviation and percentage were calculated for continuous variables and frequencies for categorical. After the descriptive analysis, P-value was derived from a paired sample t-test for continuous variables obeying normal distribution. Two-tailed P-values of ≤ 0.05 were considered statistically significant. This study was reviewed and deemed exempt by the Institutional Review Board of the Chiropractic Doctors Association of Hong Kong.

Results

Ten Chinese children, 9 females and 1 male, exhibited clinical feature consistent with a diagnosis of AIS and exclusion of other causes were included in the retrospective analysis. The mean age of these patients was 13.3 ± 2.6 years and the mean Cobb angle was 29.7 ± 10.0 degrees. Six patients showed thoracolumbar/lumbar (TL/L) curvature. The other four had a double curve with right thoracic (T) and left lumbar (L) curves. One patient (Case 9) had failed to achieve a response from bracing for one year before chiropractic intervention. The other nine patients had not received any spinal care before chiropractic treatment. Case 2 and Case 7 are sisters.

The average period of treatment was 10.3 months ($SD \pm 4.3$, range 5-18 months). Significant correction of curve deformities was observed from a pretreatment Cobb angle of average 29.7° ($SD \pm 10.0$, range 11-46 $^\circ$) down to average 23.4° ($SD \pm 13.7$,

range 0-46 $^\circ$) at the final follow-up, an overall correction of average 21.2%. A better result was obtained in younger adolescents and in those with mild/moderate initial curves ($P \leq 0.05$). Before treatment, the average Cobb angle was 15.0° of mild curves ($n=3$) and 31.1° of moderate curves ($n=9$).

Curve corrections were significantly less apparent for late adolescents with more advanced curves ($P \geq 0.05$). On follow-up radiographs, there was no instance of curve deterioration ($\geq 6^\circ$ progression). No statistical significance was obtained in term of trunk shift, apical vertebral translation,

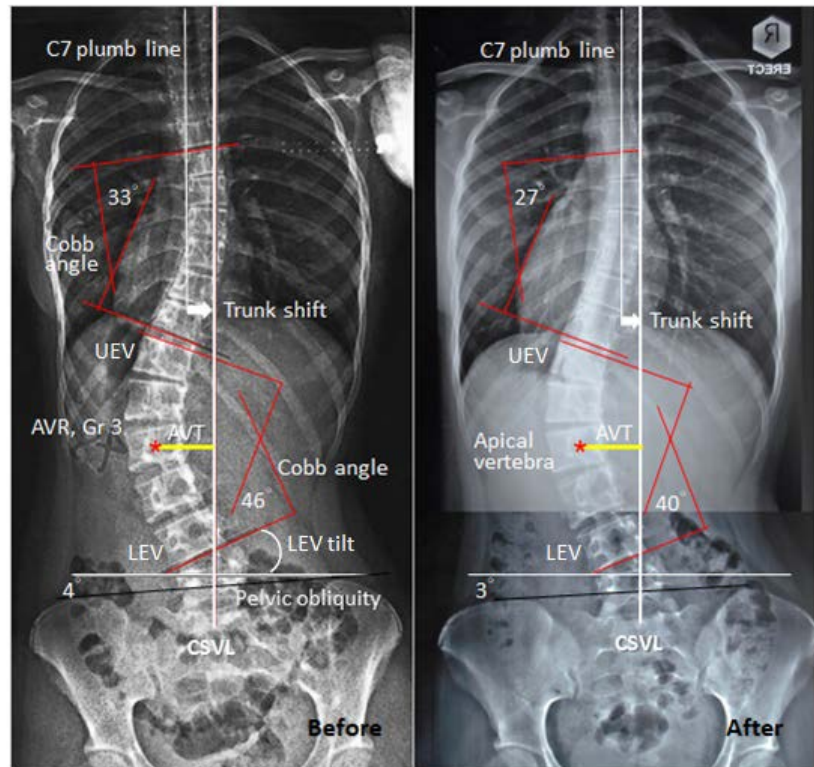


Figure 1. Comparison of pre- and post-treatment radiographs of a 16-year-old girl (Case 9) who had failed to achieve a response from bracing for one year before chiropractic intervention. Following 13 months of chiropractic manipulation, improvements in spinal morphologies were observed.

Table 1. Clinical characteristics of 10 patients in current case series.

Case	Age (years)	Sex	Risser grade (0-5)	CVM Stage (1-6)	Curve patterns	AVR (grade)	Angle change (0-4+)	Percent change (%)	Effect*	FU time (months)
1	7.9	M	0	2	Rt T Lt L	1+ 0	15°/0° 11°/1°	-100 -90.9	Corr Corr	9
2	12.0	F	1	3	Lt T-L	0	19°/7°	-63.1	Corr	9
3	12.4	F	1	3	Lt L	0	29°/21°	-27.5	Corr	13
4	12.6	F	3	3	Rt T-L	0	28°/21°	-25.0	Corr	15
5	12.7	F	3	4	Rt T Lt L	0 0	34°/31° 27°/17°	-8.8 -37.0	Stab Corr	6
6	13.3	F	3	4	Rt T Lt L	0 1+	28°/26° 35°/28°	-7.1 -20.0	Stab Corr	18
7	13.7	F	4	5	Lt T-L	2+	35°/37°	+5.7	Stab	5
8	14.8	F	4	5	Rt T-L	2+	46°/46°	±0	Stab	5
9	15.8	F	4	5	Rt T Lt L	3+ 3+	33°/27° 46°/40°	-18.1 -13.0	Corr Corr	13
10	17.8	F	5	5	Lt T-L	2+	31°/26°	-16.1	Stab	10

CVM, C-vertebral maturity; AVR, apical vertebral rotation; FU, follow up; Rt, right; T, thoracic; L, left; L, lumbar. *A successful treatment is defined as correcting curves (Corr) $\geq 6^\circ$ or stabilizing curves (Stab) $\pm 5^\circ$ of baseline values.

Table 2. Comparative analysis of radiographic parameters in the treatment of adolescent idiopathic scoliosis.

Variables	Baseline Mean±SD	Follow up Mean±SD	P-value
Scoliosis Cobb angle (°)			
Mild curve, ≤20°, n=3	15.0±4.0	2.6±3.7	0.0178*
Moderate curve, 21°-40°, n=9	31.1±3.2	26.0±5.9	0.0373*
Severe curve, ≥41°, n=2	46.0±0.0	43.0±4.2	0.4226
Trunk shift (mm)	13.8±8.4	9.4±9.3	0.284
AVT (mm)	20.2±12.2	16.7±13.2	0.482
LEV tilt (°)	15.8±5.1	12.5±7.3	0.173
Pelvic obliquity (°)	2±1.4	1.1±1.4	0.187

SD, standard deviation; AVT, apical vertebral translation; LEV, lower end vertebra. *Means significant difference of the parameters between baseline and final follow-up.

lower end vertebra tilt and pelvic obliquity ($P \geq 0.05$).

As illustrated in Figure 1, Case 9, with initial Risser pelvis grading of 4 and C-vertebral maturity of stage 5, had a moderate to severe double curve. Before chiropractic treatment she had attempted one year of bracing, but failed to stop curve progression. After chiropractic treatment, the patient's thoracic curve was reduced from 33° to 27° (18.1% improvement) and lumbar curve was reduced from 46° to 40° (13.0% improvement). In terms of curve stabilization ($\leq 5^\circ$ progression) or curve correction ($\geq 6^\circ$ reduction), the patient achieved a successful treatment. No adverse events occurred during the treatment period. Table 1 presents the clinical characteristics of each patient. Table 2 lists the changes of the radiographic parameters between the initial and final visits.

Discussion

AIS is a lateral and rotational deformity of the spine. Traditionally, Cobb angle indicates the degree of lateral curvature of the spine measured on a coronal radiographic projection. Apical vertebral translation (AVT) and apical vertebral rotation (AVR) provide better understanding of the scoliotic spines. The apex of the scoliotic spines is the vertebra (or disc) with the furthest deviation or greatest rotation from the central axis of the vertebral column. Vertebral translation is a parameter used to indirectly assess trunk balance. The larger the translation of the apex of the curve from the CSVL, the more likely it is that the spine requires a fusion procedure.¹¹ Vertebral rotation may act as an indicator of curve progression, thus being clinically applicable for both preoperative and postoperative assessment.¹² To measure the vertebral rotation, the Nash-Moe technique is commonly

used to classify the offsetting position of the pedicle-shadows. The locations of pedicle-shadows on a plane frontal radiograph only represent a projected, not actual, rotation.¹² According to the research of 30 sets of long-cassette scoliosis radiographs by Kuklo *et al.*,¹³ most of the radiographic measures (*i.e.*, the coronal Cobb angles, apical vertebral translation, apical Nash-Moe rotation, and Risser sign also used in this study) demonstrated good to excellent intraobserver and interobserver reliability. Nevertheless, due to a small patient size and small radiographic changes in relation to the treatment, we were unable to pool subgroups for the comparative analysis for treatment response in most radiographic parameters of this study.

The primary goal of conservative management for scoliosis is to stop the curve progression or possibly even reduce it.³ Conservative therapies such as physiotherapy, strengthening exercises, spinal bracing, chiropractic and acupuncture are used to control remaining spinal growth and to stabilize curve progression by strengthening the back muscles, correcting spinal loading and posture, and stiffening the spine. The success of conservative treatments is most commonly defined by preventing a curve progression of $\leq 5^\circ$ (stabilization) or even a decrease of the curve of $\geq 6^\circ$ (correction) from baseline values.³ Of the fourteen curves investigated in the present study, the outcomes of five curves fulfilled the criteria for curve stabilization ($\leq 5^\circ$ progression) and the other nine curves fulfilled the criteria for curve correction ($\geq 6^\circ$ decrease) at the end of the treatment (Tables 1 and 2).

The absolute goals of conservative treatment are to avoid surgery, improve aesthetics and improve quality of life.³ It is suggested that the shearing force resultant from asymmetric spinal loading contributes to curve progression in AIS.¹⁴ Any correction by conservative means would be biomechanically beneficial, as a straighter

spine would be subject to less shearing force and would, therefore, be less vulnerable to curve progression.¹⁵ Idiopathic scoliosis may progress to long-term effects, such as pain, limiting physical and psychological functions, and negative effect on quality of life and self-esteem.¹⁶ The improved Cobb angles can lead not only to enhance the physical functions, but also to an increase of life satisfaction. Patients' perceived improvement could arise in response to other effects of the conservative interventions even when the Cobb angles showed little to no change.¹⁷ Recent literature reviews^{8,18} found that a multidisciplinary approach is the best for AIS. Spinal manipulative therapy and soft-tissue mobilization in conjunction with other conservative regimens such as bracing and corrective exercises may potentially be effective in treating AIS.^{4,8} These techniques can translate to correct muscular imbalances, mobilize stiff tissues, restore postural alignment, stabilize curve(s) and improve proprioceptive input.^{8,18,19}

According to the SOSORT recommendations, most children with mild scoliosis ($< 20^\circ$) will only undergo periodic checkups to wait to see if progression occurs. Nevertheless, it is critical to treat scoliosis in the early stages of puberty. Current evidence demonstrates that the risk of progression at the beginning of puberty is 20% in 10° scoliosis, 60% in 20° scoliosis, and as much as 90% in 30° scoliosis.³ When compared to a mature spine, the pediatric spine has more cartilaginous components, secondary ossification centers and relative laxity of the ligaments and joints, the immature spine is thus more amenable to conservative treatment. The role of conservative treatment in the correction of Cobb angles in adult idiopathic scoliosis patients remains unknown. The practice of periodic monitoring with no intervention for mild AIS should be taken on re-evaluation case by case. Many patients and their families pre-

fer not to delay seeking treatment until the eventual curve progression. Self-image of trunk disfigurement is actually an important issue requiring earlier management.³

This study was limited by small sample size, retrospective design and absence of a control or sham treatment group. Furthermore, all radiographs were ultimately measured by one of the authors and no interobserver performance in Cobb angle measures was obtained. These risks of bias can threaten the validity of results and affect conclusions. Despite these limitations, improvements in spinal morphologies were observed following a trial of chiropractic regimen. Our findings may explain, at least partly, a known association between the chiropractic manipulations and the morphologic changes of scoliotic curvatures.

Conclusions

Positive radiological changes were observed in all of the study patients following a trial of chiropractic manipulation. Additional researches to better clarify the potential role of chiropractic regimen are warranted.

References

- Horne JP, Flannery R, Usman S. Adolescent idiopathic scoliosis: diagnosis and management. *Am Fam Physician* 2014;89:193-8.
- Cobb JR. Outline for the study of scoliosis. In: Edwards JW, ed. *The American Academy of Orthopedic Surgeons instructional course lectures*, vol. 5, 2nd edn. Ann Arbor, MI: American Academy of Orthopaedic Surgeons; 1948. pp. 261-75.
- Negrini S, Donzelli S, Aulisa AG, et al. 2016 SOSORT guidelines: orthopaedic and rehabilitation treatment of idiopathic scoliosis during growth. *Scoliosis Spinal Disord* 2018;13:3.
- Morningstar M, Oslin D. Chiropractic rehabilitation plus nighttime bracing for progressive adolescent idiopathic scoliosis: a case-control series. *Clin Pract* 2019;9:118-22.
- Byun S, Han D. The effect of chiropractic techniques on the Cobb angle in idiopathic scoliosis arising in adolescence. *J Phys Ther Sci* 2016;28:1106-10.
- Rowe DE, Feise RJ, Crowther ER, et al. Chiropractic manipulation in adolescent idiopathic scoliosis: a pilot study. *Chiropr Man Therap* 2006;14:15.
- Chu ECP, Huang KHK. Bridging the gap between observation and brace treatment for adolescent idiopathic scoliosis. *J Family Med Prim Care* 2017;6:447-9.
- Lotan S, Kalichman L. Manual therapy treatment for adolescent idiopathic scoliosis. *J Bodyw Mov Ther* 2019;23:189-93.
- Risser JC. The Iliac apophysis: an invaluable sign in the management of scoliosis. *Clin Orthop* 1958;11:111-9.
- Hassel B, Farman AG. Skeletal maturation evaluation using cervical vertebrae. *Am J Orthod Dentofacial Orthop* 1995;107:58-66.
- Jada A, Mackel CE, Hwang SW, et al. Evaluation and management of adolescent idiopathic scoliosis: a review. *Neurosurg Focus* 2017;43:E2.
- Lam GC, Hill DL, Le LH, et al. Vertebral rotation measurement: a summary and comparison of common radiographic and CT methods. *Scoliosis* 2008;3:16.
- Kuklo TR, Potter BK, Polly DW Jr, et al. Reliability analysis for manual adolescent idiopathic scoliosis measurements. *Spine (Phila Pa 1976)* 2005;30:444-54.
- Stokes IA. Analysis of symmetry of vertebral body loading consequent to lateral spinal curvature. *Spine* 1997;22:2495-503.
- Harrison DE, Oakley PA. Scoliosis deformity reduction in adults: a CBP® Mirror Image® case series incorporating the 'non-commutative property of finite rotation angles under addition' in five patients with lumbar and thoracolumbar scoliosis. *J Phys Ther Sci* 2017;29:2044-50.
- Carrasco MIB, Ruiz MCS. Idiopathic adolescent scoliosis: living with a physical deformity. *Texto Contexto Enferm* 2016;25:e3640014.
- Schreiber S, Parent EC, Hill DL, et al. Patients with adolescent idiopathic scoliosis perceive positive improvements regardless of change in the Cobb angle - results from a randomized controlled trial comparing a 6-month Schroth intervention added to standard care and standard care alone. *SOSORT 2018 Award winner. BMC Musculoskelet Disord* 2019;20:319.
- Day JM, Fletcher J, Coghlan M, Ravine T. Review of scoliosis-specific exercise methods used to correct adolescent idiopathic scoliosis. *Arch Physiother* 2019;9:8.
- Berdishevsky H, Lebel VA, Bettany-Saltikov J, et al. Physiotherapy scoliosis-specific exercises - a comprehensive review of seven major schools. *Scoliosis Spinal Disord* 2016;11:20.