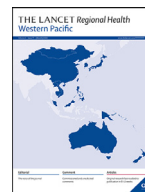



ELSEVIER

Contents lists available at ScienceDirect

## The Lancet Regional Health - Western Pacific

journal homepage: [www.elsevier.com/locate/lanwpc](http://www.elsevier.com/locate/lanwpc)

## Research paper

## Detachable string magnetically controlled capsule endoscopy for detecting high-risk varices in compensated advanced chronic liver disease (CHESS1801): A prospective multicenter study

Shuai Wang<sup>a,1</sup>, Yifei Huang<sup>b,c,1</sup>, Weiling Hu<sup>d,1</sup>, Hua Mao<sup>c,1</sup>, Mark Edward McAlindon<sup>e,1</sup>, Yanna Liu<sup>b,1</sup>, Li Yang<sup>f</sup>, Chunqing Zhang<sup>g</sup>, Ming Xu<sup>h</sup>, Chaohui He<sup>i</sup>, Tong Dang<sup>j</sup>, Bin Wu<sup>k</sup>, Dong Ji<sup>a</sup>, Liting Zhang<sup>l</sup>, Xiaorong Mao<sup>m</sup>, Lei Zhang<sup>n</sup>, Chuan Liu<sup>b</sup>, Dan Xu<sup>b</sup>, Yasong Li<sup>o</sup>, Guoan Li<sup>o</sup>, Juqiang Han<sup>o</sup>, Fangfang Lv<sup>p</sup>, Xiao Liang<sup>q</sup>, Shaoqin Jin<sup>c</sup>, Shaoheng Zhang<sup>c</sup>, Foong Way David Tai<sup>e</sup>, Qing Xu<sup>f</sup>, Changqing Yang<sup>f</sup>, Guangchuan Wang<sup>g</sup>, Lifan Wang<sup>g</sup>, Bo Li<sup>h</sup>, Haiyun Yang<sup>h</sup>, Ping Xie<sup>i</sup>, Lulin Deng<sup>i</sup>, Limei Ren<sup>j</sup>, Zhiheng Chang<sup>j</sup>, Xing Wang<sup>k</sup>, Shan Wang<sup>l</sup>, Xiaoqin Gao<sup>l</sup>, Junfeng Li<sup>m</sup>, Longdong Zhu<sup>m</sup>, Fangzhao Wang<sup>n</sup>, Lingen Zhang<sup>n</sup>, Guo Zhang<sup>r</sup>, Xi Jiang<sup>s</sup>, Jun Pan<sup>s</sup>, Wenbo Meng<sup>t</sup>, Xun Li<sup>t</sup>, Jinlin Hou<sup>u</sup>, Xavier Dray<sup>v</sup>, Zhuan Liao<sup>s</sup>, Xiaolong Qi<sup>b,\*</sup>

<sup>a</sup> CHESS Center, Department of Liver Diseases, The Fifth Medical Center, Chinese PLA General Hospital, Beijing, China

<sup>b</sup> CHESS Center, Institute of Portal Hypertension, The First Hospital of Lanzhou University, Lanzhou, China

<sup>c</sup> Department of Gastroenterology, Zhujiang Hospital, Southern Medical University, Guangzhou, China

<sup>d</sup> Department of Gastroenterology, Sir Run Run Shaw Hospital, Medical School; Institute of Gastroenterology, Zhejiang University, Hangzhou, China

<sup>e</sup> Academic Department of Gastroenterology and Hepatology, Sheffield Teaching Hospitals NHS Trust, Sheffield, UK

<sup>f</sup> Division of Gastroenterology and Hepatology, Digestive Disease Institute, Shanghai Tongji Hospital, Tongji University School of Medicine, Shanghai, China

<sup>g</sup> Department of Gastroenterology, Shandong Provincial Hospital Affiliated to Shandong First Medical University, Jinan, China

<sup>h</sup> Department of Gastroenterology, Guangdong Second Provincial General Hospital, Guangzhou, China

<sup>i</sup> Department of Gastroenterology, The Fifth Affiliated Hospital of Zunyi Medical University, Zuhai, China

<sup>j</sup> Department of Gastroenterology, The Second Affiliated Hospital of Baotou Medical College, Baotou, China

<sup>k</sup> Department of Gastroenterology, Third Affiliated Hospital of Sun Yat-sen University, Guangdong Province Engineering and Technology Research Center of Digestive Endoscopy, Guangzhou, China

<sup>l</sup> Department of Hepatology, The First Hospital of Lanzhou University, Lanzhou, China

<sup>m</sup> Department of Infectious Diseases, The First Hospital of Lanzhou University, Lanzhou, China

<sup>n</sup> Department of General Surgery, The First Hospital of Lanzhou University, Lanzhou, China

<sup>o</sup> Department of Liver Diseases, the Seventh Medical Center, Chinese PLA General Hospital, Beijing, China

<sup>p</sup> Department of Infectious Diseases, Sir Run Run Shaw Hospital, School of Medicine, Zhejiang University, Hangzhou, China

<sup>q</sup> Department of General Surgery, Sir Run Run Shaw Hospital, School of Medicine, Zhejiang University, Hangzhou, China

<sup>r</sup> Department of Gastroenterology, The People's Hospital of Guangxi Zhuang Autonomous Region, Nanning, China

<sup>s</sup> National Clinical Research Center for Digestive Diseases, Department of Gastroenterology, Changhai Hospital, Shanghai, China

<sup>t</sup> The First Hospital of Lanzhou University, Lanzhou, China

<sup>u</sup> Department of Infectious Diseases, Nanfang Hospital, Southern Medical University, Guangzhou, China

<sup>v</sup> Sorbonne University, Centre for Digestive Endoscopy, Saint Antoine Hospital, APHP, Paris, France

## ARTICLE INFO

## Article history:

Received 26 August 2020

Revised 15 November 2020

Accepted 26 November 2020

Available online 11 December 2020

## ABSTRACT

**Background:** Gastroesophageal varices is a serious complication of compensated advanced chronic liver disease (cACLD). Primary prophylaxis to reduce the risk of variceal hemorrhage is recommended if high-risk varices (HRV) are detected. We performed this study to compare the accuracy, patients' satisfaction and safety of detection of HRV by detachable string magnetically controlled capsule endoscopy (DS-MCCE) with esophagogastroduodenoscopy (EGD) as the reference.

\* Corresponding author.

E-mail addresses: [xavier.dray@aphp.fr](mailto:xavier.dray@aphp.fr) (X. Dray), [liao.zhuan@smmu.edu.cn](mailto:liao.zhuan@smmu.edu.cn) (Z. Liao), [qxixiaolong@vip.163.com](mailto:qxixiaolong@vip.163.com) (X. Qi).

<sup>1</sup> These authors contributed equally to this work.

**Keywords:**

Clinical trial  
 Prospective  
 Portal hypertension  
 Gastroesophageal varices  
 Esophagogastroduodenoscopy

**Methods:** We prospectively recruited participants with cACLD from 12 university hospitals (11 in China and one in the United Kingdom) between November 2018 and December 2019 (ClinicalTrials.gov, NCT03749954). All participants underwent DS-MCCE, followed by EGD within a week in a blinded fashion. Following endoscopy, and on the same day, participants were asked to fill in a satisfaction questionnaire regarding their experience.

**Findings:** A total of 105 eligible participants were enrolled. With EGD as the reference standard, the concordance index, sensitivity, specificity, positive predictive value, negative predictive value, positive likelihood ratio, and negative likelihood ratio of DS-MCCE in diagnosis of HRV were 0.90 (95% confidence interval [CI]: 0.83–0.95), 92% (95% CI: 78–98%), 88% (95% CI: 78–95%), 80% (95% CI: 70–92%), 95% (95% CI: 90–100%), 7.91 (95% CI: 4.10–15.30), and 0.09 (95% CI: 0.03–0.30), respectively. The kappa score of 0.78 (95% CI: 0.65–0.90) suggested substantial agreement between DS-MCCE and EGD. Moreover, in participants undergoing EGD without sedation, the satisfaction of DS-MCCE was significantly better than that of EGD ( $p < 0.0001$ ,  $d = 1.15$  [95%CI: 0.88–1.42]). All participants confirmed the excretion of the capsule, and no adverse events occurred.

**Interpretation:** DS-MCCE is an accurate alternative to EGD for detecting HRV in cACLD, which is safe and associated with better satisfaction.

**Funding:** A full list of funding can be found in the Funding Support section.

© 2020 The Authors. Published by Elsevier Ltd.

This is an open access article under the CC BY-NC-ND license (<http://creativecommons.org/licenses/by-nc-nd/4.0/>)

**Research in context****Evidence before this study**

The presence of high-risk varices (HRV) is a serious complication of compensated advanced chronic liver disease (cACLD). To prevent variceal hemorrhage, screening and surveillance aims to detect HRV in cACLD and determine the need for primary prophylaxis. Capsule endoscopy is a non-invasive substitute for esophagogastroduodenoscopy (EGD) which allows direct inspection of HRV. We searched PubMed on May 16, 2020, for publications using the search terms “capsule endoscopy” AND “varices” with no language or time restrictions. The pooled estimate from articles showed six studies designed to explore the diagnostic performance of capsule endoscopy for diagnosing HRV; however, no study demonstrated its performance in well-characterized patients with cACLD. The present study aimed at evaluating the diagnostic performance, patients' satisfaction, and safety of the detachable string magnetically controlled capsule endoscopy (DS-MCCE) for detecting HRV in patients with cACLD.

**Added value of this study**

The prospective, multicenter, blinded trial first demonstrated the excellent diagnostic performance of DS-MCCE for detecting HRV in well-characterized cACLD. In addition, in participants undergoing EGD without sedation, the satisfaction of DS-MCCE was significantly better than that of EGD. All participants confirmed the excretion of the capsule, and no adverse events occurred.

**Implications of all the available evidence**

DS-MCCE is safe and accurate in the detection of HRV in patients with cACLD, which has important implications for screening and surveillance for HRV in clinical practice. In addition, DS-MCCE is better tolerated and thus may be indicated for those unwilling or unable to undergo EGD screening for HRV. More importantly, DS-MCCE could be performed under the direct supervision of the endoscopist from a computer workstation in an adjacent but separate room. As the COVID-19 continues to spread throughout the world, non-contact DS-MCCE can minimize risk of cross-infection and protect health-care providers better.

**Introduction**

The presence of gastroesophageal varices (GEV) is a common and serious complication of compensated advanced chronic liver disease (cACLD) [1–3]. GEV hemorrhage is associated with a six week mortality rate of between 15% and 25% [2,3]. In order to prevent variceal hemorrhage, screening and surveillance aims to detect high-risk varices (HRV) and determine the need for primary preventative therapy [2,3]. Esophagogastroduodenoscopy (EGD) is therefore an important part of the diagnostic work-up in patients with cACLD, serving as the gold standard to diagnose HRV [2,3]. However, EGD is invasive and poorly tolerated, with many patients needing intravenous sedatives or general anesthesia. Although EGD with sedation relieves patients' anxiety and discomfort and reduces the potential for physical injury during the procedure, it incurs additional risks of cardiopulmonary adverse events [4]. Consequently, patients may decline a screening procedure if they are stable and asymptomatic.

Non-invasive methods for detection of cACLD are being explored [5–13]. Although preliminary research is encouraging, these techniques predict the presence, rather than confirm or assess the size, of GEV. By contrast, capsule endoscopy is a non-invasive alternative which also allows direct visualization of GEV [14]. A number of well-conducted trials [15–19] suggest that EGD and capsule endoscopy may be equivalent in terms of accuracy in the identification and grading of varices. However, concerns remain that the quality of examination may be adversely affected by the uncontrolled and sometimes rapid transit of the capsule through the esophagus [20]. String capsule endoscopy was introduced to address this concern by providing control of capsule movement as well as real-time visualization [21]. However, this technique is limited by the inability to detach the string from the capsule. Thus, observation of the fundus, one of the predilection sites of varices, is impossible and retrieval of the capsule from the esophagus causes discomfort.

Magnetically controlled capsule endoscopy (MCCE), a novel modality, was developed and approved by the China Food and Drug Administration in 2013. [22]. Our previous studies initially demonstrated that MCCE was comparable in accuracy to EGD for gastric examination [22,23]. Furthermore, it has several strengths including non-invasiveness, no sedation requirement, and easy op-

eration [22,23]. We have since combined an innovative detachable string system with the MCCE (detachable string magnetically controlled capsule endoscopy (DS-MCCE)) and carried out a pilot study showing that DS-MCCE was safe and feasible both in healthy volunteers and patients with suspected esophageal disease [24]. Moreover, successful detachment of the capsule from the string avoids the discomfort of retrieving the entire capsule from the mouth and allows subsequent investigation of the gastric cardia and fundus. To our knowledge, the diagnostic accuracy of HRV, comfort and safety of DS-MCCE in patients with cACLD have not been explored in a large-scale trial. This prospective, multicenter study aimed to assess the accuracy, patient's satisfaction, and safety of DS-MCCE for detecting HRV in well-characterized patients with cACLD.

## Methods

### Study design and participants

This study (CHESS1801 trial) was a multicenter blinded comparison trial (ClinicalTrials.gov identifier: NCT03749954), in which we prospectively recruited well-defined participants with cACLD from 12 university hospitals (11 in China and one in the United Kingdom) between November 2018 and December 2019. Inclusion criteria were: 1) clinically evident or biopsy-confirmed cACLD; 2) a schedule to undergo an EGD; 3) age between 18 and 75 years; 4) a life expectancy of at least 24 months without liver transplantation; 5) Model for End Stage Liver Disease score of 29 or less; 6) written informed consent. Participants with any contraindications to MCCE were excluded [22]. The study protocol conformed to the ethical guidelines of the Declaration of Helsinki, and was approved by the institutional review board of all institutions.

### Procedure

The DS-MCCE system (Ankon Technologies Co, Ltd, Wuhan, China) consists of a thin latex sleeve attached to a hollow string, an endoscopic capsule, a magnetic guidance robot with five-degree-of-freedom (two rotational and three translational) robotic arm, a data recorder, and a computer workstation with the NaviCam<sup>®</sup> magnetic capsule guidance software for real-time viewing and control. The string is 80 cm in length, attached to the sleeve on the caudal end of the capsule, and a sterile syringe for single use. The capsule is 27 mm in length and 11.8 mm in diameter, with a permanent magnet inside its dome and a camera at one end (Figure S1A). It is partially enclosed within the sleeve and can be separated from the string system by using the syringe to inject air into the hollow string after exploring the whole esophagus. Images are captured at a rate of two frames per second. The angle of view is up to 140 degree. A CMOS image sensor is used in DS-MCCE. The LED light exposure time and signal gain of CMOS sensor are automatically adjusted by measuring the histogram of the image to optimize brightness and contrast of the images. The operator uses two joysticks to control capsule movement by varying the strength of the magnetic field (by altering the distance of the magnet from the patient) and the polarity of the magnet (Figure S1B). Recording and downloading data are similar to other capsule endoscopies.

An overnight fast (> 8 h) was needed before the DS-MCCE examination. At 30 min before examination, study participants ingested 2.5 g of dimethicone powder (Honghe Medicine, Zigong, China) dissolved in 50 mL of water or 400 mg of simethicone suspension (Espumisan, Berlin-Chemie, Germany) dissolved in 50 mL of water as a defoaming agent, followed by 500–1000 mL of water to fill the stomach cavity to provide a better view. Participants were positioned in the left lateral decubitus and swallowed the

capsules with a small amount of water. The capsule was permitted to move passively as far as the cardia, from where the string was slowly pulled up to inspect the esophagus in real time. Regions of interest could be observed repeatedly. When the capsule reached the stomach after the esophageal observation, the string could be detached from the capsule by injecting 5–10 mL of air using the syringe. The string was then removed from the mouth and discarded. The capsule was controlled magnetically to observe the whole stomach surface area. A common protocol involved observation in the order of the fundus, cardiac regions, body, angulus, antrum, and pylorus, with the patients' body position changing from left lateral, supine to right lateral [22]. Meanwhile, water ingestion was repeated if there was insufficient gastric distention. All participants were followed during two weeks to check for capsule excretion and for any adverse events. DS-MCCE was performed by a dedicated operator at each center. All operators had been trained in a standardized manner before the enrollment.

EGD examinations were performed by experienced endoscopists using conventional standard forward-viewing upper gastrointestinal video endoscopes at individual centers and were blinded to the DS-MCCE findings. EGD was performed within a week of capsule ingestion, either without or with sedation according to the standard procedure of the center and to the preference of the patient. All major findings were recorded on digital pictures and then reported as the EGD results.

Conventional non-invasive models including image-based indexes including portal venous velocity, portal diameter, liver stiffness (LS), and LS-spleen size-to-platelet ratio score (LSPS), [13] and serum-based parameters including serum aspartate aminotransferase to alanine aminotransferase ratio (AAR), [6] aspartate aminotransferase to and platelet count ratio index (APRI), [7] fibrosis index based on four factors (FIB-4), [8] Fibrosis Index, [9] gamma glutamyl trans-peptidase to platelet count ratio (GPR), [10] King's score, [11] and Lok score [12] were collected. LS was measured by transient elastography (FibroScan, Echosens, France; or FibroTouch, Hisky, China). Portal diameter, portal venous velocity, and spleen size were measured with Doppler ultrasound. Calculation formulas for LSPS, AAR, APRI, FIB-4, Fibrosis Index, GPR, King's score, and Lok score were summarized in Table S1.

### Outcomes

The primary outcome was the diagnostic performance of DS-MCCE for HRV, identified by either large varices (varices size > 5 mm) or small varices with presence of red signs according to the Baveno VI consensus [25]. In this study, EGD served as the gold standard for HRV. Two independent experienced interpreters, blinded to the patients' EGD results, reviewed the coded images of all participants captured by DS-MCCE and rendered their opinions as to whether the patients had evidence of HRV. When there was a disagreement, a decision was made by a third independent reader. As for EGD results, saved pictures of all participants were transferred to two independent and experienced endoscopists who were blinded to each patient's history for evaluation. In the event of discordant judgements, the opinion of a third independent interpreter was sought.

The secondary outcomes included patients' satisfaction and safety of DS-MCCE. A satisfaction questionnaire (Appendix) regarding patients' preoperative perception and postoperative satisfaction was developed referring to a previous research [15]. The questionnaire was submitted to a panel comprising three professionals with expertise in gastroenterology, outcome measurement or psychology for evaluation before the questionnaire was put into the trial. Participants were asked to fill in a satisfaction questionnaire after each procedure (DS-MCCE and EGD). The questionnaire consisted

of 11 questions with total score ranged from 0 (poor) to 41 (excellent).

### Statistical analysis

The sample size calculation was based on a reported sensitivity, specificity, and prevalence of HRV in capsule endoscopy of 78%, 96%, and 27%, respectively [15]. A sample size of 101 participants was calculated by PASS (version 11.0, NCS, 2012) to be required to provide a power of 90% at a statistical significance level of 0.05, allowing for a 5% dropout rate.

Categorical data were expressed as numbers (percentages), and continuous variables were expressed as mean (standard deviation) or median (interquartile range). With EGD as the reference standard, the diagnostic performance for detecting HRV of DS-MCCE was assessed by concordance index (C-index), sensitivity, specificity, positive predictive value (PPV), negative predictive value (NPV), positive likelihood ratio (+LR), and negative likelihood ratio (-LR). The beyond-chance agreement also known as the kappa score, between the DS-MCCE and the EGD was also calculated. Kappa values between 0.40 and 0.60 were considered of moderate agreement whereas values between 0.60 and 0.80 were substantial [26]. Diagnostic performance of other conventional non-invasive models were compared using the area under the receiver operating characteristic curve (AUC), sensitivity, specificity, PPV, and NPV. Comparison of satisfaction and safety between DS-MCCE and EGD was tested using a student's *t*-test on paired data. A *p* value of < 0.05 was considered significant. An effect size (*d* value) > 0.80 was considered high effect. All statistical calculations were performed with R language (version 3.6.2, R Core Team, 2019).

### Role of the funding source

The funders had no role in study design; the collection, analysis, and interpretation of data; writing of the report; or the decision to submit for publication. The corresponding author had full access to all of the data and the final responsibility to submit for publication.

### Results

Between November 9, 2018, and December 20, 2019, a total of 113 consecutive eligible participants with well-characterized cACLD from 12 university hospitals in China and the United Kingdom were involved in this prospective trial. Among them, two participants were excluded because of failure to swallow the capsule. In addition, six were excluded during evaluation due to insufficient recordings of EGD ( $n = 5$ ) and DS-MCCE ( $n = 1$ ). Therefore, 105 eligible participants were enrolled in the final analysis (Fig. 1). The most common cause of cACLD was hepatitis B virus infection (66, 63%). Baseline characteristics of the enrolled participants were summarized in Table 1.

DS-MCCE operation procedure and representatives of high-risk and low-risk varices inspected by DS-MCCE and EGD were illustrated in Fig. 2. EGD detected HRV in 36 (34%) patients and DS-MCCE identified HRV in 33 (31%) of these. In eight cases, the diagnosis of HRV by the DS-MCCE was not confirmed by EGD. The C-index, sensitivity, specificity, PPV, NPV, +LR, -LR of DS-MCCE for detection of HRV were 0.90 (95% confidence interval [CI]: 0.83–0.95), 92% (95% CI: 78–98%), 88% (95% CI: 78–95%), 80% (95% CI: 70–92%), 95% (95% CI: 90–100%), 7.91 (95% CI: 4.10–15.30), and 0.09 (95% CI: 0.03–0.30), respectively. The kappa score between EGD and DS-MCCE on HRV diagnosis was 0.78 (95% CI: 0.65–0.90), demonstrating a substantial agreement.

Compared to conventional non-invasive tools, DS-MCCE showed the best diagnostic performance with an AUC of 0.90 (95% CI:

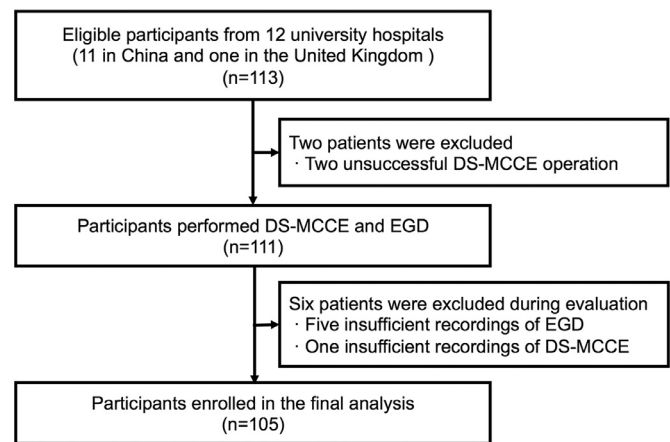


Fig. 1. Flowchart of study enrollment.

DS-MCCE, detachable string magnetically controlled capsule endoscopy; EGD, esophagogastroduodenoscopy.

Table 1  
Baseline characteristics of participants.

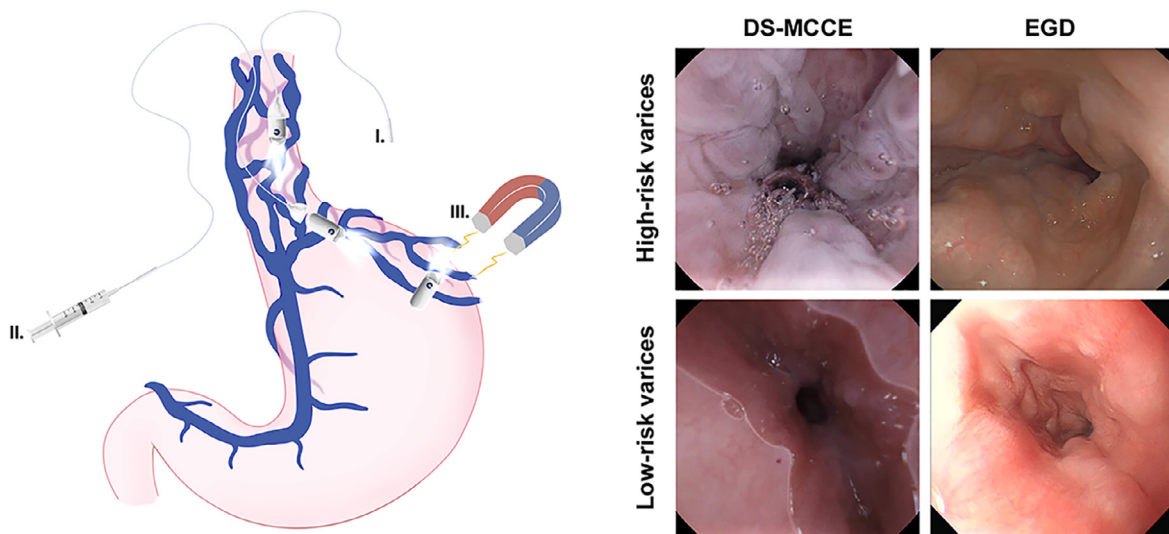
	Participants ( $n = 105$ )
Age (year), mean (SD)	50.80 (11.11)
Male, $n$ (%)	80 (76)
Etiology, $n$ (%)	
Hepatitis B infection	66 (63)
Alcoholic liver disease	10 (10)
Primary biliary cirrhosis	9 (9)
Hepatitis C infection	3 (3)
Autoimmune	2 (2)
Non-alcoholic steatohepatitis	2 (2)
Other	13 (12)
Child-Pugh Class, $n$ (%)	
Class A	95 (90)
Class B	10 (10)
Laboratory tests, median (IQR)	
Platelet count ( $10^9/L$ )	99.00 (78.50)
Alanine aminotransferase (U/L)	28.00 (24.55)
Aspartate aminotransferase (U/L)	31.00 (21.83)
Gamma-glutamyl transpeptidase (U/L)	44.00 (79.85)
Albumin (g/L)	39.60 (6.95)
Total bilirubin ( $\mu\text{mol/L}$ )	18.80 (12.39)
Prothrombin time (s)	13.50 (2.73)
International normalized ratio	1.10 (0.17)

Percentages in some categories may not add up to 100% due to rounding. SD, standard deviation; IQR, interquartile range.

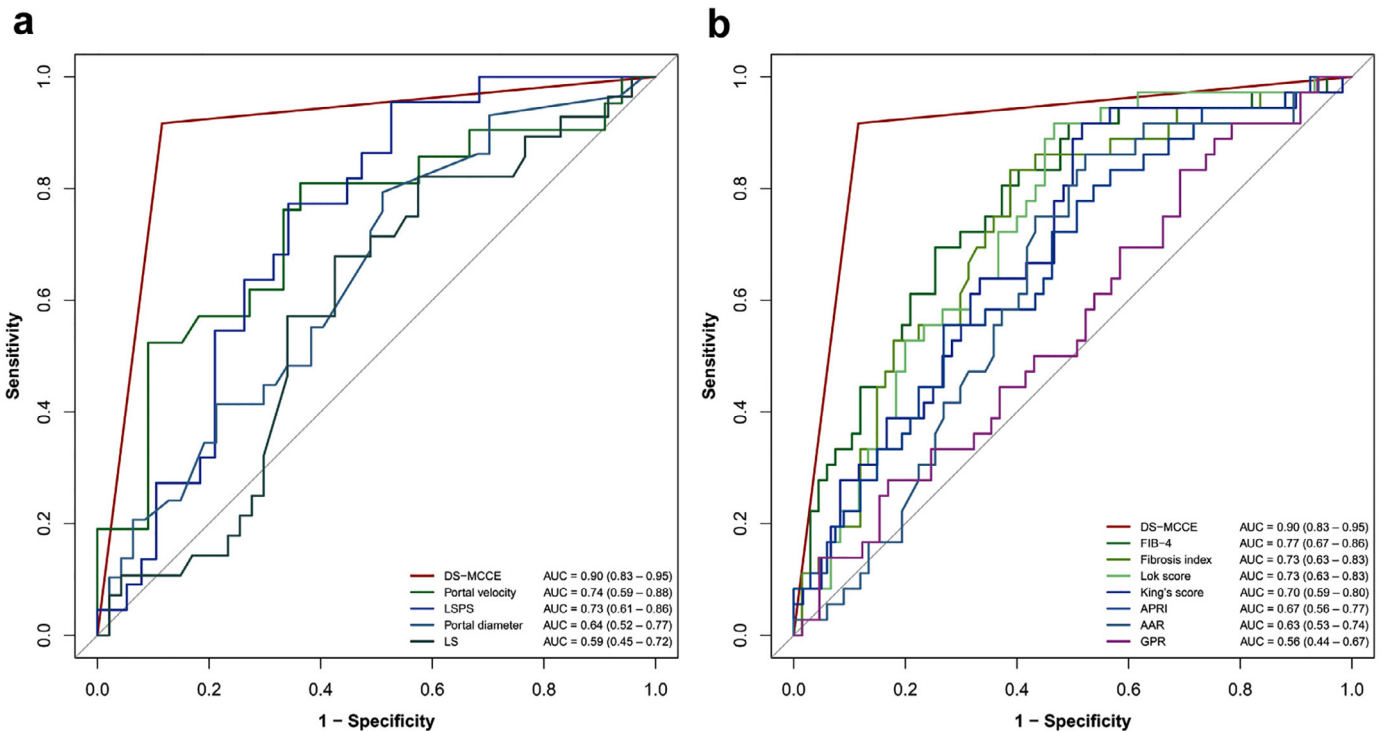
0.83–0.95). As for the image-based indexes including portal velocity, LSPS, portal diameter and LS, the AUCs were 0.74 (95% CI: 0.59–0.88), 0.73 (95% CI: 0.61–0.86), 0.64 (95% CI: 0.52–0.77), 0.59 (95% CI: 0.45–0.72), respectively (Fig. 3A). The AUCs of the serum-based parameters, FIB-4, Fibrosis index, Lok score, King's score, APRI, AAR, and GPR were 0.77 (95% CI: 0.67–0.86), 0.73 (95% CI: 0.63–0.83), 0.73 (95% CI: 0.63–0.83), 0.70 (95% CI: 0.59–0.80), 0.67 (95% CI: 0.56–0.77), 0.63 (95% CI: 0.53–0.74), and 0.56 (95% CI: 0.44–0.67), respectively (Fig. 3B). Table 2 presented the AUCs, sensitivity, specificity, PPV and NPV of all non-invasive models for identifying HRV.

Ninety-nine participants' questionnaires were collected. We classified the participants as those undergoing EGD without sedation ( $n = 89$ , 90%) or with sedation ( $n = 10$ , 10%). Calculation suggested that DS-MCCE fared significantly better than EGD without sedation for the satisfaction of the participants (average satisfaction score: 33.99 (4.23) vs. 27.84 (5.50),  $p < 0.0001$ ,  $d = 1.15$  [95%CI: 0.88–1.42]) (Fig. 4A). The respective average scores of DS-MCCE and EGD with sedation were 33.80 (3.88) and 31.80 (4.66), which showed no significant difference ( $p = 0.42$ , Fig. 4B). All par-





**Fig. 2.** Examination procedure and representative examples of detachable string magnetically controlled capsule endoscopy and esophagogastroduodenoscopy. I. A thin and hollow string was attached on the capsule to allow the observation of esophagus by controlling the string. II. The capsule was released from the string after inspecting esophagus. III. The capsule was controlled to observe the stomach by the guidance of magnet robot. DS-MCCE, detachable string magnetically controlled capsule endoscopy; EGD, esophagogastroduodenoscopy.



**Fig. 3.** Diagnostic performance of detachable string magnetically controlled capsule endoscopy and other non-invasive tools. A, Receiver operating characteristic curves of detachable string magnetically controlled capsule endoscopy (DS-MCCE) and image-based indexes; AUC, area under receiver operating characteristic curve; LSPS, liver stiffness-spleen size-to-platelet ratio score. B, Receiver operating characteristic curves of DS-MCCE and serum-based indexes. FIB-4, fibrosis index based on four factors; APRI, aspartate aminotransferase to platelet count ratio index; AAR, aspartate aminotransferase to alanine aminotransferase ratio; GPR, gamma glutamyl trans-peptidase to platelet count ratio.

ticipants confirmed excretion of the capsule and no adverse events occurred during the two-week's follow-up.

**Discussion**

GEV comprises one of the most serious complications of portal hypertension in cACLD. Endoscopic screening of patients with cACLD to assess GEV is now recommended [1-3]. However, in view of the invasiveness and poor tolerance of EGD, non-invasive tools for

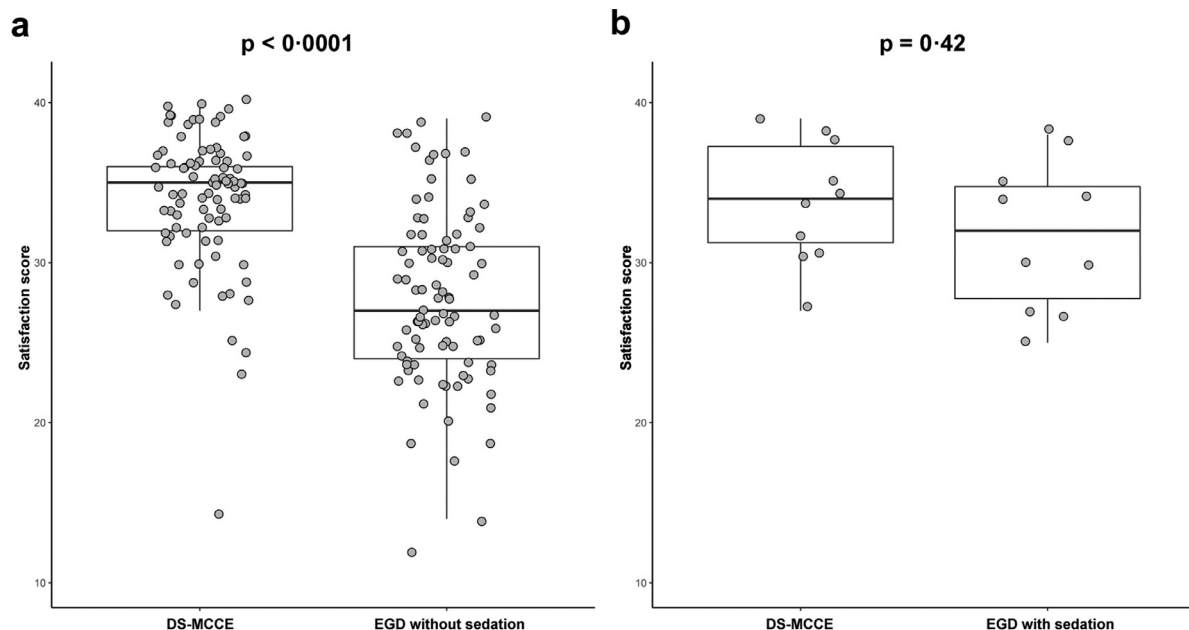
HRV detection have been highlighted in recent years. This prospective blinded study showed that DS-MCCE was an accurate, comfortable, and safe, non-invasive method for inspecting HRV. It was possible to enroll a substantial population of patients with cACLD, the characteristics of whom were representative of patients with early cirrhosis needing endoscopic screening in routine practice.

In deciding whether the DS-MCCE is a valid alternative to screening EGD for patients with cACLD, three issues should be considered: diagnostic performance, patients' satisfaction, and safety.

**Table 2**  
Diagnostic performance of DS-MCCE and other non-invasive tools for high-risk varices.

	AUC (95%CI)	Sensitivity (95%CI)	Specificity (95%CI)	PPV (95%CI)	NPV (95%CI)
DS-MCCE	0.90 (0.83–0.95)	92% (78–98%)	88% (78–95%)	80% (70–92%)	95% (90–100%)
FIB-4	0.77 (0.67–0.86)	69% (56–83%)	75% (64–85%)	60% (50–71%)	82% (75–90%)
Portal vein velocity, cm/s	0.74 (0.59–0.88)	81% (62–95%)	64% (45–79%)	59% (48–72%)	84% (72–96%)
LSPS	0.73 (0.61–0.86)	77% (59–91%)	66% (50–82%)	57% (45–71%)	83% (72–94%)
Fibrosis index	0.73 (0.63–0.83)	83% (69–94%)	61% (49–73%)	54% (46–62%)	87% (79–95%)
Lok score	0.73 (0.63–0.83)	92% (81–100%)	53% (40–67%)	54% (46–62%)	91% (82–100%)
King's score	0.70 (0.59–0.80)	92% (81–100%)	48% (35–62%)	52% (45–59%)	91% (80–100%)
APRI	0.67 (0.56–0.77)	56% (39–72%)	73% (63–84%)	53% (41–67%)	75% (69–83%)
Portal diameter, mm	0.64 (0.52–0.77)	79% (66–93%)	49% (34–64%)	49% (41–58%)	79% (67–92%)
AAR	0.63 (0.53–0.74)	86% (75–97%)	48% (36–60%)	47% (41–54%)	86% (76–97%)
LS, kpa	0.59 (0.45–0.72)	68% (50–86%)	57% (45–72%)	49% (38–60%)	75% (64–86%)
GPR	0.56 (0.44–0.67)	83% (72–94%)	31% (20–42%)	40% (35–46%)	77% (62–92%)

CI, confidence interval; AUC, the area under the receiver operating characteristic curve; PPV, positive predictive value; NPV, negative predictive value; DS-MCCE, detachable string magnetically controlled capsule endoscopy; FIB-4, fibrosis index based on 4 factors; LSPS, liver stiffness-spleen size-to-platelet ratio score; APRI, aspartate aminotransferase to platelet count ratio index; AAR, aspartate aminotransferase to alanine aminotransferase ratio; LS, liver stiffness; GPR, gamma-glutamyl transpeptidase to platelet count ratio.



**Fig. 4.** Comparison of patients' satisfaction score of detachable string magnetically controlled capsule endoscopy and esophagogastroduodenoscopy. A, Boxplot of patients' satisfaction score of DS-MCCE and EGD without sedation ( $n = 89$ ). B, Boxplot of patients' satisfaction score of DS-MCCE and EGD with sedation ( $n = 10$ ). DS-MCCE, detachable string magnetically controlled capsule endoscopy; EGD, esophagogastroduodenoscopy. Satisfaction score was tested using a student's *t*-test on paired data.

As expected, the DS-MCCE showed a good performance for HRV detection with a C-index of 0.90, and a substantial overall agreement with EGD with a kappa score of 0.78. With EGD as the reference standard, the results showed eleven (10%) patients were misclassified, of whom only three (3%) had a missed diagnosis of HRV. A low false negative value means that suitable patients were rarely denied the opportunity of being offered primary prevention therapy for variceal hemorrhage. During EGD, air insufflation will increase the volume of the oesophageal lumen relative to the varices and perhaps make them appear smaller than is evident during DS-MCCE.

The present study evaluated several non-invasive modalities for identifying HRV in cACLD. Among them, the LSPS algorithm was the most validated non-invasive surrogate measurement of EGD to identify HRV in cirrhosis with an AUC of 0.95 (95% CI: 0.93–0.97) in hepatitis B cirrhosis [13]. However, the diagnostic accuracy of LSPS for HRV was moderate in our study with an AUC of 0.73 (95% CI: 0.61–0.86). The wider range of etiology of cACLD might explain this discrepancy. With evolved higher number of centers, we again

validated that the performance of FIB-4, Fibrosis index, Lok score, King's score were just fair and performance of AAR, APRI for assessing GEV were insufficient, as previous researches demonstrated [27]. In addition, GPR, which was originally proposed as a predictor for fibrosis stage in patients with chronic hepatitis B virus infection in west Africa, [10] did not perform well in diagnosing HRV with an AUC of 0.56 (95% CI: 0.44–0.67). This still requires further studies to confirm. Overall, direct, real-time visualization and assessment of varices by DS-MCCE outperformed reported image-based parameters and serum-based scores in terms of accuracy.

Compared with previous research grading GEV by capsule endoscopy, in the largest study to date, de Franchis et al. reported a sensitivity of 78% and specificity of 96% for detecting HRV [15]. Other studies have reported a wide range of sensitivity (63–92%) and specificity (82–96%) for the detection of HRV [16–19]. However, no previous study demonstrated the diagnostic performance of capsule endoscopy for HRV in well-characterized patients with cACLD. The high sensitivity (92%) and specificity (88%) of our study for HRV suggested that DS-MCCE, in its current form, performed

well in this purpose. In addition, the patients' satisfaction for DS-MCCE was significantly better than that for EGD without sedation. DS-MCCE appeared to be a safe procedure since no adverse events occurred during follow-up. Moreover, DS-MCCE was safe for patients with dysphagia, as our previous study demonstrated the feasibility of pulling the capsule out if necessary [24]. Taken together, our results suggest that DS-MCCE used to detect varices was safe and associated with high patient satisfaction.

To the best of our knowledge, this is the first study to evaluate the DS-MCCE in assessing GEV in cACLD. The string allowed controllable movement of the capsule to observe regions of interest carefully and thoroughly. The examination scope of this technique matched that of EGD, making DS-MCCE a potential alternative to EGD especially for patients with contraindications to EGD or for those who refuse to undergo the procedure. More importantly, DS-MCCE could be performed under the direct supervision of the endoscopist from a computer workstation in an adjacent but separate room via real-time voice communication. As the COVID-19 continues to spread throughout the world, non-contact DS-MCCE can minimize risk of cross-infection and protect health-care providers better [28].

There are still some limitations. Firstly, DS-MCCE is not appropriate for patients with any contradictions to magnetic resonance imaging [22]. Secondly, the current cost of DS-MCCE is slightly higher than EGD but the cost will be decreased when it is widely used in the near future. Meanwhile, DS-MCCE takes longer than standard EGD. The median times of DS-MCCE for esophagus and stomach examinations were 6.2 and 14.3 min, respectively [29]. It should be noted that poor patient tolerance of EGD is likely to contribute to more rapid examinations, yet we know that procedures of less than seven minutes duration have half the diagnostic yield of high-risk lesions than longer procedures [30]. Therefore, a longer mean DS-MCCE examination time compared to EGD might be advantageous. Furthermore, the patient satisfaction questionnaire has not been validated. However, the questionnaire was based on one previously developed for use in assessing experience of esophageal capsule endoscopy and evaluated following the input of a panel of professionals from relevant disciplines. In addition, as DS-MCCE is a non-invasive procedure, biopsy or treatment of HRV is not possible such that a subsequent EGD is necessary for patients who need endoscopic intervention. A larger multicenter cohort (e.g. NCT03748563) is needed to further validate the accuracy of the DS-MCCE for HRV as well as portal hypertensive gastropathy.

In conclusion, DS-MCCE was an accurate, safe alternative to EGD for detecting HRV in patients with cACLD. In addition, DS-MCCE was better tolerated and thus may be indicated for those unwilling or unable to undergo EGD screening for HRV.

#### Declaration of Interests

The authors have declared no conflict of interests related to the study.

#### Author contributions

Concept and design: Xiaolong Qi; Acquisition of data and technical support: Shuai Wang, Weiling Hu, Hua Mao, Mark Edward McAlindon, Li Yang, Chunqing Zhang, Ming Xu, Chaohui He, Tong Dang, Bin Wu, Dong Ji, Liting Zhang, Xiaorong Mao, Lei Zhang, Yasong Li, Guoan Li, Juqiang Han, Fangfang Lv, Xiao Liang, Shaoqin Jin, Shaoheng Zhang, Foong Wai David Tai, Qing Xu, Changqing Yang, Guangchuan Wang, Lifeng Wang, Bo Li, Haiyun Yang, Ping Xie, Lulin Deng, Limei Ren, Zhiheng Chang, Xing Wang, Shan Wang, Xiaoqin Gao, Junfeng Li, Longdong Zhu, Fangzhao Wang, Lingling Zhang, Guo Zhang, Xi Jiang, Jun Pan, Wenbo Meng, Xun Li; Analysis and interpretation of data: Yifei Huang, Yanna Liu, Chuan Liu, Dan

Xu; Drafting of the manuscript: Yifei Huang, Yanna Liu, Xiaolong Qi. Critical revision of the manuscript: Xavier Dray, Mark Edward McAlindon, Jinlin Hou, Zhuan Liao. Final approval: All authors.

#### Financial support

Beijing Municipal Science and Technology Project (Z151100003915090); Shanghai Municipal Hospital Emerging Frontier Technology Joint Project (SHDC12019105); Medical and Health Science & Technology Development Plan in Shandong province, China (2017WS199); Key Research and Development Plans in Shandong province, China (2018GSF118100); Clinical Medicine Science & Technology Innovation Plan in Jinan City, Shandong province, China (201805069); Southern Medical University Focused Clinical Project (LC2016ZD030); National Natural Science Foundation of China (81820108006); National Natural Science Foundation of China (81670571); Shanghai Clinical Key Specialty Project (shslczdzk06801); Lanzhou Talent Innovation and Entrepreneurship Project (2019-RC-34); Guangzhou Industry-Academia-Research Collaborative Innovation Major Project (201704020015); President Foundation of Nanfang Hospital, Southern Medical University (2017Z012).

#### Data sharing

The authors declare that all data supporting the findings of this study are available within the article and its supplementary. Researchers can apply for data by submitting a proposal to the corresponding author.

#### Supplementary materials

Supplementary material associated with this article can be found, in the online version, at doi:10.1016/j.lanwpc.2020.100072.

#### References

- [1] Qi X, Berzigotti A, Cardenas A, Sarin S. Emerging non-invasive approaches for diagnosis and monitoring of portal hypertension. *Lancet Gastroenterol Hepatol* 2018;3:708–19.
- [2] European Association for the Study of the Liver/EASL Clinical Practice Guidelines for the management of patients with decompensated cirrhosis. *J Hepatol* 2018;69:406–60.
- [3] Garcia-Tsao G, Abraldes J, Berzigotti A, Bosch J. Portal hypertensive bleeding in cirrhosis: risk stratification, diagnosis, and management: 2016 practice guidance by the American Association for the study of liver diseases. *Hepatology* 2017;65:310–35.
- [4] Edelson J, Suarez A, Zhang J, et al. Sedation during endoscopy in patients with cirrhosis: safety and predictors of adverse events. *Dig Dis Sci* 2020;65:1258–65.
- [5] Berzigotti A, Gilibert R, Abraldes J, et al. Noninvasive prediction of clinically significant portal hypertension and esophageal varices in patients with compensated liver cirrhosis. *Am J Gastroenterol* 2008;103:1159–67.
- [6] Bonacini M, Hadi G, Govindarajan S, Lindsay K. Utility of a discriminant score for diagnosing advanced fibrosis or cirrhosis in patients with chronic hepatitis C virus infection. *Am J Gastroenterol* 1997;92:1302–4.
- [7] Wai C, Greenon J, Fontana R, et al. A simple noninvasive index can predict both significant fibrosis and cirrhosis in patients with chronic hepatitis C. *Hepatology* 2003;38:518–26.
- [8] Vallet-Pichard A, Mallet V, Nalpas B, et al. FIB-4: an inexpensive and accurate marker of fibrosis in HCV infection comparison with liver biopsy and fibrotest. *Hepatology* 2007;46:32–6.
- [9] Ohta T, Sakaguchi K, Fujiwara A, et al. Simple surrogate index of the fibrosis stage in chronic hepatitis C patients using platelet count and serum albumin level. *Acta Med Okayama* 2006;60:77–84.
- [10] Lemoine M, Shimakawa Y, Nayagam S, et al. The gamma-glutamyl transpeptidase to platelet ratio (GPR) predicts significant liver fibrosis and cirrhosis in patients with chronic HBV infection in West Africa. *Gut* 2016;65:1369–76.
- [11] Cross T, Rizzi P, Berry P, Bruce M, Portmann B, Harrison P. King's Score: an accurate marker of cirrhosis in chronic hepatitis C. *Eur J Gastroenterol Hepatol* 2009;21:730–8.
- [12] Lok A, Ghany M, Goodman Z, et al. Predicting cirrhosis in patients with hepatitis C based on standard laboratory tests: results of the HALT-C cohort. *Hepatology* 2005;42:282–92.

- [13] Kim B, Han K, Park J, et al. A liver stiffness measurement-based, noninvasive prediction model for high-risk esophageal varices in B-viral liver cirrhosis. *Am J Gastroenterol* 2010;105:1382–90.
- [14] Colli A, Gana J, Turner D, et al. Capsule endoscopy for the diagnosis of esophageal varices in people with chronic liver disease or portal vein thrombosis. *Cochrane Database Syst Rev* 2014;10:CD008760.
- [15] de Franchis R, Eisen G, Laine L, et al. Esophageal capsule endoscopy for screening and surveillance of esophageal varices in patients with portal hypertension. *Hepatology* 2008;47:1595–603.
- [16] Frenette C, Kuldau J, Hillebrand D, et al. Comparison of esophageal capsule endoscopy and esophagogastroduodenoscopy for diagnosis of esophageal varices. *World J Gastroenterol* 2008;14:4480–5.
- [17] Lapalus M, Ben Soussan E, Gaudric M, et al. Esophageal capsule endoscopy vs. EGD for the evaluation of portal hypertension: a French prospective multicentre comparative study. *Am J Gastroenterol* 2009;104:1112–18.
- [18] Ishiguro H, Saito S, Imazu H, Aihara H, Kato T, Tajiri H. Esophageal capsule endoscopy for screening esophageal varices among Japanese patients with liver cirrhosis. *Gastroenterol Res Pract* 2012;2012:946169.
- [19] Sacher-Huvelin S, Calès P, Bureau C, et al. Screening of esophageal varices by esophageal capsule endoscopy: results of a French multicentre prospective study. *Endoscopy* 2015;47:486–92.
- [20] Hosoe N, Naganuma M, Ogata H. Current status of capsule endoscopy through a whole digestive tract. *Dig Endosc* 2015;27:205–15.
- [21] Ramirez F, Shaikat M, Young M, et al. Feasibility and safety of string, wireless capsule endoscopy in the diagnosis of Barrett's esophagus. *Gastrointest Endosc* 2005;61:741–6.
- [22] Liao Z, Hou X, Lin-Hu E, et al. Accuracy of magnetically controlled capsule endoscopy, compared with conventional gastroscopy, in detection of gastric diseases. *Clin Gastroenterol Hepatol* 2016;14:1266–73.
- [23] Zhao A, Qian Y, Sun H, et al. Screening for gastric cancer with magnetically controlled capsule gastroscopy in asymptomatic individuals. *Gastrointest Endosc* 2018;88:466–74.
- [24] Chen Y, Pan J, Luo Y, et al. Detachable string magnetically controlled capsule endoscopy for complete viewing of the esophagus and stomach. *Endoscopy* 2019;51:360–4.
- [25] de Franchis R, Faculty Baveno VI. Expanding consensus in portal hypertension: report of the Baveno VI consensus workshop: stratifying risk and individualizing care for portal hypertension. *J Hepatol* 2015;63:743–52.
- [26] Anthony J, Joanne M. Understanding interobserver agreement: the kappa statistic. *Fam Med* 2005;37:360–3.
- [27] Deng H, Qi X, Guo X. Diagnostic accuracy of APRI, AAR, FIB-4, FI, King, Lok, Forns, and FibroIndex scores in predicting the presence of esophageal varices in liver cirrhosis: a systematic review and meta-analysis. *Medicine* 2015;94:e1795.
- [28] Pan J, Li Z, Liao Z. Noncontact endoscopy for infection-free gastric examination during the COVID-19 pandemic. *VideoGIE* 2020;5:402–3.
- [29] Jiang X, Qian Y, Liu X, et al. Impact of magnetic steering on gastric transit time of a capsule endoscopy (with video). *Gastrointest Endosc* 2018;88:746–54.
- [30] Teh J, Tan J, Lau L, et al. Longer examination time improves detection of gastric cancer during diagnostic upper gastrointestinal endoscopy. *Clin Gastroenterol Hepatol* 2015;13:480–7.