



## Case Report

# Transcatheter Aortic Valve Implantation in a Failed Perceval Sutureless Valve, Complicated by Aortic Annular Rupture

Robert T. Kay, MB, BCh, BAO,<sup>a,b,†</sup> Hatem Linjawi, MBBS,<sup>a,b,‡</sup> Craig Butler, MD, MSc,<sup>a,b</sup>  
Anoop Mathew, MBBS,<sup>a,b</sup> Isabelle Vonder Muhll, MD,<sup>a,b</sup> Sayra Khandekar, MD,<sup>a,b</sup>  
Benjamin D. Tyrrell, MD,<sup>a,c</sup> Jeevan Nagendran, MD, PhD,<sup>b,d</sup> Dylan Taylor, MD,<sup>a,b</sup> and  
Robert C. Welsh, MD<sup>a,b</sup>

<sup>a</sup>Division of Cardiology, Department of Medicine, University of Alberta, Edmonton, Alberta, Canada

<sup>b</sup>Mazankowski Alberta Heart Institute, Edmonton, Alberta, Canada

<sup>c</sup>Cardiology, CK Hui Heart Centre, Edmonton, Alberta, Canada

<sup>d</sup>Division of Cardiac Surgery, Department of Surgery, University of Alberta, Edmonton, Alberta, Canada

### ABSTRACT

As the use of surgically implanted sutureless aortic valves has increased over the past decade, we expect to encounter their failure increasingly in coming years. We describe a case of Perceval aortic valve failure with stent infolding and severe stenosis. This condition was treated with valve-in-valve transcatheter aortic valve implantation and complicated by aortic annular rupture at the site of infolding. This case is important because it outlines the limited experience with valve-in-valve transcatheter aortic valve implantation to treat failed sutureless valves and identifies sutureless valve infolding as a potential risk for annular rupture.

### RÉSUMÉ

Puisque l'implantation valvulaire aortique sans suture s'est accrue au cours de la dernière décennie, nous nous attendons à rencontrer de plus en plus de défaillances de valves dans les années à venir. Nous décrivons un cas de défaillance de la valve aortique Perceval avec pliage de l'endoprothèse et sténose grave. Le traitement qui consistait en l'implantation valvulaire aortique de type valve-in-valve par cathéter a été compliqué par la rupture de l'anneau aortique au site du pliage. Il s'agit d'un cas important puisqu'il décrit le peu d'expérience en matière d'implantation valvulaire aortique de type valve-in-valve par cathéter dans le traitement des valves sans suture défectueuses et établit que le pliage d'une valve sans suture expose à un risque de rupture de l'anneau.

### Case

A 75-year-old woman presented with 3 months of progressive exertional dyspnea culminating in New York Heart Association (NYHA) class IV symptoms. She had a surgical aortic valve replacement using a medium-size Perceval S sutureless valve (LivaNova, London, UK) 36 months prior. Initial exam and investigations were consistent with congestive heart failure, including interstitial pulmonary edema on chest

X-ray, and an elevated brain natriuretic peptide level at 697 pg/mL. She was hospitalized and started on intravenous diuretic therapy. Inpatient transthoracic echocardiogram (TTE) revealed elevated pressure gradients across the aortic bioprosthesis, compared to previous measurements, with peak and mean gradients of 63 mm Hg and 31 mm Hg, respectively, mild aortic regurgitation, and normal left ventricular systolic function. Transesophageal echocardiography was carried out and confirmed severe bioprosthetic valve stenosis, with peak and mean gradients of 79 mm Hg and 49 mm Hg, respectively, and an aortic valve area of 0.6 cm<sup>2</sup> by continuity equation and 0.5 cm<sup>2</sup> by planimetry (Supplemental Fig. S1). Her case was discussed at multidisciplinary heart team rounds. Given her overall frailty, the heart team recommended valve-in-valve (ViV) transcatheter aortic valve implantation (TAVI).

A TAVI-planning computed tomography (CT) scan was carried out per protocol and revealed that the Perceval valve frame was distorted and appeared to be infolded below the left coronary cusp (Fig. 1, A and B). The minimum and maximum

Received for publication December 7, 2021. Accepted February 8, 2022.

**Ethics Statement:** The research reported in this article has adhered to the relevant institutional ethical guidelines.

<sup>†</sup>These authors are co-first authors.

Corresponding author: Robert Kay, Division of Cardiology, University of Alberta Hospital, 2C2, Walter Mackenzie Health Sciences Centre, 8440-112 St., Edmonton, Alberta T6G 2B7, Canada. Tel.: +780-407-6507; fax: +1-780-407-6452.





E-mail: [rtkay@ualberta.ca](mailto:rtkay@ualberta.ca)

See page 580 for disclosure information.

### Novel Teaching Points

- Experience with TAVI in treating failed surgically implanted sutureless aortic valves is limited.
- Perceval valve infolding is a potential risk factor for annular rupture during ViV TAVI.

internal valve diameters were 17 mm and 19 mm, respectively (mean diameter 18 mm), and the valve area was 2.5 mm<sup>2</sup>. No thrombus, vegetations, or pannus were seen on the valve.

She then underwent TAVI via a transfemoral approach with fluoroscopic guidance. The Perceval valve was pre-dilated with an Atlas (22 × 20 mm × 80 cm) balloon (Becton Dickinson, Franklin Lakes, NJ; [Video 1](#) , view video online). A size 23 mm, SAPIEN 3 valve (Edwards Lifesciences, Irvine, CA) was then implanted to nominal pressure ([Video 2](#) , view video online). The procedure was complicated by a brief episode of complete heart block post-valve deployment, which spontaneously resolved intraoperatively. The patient was transferred to the cardiac intensive care unit in stable condition. Post-TAVI electrocardiogram revealed baseline atrial fibrillation and a new left bundle branch block. TTE on the same day showed a well-seated SAPIEN valve, with normal gradients and no regurgitation. However, a significant compression of the right ventricular outflow tract from an extrinsic source was seen, which was not evident on previous imaging ([Fig. 2](#)) ([Videos 3](#)  and [4](#) , view videos online). An emergent gated CT angiogram of the chest revealed an aortic annular rupture inferior to the origin of the left coronary artery with extravasation of contrast and a large hematoma compressing the right ventricular outflow tract ([Fig. 1, C and D](#)). Upon review of previous imaging, the rupture site appeared to correspond to the location of the previous infolded portion of the Perceval valve. The cardiovascular surgery team was consulted, and given the extent of the operation, along with the patient's baseline frailty, the risks of operation were felt to be prohibitive. The patient was stable through the day, with sudden deterioration in the early morning, when she passed away.

### Discussion

Management of native valve aortic stenosis with TAVI has produced excellent outcomes; however, expanding the use of TAVI for failed prosthetic aortic valves brings unique considerations. The past decade has seen the rise of use of surgically implanted sutureless aortic bioprostheses, of which the Perceval valve is one of the most common.

Bioprosthetic valve dysfunction has been traditionally managed via reoperation. Recently, TAVI proved to be a safe and effective treatment option for bioprosthetic aortic valve dysfunction.<sup>1</sup> Current society guidelines consider ViV TAVI a reasonable treatment option for patients with bioprosthetic aortic valve stenosis and high or prohibitive surgical risk.<sup>2</sup> However, due to the relatively recent approval and adaptation of these Perceval valves, the volume of experience in the treatment of valve dysfunction is not large. The greatest amount of data on TAVI with Perceval valves has come from Landes et al.<sup>3</sup> The procedure was successful in all 24 of their

patients, and compared with TAVI in a conventional aortic bioprostheses, this approach provided equally favourable hemodynamic outcomes and a similar, low rate of complications. In light of these data, ViV TAVI for Perceval valve degeneration appears to be both safe and effective.

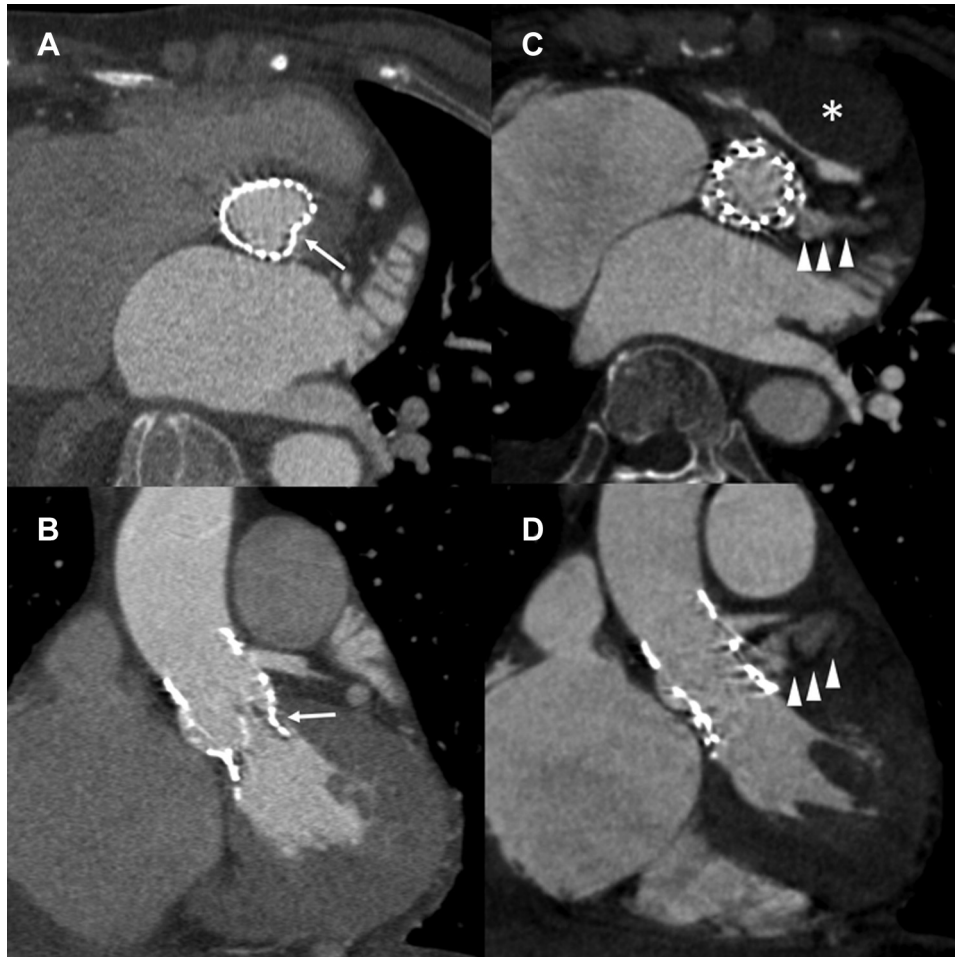
In this report, we describe a case of sutureless aortic valve degeneration in association with valve infolding that was treated with ViV TAVI and complicated by aortic annulus rupture at the site of infolding. Infolding, or distortion, of the Perceval valve has been described in case reports as a rare complication. At least 4 cases have been reported of “early” (ie, within days to a few weeks from implantation) Perceval valve infolding resulting in significant paravalvular leakage and, in most cases, clinical heart failure.<sup>4-6</sup> In 2 of the 4 cases, the decision was made to treat the Perceval valve dysfunction with ViV TAVI, which was performed successfully.<sup>5,6</sup>

We would like to highlight a case report from Patterson et al. that describes a patient with symptomatic Perceval valve dysfunction secondary to valve stent infolding, 2 years after implantation.<sup>7</sup> The patient underwent a ViV TAVI that was complicated by a contained aortic annular rupture, creating a fistula between the left ventricular outflow tract and the right ventricle. Similar to our case, this patient presented “late” (ie, more than 1 year) after their Perceval valve implantation, with valve distortion and dysfunction, and suffered a similar complication of aortic annular rupture at the site of Perceval valve infolding.

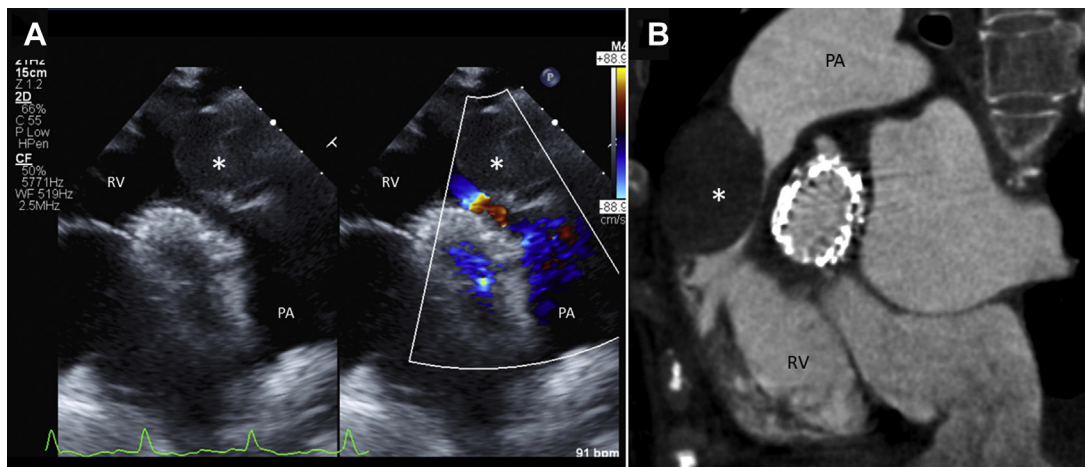
A key difference between the 2 successful ViV TAVIs for Perceval valve dysfunction with valve infolding<sup>5,6</sup> and the 2 complicated cases, including ours, was the time of presentation and intervention. In early Perceval infolding, a constant feature is the development of significant paravalvular leakage within a few weeks of surgery that was not present on initial postoperative images. This leakage suggests that the valve infolded after initially having good opposition against the aortic annulus. Authors have speculated that this early infolding may be caused by the force of the beating heart applying stress on an oversized valve. In our case, we suspect that an underlying aortic root pathology prevented initial full expansion of the Perceval valve; this possibility is supported by higher-than-expected postoperative peak and mean gradients of 43 mm Hg and 22 mm Hg, respectively, as well as apparent Perceval infolding, noted retrospectively, on intraoperative transesophageal echocardiography ([Supplemental Fig. S2](#)). We also speculate that the region of the annulus that resisted expansion with Perceval deployment again resisted expansion with TAVI, resulting in rupture.

Also important to consider is the role of SAPIEN 3 valve selection. We opted for a 23-mm SAPIEN valve that is appropriate for the native annular sizing of 21–23 mm performed intraoperatively with Perceval valve deployment. The 23-mm SAPIEN valve would have been relatively oversized based on the annular size measured from the pre-TAVI CT, which was found to have a mean diameter of 18 mm (2.5 cm<sup>2</sup>) of the in-folded Perceval annulus. We have found examples in the literature of successful implantation of 23-mm SAPIEN valves into size M and size S Perceval valves.<sup>5,8</sup>

These important similarities between the 2 cases are worthy of note and consideration when contemplating ViV TAVI. As we expect to encounter more cases of Perceval valve degeneration over the next 5–10 years, we feel that this case



**Figure 1.** Pre and post–transcatheter aortic valve implantation (TAVI) computed tomography scan. **(A)** A cross-sectional image demonstrating a kidney-shaped Perceval valve due to stent infolding (infolding indicated by **arrow**). **(B)** Stent infolding as seen from a coronal view. **(C)** Post TAVI computed tomography image revealing aortic annular rupture at the site of previous Perceval infolding with extravasation of contrast (contrast flowing from ruptured aortic annulus indicated by **arrowheads**) and a large anterior mediastinal hematoma (**asterisk**) compressing the right ventricular outflow tract. **(D)** A coronal view demonstrating the site of annular rupture below the level of the left main coronary artery.



**Figure 2.** Hematoma (**asterisks**) compressing on the slit-like right ventricular outflow tract **(A)** first identified on post–transcatheter aortic valve implantation transthoracic echocardiography and **(B)** confirmed on a computed tomography scan. PA, pulmonary artery; RV, right ventricle.

can inform future efforts involving ViV-TAVI in this patient population.

In conclusion, although ViV TAVI is a relatively common and safe procedure in treating conventional bioprosthetic valve dysfunction, the global experience of using ViV TAVI in treating sutureless valve dysfunction is still in an early stage. Although the available literature suggests that this approach is safe, the presence of structural deformations or infoldings of the frame of these sutureless valves, outside the early postoperative period, requires careful evaluation and consideration of an alternative approach. Although the mechanism of aortic root rupture is not well understood, and causation cannot be confirmed, we think that highlighting these 2 complicated cases is important, and we encourage others to publish any similar experiences. This case also highlights the utility of same-day TTE in early diagnosis of acute complications of valve implantation.

### Funding Sources

The authors have no funding sources to declare.

### Disclosures

Astra Zeneca, Bayer, and Pfizer provided research grants to R.W. The other authors have no conflicts of interest to disclose.

### References

1. Simonato M, Dvir D. Transcatheter aortic valve replacement in failed surgical valves. *Heart* 2019;105:s38-43.
2. Otto CM, Nishimura RA, Bonow RO, et al. 2020 ACC/AHA guideline for the management of patients with valvular heart disease: a report of the American College of Cardiology/American Heart Association Joint Committee on Clinical Practice Guidelines. *Circulation* 2021;143:e72-227.
3. Landes U, Dvir D, Schoels W, et al. Transcatheter aortic valve-in-valve implantation in degenerative rapid deployment bioprostheses. *Euro-Intervention* 2019;15:37-43.
4. Fleissner F, Molitoris U, Shrestha M, Martens A. Stent distortion after sutureless aortic valve implantation: a new complication seen with a novel surgical technique. *Interact Cardiovasc Thorac Surg* 2015;20:436-8.
5. Di Eusanio M, Saia F, Pellicciari G, et al. In the era of the valve-in-valve: Is transcatheter aortic valve implantation (TAVI) in sutureless valves feasible? *Ann Cardiothorac Surg* 2015;4:214-7.
6. Kalra A, Reyes M, Yang EY, et al. Transcatheter aortic valve replacement for Perceval sutureless aortic valve failure. *J Invasive Cardiol* 2017;29:E65-6.
7. Patterson T, Rajani R, Esposito G, et al. Transcatheter aortic valve-in-valve implantation complicated by aorto-right ventricular fistula. *JACC Case Rep* 2020;2:309-11.
8. Misfeld M, Abdel-Wahab M, Thiele H, Borger MA, Holzhey D. A series of four transcatheter aortic valve replacement in failed Perceval valves. *Ann Cardiothorac Surg* 2020;9:280-8.

### Supplementary Material

To access the supplementary material accompanying this article, visit *CJC Open* at <https://www.cjopen.ca/> and at <https://doi.org/10.1016/j.cjco.2022.02.003>.