



Original Article

Arthroscopic treatment for chronic lateral epicondylitis[☆]



Bernardo Barcellos Terra*, Leandro Marano Rodrigues, Anis Nahssen Filho, Gustavo Dalla Bernardina de Almeida, José Maria Cavatte, Anderson De Nadai

Santa Casa de Misericórdia de Vitória, Vitória, ES, Brazil

ARTICLE INFO

Article history:

Received 28 June 2014

Accepted 15 September 2014

Available online 9 July 2015

Keywords:

Tennis elbow/complications

Tennis elbow/surgery

Tennis elbow/therapy

Arthroscopy

ABSTRACT

Objective: To report the clinical and functional results from arthroscopic release of the short radial extensor of the carpus (SREC) in patients with chronic lateral epicondylitis that was refractory to conservative treatment.

Methods: Over the period from January 2012 to November 2013, 15 patients underwent arthroscopic treatment. The surgical technique used was the one described by Romeo and Cohen, based on anatomical studies on cadavers. The inclusion criteria were that the patients needed to present lateral epicondylitis and that conservative treatment (analgesics, anti-inflammatory agents, corticoid infiltration or physiotherapy) had failed over a period of more than six months. The patients were evaluated based on the elbow functional score of the Mayo Clinic, Nirschl's staging system and a visual analog scale (VAS) for pain.

Results: A total of 15 patients (9 men and 6 women) were included. The mean Mayo elbow functional score after the operation was 95 (ranging from 90 to 100). The pain VAS improved from a mean of 9.2 before the operation to 0.64 after the operation. On Nirschl's scale, the patients presented an improvement from a mean of 6.5 before the operation to approximately one. There were significant differences from before to after the surgery for the three functional scores used ($p < 0.01$). No correlations were observed using the Spearman test between the results and age, gender, length of time with symptoms before the operation or injury mechanism ($p > 0.05$).

Conclusion: Arthroscopic treatment for lateral epicondylitis was shown to be a safe and effective therapeutic option when appropriately indicated and performed, in refractory cases of chronic lateral epicondylitis. It also allowed excellent viewing of the joint space for diagnosing and treating associated pathological conditions, with a minimally invasive procedure.

© 2014 Sociedade Brasileira de Ortopedia e Traumatologia. Published by Elsevier Editora Ltda. All rights reserved.

[☆] Work performed within the Shoulder and Elbow Group, Department of Orthopedics and Traumatology, Santa Casa de Misericórdia de Vitória, Vitória, ES, Brazil.

* Corresponding author.

E-mail: bernardomed@hotmail.com (B.B. Terra).

<http://dx.doi.org/10.1016/j.rboe.2015.06.015>

2255-4971/© 2014 Sociedade Brasileira de Ortopedia e Traumatologia. Published by Elsevier Editora Ltda. All rights reserved.

Tratamento artroscópico da epicondilite lateral crônica

R E S U M O

Palavras-chave:

Cotovelo de tenista/complicações
Cotovelo de tenista/cirurgia
Cotovelo de tenista/terapia
Artroscopia

Objetivo: Relatar os resultados clínicos e funcionais da liberação artroscópica do extensor radial curto do carpo (ECRB) nos pacientes com epicondilite lateral crônica refratária ao tratamento conservador.

Métodos: No período compreendido entre janeiro de 2012 e novembro de 2013, 15 pacientes foram submetidos ao tratamento artroscópico. A técnica cirúrgica usada é a descrita por Romeo e Cohen, baseada em estudos anatômicos em cadáver. Os critérios de inclusão foram pacientes com epicondilite lateral nos quais o tratamento conservador (analgésicos, anti-inflamatórios, infiltração de corticoides, fisioterapia) falhou por mais de seis meses. Os pacientes foram avaliados com base no escore funcional de cotovelo da Clínica Mayo, Sistema de Estágio de Nirschl e escala visual analógica de dor.

Resultados: Foram incluídos 15 pacientes, nove homens e seis mulheres. A média do escore funcional de cotovelo de Mayo pós-operatório foi de 95 (de 90 a 100). A EVS da dor teve uma melhoria média de 9,2 no pré-operatório para 0,64 no pós-operatório. Pela escala de Nirschl os pacientes apresentaram uma melhoria média de 6,5 no pré-operatório para aproximadamente um. Foi observada diferença significativa entre pré e pós-cirúrgico nos três escores funcionais usados ($p < 0,01$). Não foram observadas correlações pelo teste de Spearman entre idade, gênero, tempo de sintomas pré-operatório, mecanismo de lesão com os resultados ($p > 0,05$).

Conclusão: O tratamento artroscópico da epicondilite lateral mostra-se como uma opção terapêutica segura e eficaz quando indicado e feito de forma adequada nos casos refratários de epicondilite lateral crônica e permite ainda uma excelente visualização do espaço articular para diagnóstico e tratamento de patologias associadas com um procedimento minimamente invasivo.

© 2014 Sociedade Brasileira de Ortopedia e Traumatologia. Publicado por Elsevier Editora Ltda. Todos os direitos reservados.

Introduction

Lateral epicondylitis, also known as tennis elbow, is a disorder with an estimated prevalence of 1–3%, peaking especially during the fifth decade of life, and with greater occurrence among men, with approximate proportions of 3:1. This condition is one of the main causes of pain in the elbow and is related to sports such as tennis and to manual work activities. Moreover, lateral epicondylitis often has a great financial impact on society, with regard to both work leave and treatment.

The pathology of this condition is a source of controversy, although there are descriptions in the literature that date back to the 1970s. Most cases are believed to be caused by a musculotendinous lesion at the origin of the proximal extensors of the lateral epicondyle, especially of the short radial extensor of the carpus.¹⁻³

The literature is vast regarding types of treatment, from relative rest to surgical treatment. However, controversy still exists regarding the best form of treatment. Conservative treatment presents excellent results, although surgical treatment becomes an option when it fails (approximately 12%) and in refractory chronic cases.⁴⁻⁷

Arthroscopic treatment has recently been described as having the advantages of allowing viewing of concomitant intra-articular lesions, not violating the aponeurosis of the extensors and having a shorter rehabilitation period and lower

complication rate.^{8,9} The objective of the present study was to report the clinical and functional results from arthroscopic release of the short radial extensor of the carpus (SREC) in patients with chronic lateral epicondylitis that was refractory to conservative treatment.

Methods

Between January 2012 and November 2013, 15 patients underwent arthroscopic treatment for lateral epicondylitis of the elbow at the Shoulder and Elbow Group of our Department of Orthopedics and Traumatology.

The inclusion criterion was that the patients needed to present lateral epicondylitis for which conservative treatment (analgesics, anti-inflammatory drugs, corticoid infiltration or physical therapy) had failed over a period of more than six months. The diagnosis was made based on the clinical history, physical examination and magnetic resonance examination (Figs. 1 and 2). The exclusion criteria were previous surgery or fractures on the ipsilateral elbow and presence of concomitant disorders, such as lateral compartment arthrosis, posterior interosseous syndrome, osteochondritis dissecans of the capitellum, instability and rheumatological diseases.

All the patients were examined and evaluated by two surgeons who were specialists in shoulder and elbow surgery. The patients were evaluated based on the elbow functional score

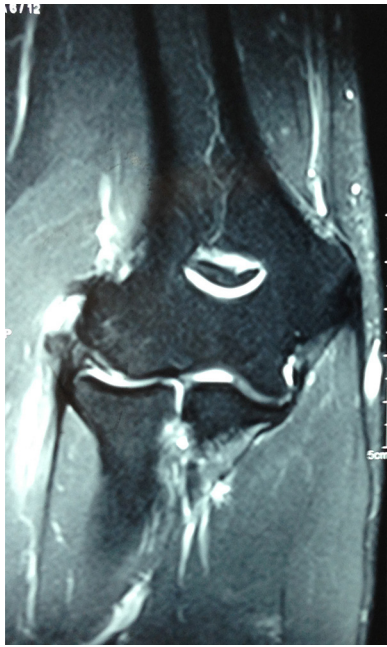

Fig. 1 – Magnetic resonance imaging of coronal section showing a lesion of the short radial extensor tendon.

of the Mayo Clinic, Nirschl staging system and a visual analog scale of pain. The visual analog scale of pain consisted of a ruler measuring 10cm in length, on which one end represented absence of pain and the other a very intense pain. The Nirschl system consisted of seven phases in increasing order of pain intensity, going from Phase 1 (slight pain with exercise that was resolved within 24 h) to Phase 7 (constant pain when resting that disrupted sleep). The scores were obtained before

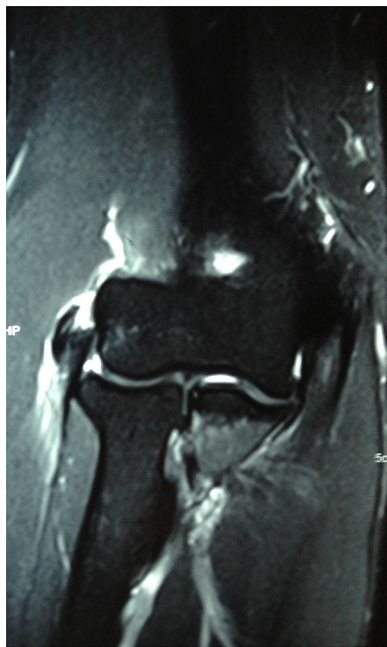


Fig. 2 – Magnetic resonance imaging of coronal section showing a lesion with tearing of the short radial extensor tendon.

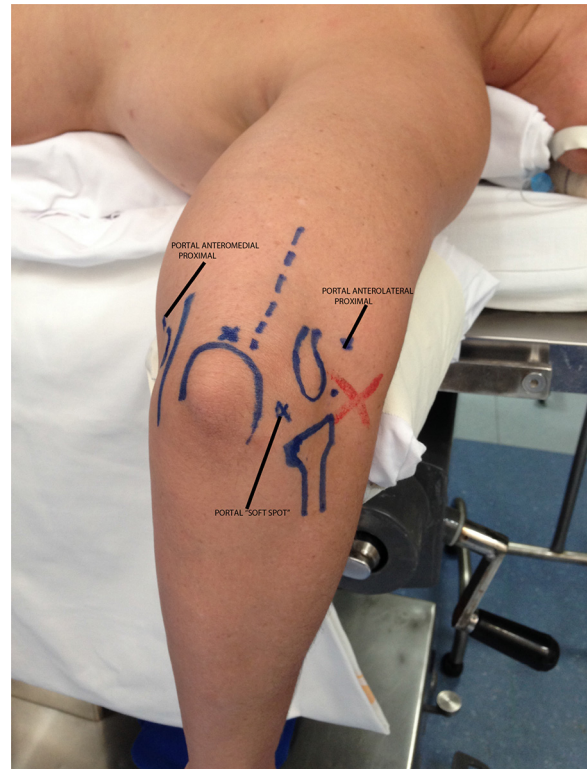


Fig. 3 – Arthroscopic portals drawn on the right elbow.

surgery and during the postoperative period after two and six weeks, and after six months.

Surgical technique

The surgical technique used was described by Cohen and Romeo,¹⁰ based on anatomical studies on cadavers.

Positioning

The patient was positioned in ventral decubitus with a support for the upper limb that allowed a range of motion of 120 degrees, from flexion to complete extension. A sterile manual tourniquet was used at the level of the middle third of the arm. The anatomical references (medial and lateral epicondyle, radial head, olecranon and ulnar nerve) and arthroscopic portals (proximal anteromedial and anterolateral and, in some cases, the standard posterior and posterolateral) were marked on the skin, as illustrated in Figs. 3 and 4.

Approximately 20 ml of sterile 0.9% saline solution was injected through the soft spot portal delineated by the radial head, olecranon and lateral epicondyle. Through this, a blunt trocar was inserted through the anteromedial portal using the cannula of the arthroscope. An optical device with a 30° angle of view was then inserted and a joint inspection was carried out in the anterior compartment of the elbow. The proximal anterolateral portal was then created 2 cm proximally and anteriorly to the lateral epicondyle using the outside-in technique with a No. 15 scalpel blade only to make an incision in the skin. A No. 18 Jelco was used to locate the correct position that would enable an adequate work portal. To do so, the

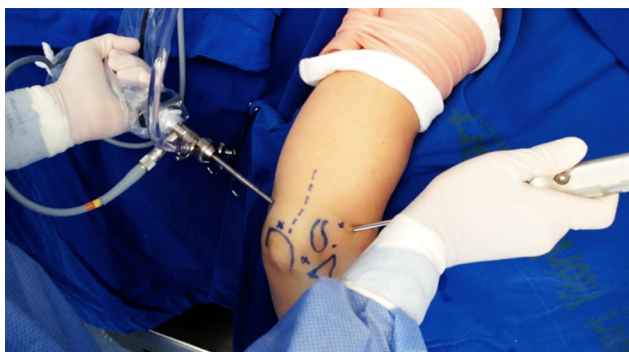

Fig. 4 – Optical device positioned in the proximal anteromedial portal and shaver positioned in the proximal anterolateral portal.

locations of the posterior interosseous nerve and short radial extensor of the carpus (which originates near to the level of the joint surface of the capitellum) are taken into account. The debrided area of the lateral condyle is trapezium-shaped with approximate dimensions of 13 mm × 7 mm, slightly more distal and anterior to the site of the apex of the lateral epicondyle. The dimensions of the tip of the shaver (4.5 mm) can help with these measurements.⁷

The capsule is partially resected and opened using a 4.5 mm soft-tissue shaver that exposes the origin of the short extensor, which is extra-articular and should be resected as far as the upper aspect of the capitellum. The muscle fibers of the long radial extensor are thus exposed (Figs. 5 and 6). Care needs to be taken regarding the fibers of the lateral collateral ligament, which mark the posterior margin of the area that should be resected, and also regarding the fibers of the common extensor of the fingers, which is superficial to the short radial extensor. After releasing the short radial extensor, microperforations were created using a Steinman wire (Fig. 7).

During the postoperative period, a brace was placed on the elbow and was maintained for five days. Passive range of motion exercises were started as soon as the patient's state of pain allowed this. Isometric stretching exercises were started as soon as a complete range of motion had been acquired and resistance exercises were started four to six weeks after

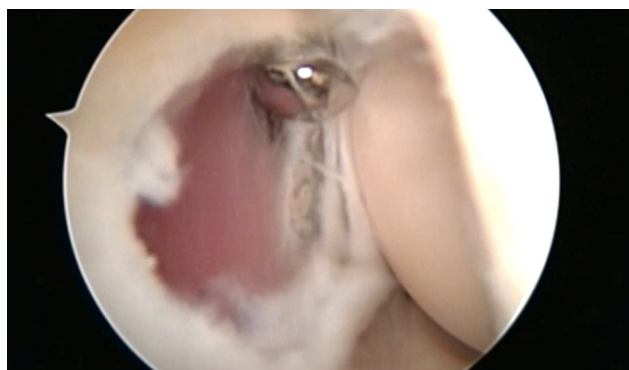

Fig. 5 – Soft-tissue shaver releasing the short radial extensor.

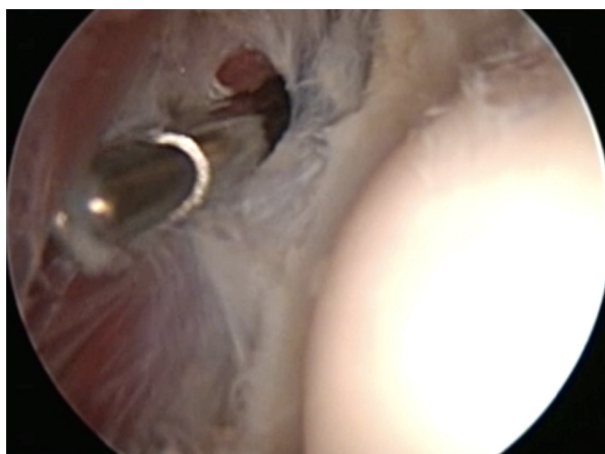


Fig. 6 – Soft-tissue shaver releasing the short radial extensor. Note the muscle fibers of the long radial extensor.

the operation. The patients return to their physical activities without restrictions 10 weeks after the operation.

Descriptive analysis was carried out on the numerical and categorical variables (Tables 1 and 2). Nonparametric tests were used in the data analysis because the data did not follow normal distribution. The pre and postoperative results from the VAS, Mayo and Nirschl scales were compared using the Mann-Whitney nonparametric test. The relationships of age and time of injury with the results (postoperative Mayo results) were assessed using Spearman's correlation test. Difference between genders and trauma mechanisms in relation to the results (postoperative Mayo score) were investigated through the Mann-Whitney test. The value of *p* was taken to be 0.05 for all statistical inferences. The software used was SPSS for Windows version 20.0.

Results

Fifteen patients (9 men and 6 women) were included in the present study. The mean age of the patients on the day of surgery was 38 ± 8.7 years. The dominant limb was involved in almost 75% of the cases.

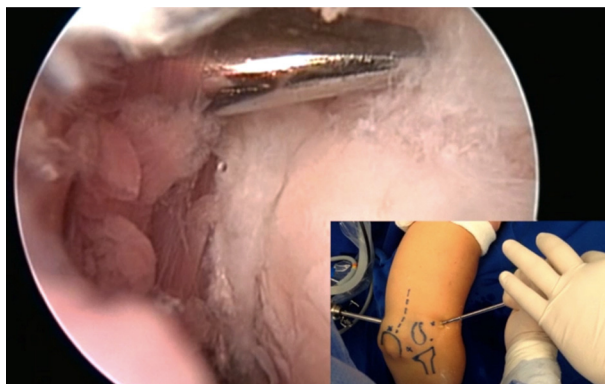


Fig. 7 – Microperforations produced in the lateral epicondyle with the aid of an ice pick.

Table 1 – Descriptive analysis.

	N	Mean	SD	Median	Min	Max
<i>Age</i>						
General	15	38.3	8.7	38.5	23	52
Male	9	38	9.8	37.5	27	52
Female	6	37.6	8.0	38.5	23	45
<i>Time of injury</i>						
General	15	6.93	0.9	7	6	9
Male	9	6.81	1.1	6.5	6	9
Female	6	7.0	0.8	7	6	8
<i>Preoperative VAS</i>						
General	15	9.21	0.6	9	8	10
Male	9	9.13	0.6	9	8	10
Female	6	8.48	0.8	9.5	8	10
<i>Postoperative VAS</i>						
General	15	0.64	0.7	0.5	0	2
Male	9	0.63	0.7	0.5	0	2
Female	6	0.67	0.8	0.5	0	2
<i>Preoperative Mayo</i>						
General	15	60.00	4.8	60	50	65
Male	9	61.25	4.4	62.5	55	65
Female	6	58.33	5.1	60	50	65
<i>Postoperative Mayo</i>						
General	15	95.71	3.8	95	90	100
Male	9	96.25	3.5	95	90	100
Female	6	95	4.4	95	90	100
<i>Preoperative Nirschl</i>						
General	15	6.5	0.5	6.5	6	7
Male	9	6.5	0.5	6.5	6	7
Female	6	6.5	0.5	6.5	6	7
<i>Postoperative Nirschl</i>						
General	15	1.07	0.2	1	1	2
Male	9	1.13	0.3	1	1	2
Female	6	1	0	1	1	1
<i>Flexion on operated side</i>						
General	15	149	11.2	152	120	160
Male	9	148	7.5	148	138	160
Female	6	151	15.5	157	120	160
<i>Flexion on non-operated side</i>						
General	15	138.9	8.2	139	130	160
Male	9	139	5.3	139	134	150
Female	6	138	11.6	135	130	160
<i>Extension on operated side</i>						
General	15	-2	1.5	-2	0	-4
Male	9	-1.75	1.2	-2	0	-4
Female	6	-2.3	1.9	-3	0	-4
<i>Extension on non-operated side</i>						
General	15	0	1.3	0	-2	2
Male	9	-0.25	1.28	0	-2	2
Female	6	0.33	1.5	0	-2	2

A total of 60% of the patients indicated that the cause of their injury was activities that were required in their professions. The other causes reported included repeated overload in 40%, tennis in 30% and a traumatic event in 30%.

The patients underwent surgery after a mean time period of seven months since the beginning of symptoms. Three patients underwent application of corticoid locally, with a maximum of two doses.

The mean time taken for the surgical procedure was 20 min.

The postoperative mean Mayo elbow functional score was 95 (range: 90–100). The VAS pain score improved from a preoperative mean of 9.2 to a postoperative mean of 0.64. On the Nirschl scale, the patients presented an improvement from a mean of 6.5 before surgery to approximately 1.0, and some patients no longer presented any pain at all. A significant

Table 2 – Descriptive analysis.

	Frequency	%
<i>Gender</i>		
Male	9	60
Female	6	40
<i>Use of corticoid</i>		
Yes	3	20
No	12	80
<i>Side of injury</i>		
Dominant	11	73.3
Non- dominant	4	26.6
<i>Trauma mechanism</i>		
Profession	9	60
Sport	6	40

Table 3 – Comparison of before and after operation, according to VAS, Mayo and Nirschl scores.

	N	Mean	SD	Median	Min	Max	p value
<i>VAS</i>							
Pre	15	9.21	0.6	9	8	10	0.000 ^a
Post	15	0.64	0.7	0.5	0	2	
<i>Mayo</i>							
Pre	15	60.00	4.8	60	50	65	0.001 ^a
Post	15	95.71	3.8	95	90	100	
<i>Nirschl</i>							
Pre	15	6.5	0.5	6.5	6	7	0.001 ^a
Post	15	1.07	0.2	1	1	2	

^a p value < 0.01.

Table 4 – Relationship between age and time of injury and the results (postoperative Mayo score).

	Correlation coefficient ^a	p value
Age	0.21	0.44
Time of injury	0.38	0.15

^a Spearman's correlation test.

difference was observed from before to after the operation for all three functional scores that were used ($p < 0.01$) (Table 3).

No correlations were observed through Spearman's test between age and the results ($p = 0.44$), or any correlation between the time of injury and the results ($p = 0.15$). The correlation coefficients were positive, which indicates that there was a proportional relationship between the two variables, e.g. the greater the age, the higher the postoperative Mayo value was; and the greater the time since the injury, the higher the postoperative Mayo value again was (Table 4). No significant difference was observed between the genders in relation to the results (postoperative Mayo score) ($p = 0.68$), or between the trauma mechanism and the results (postoperative Mayo score) ($p = 0.18$) (Table 5).

The physical examination showed a mean extension of -2° (range: -4 to 0) and flexion of approximately 150° (range: 120° to 160°). None of the patients presented a difference of 15° or more in range of motion between one side and the other.

All patients returned to work on average six weeks after surgery. Among the 15 patients, 14 were completely satisfied

and would go through the procedure again if necessary. Mild to moderate pain in strenuous repetitive activities was reported by four patients (27%).

Among the arthroscopic findings, six patients presented synovitis and two presented free bodies.

Complications such as temporary paresthesia of the forearm were observed in only one case. Anesthesia in the ulnar region and posterior interosseous deficit were not reported. No other complications were observed.

Discussion

Lateral epicondylitis is one of the main causes of elbow pain, but controversy exists regarding its physiopathology and etiology. The most accepted theory proposes that micro and macro lesions occur at the origin of the extensors (especially the SREC) as an incomplete response to regeneration and then cause a condition of tendinosis.^{3,7,11} This demonstrates that the clinical condition is due to a vascular and fibrotic response (angiofibroblastic), and not due to an inflammatory process. Treatment in most cases is conservative and only a small portion of recalcitrant cases are referred for surgical treatment.¹²

The literature demonstrating different types of therapy for treating epicondylitis is vast, ranging from clinical and physiotherapeutic treatments, including shock waves, platelet-rich plasma and corticoid, to surgery, which can be open, percutaneous or arthroscopic. Ahmad et al. demonstrated the use of platelet-rich plasma (PRP).¹³ Assendelft et al.¹⁴ conducted a systematic review that compared the validity and results of randomized clinical trials with control groups regarding the use of corticoid for treating lateral epicondylitis. These authors reported that there was a short-term beneficial effect (two to six weeks), but in follow-ups of more than six weeks, there were no statistically significant differences between the use of corticoid and other forms of treatment, including placebo. No conclusion can be reached regarding the type of corticoid, dose, dosage interval and volume injected.

In a systematic review with nine studies on the use of PRP for treating lateral epicondylitis, Ahmad et al.¹³ concluded that the evidence regarding PRP use was limited. Future investigations are needed in order to better understand the concentration and manner of preparation, so as to facilitate the best possible result. Gosens et al.¹⁵ compared the use of PRP with corticoid and found significantly superior results from the PRP group in relation to the DASH score, over one and two years of follow-up.

Miyazaki et al.¹⁶ reported the results from 20 patients operated over an eight-year period and demonstrated that 65% had excellent outcomes, according to the Bruce scale. There was one case of reflex sympathetic dystrophy. In the present study, there was one case of paresthesia of the lateral portion of the forearm. We used a similar surgical technique, although instead of carrying out decortication of the lateral epicondyle with a drill bit, we used a Steinman wire to create microperforations in the lateral epicondyle.

This study evaluated the results from the technique described by Romeo and Cohen regarding arthroscopic release of the SREC, which attained satisfactory results in nearly 90%

Table 5 – Relationship between gender and trauma mechanism and the results (postoperative Mayo score).

	N	Mean	SD	Median	Min	Max	p value ^a
<i>Gender</i>							
Male	9	96.25	3.5	95	90	100	0.68
Female	6	95	4.4	95	90	100	
<i>Injury mechanism</i>							
Profession	9	94.4	3.9	95	90	100	0.18
Sport	6	97.5	2.7	97.5	95	100	

^a Mann-Whitney test.

with a follow-up of 3.5 years. In the present study, we found that 95% of the results were excellent. A single female case was considered to have a fair result, with 72 points on the Mayo Clinic scale.

The results from the surgical treatment of lateral epicondylitis are not uniform, as also reported by other studies. Verhaar et al.¹⁷ reported that 66% of their results were satisfactory, in one of the only prospective studies on surgical treatment using the open technique over a follow-up period of one year. In their study, only one third of the patients returned to work. Nirschl and Pettrone⁷ reported that 85% of the patients treated using the open technique achieved complete improvement of their symptoms. Baumgard and Schwartz¹⁸ treated 35 patients using the percutaneous release technique and obtained excellent results in 91%. In the present study, 100% of the patients returned to work within six weeks and only one patient would not go through surgery again if necessary.

Arthroscopic treatment with SREC release is an option for lateral epicondylitis. Owen et al.¹⁹ reported their surgical results from 16 patients relating to arthroscopic release, who all achieved good results and returned to work with no restrictions within six days. In a study on 42 patients, Baker et al.⁴ reported that 95% showed good results, through only 62% patients were practically pain-free and 10% continued to present a painful condition during daily activities, similar to the results from open release.^{6,18,20,21} In the present study, among the 15 patients who underwent surgery, 90% were practically pain-free over the six-week follow up.

Controversy surrounds the physiopathology of epicondylitis. Some authors report that it is an extra-articular disorder. However, no studies have shown any difference in results between arthroscopic and open surgery.⁴ In the technique used in the present study, capsulotomy was performed in the lateral region, followed by removal of the SREC from its insertion, which is a structure adjacent to the joint capsule and thus does not affect nearby structures. We believe that the arthroscopic technique enables viewing of associated intra-articular lesions, which may reach up to 60% of the cases.²² Moreover, this allows earlier recovery, since it does not violate the aponeurosis of the extensors and does not cause deinsertion of other structures that have not been affected in the anagfibroblastic process.

Conclusion

Arthroscopic treatment for lateral epicondylitis is a safe and efficient therapeutic option when indicated and implemented

appropriately in refractory cases of chronic lateral epicondylitis. This technique also allows excellent viewing of the joint space, in order to diagnose and treat associated disorders using a minimally invasive procedure.

Conflicts of interest

The authors declare no conflicts of interest.

REFERENCES

- Edwards SG, Calandruccio JH. Autologous blood injections for refractory lateral epicondylitis. *J Hand Surg Am.* 2003;28(2):272-8.
- Leadbetter WB. Cell-matrix response in tendon injury. *Clin Sports Med.* 1992;11(3):533-78.
- Regan W, Wold LE, Coonrad R, Morrey BF. Microscopic histopathology of chronic refractory lateral epicondylitis. *Am J Sports Med.* 1992;20(6):746-9.
- Baker CL Jr, Murphy KP, Gottlob CA, Curd DT. Arthroscopic classification and treatment of lateral epicondylitis: two-year clinical results. *J Shoulder Elbow Surg.* 2000;9(6):475-82.
- Boyd HB, McLeod AC Jr. Tennis elbow. *J Bone Joint Surg Am.* 1973;55(6):1183-7.
- Coonrad RW, Hooper WR. Tennis elbow: its course, natural history, conservative and surgical management. *J Bone Joint Surg Am.* 1973;55(6):1177-82.
- Nirschl RP, Pettrone FA. Tennis elbow The surgical treatment of lateral epicondylitis. *J Bone Joint Surg Am.* 1979;61(6A):832-9.
- Hagberg S. New surgical approach to lateral epicondylitis of the humerus. *Lancet.* 1972;1(7747):441-2.
- Stovell PB, Beinfield MS. Treatment of resistant lateral epicondylitis of the elbow by lengthening of the extensor carpi radialis brevis tendon. *Surg Gynecol Obstet.* 1979;149(4):526-8.
- Cohen MS, Romeo AA. Open and arthroscopic management of lateral epicondylitis in the athlete. *Hand Clin.* 2009;25(3):331-8.
- Goldie I. Epicondylitis lateralis humeri (Epicondylalgia or tennis elbow). A pathogenetical study. *Acta Chir Scand Suppl.* 1964;57 Suppl 3391+.
- Lech O, Piluski PCF, Severo AL. Epicondylite lateral do cotovelo. *Rev Bras Ortop.* 2003;38(8):421-35.
- Ahmad Z, Brooks R, Kang SN, Weaver H, Nunney I, Tytherleigh-Strong G, et al. The effect of platelet-rich plasma on clinical outcomes in lateral epicondylitis. *Arthroscopy.* 2013;29(11):1851-62.
- Assendelft WJ, Hay EM, Adshead R, Bouter LM. Corticosteroid injections for lateral epicondylitis: a systematic overview. *Br J Gen Pract.* 1996;46(405):209-16.

15. Gosens T, Peerbooms JC, Van Laar W, Den Ouden BL. Ongoing positive effect of platelet-rich plasma versus corticosteroid injection in lateral epicondylitis: a double-blind randomized controlled trial with 2-year follow-up. *Am J Sports Med.* 2011;39(6):1200-8.
16. Miyazaki AN, Fregoneze M, Santos PD, Silva LA, Pires DC, Neto JM, et al. Avaliação dos resultados do tratamento artroscópico da epicondilite lateral. *Rev Bras Ortop.* 2010;45(2):136-40.
17. Verhaar J, Walenkamp G, Kester A, Van Mameren H, Van der Linden T. Lateral extensor release for tennis elbow A prospective long-term follow-up study. *J Bone Joint Surg Am.* 1993;75(7):1034-43.
18. Baumgard SH, Schwartz DR. Percutaneous release of the epicondylar muscles for humeral epicondylitis. *Am J Sports Med.* 1982;10(4):233-6.
19. Owens BD, Murphy KP, Kuklo TR. Arthroscopic release for lateral epicondylitis. *Arthroscopy.* 2001;17(6):582-7.
20. Gardner RC. Tennis elbow: diagnosis, pathology and treatment: nine severe cases treated by a new reconstructive operation. *Clin Orthop Relat Res.* 1970;72:248-53.
21. Posch JN, Goldberg VM, Larrey R. Extensor fasciotomy for tennis elbow: a long-term follow-up study. *Clin Orthop Relat Res.* 1978;1978(135):179-82.
22. Lattermann C, Romeo AA, Anbari A, Meininger AK, McCarty LP, Cole BJ, et al. Arthroscopic debridement of the extensor carpi radialis brevis for recalcitrant lateral epicondylitis. *J Shoulder Elbow Surg.* 2010;19(5):651-6.