



Open Access

CLINICIAN'S WORKSHOP

Sexual Function

Modified technique in treating recurrent priapism: a technique report

Wei Chen¹, Shu-Ben Sun², Li-An Sun¹, Jian-Ming Guo¹, Guo-Min Wang¹

Asian Journal of Andrology (2015) 17, 329–331; doi: 10.4103/1008-682X.144944; published online: 19 December 2014

Recurrent ischemic priapism is a problem in clinical treatment. Most of the cases require more invasive surgery to shunt the blood stasis. We introduce a modified technique in treating recurrent ischemic priapism. The technique described is applied to acute ischaemic priapic episodes in patients with a history of stuttering priapism. It was carried out by a Winter's shunt combined with a continuous cavernosal irrigation system. Priapism was effectively resolved on the patients without recurrence. The four patients who received this treatment recovered most sexual function after 6 months follow-up.

The authors would introduce a technique in treating recurrent ischemic priapism, a Winter's shunt that combined with continuous cavernosal irrigation. The measurement can overcome the shortcoming of Winter's shunt and effectively resolve recurrent ischemic priapism. It can avoid the creation of a more invasive shunt or even an open surgery.

Ischemic priapism is a rare emergency urological disease that is characterized by persistent penile erection continuing beyond, or unrelated to, sexual stimulation.^{1,2} It is a disorder of venous outflow and/or stasis.³ If it is not be treated effectively and timely, long-term impotence may result. Priapism can be treated by intracavernosal injection with a dilute solution of phenylephrine or cavernosal irrigation with saline.^{1,4} Some priapism cases need a less invasive shunt such as Winter's shunt⁵ to create a shunt distally between the corpora cavernosal and glans of the penis with the large biopsy needle. With this method, the

congested cavernosa can be drained through venous drainage of corpora spongiosum and the corporal cavernosa. However, those therapies cannot be effectively used to resolve prolonged priapism because of thrombocyte adherence and loss of contractile trabecular elements.⁶ Priapism still repeatedly recurred after the therapies. Recurrent ischemic priapism is a problem in clinical treatment. Most of the cases require more invasive surgery to shunt the blood stasis.⁷ Surgical treatment includes distal shunt (Ebbehøj, Al-Ghorab) and proximal shunt (cavernospongiosus shunt, cavernosalsaphenous shunt). Like Winter's shunting, Ebbehøj or Al-Ghorab is to create a corporoglanular shunt with a scalpel rather than a needle.^{8–10} The proximal shunts are open surgical operations.^{11,12} The surgical treatments are more invasive. It is reported that proximal shunts can easily result in impotence (49% with cavernospongiosal shunts and 52% with cavernosalsaphenous shunts) and significant complication such as urethral fistula, cavernositis¹¹ and even pulmonary embolism.^{13,14}

TECHNIQUE OUTLINE

Our technique is a Winter's shunt combined with continuous irrigation. It was designed to resolve the recurrent ischemic priapism. The technique described is applied to acute ischaemic priapic episodes in patients with a history of stuttering priapism. This technique may assist in avoiding more invasive surgery.

With the patient in the supine position or semisupine position, the perineal area was disinfected. A Winter's shunt was made by insertion of a 16 G needle (**Figure 1**) with a sheath (IV catheter, B. Braun Medical Industry, Germany) through the glans penis lateral to the meatus into the underlying distal end of one of the rigid corporal cavernosa (**Figure 2**). The puncture point

should be at 1 o'clock on glans. Another sheathed needle of the same type is inserted laterally into the corporal cavernosa in the middle of the penis. The puncture point should be at the 10 o'clock position on penis. The corpora cavernosa is then irrigated with a 20 cc syringe (**Figure 2a**). Both needles are removed from their sheaths (catheters). The catheters were left indwelling in the corpora cavernosa (**Figure 2b**). A liquid infusion pipe is connected with the catheter at the middle of the penis through which the saline solution can continuously drip into the corpora cavernosa (**Figure 2b**). Anesthesia is not necessary for the process. A drainage tube is connected with the catheter at the glans penis to drain the corpora cavernosa (**Figure 2c**). It is key to keep the catheters from sharply bending and to control the drip at a slow rate. Alpha receptor agonists should not be added to the saline solution as it might increase blood pressure during the long period of irrigation. The treatment extended over 12 h after priapism was resolved without recurrence. After removal of the catheters pressure should be applied to the puncture points for 10 minutes to assure hemostasis. During the treatment, input - output liquid should be noted in detail to keep a balance. Routine tests of blood, especially the hemoglobin content should also be monitored carefully. The four patients with ischemic priapism received the treatment. Patients' information including the duration, history, causes, and any prior management of priapism were indicated in **Table 1**.

The four patients with a history of stuttering priapism received the modified treatment. All the cases were of prolonged ischemic priapism and some interventions were tried previously including elimination of the cause promptly, aspiration, cavernosal irrigation with phenylephrine solution and

¹Department of Urology, Zhongshan Hospital of Fudan University, Shanghai, China; ²Department of Urology, The Affiliated Hospital of School of Medicine of Ningbo University, Ningbo, China.
Correspondence: Dr. JM Guo (guo.jianming@zs-hospital.sh.cn) or Dr. GM Wang (wang.guomin@zs-hospital.sh.cn)

Table 1: The information of the four patients with recurrent ischemia priapism

Patient	Age	Etiology	Duration (h)	Recurrent times	Prior intervention	Length of treatment (h)	Rinse (ml)	IIEF
1	36	Idiopathic	11	2	Intermittent massage of penis, aspiration, cavernosal irrigation with phenylephrine solution	12	2500	20
2	31	Idiopathic	18	2	Aspiration, cavernosal irrigation with phenylephrine solution, Winter's shut	24	2500	18
3	42	PDE5 inhibitor	27	3	Aspiration, cavernosal irrigation with saline solution, Winter's shut	24	2000	15
4	56	Alpha blocker	23	4	Aspiration, cavernosal irrigation with norepinephrine solution, Winter's shut	24	2000	11

IIEF: International Index of Erectile Function questionnaire (22–25: no erectile dysfunction; 17–21: mild erectile dysfunction; 12–16: mild to moderate erectile dysfunction; 8–11: moderate erectile dysfunction; 5–7: severe erectile dysfunction)

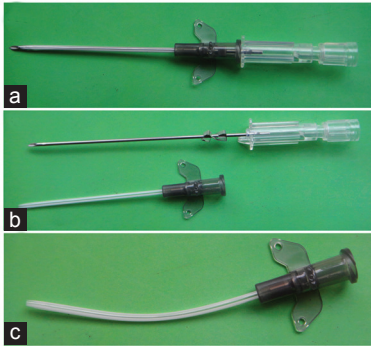


Figure 1: The apparatus used in the technique. (a) Needle and catheter. (b) Needle pulled out from catheter. (c) The catheter is soft and flexible.

Winter's shut that were successful in reaching detumescence, but the priapism recurred. The duration of priapism was from 11 h to 27 h before the modified treatment. The length of the modified treatment was from 12 h to 24 h. In the four patients, priapism were effectively resolved without recurrence after the treatment.

The modified therapy is well-tolerated. No complication happened. International Index of Erectile Function questionnaire was used to evaluate the erectile function. The four patients recovered substantial sexual function after 6 months follow-up (Table 1).

COMMENTS

Priapism represents one of the greatest challenges in therapeutic management among erectile disorders.^{1,2} If not effectively treated, low flow priapism can cause necrosis and fibrosis of the cavernous tissue and can lead to complete erectile dysfunction. The incidence of impotence is directly related to the duration of the priapism and to the aggressiveness of treatment. Because of these factors, recurrent ischemic priapism can be very damaging. It lasts longer and tends to need more aggressive approaches. Futral and Witt¹⁵ designed a continuous irrigation approach with two-needle-insertion. It can extend irrigation time and avoid repeat aspiration. But the method is still cavernosal irrigation but

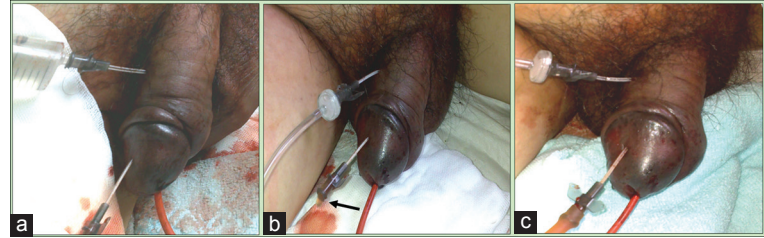


Figure 2: Winter's shunt combined with continuous irrigation. (a) Irrigated the corporal cavernosa. (b) Continuous irrigation with the two catheters. Liquid can run out from outflow tract (arrow). (c) A liquid infusion pipe and a drainage tube were connected with the catheters.

without a shunt. Besides, with two sharp and pointed needles inserted in corpora cavernosa, it is easy to dislodge the needles when patients change position. With this approach patients have to watch their position continuously and cannot readily receive long term continuous irrigation as it is not easily tolerated.

Detumescence of priapism depends on the recovery of corporeal smooth muscle function and re-established venous drainage of corpora spongiosum and the corpora cavernosa.¹⁶ The penis subjected to prolonged priapism has thrombocyte adherence and loss of contractile trabecular elements.⁶ Recurrent attack of priapism works against the recovery of corporeal smooth muscle function. Winter's shunt narrows or closes too early to cause efficient drainage because it uses simply a needle. Those factors may lead to the failure in treating the priapism.

It was upon this principle that our method was designed. Guided with the needles, two catheters were placed in cavernosa bodies, the needles are then removed leaving only the soft sheathing catheters. The soft catheters are very safe for long-term irrigation and help corporal smooth muscle recover its function. In our opinion, the longer insertion time of catheters can remove the thrombocyte adherence and may play a supporting role in keeping the shunt from narrowing or closing sooner than optimal. Although the needles are 16 G, the sheath makes a slightly larger shunt. After irrigation, the soft sheaths should be removed, and the shunt will start to work.

The main limitation of our technique is small case number. However with this procedure, all four patients with recurrent priapism had detumescence of priapism without recurrence. They had recovered most of their sexual function after 6 months follow-up. Further investigation is necessary to analyze the safety and effectiveness of the technique.

AUTHOR CONTRIBUTIONS

WC performed the operation, wrote and submitted the article. SRS and LAS followed up the patients. JMG and GMW instructed the whole study and revised the article. All authors reviewed and approved the article.

COMPETING INTERESTS

The authors declare that there is no conflict of interest.

REFERENCES

- Montague DK, Jarow J, Broderick GA, Dmochowski RR, Heaton JP, et al. American Urological Association guideline on the management of priapism. *J Urol* 2003; 170: 1318–24.
- Burnett AL, Bivalacqua TJ. Priapism: current principles and practice. *Urol Clin North Am* 2007; 34: 631–42, viii.
- Lue TF, Hellstrom WJ, McAninch JW, Tanagho EA. Priapism: a refined approach to diagnosis and treatment. *J Urol* 1986; 136: 104–8.
- Muruve N, Hosking DH. Intracorporeal phenylephrine in the treatment of priapism. *J Urol* 1996; 155: 141–3.
- Winter CC. Cure of idiopathic priapism: new procedure for creating fistula between glans penis and corpora cavernosa. *Urology* 1976; 8: 389–91.
- Spycher MA, Hauri D. The ultrastructure of the erectile tissue in priapism. *J Urol* 1986; 135: 142–7.
- Burnett AL. Surgical management of ischemic

- priapism. *J Sex Med* 2012; 9: 114–20.
- 8 Ebbehøj J. A new operation for priapism. *Scand J Plast Reconstr Surg* 1974; 8: 241–2.
 - 9 Segal RL, Readal N, Pierorazio PM, Burnett AL, Bivalacqua TJ. Corporal Burnett “Snake” surgical maneuver for the treatment of ischemic priapism: long-term followup. *J Urol* 2013; 189: 1025–9.
 - 10 Dangle PP, Patel MB, Pandya LK, Firlit CF. A modified surgical approach to the Al-Ghorab shunt – An anatomical basis. *BJU Int* 2012; 109: 1872–4.
 - 11 Shiraishi K, Matsuyama H. Salvage management of prolonged ischemic priapism: AL-Ghorab shunt plus cavernous tunneling with blunt cavernosotomy. *J Sex Med* 2013; 10: 599–602.
 - 12 Burnett AL, Sharlip ID. Standard operating procedures for priapism. *J Sex Med* 2013; 10: 180–94.
 - 13 De Stefani S, Savoca G, Ciampalini S, Stener S, Gattucio I, *et al.* Urethrocuteaneous fistula as a severe complication of treatment for priapism. *BJU Int* 2001; 88: 642–3.
 - 14 Kandel GL, Bender LI, Grove JS. Pulmonary embolism: a complication of corpus-saphenous shunt for priapism. *J Urol* 1968; 99: 196–7.
 - 15 Futral AA, Witt MA. A closed system for corporeal irrigation in the treatment of refractory priapism. *Urology* 1995; 46: 403–4.
 - 16 Broderick GA, Kadioglu A, Bivalacqua TJ, Ghanem H, Nehra A, *et al.* Priapism: pathogenesis, epidemiology, and management. *J Sex Med* 2010; 7: 476–500.