



## Case Report

# Reconsidering some standards in immediate autotransplantation of teeth: Case report with 2-year follow-up

Nuraldeen Maher Al-Khanati<sup>\*</sup>, Zafin Kara Beit

Department of Oral and Maxillofacial Surgery, Faculty of Dental Medicine, Damascus University, Damascus, Syria



## ARTICLE INFO

## Keywords:

Autogenous transplantation  
Sinus tract  
Rapid prototyping  
Pulp revitalization  
Case report

## ABSTRACT

**Introduction:** Dental autotransplantation (DAT) is that surgical procedure of extracting a tooth from one place (donor site) and transplanting it into another (recipient site) within the same individual. If successfully implemented, the treatment outcome will pose characteristics of a natural tooth rather than a dental prosthesis. This case report sheds light on the validity of this treatment option, and provides suggestions to reconsider some standards regarding its conventional protocols.

**Case presentation:** A 24-year-old female with no history of medical conditions presented with hopeless non-restorable lower molars with clinical signs of chronic infection. Cone-beam computed tomography (CBCT) was used to check compatibility of her third molars for DAT. After clinical and radiographical examination, patient's consent to perform DAT of impacted upper right third molar to replace the lower right first molar was obtained. Based on patient's CBCT, an individual replica of the donor tooth was fabricated. Replica helped in pre-preparing recipient site to fit the dimensions of the donor tooth before being extracted and transplanted. The extraction socket was thoroughly debrided and irrigated to ensure the removal of any lesion or infection. Immediate DAT was carried out with minimal trauma to the transplant. Follow-up for 2 years showed functional transplant with uneventful healing of periodontal and pulpal tissues.

**Conclusion:** Some standards regarding DAT needs to be reconsidered. Routine prophylactic endodontic treatment is not necessary for every case of DAT even when transplanted tooth is mature. Immediate autotransplantation into an infected site can be successful if the recipient site is managed properly.

## 1. Introduction

Dental autotransplantation (DAT) is a minor oral surgical procedure in which a natural tooth replaces a missing one in the same person. Like immediate dental implantation, DAT can be described as "immediate" when DAT into a recipient site is done immediately after tooth extraction. This treatment modality has proven good survival and success rates that was estimated to be 98.2% and 96.6% respectively [1]. Nevertheless, this treatment option has been ignored by many dentists and oral surgeons worldwide and specifically in Syria [2]. They may exaggerate challenges and believe that DAT will inevitably result in ankylosis, root resorption and/or pulp necrosis especially of transplants with complete root formation. Performing root canal treatment (RCT) for every mature autotransplant during or nearly after DAT as standard protocol could be another challenge. Moreover, it could not be easy to find a way to prepare the recipient site to fit transplant's roots' shape and dimensions before DAT, avoid unnecessary bone removal, and to fit transplant's

crown within occlusion without the need for further orthodontic treatment or fixed prosthesis. Last but not least, the presence of pathology and/or infection at the recipient site has always been considered as contraindication for immediate DAT [3,4].

This paper aims to provide solutions to some DAT-related concerns, and suggestions to alter some DAT standards and protocols by reporting a successful immediate DAT of a mature upper third molar into an infected recipient site with a 2-year clinical and radiographical follow-up. This case report has been reported in line with the SCARE criteria [5].

## 2. Case presentation

A 24-year-old female patient presented to the Department of Oral and Maxillofacial Surgery at Faculty of Dental Medicine (Damascus University, Damascus, Syria) with widely destructed lower right molars (Fig. 1a; Fig. 1b). She complained of unpleasant smell and taste from her mouth, and a severe masticatory dysfunction. The patient was non-

<sup>\*</sup> Corresponding author. Department of Oral and Maxillofacial Surgery, Faculty of Dental Medicine, Damascus University, P.O. Box 222, Damascus, Syria.  
E-mail address: [nuraldeen.alkhanati@gmail.com](mailto:nuraldeen.alkhanati@gmail.com) (N.M. Al-Khanati).

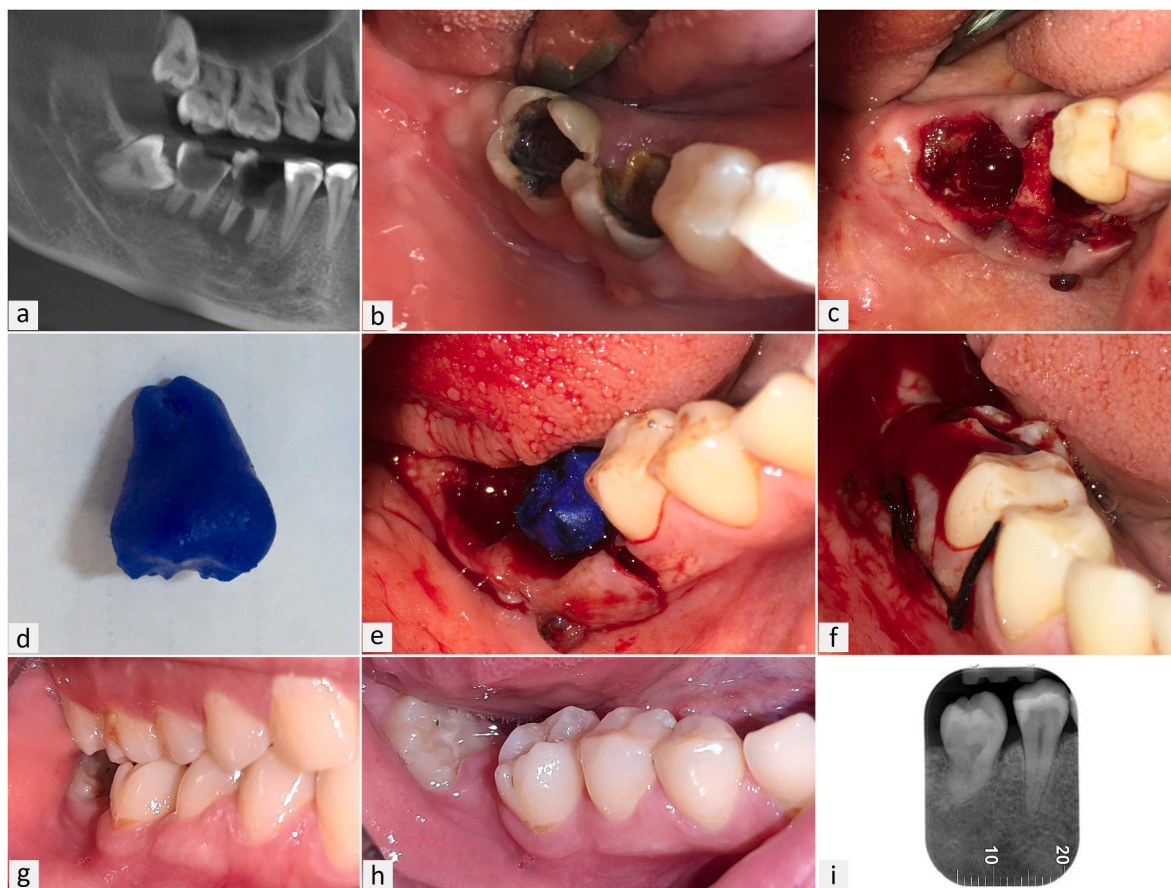
**Abbreviations**

DAT	Dental Autotransplantation
RCT	Root Canal Treatment
SCARE	Surgical CAse REport
3D	Three Dimensional
CBCT	Cone-Beam Computed Tomography
DICOM	Digital Imaging and Communications in Medicine
rpm	round per minute

smoker, and her medical history did not reveal any systemic disease. The patient was on oral contraceptives. She was directed to discontinue oral contraception and switch, if necessary, to alternative contraceptive methods for 4 weeks before and 2 weeks after the surgical procedures. The clinical (Fig. 1b) and radiographic (Fig. 1a) examination showed hopeless right lower permanent first and second molars with a radiolucent lesion involving both destructed teeth. Chronic odontogenic infection from these molars caused intraoral sinus tract on the buccal attached gingiva (Fig. 1b). She was informed of the diagnosis and the need for dental extractions. All treatment options were explained to the patient in details including DAT. The patient was very excited about autotransplantation option. Her consent to perform DAT and to use her clinical data for academic and publishing purposes, while concealing her identifying personal information, was obtained. Before any surgical

intervention, the impacted upper right third molar was evaluated as a donor using cone-beam computed tomography (CBCT) image for immediate transplantation (Fig. 1a). Also, digital imaging and communications in medicine (DICOM) files from the patient's CBCT image were used to isolate and print a three-dimensional (3D) replica of the potential donor tooth. The DICOM files processing and the segmentation of donor tooth were mainly performed using Mimics software (V21; Materialise; Leuven, Belgium).

Minimal-traumatic extraction of lower right first and second permanent molars were performed. The surgical procedure was performed by an operator experienced in DAT. Small surgical flap was retracted to enhance vision, and teeth hemi-sectioning (roots separation) was done before extraction to facilitate minimal-traumatic extraction (Fig. 1c). The extraction sockets were debrided and heavily irrigated with saline and disinfectants following Al-Khanati protocol [6]. A 3D-printed replica of the potential donor tooth (Fig. 1d) was used to prepare the recipient site (Fig. 1e). Recipient socket preparation was done via surgical contra-angled handpiece and round carbide bur (20,000 rpm) with copious saline irrigation. After the transplant bed was ready, socket bleeding was induced with a curette and the assistant was instructed not to suction the blood from the socket. Atraumatic extraction of upper right third molar was done without using surgical burs to avoid injury to the periodontal ligament. Immediate DAT of the third molar into the bloody lower first molar site was performed (Fig. 1f). Extra-alveolar time of the transplant did not exceed 20 seconds. Occlusion was examined to ensure that the transplant's crown was out of occlusion as pre-set with aid of the 3D-printed replica. Non-rigid immobilization of the transplant



**Fig. 1.** Tooth autotransplantation procedure. Patient's X-ray showing the upper third molar as a potential donor, and the destructed lower first molar with periapical lesion in the recipient site (a); Clinical image of the recipient site before teeth extraction showing signs of odontogenic infection (b); Dental extractions and sockets debridement and disinfection (c); 3D replica of the donor tooth used to prepare the recipient bed before transplantation (d, e); Dental transplant in its bloody new socket fixed with figure-of-eight suturing technique (f); Clinical follow-up (g, h); Periapical X-ray showing normal periodontal ligament and lamina dura with no pathological signs after 2 years (i).

was done using silk suture only (Fig. 1f). Post-surgical instructions included soft diet for one month and to avoid mobilizing or touching the “new tooth” as possible. Medical prescription included antibiotics: metronidazole 500mg (tablet 3 times per day for 7 days) and amoxicillin 500mg (capsule 3 times per day for 7 days), non-steroidal anti-inflammatory drug: diclofenac potassium 50mg (tablet 3 times per day for 3 days), and mouthwash with chlorhexidine gluconate 0.12% (twice a day for 10 days). The patient was very cooperative and adhered to the post-operative instructions. Sutures were removed after 2 weeks post-surgery.

The patient was followed up for 2 years. Follow-up included the following clinical parameters: periodontal probing, gingival index, mobility, percussion, occlusion, and pulp vitality tests. Although it was slightly rotated, the autotransplant was in good periodontal health and functional status after 2 years (Fig. 1g; Fig. 1h). No tooth discoloration occurred. Moreover, electric pulp vitality test showed positive results. Periapical x-ray of the transplant showed normal periodontal space along with normal lamina dura with no evidence of ankylosis, internal and external root resorptions, or periapical pathology (Fig. 1i). The patient had no complaints and showed utter satisfaction towards the treatment results.

### 3. Discussion

Despite the high success rates of dental implants, many limitations may prevent dentists and dental implantologists from providing this treatment, and patients from accepting it to replace missing teeth. For instance, high treatment costs, relatively long period of time for osteointegration, presence of infection and/or pathological lesion in the implant site, and challenges to achieve pink esthetics in some cases may be influential obstacles. Further, placing dental implants in children and adolescents has always been a controversial issue [7]. Moreover, implant-supported prostheses lack important features in comparison to natural teeth due to absence of periodontal ligament in osseointegrated implants. These missing biological properties mainly include proprioception and shock-absorption. Therefore, risk of complications like ceramic fracture and chipping significantly increases in implant-supported fixed prostheses [8]. Furthermore, essential differences between periodontal tissues versus peri-implant adaptation of soft tissues (i.e., parallel fibers orientation) exists [9]. This, in addition to lower vascularity and cellularity, makes dental implants more susceptible to bacterial invasion and disease progression than natural teeth [9]. Here, the following question can be issued: “Will DAT of a natural tooth overcome the aforementioned limitations and obstacles and be a viable good alternative to dental implants?”

This case report presents successful immediate autotransplantation of impacted maxillary third molar into a mandibular first molar site. Although similar cases can be found in the literature, most of these cases described DAT of immature donors or the DAT protocol included RCT of the mature donors usually after the surgical procedure [6,10]. It has been believed that dental pulps of completely mature teeth have no ability to regenerate [10]. In addition, the conventional protocol usually includes avoiding immediate DAT into a recipient site involving infection or pathological lesion [3]. This has been considered as one of DAT contraindications [4]. The present case issues question marks around the aforementioned criteria and standards, and highlights the possibility of immediate DAT of a tooth with complete root formation into an infected recipient site without the need for RCT. The electric pulp vitality testing, combined with absence of periapical lesion and crown discoloration for two years, can confirm pulp revitalization of the mature transplant in the present case. The deep-rooted notion that routine prophylactic RCT is necessary for every tooth intended to be transplanted during or after DAT has to be reconsidered. This practice disallows the transplant to revascularize, and can cause damage to the periodontal tissues increasing complications and failure risk especially if RCT is performed extra-orally. Hereby, we suggest changing the protocol and replacing it

with one that limits RCT to transplants that show clinical and/or radiographic signs of dental pulp necrosis.

Many factors can influence DAT success. Success in this context means presence of functional transplant that shows no clinical or radiographic signs of ankylosis, root resorption, mobility and pulp necrosis. Atraumatic or minimal-traumatic donor-site extraction and handling of the transplant have the greatest role in the success predictability. Periodontal ligament injury due to traumatic extraction, deleterious handling, or extended extra-socket time can increase auto-transplantation risk of failure [11]. Suzaki et al. suggested that application of orthodontic force to increase width of donor tooth periodontal ligament can facilitate less-traumatic extraction and increase DAT success rates [12]. However, this was not applicable in the present case where donor tooth was impacted. Generally speaking, dental extraction in the maxilla is less traumatic than in the mandible. So, it was preferred to use maxillary third molar as a donor for DAT rather than mandibular third molar. If there is a need to consider an impacted mandibular donor tooth, we suggest using piezoelectric technology for osteotomy to avoid injury to the donor tooth and its periodontal ligament with conventional surgical rotatory burs. Moreover, trauma from occlusion after DAT must be eliminated. This was done by pre-preparing the recipient site for the transplant to be out-of-occlusion. This was done aided by a 3D-printed replica of the donor tooth.

Rapid prototyping of individual replica of the donor tooth based on the patient’s CBCT was done via 3D printing technology. The 3D replica substantially aided in reducing the extra-alveolar time, which had been considered an important influencing factor for normal periodontal healing and DAT success [13]. A recent retrospective study showed that DAT assisted by rapid prototyping was associated with reduced need for RCT [14]. Pre-preparing the recipient site with aid of transplant replica also averted unnecessary osteotomy during DAT. Further, operator was able to adjust inclined adjacent teeth and overerupted opposite tooth, if necessary, by dint of this replica before extraction of the donor tooth.

### 4. Conclusion

Immediate autotransplantation of mature maxillary third molar to replace mandibular first molar with odontogenic infection and periradicular lesion can be valid treatment option if recipient site is managed properly. DAT protocols that include routine endodontic therapy for every tooth with complete root formation need to be reconsidered. Further well-designed clinical studies are warranted.

### Sources of funding

This paper received no specific grant from any funding agency in the public, commercial, or not-for-profit sectors.

### Consent

Written informed consent was obtained from the patient for publication of this case report and accompanying images. A copy of the written consent is available for review by the Editor-in-Chief of this journal on request.

### Author contributions

All authors have contributed substantially to the work. Conceptualization, N.M.A. and Z.K.B.; Methodology, N.M.A.; Writing- original draft, N.M.A.; Writing-review and editing, Z.K.B.; Final approval, N.M.A. and Z.K.B.

### Guarantor

Dr. Nuraldeen Maher Al-Khanati; [nuraldeen.alkhanati@gmail.com](mailto:nuraldeen.alkhanati@gmail.com).

## Provenance and peer review

Not commissioned, externally peer-reviewed.

## Declaration of competing interest

Each named author has no conflict of interest, financial or otherwise.

## Acknowledgment

Authors would like to share a sincere gratitude to Dr. Maher Ahmad Al-Khanati for his kind support and valuable advices.

## Appendix A. Supplementary data

Supplementary data to this article can be found online at <https://doi.org/10.1016/j.amsu.2022.103470>.

## References

- [1] E.C.M. Rohof, W. Kerdijk, J. Jansma, C. Livas, Y. Ren, Autotransplantation of teeth with incomplete root formation: a systematic review and meta-analysis, *Clin. Oral Invest.* 22 (4) (2018) 1613–1624, <https://doi.org/10.1007/s00784-018-2408-z>.
- [2] N.M. Al-Khanati, Z.K. Beit, Is dental autotransplantation underestimated and underused by Syrian dentists? *J Educ Eval Health Prof* 18 (2021) 18, <https://doi.org/10.3352/jeehp.2021.18.18>.
- [3] T. Nimčenko, G. Omerca, E. Bramanti, G. Cervino, L. Laino, M. Cicciù, Autogenous wisdom tooth transplantation: a case series with 6-9 months follow-up, *Dent Res J (Isfahan)*. 11 (6) (2014) 705–710.
- [4] K. Martin, S. Nathwani, R. Bunyan, Autotransplantation of teeth: an evidence-based approach, *Br. Dent. J.* 224 (11) (2018) 861–864, <https://doi.org/10.1038/sj.bdj.2018.432>.
- [5] R.A. Agha, T. Franchi, C. Sohrabi, G. Mathew, A. Kerwan, SCARE Group, The SCARE 2020 guideline: updating consensus surgical CAse REport (SCARE) guidelines, *Int. J. Surg.* 84 (2020) 226–230, <https://doi.org/10.1016/j.ijsu.2020.10.034>.
- [6] N.M. Al-Khanati, Immediate autotransplantation of immature maxillary third molar: a case report with 4-year clinical and radiographic follow-up, *Saudi Endod J* 9 (3) (2019) 226–230.
- [7] R.A. Shah, D.K. Mitra, S.V. Rodrigues, P.N. Pathare, R.S. Podar, H.N. Vijayakar, Implants in adolescents, *J. Indian Soc. Periodontol.* 17 (4) (2013) 546–548, <https://doi.org/10.4103/0972-124X.118335>.
- [8] B.E. Pjetursson, U. Brägger, N.P. Lang, M. Zwahlen, Comparison of survival and complication rates of tooth-supported fixed dental prostheses (FDPs) and implant-supported FDPs and single crowns (SCs), *Clin. Oral Implants Res.* 18 (Suppl 3) (2007) 97–113, <https://doi.org/10.1111/j.1600-0501.2007.01439.x>.
- [9] S. Ivanovski, R. Lee, Comparison of peri-implant and periodontal marginal soft tissues in health and disease, *Periodontol* 76 (1) (2018) 116–130, <https://doi.org/10.1111/prd.12150>, 2000.
- [10] J.H. Bae, Y.H. Choi, B.H. Cho, Y.K. Kim, S.G. Kim, Autotransplantation of teeth with complete root formation: a case series, *J. Endod.* 36 (8) (2010) 1422–1426, <https://doi.org/10.1016/j.joen.2010.04.028>.
- [11] J.H. Park, K. Tai, D. Hayashi, Tooth autotransplantation as a treatment option: a review, *J. Clin. Pediatr. Dent* 35 (2) (2010) 129–135, <https://doi.org/10.17796/jcpd.35.2.97816254u2140x88>.
- [12] Y. Suzuki, Y. Matsumoto, Z. Kanno, K. Soma, Preapplication of orthodontic forces to the donor teeth affects periodontal healing of transplanted teeth, *Angle Orthod.* 78 (3) (2008) 495–501, <https://doi.org/10.2319/020207-51.1>.
- [13] S.J. Lee, E. Kim, Minimizing the extra-oral time in autogenous tooth transplantation: use of computer-aided rapid prototyping (CARP) as a duplicate model tooth, *Restor Dent Endod* 37 (3) (2012) 136–141, <https://doi.org/10.5395/rde.2012.37.3.136>.
- [14] L.A. Hwang, C.Y. Chang, W.C. Su, C.W. Chang, C.Y. Huang, Rapid prototyping-assisted tooth autotransplantation is associated with a reduced root canal treatment rate: a retrospective cohort study, *BMC Oral Health* 22 (1) (2022) 25, <https://doi.org/10.1186/s12903-022-02058-9>.