

COVID-19 infection and treatment with hydroxychloroquine cause severe haemolysis crisis in a patient with glucose-6-phosphate dehydrogenase deficiency

Yan Beauverd¹  | Yannick Adam² | Benjamin Assouline² | Kaveh Samii¹

¹Haematology Division, Department of Oncology, Geneva University Hospitals, Geneva, Switzerland

²Intensive Care Division, Department of Acute Medicine, Geneva University Hospitals, Geneva, Switzerland

Correspondence

Yan Beauverd, Division of Haematology, Geneva University Hospitals, Rue Gabrielle-Perret-Gentil, 4, 1205 Geneva, Switzerland.
Email: yan.beauverd@hcuge.ch

Abstract

Glucose-6-phosphate dehydrogenase (G6PD) deficiency is an inherited genetic disorder caused by red cell enzymatic defects and is associated with haemolytic crisis when patients are exposed to oxidative agents (fava beans, drugs, infections). Hydroxychloroquine is suspected to trigger haemolytic crisis in G6PD-deficient patients, and off-label administration of this drug to patients infected with the novel coronavirus (SARS-CoV-2) could cause concern. We report here the first case of severe haemolytic crisis in a patient with G6PD deficiency, initiated by severe COVID-19 infection and hydroxychloroquine use. With worldwide spread of COVID-19, especially in regions with a high prevalence of G6PD deficiency, our case should alert physicians to this possible correlation.

KEYWORDS

coronavirus, COVID-19, G6PD deficiency, haemolysis, hydroxychloroquine, SARS-CoV-2

1 | CASE REPORT

A 68-year-old Congolese man with a past medical history of type 2 diabetes mellitus, high blood pressure, chronic renal insufficiency (G2 stage) and previous history of stroke was admitted to our hospital for COVID-19 infection, with fever, dyspnoea, muscular pain and tiredness. According to our institutional protocol, the patient was started on amoxicillin/clavulanate (1.2 g QID) on day 1 and hospitalised in the general internal medicine division. Because of rapid respiratory degradation and development of acute respiratory distress syndrome on day 3, amoxicillin/clavulanate was changed to piperacillin/tazobactam, and the patient was transferred to the intensive care unit (ICU), requiring mechanical ventilation. Also, regarding our institutional protocol, a single dose of hydroxychloroquine (600 mg, single dose) was administered on day 6. During hospitalisation, the patient experienced a progressive drop in haemoglobin levels from 12 g/dL on day 1 to 6.5 g/dL on day 6, requiring several blood transfusions. Full workup excluded digestive

spoliation. However, blood results demonstrated biological signs of haemolysis with a progressive increase in total and direct bilirubin and lactate dehydrogenase (LDH) levels from day 5. Analysis of a peripheral blood smear demonstrated numerous hemi-ghost cells and microspherocytes (Figure 1A) that were not present on day 1 (Figure 1B), suggesting an acute haemolytic crisis in the context of an unknown G6PD deficiency. A retrospective review of daily blood smears noted that a significant number of hemi-ghost cells and microspherocytes appeared from day 4 and gradually increased until day 7. Diagnosis of G6PD deficiency was confirmed with a dosage of G6PD/total haemoglobin (2.5 U/g HB, normal range > 7). We also noticed a worsening of haemolysis blood parameters the day following hydroxychloroquine administration (day 7). Day-by-day evolution of blood parameters, blood smear evaluation and treatment administration are summarised in Figure 1C. A retrospective analysis of medical charts did not find any medication that could have precipitated haemolysis in our patient. Based on these findings, this suggests that severe COVID-19 infection triggered haemolysis in a

patient with G6PD deficiency. Moreover, haemolysis was possibly worsened by hydroxychloroquine administration.

G6PD deficiency is the most common red cell enzyme disorder, affecting more than 300 million people worldwide. G6PD deficiency frequently occurs in Africa (especially the sub-Saharan region), Asia and the Mediterranean region.¹ G6PD enzymes catalyse the transformation of nicotinamide adenine dinucleotide phosphate (NADP) into NADPH, which protects cells from oxidative damage. Red cells are particularly sensitive to oxidative destruction because they cannot produce NADPH during their lifespan. Numerous G6PD variants have been described and provide information about the severity of enzyme deficiency and haemolysis. Class IV (no enzyme deficiency or haemolysis) and V (increased enzyme activity) have no clinical significance. Patients with Class I have severe enzyme deficiency with chronic haemolytic anaemia. Class II and III affected individuals do not present with haemolysis in the steady state, and haemolytic crisis is usually triggered by oxidative stress caused by food (fava beans), drugs, or medical conditions such as infection. No case

report describing SARS-CoV-1, SARS-CoV-2 or MERS-CoV as a trigger for G6PD deficiency haemolytic crisis has been described yet.

Currently, hydroxychloroquine is only licensed for the treatment of malaria, lupus erythematosus and rheumatoid arthritis. However, administration of hydroxychloroquine is increasing² as part of treatment for COVID-19 infection, despite lack of evidence. Current data demonstrate an in vitro activity against SARS-CoV-2,³ but clinical benefit remains unclear.⁴ Hydroxychloroquine is generally well-tolerated with only mild side effects. However, there is concern regarding haemolysis in G6PD individuals, even though a recent retrospective study did not find a correlation between hydroxychloroquine use and haemolysis in a population with G6PD deficiency and rheumatic disease.⁵

Our data demonstrated that severe COVID-19 infection can be the initial trigger of haemolytic crisis in a G6PD-deficient patient. In addition, in our patient, hydroxychloroquine administration appeared to worsen or prolong the haemolytic state. Because G6PD deficiency is the most common red cell enzymatic deficiency,

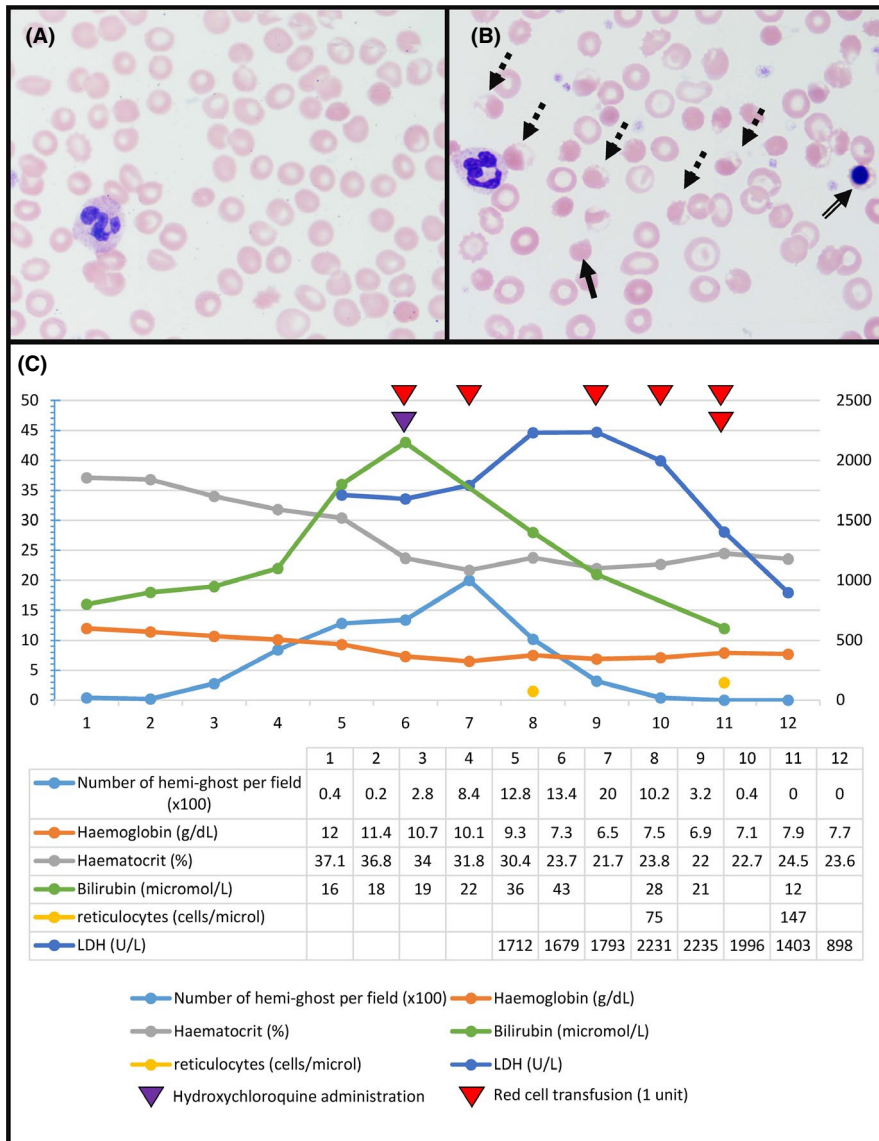


FIGURE 1 A, Normal peripheral blood smear before haemolytic crisis (100x magnification). B, Peripheral blood smear during haemolytic crisis with numerous hemi-ghost cells (dotted arrow), microspherocytes (plain arrow) and erythroblast (double arrow) (100x magnification). C, Timeline of blood parameters, blood smear, treatment administration and blood transfusion [Colour figure can be viewed at wileyonlinelibrary.com]



worldwide spread of SARS-CoV-2, especially in sub-Saharan Africa or in countries with a high proportion of African descendants, can expose numerous patients with unknown G6PD deficiency to severe haemolytic complications. In addition, concomitant use of hydroxychloroquine for COVID-19 could precipitate or worsen haemolytic crisis in G6PD-deficient patients. There are currently no data supporting the necessity for G6PD deficiency screening before starting hydroxychloroquine. However, rapid drop in haemoglobin should warn physicians, and haemolysis should be aggressively assessed. In cases of biological confirmation of haemolysis, it should be mandatory to analyse peripheral blood smears for anomalies that are orientated with a G6PD deficiency diagnosis, such as hemi-ghost cells. Diagnosis of G6PD deficiency requires confirmatory tests, usually based on a measurement of G6PD activity in red cells. In the context of acute haemolysis, reticulocytosis, or following red blood cell transfusion, G6PD activity level may provide false-negative results. In these situations, G6PD measurement should be repeated 3 months following the acute haemolytic crisis. Alternatively, testing G6PD activity in a store sample taken before the beginning of the haemolytic crisis is also an option. When suspecting G6PD haemolytic crisis, inciting agents should be withdrawn. In hypoxic patients infected with COVID-19 infection, red blood cell transfusion should be offered to anaemic patients to avoid worsening hypoxia.

In conclusion, COVID-19 infection can trigger severe acute haemolytic crisis in G6PD-deficient patients, and hydroxychloroquine can worsen this condition. Worldwide transmission of SARS-CoV-2, especially in countries with high prevalence of G6PD deficiency, should alert physicians to this possible correlation.

ORCID

Yan Beauverd  <https://orcid.org/0000-0002-7971-4326>

REFERENCES

1. Cappellini MD, Fiorelli G. Glucose-6-phosphate dehydrogenase deficiency. *Lancet*. 2008;371(9606):64-74.
2. Mahase E. Covid-19: six million doses of hydroxychloroquine donated to US despite lack of evidence. *BMJ*. 2020;23(368):m1166.
3. Yao X, Ye F, Zhang M, et al. Vitro antiviral activity and projection of optimized dosing design of hydroxychloroquine for the treatment of severe acute respiratory syndrome coronavirus 2 (SARS-CoV-2). *Clin Infect Dis*. 2020.
4. Gautret P, Lagier J-C, Parola P, et al. Hydroxychloroquine and azithromycin as a treatment of COVID-19: results of an open-label non-randomized clinical trial. *Int J Antimicrob Agents*. 2020;20:105949.
5. Mohammad S, Clowse MEB, Eudy AM, Criscione-Schreiber LG. Examination of hydroxychloroquine use and hemolytic anemia in G6PDH-deficient patients. *Arthritis Care Res (Hoboken)*. 2018;70(3):481-485.

How to cite this article: Beauverd Y, Adam Y, Assouline B, Samii K. COVID-19 infection and treatment with hydroxychloroquine cause severe haemolysis crisis in a patient with glucose-6-phosphate dehydrogenase deficiency. *Eur J Haematol*. 2020;105:357-359. <https://doi.org/10.1111/ejh.13432>