




Purely Intramuscular Giant Epidermoid Cyst of the Temporalis Muscle

Dimble Raju¹ Shamshuddin Patel¹ Sayan Das² Prasad Krishnan¹ 

¹Department of Neurosurgery, National Neurosciences Centre, Kolkata, West Bengal, India

²Department of Radiology, Peerless Hospital, Kolkata, West Bengal, India

Asian J Neurosurg 2023;18:690–691.

Address for correspondence Prasad Krishnan, MS, MCh, Department of Neurosurgery, National Neurosciences Centre, 2nd Floor, Peerless Hospital Campus, 360, Panchasayar, Garia 700094, Kolkata, West Bengal, India (e-mail: prasad.krishnan@rediffmail.com).

Introduction

An 18-year-old lady presented with a right temporal region swelling that was progressively increasing over several years duration. There was no history of trauma, and the lesion was nontender, soft, noncompressible, not attached to skin, approximately 10 × 9 cm in size and showed no transillumination. The skin over the swelling was normal and the lesion became slightly less prominent when the patient clenched her teeth indicating that it was probably below the temporalis fascia. Magnetic resonance imaging (MRI) scans showed a well-demarcated T2 hyperintense and T1 hypointense lesion within the substance of the temporalis muscle (→Fig. 1A–C). The underlying skull was normal, and the lesion had no intracranial extension. There was no enhancement on administration of contrast. There was diffusion restriction of the lesion on diffusion-weighted imaging (DWI) sequences (→Fig. 1D).

The patient underwent excision of the lesion under general anesthesia. Intraoperatively the lesion was within the substance of the thinned out right temporalis muscle and was accessed after opening the temporalis fascia (→Fig. 1E). It had a firm capsule that was opened and cheesy toothpaste like material and strands of hair were removed piecemeal from inside the lesion (→Fig. 1F). The cyst wall was then easily separated off the muscle fibers and total removal was achieved with closure of the temporalis fascia (→Fig. 1G). Histopathology was reported as an epidermoid cyst. Her postoperative course was uneventful.

Discussion

Pure intramuscular epidermoid cysts with no connection to the overlying skin are rare lesions.¹ The two hypotheses for

their origin include either epidermal cells driven inwards by trauma in the distant past or following aberrant implantation of ectoderm during embryogenesis.^{1,2} They enlarge due to slow accumulation of secretions inside them, and the term giant epidermoid cyst is used when the size of the lesion is greater than 5 cm in size.³

A literature review showed purely intramuscular epidermoid cysts, though rare, that have previously been described in the erector spinae,¹ forearm,² and gluteal muscles.⁴ We found no instance prior to this of an epidermoid cyst in the temporalis muscle. The commonest lesions described in the substance of the temporalis muscle are hemangiomas,^{5,6} which are hypo- to isointense to temporalis muscle on MRI on T1 imaging, hyperintense on T2 imaging, show contrast enhancement and may contain hemosiderin, calcification, and areas of thrombosis and fibrosis, none of which were present in our case. We had not paid cognizance to the diffusion restriction on DWI sequences that might have made us consider this diagnosis preoperatively.

Conclusions

Epidermoid cyst purely within the temporalis muscle with no cutaneous connection is a previously unreported entity. As it grows slowly and is painless, it may reach a large size before the patient seeks medical attention. Imaging findings of absence of contrast enhancement and diffusion restriction in DWI sequences on MRI can help clinch this diagnosis preoperatively. As such cysts have no cutaneous connection or punctum, there is no need to remove any skin along with the lesion. Complete excision of the cyst wall is recommended to prevent any recurrence.

article published online
August 31, 2023

DOI <https://doi.org/10.1055/s-0043-1772766>.
ISSN 2248-9614.

© 2023. Asian Congress of Neurological Surgeons. All rights reserved.

This is an open access article published by Thieme under the terms of the Creative Commons Attribution-NonDerivative-NonCommercial-License, permitting copying and reproduction so long as the original work is given appropriate credit. Contents may not be used for commercial purposes, or adapted, remixed, transformed or built upon. (<https://creativecommons.org/licenses/by-nc-nd/4.0/>)

Thieme Medical and Scientific Publishers Pvt. Ltd., A-12, 2nd Floor, Sector 2, Noida-201301 UP, India

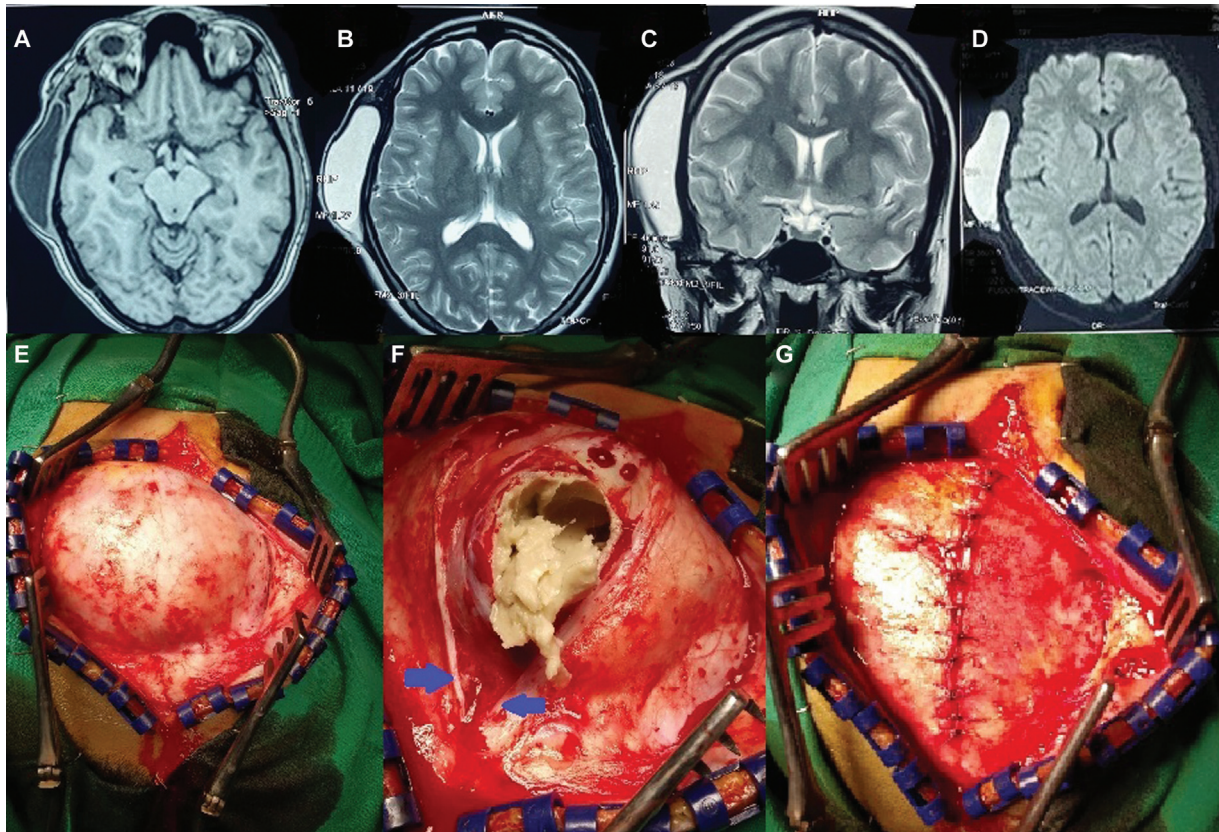


Fig. 1 Magnetic resonance imaging showing an encapsulated well-defined lesion, with no intracranial extension in right temporalis muscle (A). The lesion is hypointense to the muscle on T1 sequences and hyperintense to the muscle on T2 axial (B) and coronal images (C). It shows diffusion restriction on diffusion-weighted imaging sequences (D). Intraoperative images showing (E) lesion to be beneath the temporalis fascia; (F) cheesy material and hair seen after the capsule is opened while piecemeal removal is carried out. The cut edges of the temporalis muscle are shown (blue arrows); and (G) temporalis fascia resutured after complete removal of lesion with capsule.

Informed Consent
Received.

Conflict of Interest
None declared.

References

- 1 Bhosle R, Das S, Sarkar AK, Krishnan P. Bilateral intramuscular epidermal cysts in the erector spinae. *J Neurosci Rural Pract* 2021; 12(04):798–799
- 2 Suito M, Kitazawa T, Tsunekawa K, Shiba M, Ikeda T. Intertendinous epidermoid cyst of the forearm. *Case Reports Plast Surg Hand Surg* 2019;6(01):25–28
- 3 Low SF, Sridharan R, Ngiu CS. Giant epidermal cyst with intramuscular extension: a rare occurrence. *BMJ Case Rep* 2015; bcr2013202534
- 4 Yim Y, Kim NR, Moon SJ. Intramuscular epidermal cyst of the buttock: a case report. *J Korean Soc Radiol* 2018;79: 354–358
- 5 Alqahtani AA, AlQarni AA, Abbas MM, Alkhani AM. Temporal muscle cavernous hemangioma: a case report and literature review. *Cureus* 2022;14(03):e23166
- 6 Bucci T, De Giulio F, Romano A, Insabato L, Califano L. Cavernous haemangioma of the temporalis muscle: case report and review of the literature. *Acta Otorhinolaryngol Ital* 2008;28 (02):83–86