

Malpractice claims and unintentional outcome of tonsil surgery and other standard procedures in otorhinolaryngology

Abstract

Background: Septoplasty, tonsillectomy (with and without adenoidectomy) and cervical lymph node excision are amongst the most common 50 inpatient operations in Germany. Intracapsular tonsillectomies (i.e. tonsillotomies) are increasingly performed. The aim of this study was to evaluate technical traps and pitfalls as well as alleged medical malpractice associated with tonsillectomy (TE), adenoidectomy (AE), tonsillectomy (TT), septoplasty (SP) and cervical lymph node excision (LN).

Methods: A questionnaire was sent to the Regional Medical Conciliation Boards, Medical Services of the Health Insurance Companies (MDK) and Regional Institutes of Forensic Medicine in Germany to collect anonymized cases of complications following TE, TT, AE, LN and SP. The results were discussed in the light of the contemporary medical literature and published trials and verdicts in Germany.

Results: The response rate of our survey was 55.9%. The Institutes of Forensic Medicine contributed nine cases, 49 cases were submitted by the Regional Conciliation Boards and none by MDK. All forensic cases were associated with exsanguinations following tonsillectomy including two children (5 and 8 years of age) and seven adults (aged 20 to 69 years). The fatal post-tonsillectomy hemorrhage (PTH) had occurred 8.7 days on average; four patients experienced the bleeding episode at home (day 5, 8, 9 and 17, respectively). Repeated episodes of bleeding requiring surgical intervention had occurred in 6 patients. Three Conciliation Boards submitted decisions associated with TT (1), AE (4), LN (3), SP (16) and TE (25). Cases with lethal outcome were not registered. Only three of the 49 cases were assessed as surgical malpractice (6.1%) including lesion of the spinal accessory nerve, wrong indication for TE and dental lesion after insertion of the mouth gag. The review of the medico legal literature yielded 71 published verdicts after AE and TE (29), LN (28) and SP (14) of which 37 resulted in compensation of malpractice after LN (16; 57%), TE (10; 37%), SP (8; 57%) and AE (2; 100%). There were 16 cases of PTH amongst 27 trials after TE resulting either in death (5) or apallic syndrome (5). Bleeding complications had occurred on the day of surgery in only 2 patients. 16 trials were based on malpractice claims following SP encompassing lack of informed consent (6), anosmia (4), septal perforation (2), frontobasal injury (2) and dry nose (2). Trials after LN procedures were associated exclusively with a lesion of the spinal accessory nerve (28), including lack of informed consent in 19 cases. 49 cases (69%) were decided for the defendant, 22 (31%) were decided for the plaintiff with monetary compensation in 7 of 29 AE/TE-trials, 9 of 28 LN-trials and 6 of 14 SP-trials. Lack of informed consent was not registered for AE/TE but LN (11) and SP (2).

Conclusion: Complicated cases following TE, TT, ATE, SP and LN are not systematically collected in Germany. It can be assumed, that not every complicated case is published in the medical literature or law journals and therefore not obtainable for scientific research. Alleged medical malpractice is proven for less than 6% before trial stage. Approximately half of all cases result in a plaintiff verdict or settlement at court. Proper documentation of a thorough counselling, examination, indication,

Jochen P. Windfuhr¹

1 Department of
Otorhinolaryngology, Plastic
Head and Neck Surgery,
Kliniken Maria Hilf,
Mönchengladbach, Germany

informed consent and follow-up assists the surgeon in litigation. An adequate complication management of PTH is essential, including instructions for the patients/parents, instructions for the medical staff and readily available surgical instruments. Successful outcome of life-threatening PTH is widely based on a proper airway management in an interdisciplinary approach. Electrosurgical tonsillectomy techniques were repeatedly labeled as a risk factor for bleeding complications following TE. Institutions should analyse the individual PTH rate on a yearly basis. Contradictory expert opinions and verdicts of the courts concerning spinal accessory nerve lesions following LN are due to a lack of a surgical standard.

Keywords: tonsillectomy, tonsillotomy, adenoidectomy, septoplasty, cervical lymph node, malpractice, litigation, complication, negligence, death, fatality

1 Introduction

Septoplasty (SP), tonsillectomy (TE) and cervical lymph node excision (LN) are amongst the most common 50 inpatient surgical procedures in Germany [1] (Table 1). The number of tonsillotomies (TT) has nearly doubled between 2007 (4,659) and 2010 (8,799). In the pediatric population, TE with adenoidectomy (AE) is one of the most common five surgical procedures in girls (12,094) [2] and boys aged 14 years or younger (13,724) [3].

This study analyzes clinical negligence claims following TE, AE, TT, SP and LN and analyzes traps and pitfalls associated with these procedures with a review of the medical literature. Current efforts of the German government to strengthen the patient's legal rights are heterogeneous and mirrored by an update of laws associated with medical malpractice [4]. Regional Conciliation Boards answered to 11,107 patient pleas in the year 2011 of which 7,452 were associated with 14,095 medical failures of the physicians. Amongst the most common were surgical techniques, postoperative care, radiologic diagnostic procedures, history/examination, informed consent, drug therapy, conservative therapy, indication, analyses of blood values and postoperative antibiotics. In 5,165 cases (69.3%) the accusations were settled but admitted in 2,241 cases (30.1%). A lack of informed consent was identified in 46 pleas (6.2%). Hospitals (72.2%) as well as doctors in private institutions were accused (27.8%). Otorhinolaryngology is amongst the most common 10 disciplines affected either in private practices (3.9%) or within a hospital (2.9%) [5] which is comparable with the rate of 2.5%, indicated by the Regional Medical Services of the different health insurance companies (MDK) [6]. According to the Federal Supreme Court, medical malpractice is defined by the negligence of adequate medical care which is not restricted to the individual capabilities of the physician. Physicians are also charged for complications later resulting from secondary medical procedures even if the secondary procedure was incorrectly undertaken. Adequate medical care includes diagnosis, therapy and informed consent based on the contemporary medical knowledge [7]. Patients or their heirs have to prove that health defects resulted from a medical error (burden

of proof). If, by law, the error of the treating physician is to be considered a "gross" medical error, the burden of proof is reversed. In such a case, the treating physician has to prove that his medical treatment was correct. "Gross" is clearly related to the quality of the medical error [8]. A "gross" medical error has not been given at unequivocal finding of a violation of the relevant medical standards, it rather requires next to a clear violation of established rules of medical treatment or medical evidence backed the findings that the doctor made a mistake, which is objectively no longer seems understandable [9]. These include diagnostic and control failures [10], finding survey errors [11] or lack of informed consent before therapeutic measures [12]. Lastly, this is also the responsibility in determining the indication of an operation, which is almost the surgeon [13].

2 Material and methods

A questionnaire was sent in December, 2011, to the Regional Conciliation Boards, MDK and Institutes of Forensic Medicine in Germany to collect anonymized complicated cases following TE, TT, AE, LN and SP. The intent was to detect unusual complications of standard procedure in the field of otorhinolaryngology and to discuss the cases with knowledge obtainable from contemporary medical literature and published trials using search engines like "Juris" or "Rechtssprechungssammlung zur Arzthaftpflicht" (Erich Schmidt Verlag, Berlin) with search terms "Tonsillektomie", "Mandelopoperation", "Mandelentfernung", "Tonsillotomie", "Adenotomie" "Septoplastik", "Nasenscheidewand", "Nasenscheidewandoperation", "Halslymphknoten", "Nervus accessorius", "Chylusfistel" or "Recurrentsparese". Verdicts, dealing with billing questions, deportation procedures, accidents, paranasal sinus surgery or cosmetic surgery were excluded. A Medline Research [14] was used with search terms "septoplasty complications review", "tonsillectomy sequelae review", "tonsillotomy sequelae", "cervical lymph node dissection complications review", "spinal nerve injury lymph node", "iatrogenic injury neck lymph node excision", "internal jugular vein injury neck lymph node ex-

Table 1: Inpatient procedures in German hospitals (2010)

Operation	OPS Code	Total	Male	Female
TE included TT	5-281 5-281.5	92,594 8,798	41,986 5,146	50,602 3,652
ATE	5-282	35,539	17,062	18,476
AE	5-285	37,687	21,830	15,853
SP	5-214	102,916	66,038	36,871
TU	5-215	147,179	90,476	56,695
ID	5-280	4,340	2,580	1,760
LN	5-401	97,988	18,251	79,734
LNE	5-402	12,291	4,079	8,211

TE = Tonsillectomy; AE = Adenoidectomy; ATE = Tonsillectomy /w Adenoidectomy; SP = Septoplasty; TU = Turbinoplasty; ID = incision drainage of a (para)pharyngeal abscess; LN = excision of a single cervical lymph node; LNE = excision of multiple cervical lymph nodes

Source: Sonderauswertung des Statistischen Bundesamts sowie https://www.destatis.de/DE/Publikationen/Thematisch/Gesundheit/Krankenhaeuser/OperationenProzeduren5231401107014?__blob=publicationFile

cision", "chylous fistula neck lymph node excision", "neural injury lymph node excision", "neck node excision complication", "phrenic nerve lymph node excision". Terms such as "Malpractice Claims", "Malpractice Cases", "Closed Claims" or "Clinical Negligence Claims" were used individually with "tonsillectomy", "tonsillotomy", "Septoplasty" or "cervical lymph node".

3 Results

The response rate to the questionnaire was 55.9% including 6 of 16 MDK (37.5%), 20 of 33 Forensic Institutes (61%) and 12 of 19 Conciliation Boards (63.2%). One regional Conciliation Board refused to submit anonymized cases and one regional MDK set unacceptable conditions for the release of anonymized patient data.

A total of nine cases from the Forensic Institutes (autopsy reports) and 49 cases were submitted by the Conciliation Boards. No cases were submitted by the MDK, either for lack of knowledge, lack of digital archiving or inadequate time-consuming research. The lack of digital archiving and accessibility was also the reason why data on at least six Institutes of Forensic Medicine could not be provided. In all nine cases submitted by Forensic Medical Institutes fatal hemorrhagic complications after TE had occurred. Amongst those were two children aged five and eight years and seven adults aged between 20 and 69 years. The lethal bleeding events were experienced between the 4th and 18th postoperative day (mean: 8.7 days, median: 6 days, STD: 5.2 days). In four cases, the bleeding had occurred at home (5th, 8th, 9th, 17th postoperative day). In six cases, the bleeding was preceded by at least one bleeding complication requiring revision.

A total of 49 cases of the Conciliation Boards were submitted by only three institutions (1; 18; 30 cases, respectively). Accusation of medical malpractice had been raised after TT (1), AE (4), LN (3), SP (16) and TE (25). Cases

with lethal outcome were not registered. Errors in medical treatment were not identified in 46 cases, but in one case after LN and twice affirmed after TE. In one LN case (33%) a spinal accessory nerve lesion resulted. Since no abnormal intraoperative characteristics were described, the expert went out of negligence. In one of the two cases after TE (8%) an indication error was identified and in the second case, the tooth decay explained by lack of care when inserting the mouth gag. Miscellaneous allegations were rejected after AE (laryngospasm in the recovery room, postoperative bleeding (2), injury to the Eustachian tube cartilage); LN (spinal nerve injury (2)); SP (saddle nose deformity (2), postoperative bleeding (3), re-deviation (2), septal perforation (5), anosmia, synechia, retracted columella, wrong indication, thrombosis of the cavernous sinus); TE (postoperative Bleeding (14), dysgeusia, dysphagia/dysphonia resulting from soft palate injury, remnants, painful dysphagia (2), convulsion, postemetic soft palate perforation, cracking noise in the temporomandibular joint, facial hypesthesia); and TT (injured tongue).

The review in the search engines yielded 71 published verdicts. Among these there were 29 after AE and TE, 28 after LN and 14 after SP. The verdicts came from the Federal Constitutional Court (1), Federal Courts (3), District Courts (13) and Appellate Courts (54) from the period 1954 to 2011. 27 of the 71 procedures resulted in convictions for medical malpractice by LN (16, 57%), TE (10, 37%), SP (8, 57%) and AE (2, 100%). In one AE-case the surgeon was convicted, in the second case the anesthesiologist. Among the 27 TE cases, 16 were due to bleeding complications, only 2 of which had occurred on the day of surgery. Because of the bleeding complications 5 patients died, 5 kept back a vegetative state. Taste Disorders (3 cases) and miscellaneous (7 cases) were the subject of further legal argument. Details of a single case with a remaining vegetative state were not available. The three plaintiff verdicts were based on neglected postoper-

ative medical care with lack of clear instructions; inadequate management of septic fever; inadequate management of PTH with lack of clear instructions (3); failure in diagnosing septic fever; inadequate surgical trauma requiring reconstructive surgery; PTH resulting in apallic syndrome; inadequate information transfer by the nursing staff; inadequate PTH management; and hyperhydration to compensate blood loss. Defendant verdicts included instable iv-line, PTH (3), dysgeusia (2), dysgeusia with dysosmia, inadequate hospitalization (2), indication (3), lateralized soft palate, and antibiotic therapy. In one case the verdict was returned to the anesthetist for delayed bronchoscopy/tracheotomy to resolve ventilation problems caused by PTH.

The pleas after SP were highly heterogeneous; most were related to a lack of informed consent (6), olfactory dysfunction (4), septal defects (2), skull base injury (2) and dry nose (2). All other process objects were isolated cases. Plaintiff verdicts were based on forgotten gauze; anosmia with inadequate documentation of the surgical procedure resulting in anosmia (2); lack of informed consent in a case with unilateral blindness that resulted in complete blindness after SP; lack of informed consent (3); skull base injury with destruction of the pituitary gland. Defendant verdicts included lack of surgical experience, lack of informed consent for an additional cartilage graft, indication, antibiotic therapy, meningitis, and saddle nose deformity.

All 28 cases related to LN dealt with injury of the spinal accessory nerve. In most cases (19) a lack of informed consent was accused and in all trials a wrong surgical technique was alleged. Neurosurgical re-operations were performed in 6 patients; tuberculosis was detected in 5, toxoplasmosis in one single case. Plaintiff verdicts were based on inadequate surgical experience (2), lack of informed consent (10), inadequate surgical technique (6), and wrong indication including several cases with multiple issues of medical malpractice. Defendant verdicts included indication (6), inadequate surgical technique (6), lack of informed consent (8), including several cases with multiple allegations.

Compensation was in 7 of 29 AE/TE trials awarded (24.1%), the amounts ranged between 500 € and 346,612 € and 12,000 DM and 150,000 DM (7 cases). In two cases, the verdict included pension payments, the monthly amount was 60 € and 500 €. In 9 of 28 LN-trials were the defendants sentenced to compensation payments (32.1%), in only one case was the amount stated in €, the currency in 8 other cases was DM with amounts ranging between 5,000 DM and 12,300 DM. Compensation by the defendant resulted from 6 of 14 SP-trials (42.9%), with a monthly pension payment of 200 € in one case and 500 € in a second one. The amounts ranged from 2,500 € (one case) and 20,000 € (second) and, earlier, from 7,000 DM (two cases) to 100,000 € (one case). Note: compensation in DM currency dated before January 1, 2002, the date when the EURO (€) was introduced as the new currency in several European States, including Germany.

Lack of informed consent was explicitly denied in trials after five TE cases, six LN cases and two SP. A lack of informed consent did not lead to condemnation in AE/TE-trials, but in 11 LN-trials and 2 SP-trials.

4 Discussion

4.1 Tonsillectomy

Bleeding is basically the most important complication of this procedure and therefore deserves an intensive discussion. What a bleeding episode is, must – by law – be evaluated by a doctor. Reliance on assessments of the nursing staff only to give commands such as monitoring, ice packing and re-call in conspicuous courses has therefore led to final conviction with pain and compensation: “The duty to visit his patients of duty cannot escape the doctor, only when serious reasons prevent him and he cares for other equivalent means.”...“it is a safe principle medical profession and thus medical standard that a doctor is in breach of duty if he is satisfied with a remote diagnosis” [15]. To evaluate a bleeding complication may not be delegated to the nursing staff, not even with specialized knowledge. This provides in-itself a technical-medical situation overtaxing [16]. Even the hospital authority is responsible for an adequate medical care of TE patients which excludes employment of inexperienced nurses on night duty. The hospital authority is also made in the duty when it comes to the attending physician to require clear instructions to the nurses in the event of bleeding complications [15]. This illustrates the importance of complication management. If a nurse is unable to carry explicitly granted (documented) doctor’s orders, she is required to report it. If not, this will be seen as culpable misconduct [17]. It is also a gross error of the nurse, if she does not inform the doctor about a bleeding event [18].

Most authors distinguish between primary (<24 h) and secondary (>24 h) bleeding [19]. In contrast, the intensity of a bleeding episode is not uniformly defined. Some authors count even blood-tinged sputum as post-tonsillectomy hemorrhage while others count only episodes that required surgical intervention [20]. What makes things complicated is the fact, that bleeding episodes with spontaneous cessation can precede in unpredictable massive bleeding with a life-threatening character [21], [22], [23]. This may happen at any time, in any patient and, rarely, with a devastating outcome [21], [24]. It has been suggested to analyze the PTH regularly, preferably on a yearly basis [25]. This suggestion is emphasized by the concluding remarks of the prospective Tonsillectomy Study in England in order to find out avoidable causes of the bleeding event [26]. In Germany, only the University Hospitals (33) currently publish the PTH rates ranging between 1.0% to 6.4% [27]. A special analysis of the Federal Statistical Office for the year 2010 identified 7,808 TE and 943 AE procedures requiring surgical intervention under general anesthesia. Based on the total

Table 2: Post-tonsillectomy hemorrhage in the English literature

Alexander [500]	2004	9.2% SB
Alexiou [501]	2011	0.13–0.61
Amir [502]	2012	1.70%
Arnoldner [132]	2008	1.78%
Attner [503]	2009	7.50%
Brigger [504]	2006	9.80%
Burton [190]	2007	0.0–28% PB; 0.0–50% SB
Cardwell [341]	2005	0.39–2.53%
Chiang [505]	1968	0.006%
Dhiwakar [506]	2010	2.50%
Diakos [507]	2011	0.25–0.80%
Evans [508]	2003	3% SB
Guida [509]	1990	1.7% PB
Handler [510]	1986	2.62%
Heidemann [511]	2009	22.7%
Hessén Söderman [512]	2011	1.3% PB
Kristensen [513]	1984	2.80%
Laureyns [514]	2006	2.2%
Marret [515]	2003	2.6–7.3%
Moiniche [516]	2003	0.0–30%
Moralee [517]	1995	0.8% PB
Mösges [518]	2011	4.1%
Mowatt [519]	2006	2.0–18.3%
Ovesen [520]	2012	4.00%
Salonen [521]	2002	8.80%
Sarny [44]	2011	15.0%; RTT 4.6%
Tomkinson [522]	2005	0.60%
Tomkinson [523]	2011	1.5–29.1%
Wagner [524]	1991	7.05%
Windfuhr [35]	2005	1.5%

PB = primary bleeding (< 24 h); SB = secondary bleeding (>24 h); RTT = return to theatre

number of AE/TE procedures, the complication rate is 6.5% for ATE/TE procedures and 2.5% for AE procedures (data for TT not provided). In the English literature, PTH rates up to 22.7% has been reported [28], but the studies are hardly comparable due to different study designs, population sizes, terms, definitions and differences in the follow-up (Table 2). Only few clinics analyze possible causes and rates of PTH, effects of newer surgical instruments or make suggestions for an adequate complication management protocol [29], [30], [31], [32], [33], [34], [35], [36], [37], [38], [39], [40], [41]. For the first time, the Prospective Multicenter Tonsillectomy Study in Austria stratified bleeding events by a sophisticated classification system [42], [43], [44]. It is noteworthy, that bleeding complications are not always treated at the same department where the TE was performed [45]. This has been confirmed by the Sarny for 20% of the patients with PTH [46]. In no case the sole occurrence of PTH was acknowledged as medical malpractice, even in cases with fatal

outcome [47]. For this reason, an investigation was discontinued or dismissed complaints [48], [49]. It can be concluded from the literature, that the more severe the consequences associated with a bleeding complication, the greater the risk of a legal dispute [50], [51]. Critical to the discussion of medical malpractice allegation is proof of adequate complication management, which however in itself cannot provide absolute certainty. Guidelines on the management and prevention of PTH do not exist. Therefore individuals depend on collection of their own experiences or others to release a concept for the prevention and management of this complication. Medical and legal aspects must be considered equally when considering the preoperative, intraoperative and postoperative period.

Table 3: Indication for pediatric tonsillectomy [58]

Criterion	Definition
Frequency of sore throat episodes	7 or more episodes in the preceding year, or 5 or more episodes in each of the preceding 2 y, or 3 or more episodes in each of the preceding 3 y
Clinical features (sore throat plus the presence of one or more qualifies as a counting episode)	temperature >38.3°C, or cervical lymphadenopathy (tender lymph nodes or >2 cm), or tonsillar exudate, or positive culture for group A β -hemolytic streptococcus
Treatment	Antibiotics had been administered in conventional dosage for proved or suspected streptococcal episodes
Documentation	Each episode and its qualifying features had been substantiated by contemporaneous notation in a clinical record, or If not fully documented, subsequent observance by the clinician of 2 episodes of throat infection with patterns of frequency and clinical features consistent with the initial history*

*This statement allows children who meet all other criteria for tonsillectomy except documentation to nonetheless qualify for surgery if the same pattern of reported illness is observed and documented by the clinician in 2 subsequent episodes. Because of this tendency to improve with time, a 12-month-period of observation is usually recommended prior to consideration of tonsillectomy as an intervention [25].

4.1.1 Preoperative period

4.1.1.1 Indication

Because of the possibility of a potentially life-threatening bleeding complication the question comes after a treatment alternative to a special significance [52], [53], [54], [55], [56] (cited [57]). Therefore, the indication has to be individualized. The clear indication criteria in children up to 15 years of age have been established in 1984 by Paradise [58] and remain unchallenged to date (Table 3). Under these circumstances, the benefit of surgery is clearly superior and significantly compared to a conservative treatment of recurrent tonsillitis. In softer criteria the benefits of surgery compared to conservative treatment in children are less significant [59] and even comparable to a wait-and-see-policy [60]. However, this finding emphasizes the need for an individualized indication rather than to state, that there is no more sense to perform TE [61]. This is supported by the benefit of surgery with various indications as explained by Luckhaupt [62] and Deitmer [61]. It is noteworthy to mention, that patients are often not treated exclusively by ENT specialists but also, or instead, by family physicians or pediatricians. These specialties may have different definition of an episode of tonsillitis and therefore may have different indication criteria for TE. The Problem is aggravated by unreliable information of the patients who are treated or should be. Therefore, the current guideline of the ENT specialists of the USA still rely upon the criteria set by Paradise in 1984. This guideline, however, mentions also individual criteria that might justify surgery, such as allergic reactions to multiple antibiotics, PFAPA syndrome (periodic fever, aphtosis, pharyngitis, cervical lymphoma)

or previous peritonsillar abscess. TE to resolve sleep-related disorders are a different indication based on very strict criteria after detailed counseling [25]. The current guideline of the Scottish ENT-Society also relies upon the strict Paradise indications for TE [63]. According to the guideline of the Italian ENT-Society, TE is indicated after a waiting period of 6 months that followed treatment of at least 5 episodes of tonsillitis within one year [64]. This statement is supported by the American ENT Society: "because of this tendency to improve with time, a 12-month period of observation is usually recommended prior to consideration of tonsillectomy as an intervention" [25].

Unlike in children comparable studies with adult patients in terms of follow-up, population size do not exist. Alho, however, recruited 70 adults with documented recurrent episodes of pharyngitis due to group A streptococcus, having had three three or more episodes of pharyngitis in six months or four in 12 months. Participants were allocated by replacement allocation to either TE or waiting list (control) and followed for 90 days. Superior results were obtained after TE [65], [66]. This conclusion is supported by the findings in retrospective [67], [68], [69], [70], [71], [72], [73], [74], [75], [76], [77], [78], [79], [80] and prospective [81], [82], [83], [84] studies proving the positive effect on the quality of life after TE which was questioned by Stafford [85]. However, the quality of the studies is not comparable to the aforementioned studies of Paradise. Stafford, for instance, concluded that the effect of TE is not superior to conservative treatment but he followed only 40 patients in total [85]. In contrast to this statement a more recent study concluded, that the quality of life significantly improved after TE [86]. Comparable studies are currently undertaken in the UK as an

answer to the restrictions of the National Health System (NHS) [87]. The NHS has stated for TE cases, that a reimbursement can be expected only for malignancy, a second event of a peritonsillar abscess or acute upper airway obstruction. Indications such as recurrent tonsillitis and upper airway obstruction require approval and are based on the certificates of the family physicians, records of the height development, findings in somnography and even certificates of employers/schools. Payments to resolve snoring, either by TE or tongue base resection, SP are rejected unchecked, because they are classified as "procedures of limited clinical value" [88].

It is noteworthy, that TE is not mentioned as a routine measure of treatment to resolve infectious mononucleosis [89]. Hitherto, no evidence of a positive impact was proven by studies published in journals with a peer-review. Likewise, a surgical procedure to cure a systematic disease initiated by a virus appears questionable from a scientific point of view. This statement was supported by representatives of the American and German Society of Virology. Anecdotal reports in the past could only demonstrate, that the incidence of infectious mononucleosis was related to the presence of tonsils [90], [91]. It can be concluded, that TE in patients with infectious mononucleosis is only indicated to resolve upper airway obstruction or severe dysphagia [92], [93], [94], [95], which is mirrored by statements in trials [96]. Most commonly, the disease heals spontaneously with cortisone having a positive effect on the upper airway obstruction [97]. Sonography is mandatory to assess the risk of splenic rupture. A different approach is indicated in patients presenting with peritonsillar abscess and is indicated in cases not responding to previous incision drainage or needle aspiration, a history of recurrent episodes of tonsillitis, an age less than 40 years or complications related to the abscess [98], [99]. Rosenfeld and Green reported a changing trend concerning the indication for TE with hyperplasia prevailing tonsillitis [100]. This finding supported the idea of TT replacing TE, occasionally with a certain age limit [101], [102], [103], [104], [105], [106], [107], [108]. Evidence has been given that TT is capable to resolve tonsillitis in children and adolescents by Hultcrantz and Ericsson [84], [109], [110], [111]. Age restrictions as well as assumed advantages of certain surgical instrument as demanded in various contracts are not scientifically supported [112]. Despite the increasing acceptance of TT to resolve upper airway obstruction (with or without sleep-related breathing disorder) [29], [101], [102], [103], [104], [107], [108], [113], differences in postoperative morbidity in contrast to TE were not evident in other studies. Moreover, patients run at risk to experience tonsillar regrowth after TT [114].

AE is most commonly indicated to resolve upper airway obstruction and/or infections as well as chronic serous otitis media [62]. AE is capable to resolve hearing impairment resulting from the effusion but not the number of acute otitis episodes [115]. A contemporary study questions the benefit of AE on upper airway infection

based on results obtained in a prospective study on 111 children aged 6 years and younger [116].

In cases with unintentional outcome, indication for surgery is doubted. If this is indeed the case, it is clear the errors in treatment, which corresponds to a gross medical error. Individual indication of adequate documentation is the only way to avoid this error.

4.1.1.2 Informed consent

As early as 1974, Becker has been with the meaning and practice of an adequate informed consent [117]. The Federal Supreme Court differentiated as to the extent of the informed consent, which the doctors have to give without the demand of the patient, and the attention to the demand of the patient. Limitations to essentials are accepted, if the patient has no further demands, but should explain all complications and questions, that may arise in every patient. Further explanations are required on demand. The Federal Supreme Court explicitly denied, that the extent of the informed consent is related to a certain complication rate. Furthermore, the complication rate has not to be quoted in numbers, percentages, not even in more difficult anatomical circumstances [118]. The complication rate is much more a hint to explain a certain complication related to the surgical procedure. The less likely a complication occurs, the more decisive is the presumable impact on life of it [119], [120]. Therefore, under certain conditions, the informed consent has to include complications occurring with a rate of 0.1% which was verified for a case of blindness following ethmoidectomy. The trivialization of serious risks in a written protocol of the informed consent would not be offset by the fact that the patients are given the opportunity to ask the doctor if something was not understood, or he wants to know the details. Accordingly, the medical intervention is only legal if it is covered by the consent of the patient. But in order to comply effectively, the patient must know exactly what he is giving his consent, so they have knowledge of all the relevant circumstances of the engagement. This includes the true rare but serious complications. The judgment can be transferred also to other surgical procedures and complications, like exsanguinations following TE. Therefore commercial informed consent sheets are inadequate, if they do not list this particular complication [121]. The importance of the written protocol of the informed consent becomes clear when plaintiffs claim not to have been informed about the possible complications, which then proves by presenting the document to be untrue [15], [118], [122], [123], [124], [125], [126], [127], [128], [129]. In interdisciplinary surgical indication (here: LN with subsequent lesion of the spinal accessory nerve), the surgeon should never trust that the other discipline does it for him. It is his duty to inform the patient properly and to take care for an adequate documentation [130].

Bleeding patients (especially children) should not be transported on privately organized car to the hospital, but by ambulance [131]. This might have been rescued one

Table 4: Checklist tonsillectomy, tonsillotomy, adenoidectomy

1.	bleeding (even after weeks), exsanguination, death
2.	revision surgery, ligation of the branches of the external carotid artery/blood transfusion (transmission of viral diseases)
3.	aspiration of blood
4.	injury of the temporomandibular joint, lips, tongue, teeth, uvula
5.	revision surgery due to tonsil remnants
6.	dysphonia
7.	injury of the soft palate (rhinolalia, nasal regurgitation)
8.	injury of the hypoglossal, glossopharyngeal, vagal nerve resulting in transient or permanent dysphagia, dysgeusia
9.	purulent neck infection
10.	internal jugular vein thrombosis
11.	prolonged wound healing
12.	emphysema, mediastinitis
13.	Grisel's syndrome
14.	adenoidectomy: injury of the cartilage of the Eustachian tube

published case with lethal outcome [22]. This statement is in line with findings of Deitmer [30] who registered more critical situations in patients that were privately transported to the hospital instead of calling for professional medical help. This finding is emphasized by the fact, that secondary bleeding might occur as late as two weeks after TE [30], [132], which has to be explained to the patients or parents in full detail prior to surgery. The patients or parents must receive clear instructions for behavioral measures in case of a bleeding event along the postoperative course. This aspect was addressed in detail by the Joint Recommendation of the Austrian Societies of Oto-Rhino-Laryngology, Head and Neck Surgery and Child and Adolescent Medicine with a proposal to "Response to hemorrhage after tonsillectomy": maintain adequate airway, nothing to eat and drink, transport to hospital for emergency rescue call, avoid own transport whenever possible. On a separate document to be signed, it must be discussed in the informed consent discussion and documented what ENT Department is closest to the place the patient/child lives [131]. This suggestion is supported by the finding, that 19 of 31 cases with fatal outcome following TE had occurred at home, despite inpatient observation for several days [133]. AE is rarely followed by bleeding and fatalities are extremely rare which explains the paucity of literature related to this subject [134], [135], [136], [137], [138]. Fatalities following TT have not yet been published and are not to be expected, as long as the dissection is properly performed. A postoperative edema of the oropharyngeal mucosa might jeopardize adequate breathing (K. Hörmann, personal communication) which justifies administration of cortisone. A comprehensive checklist for the informed consent discussion is especially helpful for inexperienced fellows (Table 4). It is mandatory to inform the patients or parents about the risk of dental injuries and injuries to the temporomandibular joint prior to AE, TT or TE.

4.1.1.3 Prerequisites

Identification of risk factors for PTH in larger patient populations by means of retrospective studies [139], like age, gender and indication for surgery, does not necessarily result in improvement of clinical procedures. This statement is obviously different in regard to the choice of surgical techniques. It appears, as if the application of electrosurgical means has a consequences for the overall incidence of PTH and much more for their time occurrence [31]. If electrosurgical instruments are avoided, it seems reliable that three of four bleeding events occur on the day of surgery and then promptly within the first four postoperative hours [139]. If the interventions are completed in the morning, PTH is therefore likely to occur at a time with full staff available during regular hours. Moreover, the decreased incidence of secondary PTH supports standards for dismissal policy of hospital care. Since secondary PTH peaks at a time five to six days after surgery it is advisable not to perform tonsillectomy on Mondays or Tuesdays since the complication is likely to occur during the weekend with a reduced medical care in the hospitals or private practices. It is a duty of larger departments to treat serious episodes of PTH by rare means like ligation of branches of the external carotid artery, blood transfusions, administration of coagulation factors or tracheotomy. The length of inpatient observation is still a matter of debate [132]. Surgical techniques and the quality of medical care at home are factors to be considered. An inpatient observation for five days appears wise, when secondary PTH had required surgical revision under general anesthesia. However, inpatient observation is not capable to prevent lethal outcome [133], [140], which is supported by the answers of the Forensic Institutes to our questionnaire. It is noteworthy to emphasize, that repeated episodes of PTH (with or without spontaneous cessation) are a warning sign for an excessive bleeding event [23], [24], [141]. The time of dismissal from inpatient observation does not correlate with the

onset of bleeding [142]. The court proceedings and cases reported by the Medical Conciliation Boards to make clear that the professionalism of complication management is crucial for the legal review. This statement is valid for public departments as well as private institutions. Medical standard procedures may help to treat serious PTH with success. Unfortunately, this is not guaranteed for any patient and therefore fateful. Blood loss and particularly aspiration requires an immediate and adequate airway management. Medical assessment and determination of at least two of the four parameters (clotting time, bleeding time, platelet count or prothrombin time) in case of a conspicuous history is mandatory. Measurement of body temperature and heart rate to exclude sepsis is also indispensable. Oozing requires an hourly wound inspection and blood values should be monitored when vomiting of blood occurs. Blood count, INR and PTT, as well as installation of an iv-line are indispensable and fundamental measures of complication management.

4.1.1.4 Coagulation disorders

Unidentified coagulation disorders are an uncommon reason for PTH [33], [143], and therefore evaluation of a bleeding history is nowadays recommended instead of determination of coagulation values [144], [145], [146], [147], [148], [149], [150], [151], [152], [153], [154], [155]. However, if the clinical findings are suspicious for a coagulation disorder or anemia, exclusion is only possible by taking blood samples.

4.1.2 Intraoperative period

There are several surgical techniques currently in use, but the superiority of one over another has not been clearly demonstrated, including powered instruments (not subject of this review). It appears wise to use the microscope instead of a head lamp, since visualization of the delicate structures is improved, particularly for surgeons in training [156], [157]. Injury to the cartilage of the Eustachian tube or aberrant arteries can be avoided by curettage of the adenoid tissue along the median line and not lateral to the pharynx. Fatal injuries of the internal carotid artery resulted from using a sharp forceps to remove adenoid remnants [133], [136] and are therefore not recommended.

In most cases, a temporary packing of the nasopharynx is sufficient enough to treat intraoperative oozing. Serious bleeding may require a tight packing of the pharynx and cervical revision of the greater arteries or bronchoscopy if the situation is suspicious for blood aspiration. In most cases, adenoid remnants are the source of bleeding [158]. The surgical instruments for tonsil dissection and intraoperative hemostasis vary according to the surgeon's preference. In addition to cold steel instruments (scissors, snare, raspator) there exists a great number of electro-surgical techniques. Each method is associated with advantages and disadvantages. Serious episodes of PTH seem to be related to suture ligation techniques according to

some studies [31], [35] or case reports [159]. However, this statement is not supported by a separate study of 6,400 patients [132] and the findings of Günzel in his study [29]. It can be concluded, that there exists no compelling relationship between suture ligation techniques and serious PTH complications. However, it appears noteworthy to emphasize, that careful medialization of the soft tissues with a forceps prior to insertion of the needle is mandatory to avoid injury to greater vessels running close to the tonsil fossa [94]. This statement is particularly supported by reports of aberrant courses of the internal carotid artery [160], [161], [162], [163], [164], [165], [166], [167], [168], [169], since injuries are followed by devastating outcomes [121], [170]. It should be noted that these anomalies do occur in the oropharynx and the nasopharynx [158], a finding that has been described in detail by Stupka [171]. Only few cases have been described [172], [173], [174], and contemporary studies are rare (Figure 1), although Demme's description dates back to 1901 [175]. It remains unclear, whether or not this vascular anomaly existed in one trial [176] or published case [133]. An aberrant course of the ascending pharyngeal artery resulted in a delayed bleeding complication following AE [137].

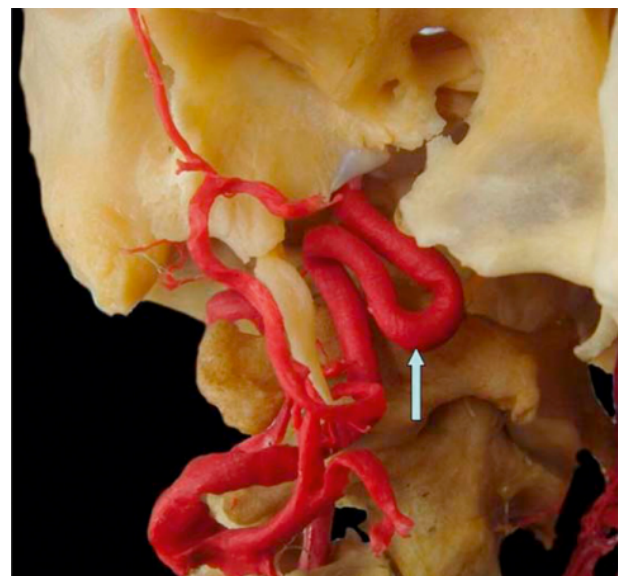


Figure 1: Kinking of the internal carotid artery at the level of the nasopharynx. Right internal carotid artery with ventral protrusion (arrow).

Courtesy of Professor Andreas Prescher; RWTH Aachen, Germany.

Electrosurgical means for tonsil dissection and/or hemostasis is obviously associated with a greater risk of PTH in general [177], [178], [179], a higher rate of secondary bleeding and greater chronological variety [29], [30], [31]. Bleeding complications are therefore likely to occur outside the hospital, which is considered not to be life-threatening [31], but may be so [21]. It appears likely, that the risk of a serious bleeding event is related to the necrotic zone of the wounds resulting from the applied electric energy. It is assumed that enzymes of the saliva and bacterial superinfection are contributing factors for

digestion of the soft tissues and capable to expose greater arteries [180], the hyoid bone or larynx [47]. This hypothesis is supported by findings of a significant relationship between postoperative pain and bipolar electric energy [181], [182]. Comparable findings have been reported for Grisel's syndrome, which is more likely to occur, when monopolar instead of bipolar means are used to achieve hemostasis during AE procedures [183]. Pinder stated in his meta-analysis that "there are insufficient data to show that one method of tonsillectomy is superior. There is evidence that pain may be greater after monopolar dissection. Large, well designed randomized controlled trials are necessary to determine the optimum method for tonsillectomy" [184]. However, it should be noted, that current guideline mention electrosurgical means as a significant risk factor for PTH [185], [186], [187], [188], although this is denied by some authors [189], [190], [191], [192]. However, a survey in Germany [179] and Austria [44] confirmed the conclusions of the National Prospective Tonsillectomy Audit: electrosurgery is a risk factor for PTH. Interestingly, the National Prospective Tonsillectomy Audit recommended that "all trainee surgeons should become competent in cold steel dissection and hemostasis using ties before learning other techniques in tonsillectomy".

4.1.2.1 Local infiltration

While some authors recommend intraoperative infiltration of local anesthetics to relieve postoperative pain [193], [194], [195], others could not identify any benefit for the patient [196], [197], [198]. The rate of PTH significantly increases when TE is performed under local instead of general anesthesia [39]. However, bleeding complication may not compellingly occur, but other rare complications have to be considered whenever local anesthetics are infiltrated. These complications encompass deep cervical abscess [199], myocard ischemia [200], circulatory failure [201], lung edema/bulbar paralysis [202], upper airway obstruction [203], temporal glossopharyngeal lesion [204], temporal bilateral vocal cord paralysis [205], temporal facial nerve paralysis [206], brain stem stroke [207], congestive heart failure with lung edema [208], local wound infection und death [209]. Cranial nerve dysfunction resulted in transient or permanent blindness [210], [211], [212], [213], facial nerve paralysis [214], [215], [216], [217], [218], [219], [220], vocal cord dysfunction [205], [221], [222], [223], [224], [225] or lesion of the sympathetic chain [222], [226], [227], [228], [229], [230], [231], [232], [233]. While infections may result from bacterial spreading from insertion of the needle, cranial nerve dysfunction may result from a spasm of the vasa vasorum induced by a high content of adrenalin, which is supported by data from Bolliger [234].

4.1.2.2 Histology

Williams concluded that "microscopic examination of all routine tonsils and adenoids for individuals 21 years or

younger is not indicated". This statement is supported by an analysis of 4,070 specimen, of whom only three identified a malignant disease that was already apparent by the clinical findings [235]. His findings are comparable to the analysis in a pediatric population of Dohar [236]. To date, a national guideline for histological examination of adenoids and tonsils does not exist [237], although the cost-benefit ratio of routine histology appears questionable [238], [239], [240], [241], [242].

4.1.2.3 Dexamethasone

Czarnetzki concluded after his study in a pediatric patient population that "dexamethasone decreased the risk of PONV dose dependently but was associated with an increased risk of postoperative bleeding". Unfortunately, the surgical technique for dissection and hemostasis were not standardized which is a confounding factor of the study. Despite his report, the current guidelines in the USA, Scotland and Italy still recommend the administration of dexamethasone to prevent postoperative nausea and vomiting (PONV) [25], [63], [64].

4.1.2.4 Forgotten gauze, broken needle

Broken surgical needles may be a challenge for the surgeon and sometimes require radiological diagnostic procedures [243], [244]. Therefore, the surgical needles should be of adequate size and always guided with needle holders or forceps. A thread sutured to the packing will prevent to forget the packing in the nasopharynx. Counting of a standardized number of swabs is recommended to be included in surgical safety checklists as suggested by the WHO [245].

4.1.3 Postoperative period

4.1.3.1 General remarks

Medical care in the postoperative period is focused on wound inspection but should also include the evaluation of the patient's general conditions in terms of body temperature and heart rate. These simple measures help to diagnose septicemia early which requires an adequate management protocol. When septic fever has been confirmed by blood cultures, increased blood sedimentation rate, suspicious blood cell count and increased urinary waste products an antibiotic therapy is immediately indicated. According to current verdicts, only the surgeon is responsible for the diagnosis and management of septicemia, whether working in a general or private institution [13]. The hospital authority is authorized to demand the surgeon for clear instructions and the nursing staff is committed to follow these instructions [246].

4.1.3.2 PTH

Bleeding following TE is acknowledged as a typical complication of this procedure and therefore not a failure of the surgeon by itself [247]. The length of inpatient obser-

vation has no impact on its occurrence [142]. Repeated episodes of PTH with spontaneous cessation can erroneously be assessed as harmless. This may be applicable to an unknown amount of patients. However, several reports in the literature indicate, that repeated episodes of PTH with spontaneous cessation can be a warning sign for an imminent excessive bleeding event [21], [23]. The risk to experience a serious bleeding episode doubles when the patient had experienced a bleeding event before [43], [44].

It appears wise to use metal blades for the wound inspection, since they do not bend. This helps to expose the lower poles of the wounds where coagula or fresh blood may come into view. An adequate documentation including the side of the abnormality is highly recommended to facilitate the assessment of eventful courses. Oozing may erroneously be assessed as harmless but should indicate at least a red blood cell count. This statement is particularly applicable for patients with blood vomiting. Blood loss and aspiration of blood jeopardizes patients in the early postoperative period in the recovery room [17], [248]. The assessment of postoperative bleeding complications has to be done by the surgeon or an associated physician to indicate adequate measure like hourly wound inspection, installation of an iv-line, blood cell count, determination of coagulation values and blood group on an individual basis [94]. The individual evaluation by the surgeon or an associated physician is not transferrable to the nursing staff or inexperienced physicians [249]. Installation of an adequate iv-line can be life-saving in case of a massive bleeding episode to facilitate immediate volume substitution and blood transfusion, if required. It appears wise to determine the patient's blood group and to prepare erythrocyte concentrates, when hemoglobin values are less than 10 g/100 ml. Coagula should be removed with great care, since an excessive bleeding with cardiovascular failure may follow [141]. Successful management of life-threatening PTH is widely based on an interdisciplinary approach including an adequate airway management to prevent hypoxemia [250]. Technical helps, like an alarm button on the wards, the ambulances and a clear management protocol are prerequisite for an immediate intervention.

Since transoral intubation is complicated by the bleeding [251] a simple rigid suction instrument is lifesaving in such situations. If transoral intubation fails repeatedly, immediate tracheotomy should be performed to establish safe airways. Therefore, a rigid suction and instruments for tracheotomy should be readily available. Transoral compression of the bleeding vessel with the index finger or a clamped swab is the method of choice to control the situation outside the OR or the ward. A rigid bronchoscopy is mandatory since it facilitates removal of aspirated blood or coagula which has been emphasized by several authors [117], [140], [252]. A quick patient transportation is essential for a successful outcome and should be supported by privileged elevator systems. Measures to achieve hemostasis are determined by the history, site and intensity

of bleeding. If transoral methods fail to control excessive bleeding, a ligature of all branches of the external carotid artery remains the method of choice [141]. Suction of gastric contents helps to assess the amount of blood, swallowed by the patient. According to expert opinion oozing mandates an hourly wound inspection with a spatula and examination light (case 27). Bilateral oozing not responding to transoral measures is suspicious for a coagulation disorder and may require a packing of the pharynx and detailed blood analysis. It appears wise, not to dismiss patients with visible coagula.

Hemorrhage following AE is uncommon, and most likely derives from remnants of adenoid tissue. Therefore, inspection of the nasopharynx and curettage under visual control is indicated. Local infections are treated with antibiotics, but suppuration is highly suspicious for a forgotten packing. Injury of the Eustachian tube may respond to nose drops, Valsalva-manuever and cortisone. Nasopharyngeal stenosis indicates administration of cortisone and in some cases reconstructive surgery. Grisel's-syndrome mandates antibiotic therapy [158].

4.1.3.3 Pseudoaneurysm

Pseudoaneurysms should be considered if repeated episodes of copious bleeding with spontaneous cessation are reported. If the situation is not life-threatening, immediate arteriography is the method of choice to identify the bleeding source with simultaneous embolization. Life-threatening situation mandate an immediate surgical treatment [253], [254], [255], [256], [257], [258], [259], [260], [261], [262], [263], [264], [265], [266], [267], [268], [269], [270].

4.1.3.4 Blood transfusion

It has been stated in the "Querschnitts-Leitlinien zur Therapie mit Blutkomponenten und Plasmaderivaten" of the German Medical Association that hemoglobin concentration of about 6 g/100 ml or a hematocrit of 18% is sufficient to maintain adequate oxygenation [271]. However, volume substitution has to be considered when hemoglobin values are evaluated [272].

4.1.3.5 Neural lesions

Taste disorders following TE were reported as case reports [273], [274], [275], [276], [277], [278], [279], [280], [281], [282], [283], [284], [285], [286], [287], [288], [289], [290], [291], [292] or subject of studies [234], [293], [294], [295], [296], [297], [298], [299], [300], [301], [302], [303], [304], [305], [306]. Depending on the population size studied and follow-up the rate varies between 0% [293] and 25.7% [234]. Three years after surgery, dysgeusia was identified in 1% of the patients [307]. In most patients, the phenomenon is transient [304]. Taste disorders may be accompanied by dysphagia [275], [280], [281], [282], [285], [287], hypesthesia [234], [273], [276], [278], [285], [289] or pain [234],

Table 5: Unusual complications following tonsillectomy, tonsillotomy and adenoidectomy

1.	death [24, 35, 51, 134, 140, 179, 209, 525–533]
2.	emphysema [216, 534–558]
3.	hematoma of the mouth floor [559]
4.	Lemierre's syndrome [320, 560]
5.	Grisel's syndrome [183, 322–329, 552, 561–563]
6.	burns [322, 350, 351, 564–566]
7.	stenosis of the nasopharynx [567–571]
8.	necrotizing fasciitis [552, 572, 573]
9.	mediastinitis [333]
10.	soft palate perforation [574]
11.	meningitis [575, 576]
12.	bacteremia [575, 577–584]
13.	hyponatremia [526, 527, 585, 586]
14.	temporomandibular joint dysfunction [587, 588]
15.	tooth aspiration [589]
16.	forgotten swab [590]

[286], [289], [295]. Bicknell [277], Tomita [300] and Tomofuji [294] used oral zinc therapy to treat dysgeusia which has been successful in another patient even several years after surgery [308]. Several etiological factors have been considered such as an ossification of the stylohyoid ligament [280], iatrogenic nerve lesion [274], [276], [284], [288], [294], [295], [296], local infection [281], [287], [297], content of adrenalin in local anesthetics [234], psychological disorders [281], [286] or idiopathic [273], [275], [278], [279], [285], [287], [298], [299], [301]. Permanent dysgeusia may become clinically apparent and may result in litigations. Trials in Germany resulted in dismissal of surgeons as defendants in all cases [309], the plaintiffs were not successful (Table 2). It is *res judicata*, that lesion of the lingual and glossopharyngeal nerve is not part of the informed consent, even in cases of revision surgery [121].

4.1.3.6 Fatalities

Hermann stated that bleeding episodes following TT occur predominantly 12–48 hours postoperatively, resulting in death due to exsanguinations and/or aspiration of blood [252]. His admonition, that fatalities are rarely reported in the literature is worth to be repeated. Two cases with lethal bleeding following Coblation-TE occurred in Sweden. One child was scheduled for TT, but autopsy identified the wound outside the capsule. All fatalities occurred 3 and 5 days after surgery, respectively. Repeated episodes of bleeding with spontaneous cessation had occurred in the children [310]. Three cases with lethal outcome following TT had occurred in Germany, typically as secondary hemorrhage. Coblation technique was involved in two cases [311] and CO₂-Laser in one case. In this child, autopsy identified a lesion of the lingual artery, indicating a wrong surgical technique [133]. In the USA, facts about one case with lethal outcome are available one from the mass media [312]. National collections of fatalities fol-

lowing TE, TT or AE do not exist. Population size and time interval of the individual study are confounding factors and explain a varying incidence ranging between one fatality after 7,132 [35], 12,000 [313], 15,996 [314], 16,381 [315] and 170,000 [134] tonsillectomies. Two fatalities were registered in Germany in a survey, including one TT case [179] after 130,000 surgical procedures (Table 1). Becker reported 32 cases with lethal outcome, of whom 20 had occurred in children under 10 years of age [316]. Fatalities may result from primary or secondary embolism, even if performed under local anesthesia [317].

4.1.3.7 Unusual complications

See Table 5. One case with hemiplegic following TE remained unclear [318]. It is assumed, that emphysema formation results from air that is pressed through the mucosa during coughing or vomiting. Emphysema may be associated with spreading of bacteria which becomes life-threatening when the mediastinum is involved [319]. A thrombosis of the internal jugular vein is extremely rare and may result from dehydration, intravascular turbulences and/or simultaneous infection, altered endothelium and coagulation disorders. The disease is always life-threatening and mandates an interdisciplinary approach [320], [321]. Only one case with a thrombosis of the sagittal sinus has been reported to date [322]. According to Feldmann and Brusis suspension of the inserted mouth gag may damage the cervical spine resulting in a torticollis [121]. This phenomenon has been observed after AE [323], [324], [325], [326], [327] but also after middle ear surgery [328], [329]. In contrast to the finding immediately after surgery, Tschopp reported a delayed Grisel's syndrome resulting from a discitis when monopolar instead of bipolar coagulation was used to achieve hemostasis after AE [330]. Successful treatment consists of immediate administration of antibiotics [323].

Nasopharyngeal stenosis occurs more often after AE than TE. A necrotizing fasciitis following TE is extremely rare and successful treatment widely based on aggressive surgical treatment supported by broad-spectrum antibiotics [331], comparable to cases with [332] and mediastinitis [333].

4.1.3.8 Tonsillar remnants

Kaiser found in 1930 tonsil remnants in 381 of 1,000 children who had undergone TE [334]. This high rate may be explained by the surgical technique at that time. In 1973, Bonding reported a rate of 2.97% [335] and Nielsen in 1981 a rate of 5.4% [336], [337]. According to a specified analysis of the German Statistical Federal Bureau 861 operations to remove tonsil remnants were performed in 2010. The term "tonsillar remnant" suggests a surgical misadventure. However, suturing of the tongue mucosa to the caudal wound edge transposes parts of the lingual tonsil to the former caudal part of the tonsil [338] (cited: [121]). In another trial at court, the case of a 7-year-old was compensated with payment of 4,500 DM since secondary surgery was required to remove a single-sided "tonsil remnant" [339].

4.1.3.9 Analgesics

A regular intake is much more effective than on-demand therapy. It should be considered, that the analgesic effect is limited to four hours. Paracetamol is most commonly given to children [63], [64], other surgeons prefer ibuprofen [25]. Since pain sensation varies interindividually, an individualized analgesic regime is mandatory [340]. Administration of NSAIDs is not associated with an increased hemorrhage rate according to Cardwell [341] and Moiniche [342]. Acetylsalicylic acid, however, is a risk factor for PTH [343]. Antibiotics have no impact on bleeding complications [344]. Negligent postoperative care including problems associated with analgesics were addressed by Stevenson [51] and are discussed later.

4.1.3.10 Medical malpractice in the literature

It can be stated that malpractice claims are very likely in the light of thousands of operations performed yearly. These cases are labeled as "Malpractice Claims", "Malpractice Cases" or "Clinical Negligence Claims" in the medical literature. Concerning tonsillectomy, we identified four scientific papers that were published most recently. Mathew reported of malpractice claims relating to tonsillectomy between 1995 and 2010 as obtainable from the National Health Service Litigation Authority database. There were 34 closed claims, of which 32 (94%) resulted in payment of damages. Postoperative bleeding was the most common injury (10 cases, including 2 fatalities), with delayed recognition and treatment of bleeding alleged in most cases. Nasopharyngeal regurgitation (5) as a result of soft palate fistulas (2) or excessive tissue resection (1) and inadequate informed consent (5) were

the next-commonest cause of a claim. The other injuries claimed included dentoalveolar injury (4), burns (3), tonsillar remnants (3), and temporomandibular joint dysfunction, wrong indication (2), forgotten swab (2), infection (2), and miscellaneous (11) [345]. Burns related to TE are acknowledged as malpractice [346]. According to final judgment of German courts, a lesion of the hypoglossal nerve is not a result of medical malpractice [347] which was differently judged in the USA [345].

Stevenson analyzed data of 178 cases from 1984 through 2010 in a retrospective study at a tertiary medical center of jury verdict reports within the LexisNexis (Dayton, OH) database submitted after tonsillectomy malpractice cases. Postoperative bleeding was the most common complication (60), followed by anoxic events (30) and impaired nerve function resulting in dysgeusia or dysphagia (28), miscellaneous (19), burns (13), medication issues (12) and thermal airway injury (5). 72 Patient died as a result from bleeding (39), anoxia (13), postoperative medication issues (12), intraoperative events (5) and infections (3). Monetary awards were available in 24.7% of reports. Anoxic event was noted to have the highest median award at \$ 3,051,296, followed by postoperative medication at \$ 950,000. The paper emphasizes the value of a proper complication management protocol and adequate documentation, particularly of the individualized informed consent [51]. Surgeons have to be prepared to treat either PTH 2 weeks after surgery [348] or in the early postoperative period in the recovery room [248].

Simonsen obtained data from 154 cases concerning TE, AE and ATE from 16 members of the Physician Insurers Association of America. All claims were either filed or closed between 1985 and 2006 and included burns (28), bleeding (27; in 10 cases resulting in death), informed consent (9), medication issues (9), tonsillar remnants (9) and miscellaneous (70). The group of miscellaneous issues included uvular injuries (6), velopharyngeal insufficiency (2), nasopharyngeal stenosis (1), dysgeusia (4), retained foreign bodies (3; in one patient found four months after AE when the patient presented with sinusitis), broken suture needle left in the tonsillar fossa (1). Complications related to post-operative infection led to six claims including pneumonia, abscess with osteomyelitis of C2, and bacteremia. Three of the six infections resulted in death. Two cases involved aspiration of adenoid tissue. There was one wrong site surgery in which a tonsillectomy, adenoidectomy and bilateral tympanostomy tubes was performed on a seven-year-old female who was scheduled for eye surgery. One miscellaneous case claimed that the fellow or resident was intoxicated [349]. The paper mentioned 4 cases of burns related to a hot mouth gag and emphasizes the need of safety instructions [350], [351], [352]. The authors also emphasize the need of an adequate documentation, particularly of the informed consent as recommended by Mistry and Kelly [353]. Nine errors in medication resulted in death (4) or neurologic sequelae (3). Six of nine patients with

remnants underwent revision surgery. Monroy reported a rate of 0.55% after 13,005 AE procedures [354]. Morris reviewed 69 New York State insurance claims (1985–2007) and 87 national court trials (1979–2007) alleging injury after tonsillectomy. The New York State insurance cases were most commonly discontinued (30) or settled before (29) or at (10) trial. Compensations with a settlement or verdict were made in 48 percent of cases. The severity of injury was discernible in 48 cases. Of these, 25 involved death or major injury; 13 of these 25 cases were compensated. Minor or moderate injury was claimed in 23 cases, 15 of these 23 cases were compensated. The specific types of negligence alleged in the cases that proceeded to national court trials included surgical misadventure (37), negligent postoperative care (28), negligent anesthesia care (15), informed consent (4) and failure to diagnose (3; all of which involved a delayed diagnosis of cancer in adults). The patient's location at the time of the bleeding, respiratory, or medical complication was discernible in 46 cases: 28 (61%) occurred intraoperatively, 5 (13%) occurred in the hospital, and 13 (28%) occurred at home. Of bleeding complications, only one was intraoperative, with the remaining cases occurring at home between postoperative days 0 to 14 (median, postoperative day 5). Focusing on the 38 cases of death/major injury, the cause was identifiable in 36 cases: 25/45 pediatric cases and 11/42 adult cases. The causes were postoperative respiratory complications (13), bleeding (12), intraoperative anesthesia-airway complications (6), intraoperative anesthesia-medication complications (3), intraoperative vasoconstrictor toxicity (1), and postoperative sepsis in an adult who developed septic shock after Quinsy tonsillectomy [355]. Nikoghosyan-Bossen reviewed 480 decisions of the National Board of Patients' Complaints from 1998 through 2008, including 50 tonsillectomy cases. Complaints were filed for velopharyngeal insufficiency (13), pain and pain management (11), bleeding (10), residual or re-occurred tonsillar tissue (6), perforation of the palatal arch (6), dysgeusia (3), hoarseness (3) and a left retained packing in the nasopharynx (2). 10/50 complaints resulted in criticism for either medical error (4), deficient medical recording (5), deficient information (1) or lack of adequate informed consent (1). Seventeen malpractice complaints were filed due to a lethal outcome of a treatment, seven of them after various surgical procedures including one single case of delayed PTH. The authors emphasize the need to mention velopharyngeal insufficiency in the informed consent [356].

4.2 Septoplasty

Several seminar papers concerning SP are obtainable in the archives of the German Society of Oto-Rhino-Laryngology, Head and Neck Surgery [357], [358], [359], [360]. The satisfaction rate following SP varies between 51% and 86% [358], [360], [361], [362], [363], [364]. Nowadays, Cottle's techniques is acknowledged as the

surgical standard and basis for newer developments [365].

4.2.1 Preoperative period

4.2.1.1 Indication

The indication for surgery is widely based on the complaints of the patient in terms of impaired nasal breathing, preferably supported by pathologic findings in rhinomanometry. Other complaints, like nasal hypersecretion question the value of surgical therapy and mandate an individualized informed consent [366]. According to expert opinion, rhinosurgeons are not committed to recommend SP, when cosmetic corrections like hump removal are the indication for surgery and the patient do not complain impaired breathing [367]. Endoscopy, rhinomanometry before and after decongestion and smell tests are recommended before surgery [358]. Acoustic rhinometry, rhinoresistometry and rhinoflowmetry may help to localize the site of deviation, but these procedures are performed in only few institutions [357]. Septal deviations are currently classified with some modifications [368], [369], [370] based on suggestions of Masing [371]. A simultaneous perforation of the tympanic membrane is accepted as indication for SP to resolve the problems associated with the septal deviation [372]. Rettinger suggests fractures of the septum, reconstructive surgery to correct a saddle nose and an impaired approach to the nasal sinuses as a clear indication for SP [373].

4.2.1.2 Informed consent

Infection, abscess, septal defect (resulting in bleeding, pain, audible breathing, crusting, impaired breathing), deformities, dysosmia, failure and rare complications like meningitis, skull base injuries, rhinoliquorrhea, injury to the orbital contents, impaired vision and blindness have to be mentioned in the informed consent [374]. The general remark of a possible functional deficit is not sufficient in the informed consent [375]. However, the unlikely risk of a lethal outcome is not an issue to be discussed with the patient before SP [122]. A checklist supports the safety of the preoperative comprehensive informed consent (Table 6). Care has to be taken, that patients understand the explanations otherwise the physicians may be charged for medical malpractice. The informed consent has to explain the entire surgical concept, including cartilage grafting which was neglected in one case of our study.

4.2.2 Intraoperative period

Hemitransfixion is the standard approach to expose the septum. While it is important to incise the skin rather than the mucosa, the side of the incision not important [357]. Schultz-Coulon recommends a speculum to expose the caudal end of the septum for the skin incision which should be done in a cranial to caudal fashion. Care has

Table 6: Checklist septoplasty

- | | |
|-----|--|
| 1. | vascular injury, postoperative bleeding |
| 2. | re-operation due to surgical failure |
| 3. | lesion of the orbita and orbital contents (blindness, double vision) |
| 4. | injury of the dura, meningitis, liquorrhea |
| 5. | neural lesion resulting in dumbness of the incisor teeth |
| 6. | necrotic dental root, dental discoloration |
| 7. | synechia requiring revision surgery |
| 8. | olfactory dysfunction (permanent) |
| 9. | crusting, smelling superinfected nasal contents, nasal dryness |
| 10. | septal perforation resulting in impaired nasal breathing, audible noise during breathing, bleeding, requiring revision surgery or button |
| 11. | septumhematoma/abscess requiring revision surgery |
| 12. | external nose deformation requiring revision surgery |

to be taken not to incise the cartilage to prevent postoperative scarring and secondary deviation. Leaving periosteum on the anterior nasal spine facilitates to re-fixate the corrected septum. To reduce tension on the mucosa, a floor tunnel is recommended. In case of a vertical deviation, chondrotomy anterior to the deviation prevents tearing of the mucosa and reduces the risk of a septal defect [361]. Aerated middle turbinates as well as hypertrophic turbinates have to be considered in the surgical concept [358], [368]. Submucosal resection of the septum is limited to the central and dorsal part of it, leaving an L-shaped frame intact otherwise a reconstruction of this particular frame is mandatory to prevent visible deformities. Schultz-Coulon recommended to use a microscope for optimal visualization of the delicate structures [361], other authors suggested endoscopes for the same reason [376], [377]. The surgical steps consist of injection of adrenalincontaining local anesthetics, hemitransfixion, incision of the mucoperichondrium 1 to 2 mm dorsal to the caudal end of the septum, undermining of the mucoperichondrium, exposure of the cartilage/bone by tunneling, vertical chondrotomy leaving at least 1 cm of cartilage to the nasal dorsum/caudal end of septum intact, separation of the cartilage from the premaxilla, osteotomy or fracture of the bony septum, resection of the deviated cartilage/bone, re-insertion of the corrected septum material, stability check, fixation of septum splints or transseptal suture fixation, wound closure, packing [373]. Re-insertion of the septum material impedes flaring of the septum [361].

Severe septal deformities can not be corrected properly with this standard septoplasty techniques and require extracorporeal correction after the entire septum was taken out to reconstruct a new septal plate that is re-fixated [378], [379], [380]. If there is a lack of material, fixation of septal remnants to a PDS-foil has been suggested [381], [382], [383], [384]. Less invasive surgical techniques may be useful for limited pathologies [385]. Application of the CO₂-Laser has been suggested [386] but the benefit appears questionable [358], [387].

Vertical septum deviations may require different measures, including excision and re-fixation of a septal plate

from backwards to the caudal end of the septum, anterior nasal spine and columella pocket [388]. Lack of septum structures may require cartilage grafts from the ear [358] or rib [389]. A height of at least 3 cm has to be considered for this procedure [357]. Deviations at the caudal end of the septum may respond to incisions/resections of the cartilage [388] or suturing after horizontal cartilage transection [390]. SP in childhood is justified in case of seriously impaired breathing, hematoma or abscess formation after trauma. Huizing recommends reposition of dislocated structures within 5 days and immediate drainage of the hematoma/abscess. If indicated, cartilage grafts are necessary for septum reconstruction [388]. Growth of nasal cartilage and bone mandates a thorough consideration of the surgical risk and benefit especially at the age between 3 to 5 years and during puberty [358]. Growth zones at various sites have to be spared by the surgeon [388], [391], [392], [393], [394]. Schultz-Coulon recommended sparing of the junction area between the lamina quadrangularis and perpendicularis [361].

4.2.2.1 Complications

Blindness is an extremely rare complication [374], [395], [396] and most likely caused by unintentional intravascular injection of adrenalin-containing local anesthetics [397]. An injection of at most 5 to 10 ml into the area of the hemitransfixion area has been suggested by Rettinger. In case of an existing single-sided blindness, the possibility of a total blindness resulting from the injection has to be discussed thoroughly with the patient, particularly in case of a questionable indication [398], [399]. It is advisable to refrain from local infiltration of adrenalin-containing anesthetics. In any case of postoperative blindness a thorough clinical and ophthalmological examination and a CT-scan has to be done within 2 hours [400]. Cardiovascular collapse has also been attributed to the injection of adrenalin-containing local anesthetics [401]. Single-sided perforations of the mucosa have to be sutured, if re-inserted septum material may penetrate the perforation as suggested by Baumann [358], Matthias [357] and Schultz-Coulon [361]. Double-sided perfora-

tions should be sutured immediately after interposition of septum material [361], [402]. Rhinoliquorrhea may result after fracturing of the perpendicular plate due to the close connection to the lamina cribrosa [357], [403], [404], which was also reported after reposition of a fractured nasal bone [361]. After removal of the nasal packing a thorough examination of the inner nose and the packing is mandatory to exclude that parts of the packing remain in the nose. This gross negligence may result in a long-term period of headaches, as reported for a patient who finally, after three years, was freed from the packing. The event was assessed as medical malpractice and the responsible surgeon fully charged [405].

4.2.3 Postoperative period

The **infections** rate hardly reaches 3%, and antibiotics as a routine procedure are not indicated in primary SP [357], [374]. However, cases with septum abscess, perichondritis, septic fever, endocarditis, meningitis, brain abscess, thrombosis of the cavernous sinus [406] and toxic-shock-syndrome were reported [121], [374], [406], [407], [408]. According to expert opinion, toxic-shock-syndrome is such a rare complication, that it can be neglected in the preoperative consent [122].

Bleeding complications may occur in 2 to 7% [357], [402], [409] but are mainly associated to simultaneous surgery of the turbinates [374]. Kocak reported one single case with lethal outcome resulting from an injured internal carotid artery after resection of the vomer [410]. There is only one single case obtainable from the literature with a fistula between the internal carotid artery and the cavernous sinus presumably as a result from a *via falsa* dissection [411].

A **hematoma** of the septum mandates immediate surgical drainage to prevent abscess formation [357], [412], [413]. It has been suggested to use fibrin glue and transseptal suture after incision drainage [361]. Abscess formation is also an indication for an immediate incision drainage supported by intravenous administration of antibiotics. In some cases, reconstructive procedures are required [374], [413], the earlier, the better [361].

Synechia may occur in 1 to 7% of cases [374], [414], particularly, if the turbinates were treated simultaneously. Splints, sutured to the septum, prevent synechia formation [404], [415]. Crusting and atrophication of the mucosa is extremely rare [361], [412]. It has been suggested to clean the nose twice a week for 2 to 4 weeks after surgery to prevent synechia formation [372].

Nasal deformities are observed in 5 to 60% after SP. They typically encounter the lower third of the nose, but are not a result of medical malpractice [416]. If they develop early, re-fixation of the dislocated septum cartilage to the anterior nasal spine is indicated within the first 2 to 4 postoperative weeks. If the deformity becomes visible with a delay, cartilage grafts are useful to resolve the problem [358], [361], [406], [414]. Various deformities of the external nose result from either inadequate fixation of the mobilized septum cartilage or an overresection of

the cartilaginous frame. To prevent deformities, Schultz-Coulon recommended starting with bone resection followed by resection of the septal cartilage, especially in cases with septal luxation. Cross-hatching of the septal cartilage is not recommended, since the functional results are unpredictable and the stability jeopardized [361]. Vuyk and Langenhuijsen analyzed pre-and postoperative images of 100 patients. They identified 21 cases with minor changes and one case with a major postoperative deformity. There was no relationship between surgical technique and result [417].

Septal perforations may occur at rate ranging between 1 to 25% [374], [406], [414] and should be treated surgically as early as possible [361]. If they are associated with bleeding, crusting, audible breathing, impaired breathing, headache or enlarge, closure within 6 months is advisable. The distance between the cranial border of the perforation to the nasal dorsum should be greater than the vertical length of the perforation itself. The mucosa should be free of infection when patients are scheduled for revision surgery [374]. It has been stated, that the rate of perforations decrease with surgical experience [413] and its occurrence is not a result of medical malpractice [372]. There is no evidence for the best postoperative care, advantages of nasal splints and packing [357].

Permanent **dysosmia** is reported for less than 1% [418], [419] but may be transient in 2.9% [406] of all procedures. It appears wise to perform smell tests as a routine to be prepared for medical practice claims [374]. Dysosmia has been evaluated as a result from synechia formation and the surgeon not charged for medical malpractice [372]. However, any smell dysfunction has to be included in the informed consent prior to any SP.

Re-dislocation of the septum may result from an untreated crooked nose, overresection of cartilage or inadequate suturing of the septal cartilage to the anterior nasal spine and occur after 1 to 8% of all cases. Constant pressure of the soft tissue envelope impedes nasal form and function with time resulting in a "tension released nose". The basic principle to prevent such results consists of leaving the junction between the lamina perpendicularis and lamina quadrangularis as well as the connection of the septal cartilage with the anterior nasal spine untouched. Finally, a single-sided dissection of the tunnels jeopardizes less the stability of the nose. If the septal cartilage has been severed from its framework, meticulous re-fixation is strongly advised [374].

A lesion of the **incisive nerve** is rare [420], occurs more often in combination with sinus surgery [420] and in most cases is obviously transient [421]. Langraf-Favre, Sykes and Issing reported a combination of devitalized incisor teeth with discoloration after septorhinoplasty (cited [422]).

Foreign body aspiration can be avoided when the nose is packed with a small gauze prior to reinsertion of septum material [361]. It is crucial to knot both safety threads of the packing outside the nose to prevent aspiration of the packing material which resulted in death in two [423]

and four patients [424]. The safety thread is acknowledged as medical standard. According to expert opinion, it is medical malpractice not to use it which is also valid if packing is used to control nasal bleeding [425].

4.3 Cervical lymph node excision

The current Robbins-Classification defines six different regions in the neck [426]. Typical complications associated with neck dissection surgery are obtainable from the survey of Werner [427]. Not all complications may result from LN since neck dissection procedures expose larger areas, frequently on both sides of the neck. Moreover, since lymph node metastases are removed, postoperative sequelae due to oncologic safety reasons are accepted for neck dissection. The more aggressive the plan for surgery is, the more serious are postoperative complications like increased intracranial pressure, impaired vision or vision loss, fracture/osteomyelitis of the clavicle, chylothorax and lymph edema. However, hypertrophic scars may occur after every surgical procedure in the neck resulting in contraction and impaired mobility of the neck [428], [429]. Permanent hypoesthesia, impaired healing or hematoma are other issues to be mentioned in the informed consent [430]. Injury to the greater vessels in the neck may require blood transfusions and result in hemiplegic, exsanguination, brain edema, blindness or thrombosis. Parts of the sympathetic chain, the phrenic nerve as well as the lower cranial nerves are jeopardized by surgical procedures in the neck. A lesion of the Ductus thoracicus may be followed by chylothorax formation and death. Conservative or surgical measures of treatment have to be considered, when vascular, neural or lymphatic sequelae occur [427], [431], [432].

4.3.1 Preoperative period

LN is indicated to clarify the dignity of the suspicious lymph node [432], [433], [434], [435]. Mycobacteria other than the tubercle bacillus sometimes infect humans, especially children. The lungs are the most common site but occasionally, the lymph nodes, bones and joints, skin and wounds are involved. Clinical, radiographic, and microbiologic criteria are equally important and all must be met to make a diagnosis. If the lesion in the neck is suspicious for atypical tuberculosis, swabs from the excised lymph node for microbiological analysis are mandatory. The preferred staining procedure is the fluorochrome method. Specimens should be cultured on both liquid and solid media. Methods of rapid species identification include commercial DNA probes, high-performance liquid chromatography, antibiotic *in vitro* susceptibility testing, DNA sequencing or polymerase chain reaction [436]. Solid lymph nodes with a diameter of more than 15 mm are an accepted indication for LN after thorough blood analyses, ultrasound and clinical examination [435]. The indication to perform CT scans of the neck has to be individualized [432]. LN may be indicated by the ENT-surgeon,

family physician or pediatrician [130], to exclude a malignant disease, sarcoidosis or tuberculosis. According to the current German jurisdiction it is not the duty of the surgeon to prove the indication of other disciplines [437].

4.3.1.1 Informed consent

The extent of the informed consent is related to the extent of the surgical approach and the site of the lesion (Table 7). In the submental region, the skin incision is made along the relaxed skin tension lines (level I A), in the submandibular area more bow-shaped (level I B), straight along the anterior border of the sternocleidomastoid muscle or along the relaxed skin tension lines (level II-V) [432]. It has been suggested to explain neural lesions in the informed consent [95]. Neural lesions after neck dissection procedures may occur with varying rates and involved the spinal accessory nerve (1.68%), ramus marginalis of the facial nerve (1.26%), sympathetic chain (0.56%) and hypoglossal nerve (0.42%) after 442 procedures [438]. Ferencsik identified a lesion of the spinal accessory nerve in 1.55% after 263 operations [439]. Until 1954 no case of spinal accessory nerve injury reached court trial in Germany, but from that day on, surgeons have to include the issue in the informed consent [440]. It is the most common and typical complication associated with LN in the neck [441], [442]. It has been decided by German courts that for the patient's self-determination the clinical consequences of the nerve lesion have to be explained by the surgeon. Characterizing the risk as very low without explanations is not sufficient for the informed consent [443]. The consent is ineffective, if the patient is not informed about the fact, that the surgeon is not experienced with this particular operation. It is allowed that residents in training perform the operation after adequate and repeated procedures with supervision. If this not the case, uninterrupted surveillance by an experienced surgeon is mandatory [444]. If the informed consent is delegated to residents in training, a comprehensive checklist appears useful (Table 8).

4.3.2 Intraoperative period

To prevent postoperative fistula formation, a complete excision of the affected lymph nodes is required if the finding is suspicious for an infection of atypical mycobacteria. It may be difficult for the inexperienced surgeon to distinguish between a lymph node and a Glomus caroticum tumor. Supraclavicular LN may be complicated by injury of greater vessels or pleura and mandate immediate suturing of the injured structure [432]. Dissection of lymph nodes along the greater vessels in the neck is sometimes complicated by the variable relation of the spinal accessory nerve to the internal jugular vein [445]. A comparable variety has been identified for the Ductus lymphaticus dexter and Ductus thoracicus [446]. It has been postulated, that the marginal branch of the facial nerve has to be exposed to prevent its lesion, usually accompanied with ligation of the facial vein [447]. Sparing

Table 7: Cervical lymph node excision – complications

Level [426]	cranial border	caudal border	anterior border	posterior border	Complication
IA IB	Mandibula	Hyoid post.digastric m.	contralateral anterior digastric m. ipsilateral anterior digastrics m.	ipsilateral anterior digastric m. stylohyoid m.	N2,3,6
IIA IIB	skull base	Hyoid	stylohyoid m. N XI, medial	N.XI, medial SCM	N1,2,5,8,9; V1,2,4 N1,2,5,8,9; V1,2,4
III	Hyoid	Cricoid	sternohyoid m., lateral	SCM / cervical plexus	N1,4,5,7,8,9; V1,2,4
IV	Cricoid	Clavicle	sternohyoid m., lateral	SCM / cervical plexus	L1; N4,5,8; V1–4
VA VB	apex SCM / trapezius m. Cricoid	Cricoid Clavicle	SCM, dorsal/cervical plexus	trapezius m., anterior	N1,7,V3 N1,V3
VI	Hyoid	Sternum	common carotid artery	common carotid artery	L1; N5,8; V1–4

Legend:

	Lesion	Effect	how to avoid; therapy
L1	Ductus thoracicus / lymphaticus	cardiorespiratory / metabolic deficiencies	pressure packing; MCT; suture ligation, muscle flap
N1	spinal accessory nerve	shoulder syndrome	visual identification; neural suture
N2	hypoglossal nerve	tongue hypomobility	visual identification; neural suture
N3	lingual nerve	tongue dysesthesia	visual identification; neural suture
N4	phrenic nerve	dyspnea	visual identification; neural suture
N5	vagal nerve	dysphonia, dyspnea	visual identification; neural suture
N6	marginal branch of facial nerve	hanging lower lip	visual identification; neural suture; intraoperative monitoring
N7	Plexus brachialis	arm plegia	spare deep cervical fascia
N8	Truncus sympathicus	Horner's syndrome	dissection not medial to the carotid artery
N9	Glomus caroticum	vasovagal reflex	immediate information of the anesthetist, heart massage
V1	internal jugular vein	bleeding, air embolism	immediate: compression, Trendelenburg position, information of the anesthetist; vascular suture or ligation; eventually air embolism resolved via central venous line in left-sided position
V2	carotid artery	bleeding, hemiplegia, death	vascular suture or ligation
V3	subclavian vein	bleeding, air embolism	immediate: compression, Trendelenburg position, information of the anesthetist; vascular suture or ligation; eventually air embolism resolved via central venous line in left-sided position; eventually removal of the median third of the clavicle
V4	internal jugular vein	thrombosis	do not let dry out the vascular wall; meticulous dissection of the vascular wall

of the phrenic nerve and Ductus thoracicus is accomplished by meticulous dissection of the deep fascia without penetrating it and clamping of the soft tissue prior to transection [448].

4.3.3 Postoperative period

The incidence of a chylous fistula following neck dissection ranges between 1 to 5% (not specified for LN). Surgical radicality, left side and previous irradiation therapy

are acknowledged as risk factors [449]. After diagnosis is established, the amount of fluid production has to be measured on a daily basis accompanied by blood cell count, determination of electrolytes, serum albumin, kidney and liver function and pressure dressing. A chest X-ray is helpful to exclude a chylothorax [427], [432]. A lethal has been reported for few cases [449], [450]. Some authors suggest parenteral feeding, especially when other measures of treatment failed [451], [452], [453], [454], [455], [456], [457]. Most authors suggest conser-

Table 8: Checklist cervical lymph node excision

1.	bleeding, pain, swelling, infection
2.	dyspnea, tracheotomy
3.	neural lesion resulting in transient or permanent impaired and painful shoulder elevation, facial paralysis, tongue dysmobility, dysarthria, hoarseness, dyspnea, disturbances of the intestines, impaired speech
4.	brachial plexus lesion (arm / hand plegia)
5.	Truncus sympathicus lesion (Horner's syndrome)
6.	permanent dysesthesia or pain in the neck/ear
7.	pneumothorax (dyspnea) requiring surgical intervention
8.	cosmetic disfigurement of the neck
9.	keloids requiring secondary therapy; scar contraction
10.	dyspnea, tracheotomy
11.	lymphedema
12.	chylous fistula requiring targeted therapy, eventually revision surgery

vative treatment and a lowfat diet supplemented with medium-chain triglycerides [427], [449], [452], [453], [454], [455], [456], [457], [458], [459], [460], [461]. Only few authors suggest surgical revision generally [462] or in case of hypoalbuminemia, duration more than 30 days or a daily amount of more than 600 ml [427], [432], [453], [454], [456], [463], [464], [465]. Nussenbaum suggests surgical revision if more than 1000 ml are drained within the first 24 hours [466]. Chylothorax is a life-threatening situation that may require repeated incision drainages of the thorax, low-fat diet, parenteral nutrition and sometimes suture ligation if not responding to the previously mentioned measures of treatment [427], [432], [467], [468]. Since dyspnea may also result from a lesion of the phrenic nerve [469] diagnosis of a chylothorax is based on an X-ray of the thorax [470]. A single-sided lesion of the phrenic nerve usually is not clinically apparent and only sometimes complicated by pulmonary atelectasis and subsequent infection [471]. Injection of tetracyclines to induce sclerosis [472] jeopardizes at least the phrenic nerve [473].

4.3.3.1 Spinal accessory nerve lesion

A lesion of the spinal accessory nerve occurs in 3 to 8% of cases, particularly if the lateral triangle of the neck was involved [474]. Painful and restricted mobility of the shoulder may lead to inability to work [427], [432], [475] which explains the great number of negligence claims that reached German courts [476], [477]. The impairment may reduce general ability to work by 30% according to expert opinion [478], and the ability to work in qualified job by 15% [479]. Delay to diagnose the lesion has been punished in court trials [480]. Ultrasound is capable to identify the continuity of the nerve [481]. Immediate surgical repair appears to be most successful [482] but successful outcome was reported even if revision surgery was performed with a delay of 3 [483] or 6 months [484]. One court trial followed the expert opinion to refrain from revision surgery although the diagnosis was clear immediately after LN [437]. To date, no consensus has

emerged on how to prevent spinal accessory nerve injuries, assess surgical experience [476], confirmed by Hopf [485]. Alleged medical malpractice is widely based on an assumed, but not written-down medical standard. Surgical improvements have been suggested in surgical textbooks and encompass electrosurgical means to achieve hemostasis, avoidance of hooks, magnification with loupes, nerve monitoring, general anesthesia, at least one assisting surgeon, adequate surgical experience, pre- and post-operative diagnostic, adequate documentation, minimum time for the operation, leaving the "back-side" of the lymph node in the surgical field and complete exposure of the nerve [442]. However, it has been doubted, that exposure of the nerve is capable to prevent its lesion [476], [477]. Although no evidence for the best method to spare the nerve is supported by scientific papers, expert statements occasionally can read differently. Since court trials usually follow expert opinions, this may result in verdicts in favor of the plaintiff [486] or defendant [487]. While one expert stated, that identification and prevention of the nerve is always possible, even in cases with severe inflammation [488] a contradictory statement is supported by the finding of an intact nerve in revision surgery in a case with serious inflammation [489]. Some experts conclude, that lesion of the spinal accessory nerve is a typical and fateful complication [490], that occurs even after accurate operations [437], [491] which may explain, that one trial was stopped at court [492]. Operation time, adequate documentation of the procedure and histological confirmation of the inflammation is helpful for the surgeon [128] and a meticulous description of the dealing with the advisable [130]. This statement is confirmed by the legal adviser of the German Society of Oto-Rhino-Laryngology, Head and Neck Surgery [490] and helpful at a time of confusing and contradictory verdicts [493]. It is noteworthy to repeat, that an adequate documentation is of paramount importance. A lack of informed consent was identified in 12 of 15 cases of medical malpractice.

Current surgical handbooks emphasize the need of a meticulous and careful dissection of the nerve after

visual identification [494]. Unintentional stretching of the nerve may occur even with soft retractors [494]. Good experiences with nerve monitoring in 10 patients were reported by Midwinter [495], who confirmed earlier findings of Harpf [482]. To date, nerve monitoring of the spinal accessory nerve is not widely accepted as it is for cranial base surgery, parotid gland surgery or thyroid surge [427]. Visual identification of the nerve and wound retraction with blunt hooks were highly recommended by Thumfart [431]. Indeed, in only of 55 medical malpractice cases, the nerve had been identified by the surgeon [476]. To facilitate identification of the nerve Tatla uses the tendon of the sternocleidomastoid muscle as surgical landmark [496]. His finding of a great variability of the nerve's course and its relation to the internal jugular vein is confirmed by other authors [497], [498]. Testing of the nerve function before and after LN in level V is essential to prevent claims before trial [127]. However, a normal finding immediately after surgery does not exclude a permanent dysfunction that develops with a delay [478] and is noticed by painful impaired mobility of the shoulder [499].

4.3.4 Medical malpractice in the literature

Morris reviewed 39 indemnity insurance cases and 55 court trials between 1985 and 2007 involving injury of the spinal accessory nerve. Defendants were mainly general surgeons and otolaryngologists. The indemnity insurance cases involved a posterior triangle lymph node biopsy, 10 were discontinued, 22 settled before and 8 at trial. Two of the 8 cases returned in defendant verdict, 28 ultimately compensated the plaintiff. All court trials dealt with alleged surgical injury to the spinal accessory nerve. In essentially all verdict reports, the defendant surgeon argued that either nerve injury was a recognized complication of surgery or the shoulder weakness was caused by a separate process, such as trauma, infection, or cancer. Most defendants argued that it was not necessary to identify the nerve in the posterior triangle, the nerve was only identified in 1 case. In 9 cases, the nerve injury found on re-exploration was reported: there were 7 nerve transections, 1 neuroma, and 1 case of intraneural fibrosis. Of the 55 cervical lymph node cases, 7 were settled, 25 were defendant verdicts, and 23 were plaintiff verdicts. Therefore, 30 of 55 plaintiffs in lymph node court cases received monetary awards at trial [476].

5 Conclusion

Complicated cases following TE, TT, ATE, SP and LN are not systematically collected in Germany. It can be assumed, that not every complicated case is published in the medical literature or law journals and therefore not obtainable for scientific research. Alleged medical malpractice is proven for less than 6% before trial stage. Approximately half of all cases result in a plaintiff verdict or settlement at court. Proper documentation of a thorough

counselling, examination, indication, informed consent and follow-up assists the surgeon in litigation. An adequate complication management of PTH is essential, including instructions for the patients/parents, instructions for the medical staff and readily available surgical instruments. Successful outcome of life-threatening PTH is widely based on a proper airway management in an interdisciplinary approach. Electrosurgical tonsillectomy techniques were repeatedly labeled as a risk factor for bleeding complications following TE. Institutions should analyse the individual PTH rate on a yearly basis. Contradictory expert opinions and verdicts of the courts concerning spinal accessory nerve lesions following LN are due to a lack of a surgical standard.

Notes

Competing interests

The author declares that he has no competing interests.

References

1. Die 50 häufigsten Operationen der vollstationären Patientinnen und Patienten in Krankenhäusern (Rang, Anzahl, Anteil in Prozent). Gliederungsmerkmale: Jahre, Deutschland, Geschlecht, Art der Operation. Available from: http://www.gbe-bund.de/oowa921-install/servlet/oowa/aw92/dboowasys921.xwdevkit/xwd_init?gbe.isgbetol/xs_start_neu/&p_aid=3&p_aid=8630964&nummer=666&p_sprache=D&p_indsp=-&p_aid=74785474
2. Statistisches Bundesamt. Die fünf häufigsten Operationen (OPS-Schlüssel 5) der vollstationär behandelten Patienten (weiblich) nach ausgewählten Altersgruppen. Available from: <https://www.destatis.de/DE/ZahlenFakten/GesellschaftStaat/Gesundheit/Krankenhaeuser/Tabellen/HaeufigstenOPSFrauen.html;jsessionid=4EA0B913B2DD4145AB0EE0824BC63910.cae4#Start>
3. Statistisches Bundesamt. Die fünf häufigsten Operationen (OPS-Schlüssel 5) der vollstationär behandelten Patienten (männlich) nach ausgewählten Altersgruppen. Available from: <https://www.destatis.de/DE/ZahlenFakten/GesellschaftStaat/Gesundheit/Krankenhaeuser/Tabellen/HaeufigstenOPSMaenner.html>
4. Referentenentwurf des Bundesministeriums der Justiz und des Bundesministeriums für Gesundheit Entwurf eines Gesetzes zur Verbesserung der Rechte von Patientinnen und Patienten. Available from: http://www.bmg.bund.de/fileadmin/dateien/Downloads/Gesetze_und_Verordnungen/Laufende_Verfahren/P/Patientenrechte/Referentenentwurf_Patientenrechte_BMJ_BMG_Endfassung_120116.pdf
5. Gerst T. Gutachterkommissionen und Schlichtungsstellen: Hohe Akzeptanz des Verfahrens. Dtsch Arztebl. 2012;109:A-1299/B-1123/C-1107.
6. Fragen und Antworten zur Begutachtung von Behandlungsfehlern durch den MDK. Available from: http://www.mdk.de/media/pdf/7_-12-03-26_Faktenblatt_Behandlungsfehler_FAQ_final.pdf
7. BGH 06.05.2003 VI ZR 259/02.
8. Deutsch E. Der grobe Behandlungsfehler: Dogmatik und Rechtsfolgen. VersR. 1988;1.
9. BGH 10.05.1983 VI ZR 270/81.

10. BGH 21. 09.1982 VI ZR 302/80.
11. BGH 23.03. 2004 VI ZR 428/02.
12. BGH 16.11.2004 VI ZR 328/03.
13. OLG Köln 20.09.1989 27 U 158/88.
14. PubMed.gov. Available from: <http://www.ncbi.nlm.nih.gov/pubmed>
15. OLG Hamm 29.02.1988 3 U 44/87.
16. OLG München 29.09.1988 24 U 806/87.
17. OLG Hamm 05.11.1980 3 U 67/80.
18. OLG Oldenburg 09.04.1996 5 U 158/95.
19. Randall DA, Hoffer ME. Complications of tonsillectomy and adenoidectomy. *Otolaryngol Head Neck Surg.* 1998;118(1):61-8. DOI: 10.1016/S0194-5998(98)70376-6
20. Liu JH, Anderson KE, Willging JP, Myer CM 3rd, Shott SR, Bratcher GO, Cotton RT. Posttonsillectomy hemorrhage: what is it and what should be recorded? *Arch Otolaryngol Head Neck Surg.* 2001 Oct;127(10):1271-5. DOI: 10.1001/archotol.127.10.1271
21. Windfuhr JP, Schloendorff G, Baburi D, Kremer B. Life-threatening posttonsillectomy hemorrhage. *Laryngoscope.* 2008;118(8):1389-94. DOI: 10.1097/MLG.0b013e3181734f7e
22. Windfuhr JP, Sesterhenn K. Blutung nach Tonsillektomie. Analyse von 229 Fällen [Hemorrhage after tonsillectomy. Analysis of 229 cases]. *HNO.* 2001 Sep;49(9):706-12. DOI: 10.1007/s001060170041
23. Windfuhr JP. Excessive post-tonsillectomy hemorrhage requiring ligation of the external carotid artery. *Auris Nasus Larynx.* 2002;29(2):159-64. DOI: 10.1016/S0385-8146(01)00138-9
24. Windfuhr JP, Schloendorff G, Baburi D, Kremer B. Lethal outcome of post-tonsillectomy hemorrhage. *Eur Arch Otorhinolaryngol.* 2008;265(12):1527-34. DOI: 10.1007/s00405-008-0699-4
25. Baugh RF, Archer SM, Mitchell RB, Rosenfeld RM, Amin R, Burns JJ, Darrow DH, Giordano T, Litman RS, Li KK, Mannix ME, Schwartz RH, Setzen G, Wald ER, Wall E, Sandberg G, Patel MM; American Academy of Otolaryngology-Head and Neck Surgery Foundation. Clinical practice guideline: tonsillectomy in children. *Otolaryngol Head Neck Surg.* 2011;144(1 Suppl):S1-30. DOI: 10.1177/0194599810389949
26. National Prospective Tonsillectomy Audit. Available from: http://www.rcseng.ac.uk/publications/docs/national_prospective.html
27. Spitzenmedizin der Deutschen Hochschulmedizin. Qualität Leben. Available from: http://www.uniklinika.de/media/file/3397.2011%20QUALITAET%20LEBEN_VUD_Druckversion.pdf
28. Windfuhr JP. Serious Complications following Tonsillectomy: How Frequent Are They Really? *ORL J Otorhinolaryngol Relat Spec.* 2013;75(3):166-73. DOI: 10.1159/000342317
29. Günzel T, Zenev E, Heinze N, Schwager K. Tonsillektomienachblutungen im Zeitraum von 1985 bis 2001 und Erfahrungen bei der Anwendung der Lasertonsillotomie bei Kleinkindern [Postoperative bleeding after tonsillectomy between 1985 and 2001 and experiences to perform laser tonsillotomy]. *Laryngorhinootologie.* 2004;83(9):579-84. DOI: 10.1055/s-2004-825810
30. Deitmer T, Neuwirth C. Untersuchungen an 105 Fällen von Nachblutungen nach Tonsillektomie [105 cases of post-tonsillectomy hemorrhage revisited]. *Laryngorhinootologie.* 2010;89(7):424-8. DOI: 10.1055/s-0030-1253366
31. Schmidt H, Schmitz A, Stasche N, Hörmann K. Operativ versorgte Nachblutungen nach Tonsillektomie [Surgically managed postoperative hemorrhage after tonsillectomy]. *Laryngorhinootologie.* 1996;75(8):447-54. DOI: 10.1055/s-2007-997613
32. Papaspyrou K, von Creyzt H, Kolonko K, Mewes T, Mann W, Scharrer I. Nachblutungen und Gerinnungsstörungen bei Tonsillektomien [Bleeding and coagulation disorders in tonsillectomies]. *HNO.* 2012;60(6):511-7. DOI: 10.1007/s00106-011-2454-1
33. Scheckenbach K, Bier H, Hoffmann TK, Windfuhr JP, Bas M, Laws HJ, Plettenberg C, Wagenmann M. Risiko von Blutungen nach Adenotomie und Tonsillektomie. Aussagekraft der präoperativen Bestimmung von PTT, Quick und Thrombozytenzahl [Risk of hemorrhage after adenoidectomy and tonsillectomy. Value of the preoperative determination of partial thromboplastin time, prothrombin time and platelet count]. *HNO.* 2008;56(3):312-20. DOI: 10.1007/s00106-007-1585-x
34. Heyden Hv, Schäfer E, Jecker P, Gosepath J, Mann WJ. Tonsillektomie mit Koagulationsschere oder Raspatorium: Ergebnisse einer Fallkontrollstudie bei 138 Patienten [Tonsillectomy technique: bipolar scissors vs raspatory: results of a case control study in 138 patients]. *HNO.* 2007;55(9):684-9. DOI: 10.1007/s00106-006-1502-8
35. Windfuhr JP, Chen YS, Rimmert S. Hemorrhage following tonsillectomy and adenoidectomy in 15,218 patients. *Otolaryngol Head Neck Surg.* 2005;132(2):281-6. DOI: 10.1016/j.otohns.2004.09.007
36. Lorenz KJ, Kresz A, Maier H. Tonsillektomie in Hydrodissektionstechnik. Ergebnisse einer Pilotstudie– intraoperativer Blutverlust, postoperative Schmerzsymptomatik und Nachblutungsrisiko [Hydrodissection for tonsillectomy. Results of a pilot study–intraoperative blood loss, postoperative pain symptoms and risk of secondary hemorrhage]. *HNO.* 2005;53(5):423-7. DOI: 10.1007/s00106-004-1129-6
37. Jäckel MC, Petzold S, Dimmer V, Mall G, Reck R. Die mikrochirurgische Tonsillektomie mit dem CO2-Laser. Eine Analyse klinischer und morphologischer Daten [Tonsillectomy by CO₂ laser microsurgery–an analysis of clinical and morphological data]. *HNO.* 2003 Aug;51(8):634-9. DOI: 10.1007/s00106-002-0789-3
38. Haegner U, Handrock M, Schade H. Die "Ultraschalltonsillektomie" im Vergleich zur konventionellen Tonsillektomie ["Ultrasound tonsillectomy" in comparison with conventional tonsillectomy]. *HNO.* 2002 Sep;50(9):836-43. DOI: 10.1007/s00106-001-0607-3
39. Tisch M, Bruder M, Maier H. Nachblutungsrisiko bei Tonsillektomie. Ein Vergleich zwischen Vollnarkose und lokaler Betäubung [Risk of postoperative hemorrhage in tonsillectomy. A comparison between general anesthesia and local anesthesia]. *HNO.* 2002 Mar;50(3):230-2. DOI: 10.1007/s001060100538
40. Bergler W, Huber K, Hammerschmitt N, Hölzl M, Hörmann K. Tonsillektomie mit dem Argon-Plasma-Koagulations-Raspatorium. Eine klinisch prospektive randomisierte Blindstudie [Tonsillectomy with the argon-plasma-coagulation-raspatorium - a prospective randomized single-blinded study]. *HNO.* 2000 Feb;48(2):135-41. DOI: 10.1007/s001060050021
41. Metternich FU, Sagowski C, Wenzel S, Jäkel K. Tonsillektomie mit dem ultraschallaktivierten Skalpell. Erste Ergebnisse zur Technik mit dem Ultracision Harmonic Scalpel [Tonsillectomy with the ultrasound activated scalpel. Initial results of technique with Ultracision Harmonic Scalpel]. *HNO.* 2001 Jun;49(6):465-70. DOI: 10.1007/s001060170098
42. Sarny S, Ossimitz G, Habermann W, Stammberger H. "Die Österreichische Tonsillenstudie 2010"-Teil 1: Statistischer Überblick [The Austrian tonsil study 2010–part 1: statistical overview]. *Laryngorhinootologie.* 2012;91(1):16-21. DOI: 10.1055/s-0031-1291310

43. Sarny S, Habermann W, Ossimitz G, Stammberger H. "Die Österreichische Tonsillenstudie 2010" - Teil 2: Postoperative Blutungen [The Austrian Tonsil Study 2010 - Part 2: Postoperative haemorrhage]. *Laryngorhinootologie*. 2012;91(2):98-102. DOI: 10.1055/s-0031-1291309
44. Sarny S, Ossimitz G, Habermann W, Stammberger H. Hemorrhage following tonsil surgery: a multicenter prospective study. *Laryngoscope*. 2011;121(12):2553-60. DOI: 10.1002/lary.22347
45. Windfuhr JP, Ulbrich T. Post-tonsillectomy hemorrhage: results of a 3-month follow-up. *Ear Nose Throat J*. 2001 Nov;80(11):790, 795-8, 800 passim.
46. Sarny S, Habermann W, Ossimitz G, Schmid C, Stammberger H. Tonsillar haemorrhage and re-admission: a questionnaire based study. *Eur Arch Otorhinolaryngol*. 2011;268(12):1803-7. DOI: 10.1007/s00405-011-1541-y
47. Wienke A. Nachblutungen infolge einer Mandeloperation [Postoperative hemorrhage after tonsillectomy]. *Laryngorhinootologie*. 1999;78(7):408-9. DOI: 10.1055/s-2007-996898
48. Wienke A. Nachblutungen nach Tonsillektomie. Ermittlungsverfahren der Staatsanwaltschaft Hagen-71 Js 565/96-(Einstellung des Ermittlungsverfahrens gem. section 170 Abs. 2 StPO) [Postoperative hemorrhage after tonsillectomy. Clarification procedure of the federal court Hagen-71 Js 565/96-(implementing the clarification procedure according to section 170 Abs. 2 StPO)]. *Laryngorhinootologie*. 1999;78(5):293-4. DOI: 10.1055/s-2007-996874
49. OLG Koblenz 12.09.1994 3 Ws 500/9.
50. Morris LG, Lieberman SM, Reitzen SD, Edelstein DR, Ziff DJ, Katz A, Komisar A. Characteristics and outcomes of malpractice claims after tonsillectomy. *Otolaryngol Head Neck Surg*. 2008;138(3):315-20. DOI: 10.1016/j.otohns.2007.11.024
51. Stevenson AN, Myer CM, Shuler MD, Singer PS. Complications and legal outcomes of tonsillectomy malpractice claims. *Laryngoscope*. 2012;122(1):71-4. DOI: 10.1002/lary.22438
52. OLG Braunschweig 18.1.2007 1 U 24/06.
53. OLG Dresden 23.10.2003 4 U 980/03.
54. OLG Hamm 7.7.2004 3 U 264/03.
55. OLG Koblenz 12.10.2006 5 U 456/06.
56. OLG München 12.10.2006 U 2142/06.
57. Bergmann K. Neue Rechtsprechung zum Arzthaftungsrecht. Bonn: Deutscher Anwaltverlag; 2006.
58. Paradise JL, Bluestone CD, Bachman RZ, Colborn DK, Bernard BS, Taylor FH, Rogers KD, Schwarzbach RH, Stool SE, Friday GA. Efficacy of tonsillectomy for recurrent throat infection in severely affected children. Results of parallel randomized and nonrandomized clinical trials. *N Engl J Med*. 1984;310(11):674-83. DOI: 10.1056/NEJM198403153101102
59. Paradise JL, Bluestone CD, Colborn DK, Bernard BS, Rockette HE, Kurs-Lasky M. Tonsillectomy and adenotonsillectomy for recurrent throat infection in moderately affected children. *Pediatrics*. 2002 Jul;110(1 Pt 1):7-15. DOI: 10.1542/peds.110.1.7
60. van Staaik BK, van den Akker EH, Rovers MM, Hordijk GJ, Hoes AW, Schilder AG. Effectiveness of adenotonsillectomy in children with mild symptoms of throat infections or adenotonsillar hypertrophy: open, randomised controlled trial. *BMJ*. 2004;329(7467):651. DOI: 10.1136/bmj.38210.827917.7C
61. Deitmer T. Tonsillektomie-Indikation und Ausführung heute. In: Ganz H, Iro H, eds. *HNO-Praxis heute*. Berlin, Heidelberg: Springer; 2000. p. 83-107.
62. Luckhaupt H. Tonsillektomie, Adenotomie, Paukenergüsse. In: Hildmann H, Koch U, eds. *Hals-Nasen-Ohren-Chirurgie im Kindes- und Jugendalter Verhandlungsbericht*. Berlin, Heidelberg, New York, Tokio: Springer; 1999. p. 127-34.
63. Management of sore throat and indications for tonsillectomy. A national clinical guideline. Available from: <http://www.sign.ac.uk/pdf/sign117.pdf>
64. The clinical and organisational appropriateness of tonsillectomy and adenoidectomy. Available from: <http://www.snlg-iss.it/PNLG/LG/007tonsille/tonsillectomy.pdf>
65. Alho OP, Koivunen P, Penna T, Teppo H, Koskela M, Luotonen J. Tonsillectomy versus watchful waiting in recurrent streptococcal pharyngitis in adults: randomised controlled trial. *BMJ*. 2007 May;334(7600):939. DOI: 10.1136/bmj.39140.632604.55
66. Burton MJ, Glasziou PP. Tonsillectomy or adeno-tonsillectomy versus non-surgical treatment for chronic/recurrent acute tonsillitis. *Cochrane Database Syst Rev*. 2009;(1):CD001802. DOI: 10.1002/14651858.CD001802.pub2
67. Akgun D, Seymour FK, Qayyum A, Crystal R, Frosh A. Assessment of clinical improvement and quality of life before and after tonsillectomy. *J Laryngol Otol*. 2009;123(2):199-202. DOI: 10.1017/S0022215108002600
68. Mui S, Rasgon BM, Hilsinger RL Jr. Efficacy of tonsillectomy for recurrent throat infection in adults. *Laryngoscope*. 1998 Sep;108(9):1325-8. DOI: 10.1097/00005537-199809000-00012
69. Schwentner I, Höfer S, Schmutzhard J, Deibl M, Sprinzl GM. Impact of tonsillectomy on quality of life in adults with chronic tonsillitis. *Swiss Med Wkly*. 2007 Aug;137(31-32):454-61.
70. Bhattacharyya N, Kepnes LJ. Economic benefit of tonsillectomy in adults with chronic tonsillitis. *Ann Otol Rhinol Laryngol*. 2002 Nov;111(11):983-8.
71. Marshall T. A review of tonsillectomy for recurrent throat infection. *Br J Gen Pract*. 1998 Jun;48(431):1331-5.
72. Thompson AC. Adult tonsillectomy--results and patient selection. *J Laryngol Otol*. 1991 Oct;105(10):836-8. DOI: 10.1017/S0022215100117475
73. Stafors J, Ericsson E, Hemlin C, Hultcrantz E, Månsson I, Roos K, Hessén Söderman AC. Tonsil surgery efficiently relieves symptoms: analysis of 54 696 patients in the National Tonsil Surgery Register in Sweden. *Acta Otolaryngol*. 2012;132(5):533-9. DOI: 10.3109/00016489.2011.644252
74. Hsu AP, Tan KL, Tan YB, Han HJ, Lu PK. Benefits and efficacy of tonsillectomy for recurrent tonsillitis in adults. *Acta Otolaryngol*. 2007;127(1):62-4. DOI: 10.1080/00016480500540501
75. Fujihara K, Koltai PJ, Hayashi M, Tamura S, Yamanaka N. Cost-effectiveness of tonsillectomy for recurrent acute tonsillitis. *Ann Otol Rhinol Laryngol*. 2006 May;115(5):365-9.
76. Blair RL, McKerrow WS, Carter NW, Fenton A. The Scottish tonsillectomy audit. The Audit Sub-Committee of the Scottish Otolaryngological Society. *J Laryngol Otol Suppl*. 1996;20(1):1-25.
77. Kim JY, Lee CH. Clinical study on the efficacy of tonsilloadenoidectomy. *Acta Otolaryngol Suppl*. 1988;454():265-72.
78. Richards AL, Bailey M, Hooper R, Thomson P. Quality-of-life effect of tonsillectomy in a young adult group. *ANZ J Surg*. 2007 Nov;77(11):988-90. DOI: 10.1111/j.1445-2197.2007.04296.x
79. Baumann I, Kucheida H, Blumenstock G, Zalaman IM, Maassen MM, Plinkert PK. Benefit from tonsillectomy in adult patients with chronic tonsillitis. *Eur Arch Otorhinolaryngol*. 2006;263(6):556-9. DOI: 10.1007/s00405-006-0009-y

80. Oluwasanmi AF, Thornton MR, Khalil HS, Tierney PA. Effect of tonsillectomy on recurrent sore throats in adults: patients' perspectives. *J Laryngol Otol.* 2006 Feb;120(2):e7. DOI: 10.1017/S0022215105002197
81. Laing MR, McKerrow WS. Adult tonsillectomy. *Clin Otolaryngol Allied Sci.* 1991;16(1):21-4. DOI: 10.1111/j.1365-2273.1991.tb01936.x
82. Witsell DL, Orvidas LJ, Stewart MG, Hannley MT, Weaver EM, Yueh B, Smith TL, Goldstein NA; TO TREAT Study Investigators. Quality of life after tonsillectomy in adults with recurrent or chronic tonsillitis. *Otolaryngol Head Neck Surg.* 2008;138(1 Suppl):S1-8. DOI: 10.1016/j.otohns.2007.08.015
83. Koskenkorva T, Koivunen P, Penna T, Teppo H, Alho OP. Factors affecting quality-of-life impact of adult tonsillectomy. *J Laryngol Otol.* 2009 Sep;123(9):1010-4. DOI: 10.1017/S0022215109005271
84. Ericsson E, Ledin T, Hultcrantz E. Long-term improvement of quality of life as a result of tonsillotomy (with radiofrequency technique) and tonsillectomy in youths. *Laryngoscope.* 2007;117(7):1272-9. DOI: 10.1097/MLG.0b013e31805559e1
85. Stafford N, von Haacke N, Sene A, Croft C. The treatment of recurrent tonsillitis in adults. *J Laryngol Otol.* 1986 Feb;100(2):175-7. DOI: 10.1017/S0022215100098935
86. Senska G, Ellermann S, Ernst S, Lax H, Dost P. Recurrent tonsillitis in adults: quality of life after tonsillectomy. *Dtsch Arztebl Int.* 2010;107(36):622-8. DOI: 10.3238/arztebl.2010.0622
87. Powell HR, Mehta N, Daly N, Watters GW. Improved quality of life in adults undergoing tonsillectomy for recurrent tonsillitis. Is adult tonsillectomy really a low priority treatment? *Eur Arch Otorhinolaryngol.* 2012;269(12):2581-4. DOI: 10.1007/s00405-012-2095-3
88. Commissioning policy for procedures of limited clinical value (PLCV). Available from: <http://ebookbrowse.net/gdoc.php?id=295484488&url=e5e77312f371a74528dd1dcac4ebd703>
89. Walther LE, Ilgner J, Oehme A, Schmidt P, Sellhaus B, Gudziol H, Beleites E, Westhofen M. Die infektiöse Mononukleose [Infectious mononucleosis]. *HNO.* 2005;53(4):383-92; quiz 393. DOI: 10.1007/s00106-004-1210-1
90. Sumaya CV, Downey K, Ullis KC. Tonsillectomy and infectious mononucleosis. *Am J Epidemiol.* 1978 Jan;107(1):65-70.
91. Goode RL, Coursey DL. Tonsillectomy and infectious mononucleosis—a possible relationship. *Laryngoscope.* 1976 Jul;86(7):992-5. DOI: 10.1288/00005537-197607000-00013
92. Stuck BA, Götte K, Windfuhr JP, Genzwürker H, Schrotten H, Tenenbaum T. Tonsillectomy in children. *Dtsch Arztebl Int.* 2008 Dec;105(49):852-60; quiz 860-1. DOI: 10.3238/arztebl.2008.0852
93. Stevenson DS, Webster G, Stewart IA. Acute tonsillectomy in the management of infectious mononucleosis. *J Laryngol Otol.* 1992 Nov;106(11):989-91. DOI: 10.1017/S0022215100121541
94. Theissing J. *HNO-Operationslehre. Mit allen wichtigen Eingriffen.* Stuttgart, New York: Thieme; 2006.
95. Zenner HP. *Praktische Therapie von HNO-Krankheiten. Operationsprinzipien, konservative Therapie, Chemo- und Radiochemotherapie, Arzneimittel- und physikalische Therapie, Rehabilitation und psychosoziale Nachsorge.* 2. Auflage. Stuttgart, New York: Schattauer; 2008.
96. *LG Stuttgart* 26.11.1986 15 O 150/184.
97. Candy B, Hotopf M. Steroids for symptom control in infectious mononucleosis. *Cochrane Database Syst Rev.* 2006;(3):CD004402. DOI: 10.1002/14651858.CD004402.pub2
98. Herzon FS. Harris P. Moshier Award thesis. Peritonsillar abscess: incidence, current management practices, and a proposal for treatment guidelines. *Laryngoscope.* 1995;105(8 Pt 3 Suppl 74):1-17.
99. Windfuhr JP, Remmert S. Peritonsillarabszess Trends und Komplikationen bei der Behandlung, insbesondere bei Kindern [Trends and complications in the management of peritonsillar abscess with emphasis on children]. *HNO.* 2005;53(1):46-57. DOI: 10.1007/s00106-003-1036-2
100. Rosenfeld RM, Green RP. Tonsillectomy and adenoidectomy: changing trends. *Ann Otol Rhinol Laryngol.* 1990 Mar;99(3 Pt 1):187-91.
101. Hanenkamp U, Helling K, Mann WJ. Die Tonsillotomie mit der bipolaren Koagulationsschere [Tonsillotomy with bipolar coagulation scissors]. *Laryngorhinootologie.* 2008;87(12):870-3. DOI: 10.1055/s-2008-1077387
102. Smith E, Wenzel S, Rettinger G, Fischer Y. Lebensqualität bei kindlichem obstruktiven Schlafapnoesyndrom nach Tonsillektomie, Tonsillotomie und/oder Adenotomie [Quality of life in children with obstructive sleeping disorder after tonsillectomy, tonsillotomy or adenotomy]. *Laryngorhinootologie.* 2008;87(7):490-7. DOI: 10.1055/s-2007-995627
103. Unkel C, Lehnerdt G, Metz K, Jahnke K, Dost P. Langzeitverlauf nach Laser-Tonsillotomie bei symptomatischer Tonsillenhyperplasie [Long-term results of laser-tonsillotomy in obstructive tonsillar hyperplasia]. *Laryngorhinootologie.* 2004;83(7):466-9. DOI: 10.1055/s-2004-814469
104. Unkel C, Lehnerdt G, Schmitz KJ, Jahnke K. Laser-tonsillotomy for treatment of obstructive tonsillar hyperplasia in early childhood: a retrospective review. *Int J Pediatr Otorhinolaryngol.* 2005;69(12):1615-20. DOI: 10.1016/j.ijporl.2005.08.017
105. Jahnke K. Laser-Tonsillotomie, Wissensstand und offene Fragen [Laser-tonsillotomy, state of the art and open questions]. *Laryngorhinootologie.* 2005;84(9):651-2. DOI: 10.1055/s-2005-870376
106. Scherer H. Tonsillotomie versus Tonsillektomie [Tonsillotomy versus tonsillectomy]. *Laryngorhinootologie.* 2003;82(11):754-5. DOI: 10.1055/s-2003-44535
107. Helling K, Abrams J, Bertram WK, Hohner S, Scherer H. Die Lasertonsillotomie bei der Tonsillenhyperplasie des Kleinkindes [Laser tonsillectomy in tonsillar hyperplasia of early childhood]. *HNO.* 2002 May;50(5):470-8. DOI: 10.1007/s00106-001-0580-x
108. Densert O, Desai H, Eliasson A, Frederiksen L, Andersson D, Olaison J, Widmark C. Tonsillotomy in children with tonsillar hypertrophy. *Acta Otolaryngol.* 2001 Oct;121(7):854-8. DOI: 10.1080/00016480152602339
109. Hultcrantz E, Linder A, Markström A. Long-term effects of intracapsular partial tonsillectomy (tonsillotomy) compared with full tonsillectomy. *Int J Pediatr Otorhinolaryngol.* 2005;69(4):463-9. DOI: 10.1016/j.ijporl.2004.11.010
110. Hultcrantz E, Linder A, Markström A. Tonsillectomy or tonsillotomy?—A randomized study comparing postoperative pain and long-term effects. *Int J Pediatr Otorhinolaryngol.* 1999;51(3):171-6. DOI: 10.1016/S0165-5876(99)00274-8
111. Ericsson E, Hultcrantz E. Tonsil surgery in youths: good results with a less invasive method. *Laryngoscope.* 2007;117(4):654-61. DOI: 10.1097/mlg.0b013e318030ca69
112. Kassenärztliche Vereinigung Nordrhein. Tonsillotomie. Available from: http://www.kvno.de/10praxis/50qualitaet/20leistungen_a-z/tonsillotomie/index.html

113. Ilgen F. Die Lasertonsillotomie bei der obstruktiven Schlafapnoe aufgrund adenotonsillärer Hyperplasie im Kindesalter–Ergebnisse aus der Praxis [Laser-assisted tonsillotomy in children with obstructive sleep apnea and adenotonsillary hyperplasia–experiences as an outpatient procedure]. *Laryngorhinotologie*. 2005;84(9):665-70. DOI: 10.1055/s-2004-826197
114. Acevedo JL, Shah RK, Brietzke SE. Systematic review of complications of tonsillotomy versus tonsillectomy. *Otolaryngol Head Neck Surg*. 2012;146(6):871-9. DOI: 10.1177/0194599812439017
115. van den Aardweg MT, Schilder AG, Herkert E, Boonacker CW, Rovers MM. Adenoidectomy for otitis media in children. *Cochrane Database Syst Rev*. 2010;(1):CD007810. DOI: 10.1002/14651858.CD007810.pub2
116. van den Aardweg MT, Boonacker CW, Rovers MM, Hoes AW, Schilder AG. Effectiveness of adenoidectomy in children with recurrent upper respiratory tract infections: open randomised controlled trial. *BMJ*. 2011;343:d5154. DOI: 10.1136/bmj.d5154
117. Becker W. Erfahrungen als Gutachter bei Vorwürfen wegen mangelnder Aufklärung und Fahrlässigkeit. *Laryngol Rhinol*. 1974;53:75-89.
118. OLG Oldenburg 15.06.1993 5 U 10/93.
119. Bepfel A. Ärztliche Aufklärung in der Rechtsprechung. Die Entwicklung der Rechtsprechung zur ärztlichen Aufklärung in Deutschland, Österreich und der Schweiz. Göttingen: Universitätsverlag; 2007.
120. BGH 2.11.1993 VI ZR 245/92.
121. Feldmann H, Alberty J, Brusis T, et al. Das Gutachten des Hals-Nasen-Ohrenarztes. 7. Auflage. Stuttgart, New York: Georg Thieme Verlag; 2012.
122. OLG Hamm 07.03.2005 3 U 204/04.
123. OLG Saarbrücken 14.07.1993 1 U 52/93.
124. OLG Hamm 14.01.1998 3 U 23/97.
125. OLG Köln 21.04.1993 27 U 145/92.
126. OLG Zweibrücken 11.10.2005 5 U 10/05.
127. OLG München 21.03.2002 1 U 5064/01.
128. OLG Hamm 05.12.1994 3 U 8/94.
129. OLG Hamm 05.05.1999 3 U 194/98.
130. OLG Hamm 16.12.1992 3 U 241/91.
131. Tonsillektomie Konsensuspapier. Gemeinsame Empfehlungen der österreichischen Gesellschaften für Hals-, Nasen-, Ohren-Heilkunde, Kopf- und Halschirurgie und Kinder- und Jugendheilkunde zur Entfernung der Gaumenmandeln (Tonsillektomie). 2007. Available from: http://www.hno.at/fileadmin/hno/pdfs/Konsensuspapier_Tonsillektomie_HNO_OEGKJ_9Nov2007.pdf
132. Arnoldner C, Grasl MCh, Thurnher D, Hamzavi JS, Kaider A, Brunner M, Erovic BM. Surgical revision of hemorrhage in 8388 patients after cold-steel adenotonsillectomies. *Wien Klin Wochenschr*. 2008;120(11-12):336-42. DOI: 10.1007/s00508-008-0982-9
133. Windfuhr JP, Schloendorff G, Sesterhenn AM, Prescher A, Kremer B. A devastating outcome after adenoidectomy and tonsillectomy: ideas for improved prevention and management. *Otolaryngol Head Neck Surg*. 2009 Feb;140(2):191-6. DOI: 10.1016/j.otohns.2008.11.012
134. Rasmussen N. Complications of tonsillectomy and adenoidectomy. *Otolaryngol Clin North Am*. 1987 May;20(2):383-90.
135. Schmiegelow E. A case of primary death after removal of adenoid tissue. *Mschr Ohrenheilk*. 1897;31:115
136. McKenzie W, Woolf Cl. Carotid abnormalities and adenoid surgery. *J Laryngol Otol*. 1959;73:596-602. DOI: 10.1017/S0022215100055766
137. Windfuhr JP. An aberrant artery as a cause of massive bleeding following adenoidectomy. *J Laryngol Otol*. 2002 Apr;116(4):299-300. DOI: 10.1258/0022215021910591
138. Helmus C, Grin M, Westfall R. Same-day-stay adenotonsillectomy. *Laryngoscope*. 1990;100(6):593-6. DOI: 10.1288/00005537-199006000-00008
139. Windfuhr JP, Chen YS, Rimmert S. Hemorrhage following tonsillectomy and adenoidectomy in 15,218 patients. *Otolaryngol Head Neck Surg*. 2005;132(2):281-6. DOI: 10.1016/j.otohns.2004.09.007
140. Windfuhr JP, Schloendorff G, Baburi D, Kremer B. Serious post-tonsillectomy hemorrhage with and without lethal outcome in children and adolescents. *Int J Pediatr Otorhinolaryngol*. 2008;72(7):1029-40. DOI: 10.1016/j.ijporl.2008.03.009
141. Windfuhr JP. Indications for interventional arteriography in post-tonsillectomy hemorrhage. *J Otolaryngol*. 2002 Feb;31(1):18-22. DOI: 10.2310/7070.2002.19160
142. OLG Düsseldorf 16.09.1993 8 U 60/92.
143. Windfuhr JP, Chen YS, Rimmert S. Unidentified coagulation disorders in post-tonsillectomy hemorrhage. *Ear Nose Throat J*. 2004 Jan;83(1):28, 30, 32 passim.
144. Gumprecht TF, Cichon JV. Otolaryngology and von Willebrand's disease. *Arch Otolaryngol*. 1981;107(8):491-3. DOI: 10.1001/archotol.1981.00790440031008
145. Lekas MD, DiBenedetto J Jr, Smith PS, Kantesaria KP. Surgery on patients with hemostatic disorders. *Laryngoscope*. 1982 Aug;92(8 Pt 1):873-7.
146. Asaf T, Reuveni H, Yermiahov T, Leiberman A, Gurman G, Porat A, Schlaeffer P, Shifra S, Kapelushnik J. The need for routine preoperative coagulation screening tests (prothrombin time PT/partial thromboplastin time PTT) for healthy children undergoing elective tonsillectomy and/or adenoidectomy. *Int J Pediatr Otorhinolaryngol*. 2001;61(3):217-22. DOI: 10.1016/S0165-5876(01)00574-2
147. Close HL, Kryzer TC, Nowlin JH, Alving BM. Hemostatic assessment of patients before tonsillectomy: a prospective study. *Otolaryngol Head Neck Surg*. 1994;111(6):733-8. DOI: 10.1016/S0194-5998(94)70560-7
148. Burk CD, Miller L, Handler SD, Cohen AR. Preoperative history and coagulation screening in children undergoing tonsillectomy. *Pediatrics*. 1992 Apr;89(4 Pt 2):691-5.
149. Manning SC, Beste D, McBride T, Goldberg A. An assessment of preoperative coagulation screening for tonsillectomy and adenoidectomy. *Int J Pediatr Otorhinolaryngol*. 1987;13(3):237-44. DOI: 10.1016/0165-5876(87)90104-2
150. Zwack GC, Derkay CS. The utility of preoperative hemostatic assessment in adenotonsillectomy. *Int J Pediatr Otorhinolaryngol*. 1997;39(1):67-76. DOI: 10.1016/S0165-5876(96)01465-6
151. Howells RC, Wax MK, Ramadan HH. Value of preoperative prothrombin time/partial thromboplastin time as a predictor of postoperative hemorrhage in pediatric patients undergoing tonsillectomy. *Otolaryngol Head Neck Surg*. 1997;117(6):628-32. DOI: 10.1016/S0194-5998(97)70044-5
152. Kaplan EB, Sheiner LB, Boeckmann AJ, Roizen MF, Beal SL, Cohen SN, Nicoll CD. The usefulness of preoperative laboratory screening. *JAMA*. 1985 Jun;253(24):3576-81. DOI: 10.1001/jama.1985.03350480084025

153. Stuck BA. Gemeinsame Stellungnahme zur Notwendigkeit präoperativer Gerinnungsdiagnostik vor Tonsillektomie und Adenotomie bei Kindern. 2005. Available from: <http://hno.org/kollegen/StellungnahmeGerinnungsdiagnostikvorAT-TE.pdf>
154. Sarny S, Ossimitz G, Habermann W, Stammberger H. Preoperative coagulation screening prior to tonsillectomy in adults: current practice and recommendations. *Eur Arch Otorhinolaryngol*. 2013;270(3):1099-104. DOI: 10.1007/s00405-012-2099-z
155. Suchman AL, Mushlin AI. How well does the activated partial thromboplastin time predict postoperative hemorrhage? *JAMA*. 1986;256(6):750-3. DOI: 10.1001/jama.1986.03380060076029
156. De Carpentier J, Timms M. Preliminary experiences with microscopic tonsillectomy. *Clin Otolaryngol Allied Sci*. 1994 Aug;19(4):352-4. DOI: 10.1111/j.1365-2273.1994.tb01246.x
157. Kujawski O, Dulguerov P, Gysin C, Lehmann W. Microscopic tonsillectomy: a double-blind randomized trial. *Otolaryngol Head Neck Surg*. 1997;117(6):641-7. DOI: 10.1016/S0194-5998(97)70046-9
158. Theissing J. Eingriffe am Epipharynx. In: Theissing J, Rettinger G, Werner J, eds. HNO-Operationslehre. Mit allen wichtigen Eingriffen. Stuttgart, New York: Thieme; 2006. p. 151
159. Gardner JF. Sutures and disasters in tonsillectomy. *Arch Otolaryngol*. 1968 Nov;88(5):551-5. DOI: 10.1001/archotol.1968.00770010553018
160. Fisher AGT. Sigmoid tortuosity of the internal carotid artery and its relation to tonsil and pharynx. *Lancet*. 1915;2:128-130. DOI: 10.1016/S0140-6736(01)56103-6
161. Cairney J. Tortuosity of the Cervical Segment of the Internal Carotid Artery. *J Anat*. 1924 Oct;59(Pt 1):87-96.
162. Kelly AB. Tortuosity of the internal carotid artery in relation to the pharynx. *J Laryngol Otol*. 1925;40:15-23. DOI: 10.1017/S0022215100026955
163. Jackson JL. Tortuosity of the internal carotid artery and its relation to tonsillectomy. *Can Med Assoc J*. 1933 Nov;29(5):475-9.
164. Weibel J, Fields WS. Tortuosity, Coiling, And Kinking Of The Internal Carotid Artery. I. Etiology And Radiographic Anatomy. *Neurology*. 1965;15():7-18.
165. Ceylan S, Salman S, Bora F. Anomaly of the internal carotid artery detected during tonsillectomy. *J Craniofac Surg*. 2010;21(5):1638-9. DOI: 10.1097/SCS.0b013e3181ef67ba
166. Bergquist B. Anomalies in the course of arteria carotis interna in the upper region of the pharynx. *Acta otolaryngol*. 1946;34:246-255. DOI: 10.3109/00016484609128379
167. Herrschaft H. Abnorme Schlingenbildungen der A. carotis interna und ihre klinische Bedeutung bei Operationen im Halsbereich [Abnormal tortuosity of the internal carotid artery and its clinical significance in surgery of the neck area]. *Z Laryngol Rhinol Otol*. 1969 Feb;48(2):85-98.
168. Schumacher WA, Schafig A, Kehrl W, Pau HW. Verlaufsvarianten der Arteria carotis interna: Mögliche Risiken bei sogenannten Standardoperationen im Pharynxbereich [Variations in the course of the internal carotid artery: possible risks in so-called standard operations in the area of the pharynx]. *Laryngorhinotologie*. 1998 Sep;77(9):517-20. DOI: 10.1055/s-2007-997016
169. Windfuhr JP, Stow NW, Landis BN. Beware of kissing carotids. *ANZ J Surg*. 2010;80(9):668-9. DOI: 10.1111/j.1445-2197.2010.05421.x
170. Carmack J. Aberrant internal carotids and their relation to surgery of the pharynx. *Laryngoscope*. 1929;39:707-20. DOI: 10.1288/00005537-192911000-00001
171. Stupka W. Die Missbildungen u. Anomalien d. Nase und d. Nasenrachenraumes. Wien: Springer; 1938. DOI: 10.1007/978-3-7091-9958-9
172. Ricciardelli E, Hillel AD, Schwartz AN. Aberrant carotid artery. Presentation in the near midline pharynx. *Arch Otolaryngol Head Neck Surg*. 1989 Apr;115(4):519-22. DOI: 10.1001/archotol.1989.01860280117029
173. Prescher A. Personal communication.
174. Osguthorpe JD, Adkins WY Jr, Putney FJ, Hungerford GD. Internal carotid artery as source of tonsillectomy and adenoidectomy hemorrhage. *Otolaryngol Head Neck Surg*. 1981 Sep-Oct;89(5):758-62.
175. Demme K. Über Gefässanomalien im Pharynx. *Wien Med Wochenschr*. 1901;51:2245
176. LG Hagen 29.05.2009 42 Ns 600 Js 392/04 - 71/08.
177. Lowe D, van der Meulen J; National Prospective Tonsillectomy Audit. Tonsillectomy technique as a risk factor for postoperative haemorrhage. *Lancet*. 2004;364(9435):697-702. DOI: 10.1016/S0140-6736(04)16896-7
178. Lowe D, van der Meulen J, Cromwell D, Lewsey J, Copley L, Browne J, Yung M, Brown P. Key messages from the National Prospective Tonsillectomy Audit. *Laryngoscope*. 2007;117(4):717-24. DOI: 10.1097/mig.0b013e318031f0b0
179. Windfuhr JP, Wienke A, Chen YS. Electrosurgery as a risk factor for secondary post-tonsillectomy hemorrhage. *Eur Arch Otorhinolaryngol*. 2009;266(1):111-6. DOI: 10.1007/s00405-008-0720-y
180. Başaran B, Orhan KS, Yıldırım K, Hafız G. Tonsillektomi sonrası sekonder kanama olgusu: Internal karotis arter nekrozu [A case of secondary post-tonsillectomy bleeding: necrosis of the internal carotid artery]. *Kulak Burun Bogaz Ihtis Derg*. 2011 Mar-Apr;21(2):98-101.
181. Cardozo AA, Hallikeri C, Lawrence H, Sankar V, Hargreaves S. Teenage and adult tonsillectomy: dose-response relationship between diathermy energy used and morbidity. *Clin Otolaryngol*. 2007;32(5):366-71. DOI: 10.1111/j.1749-4486.2007.01529.x
182. Thomaser EG, Tschopp K. Der Einfluss des bipolaren Koagulationsstromes bei der Tonsillektomie auf den postoperativen Heilungsverlauf [Influence of intraoperatively applied current of coagulation on the postoperative course in tonsillectomy]. *Laryngorhinotologie*. 2004;83(8):501-6. DOI: 10.1055/s-2004-814467
183. Tschopp K. Monopolar electrocautery in adenoidectomy as a possible risk factor for Grisel's syndrome. *Laryngoscope*. 2002;112(8 Pt 1):1445-9. DOI: 10.1097/00005537-200208000-00022
184. Pinder D, Hilton M. Dissection versus diathermy for tonsillectomy. *Cochrane Database Syst Rev*. 2001;(4):CD002211. DOI: 10.1002/14651858.CD002211
185. Haddow K, Montague ML, Hussain SS. Post-tonsillectomy haemorrhage: a prospective, randomized, controlled clinical trial of cold dissection versus bipolar diathermy dissection. *J Laryngol Otol*. 2006;120(6):450-4. DOI: 10.1017/S0022215106000120
186. Lee MS, Montague ML, Hussain SS. Post-tonsillectomy hemorrhage: cold versus hot dissection. *Otolaryngol Head Neck Surg*. 2004;131(6):833-6. DOI: 10.1016/j.otohns.2004.08.008
187. Gendy S, O'Leary M, Colreavy M, Rowley H, O'Dwyer T, Blayney A. Tonsillectomy-cold dissection vs. hot dissection: a prospective study. *Ir Med J*. 2005 Nov-Dec;98(10):243-4.
188. O'Leary S, Vorrath J. Postoperative bleeding after diathermy and dissection tonsillectomy. *Laryngoscope*. 2005;115(4):591-4. DOI: 10.1097/01.mig.0000161361.66191.60

189. Leinbach RF, Markwell SJ, Colliver JA, Lin SY. Hot versus cold tonsillectomy: a systematic review of the literature. *Otolaryngol Head Neck Surg.* 2003;129(4):360-4. DOI: 10.1016/S0194-5998(03)00729-0
190. Burton MJ, Doree C. Coblation versus other surgical techniques for tonsillectomy. *Cochrane Database Syst Rev.* 2007;(3):CD004619. DOI: 10.1002/14651858.CD004619.pub2
191. Glade RS, Pearson SE, Zalzal GH, Choi SS. Coblation adenotonsillectomy: an improvement over electrocautery technique? *Otolaryngol Head Neck Surg.* 2006;134(5):852-5. DOI: 10.1016/j.otohns.2005.11.005
192. Neumann C, Street I, Lowe D, Sudhoff H. Harmonic scalpel tonsillectomy: a systematic review of evidence for postoperative hemorrhage. *Otolaryngol Head Neck Surg.* 2007;137(3):378-84. DOI: 10.1016/j.otohns.2007.05.003
193. Jebeles JA, Reilly JS, Gutierrez JF, Bradley EL, Kissin I. The effect of pre-incisional infiltration of tonsils with bupivacaine on the pain following tonsillectomy under general anesthesia. *Pain.* 1991;47(3):305-8. DOI: 10.1016/0304-3959(91)90220-R
194. Jebeles JA, Reilly JS, Gutierrez JF, Bradley EL, Kissin I. Tonsillectomy and adenoidectomy pain reduction by local bupivacaine infiltration in children. *Int J Pediatr Otorhinolaryngol.* 1993;25(1-3):149-54. DOI: 10.1016/0165-5876(93)90048-8
195. Goldsher M, Podoshin L, Fradis M, Malatsky S, Gerstel R, Vaida S, Gaitini L. Effects of peritonsillar infiltration on post-tonsillectomy pain. A double-blind study. *Ann Otol Rhinol Laryngol.* 1996 Nov;105(11):868-70.
196. Schoem SR, Watkins GL, Kuhn JJ, Alburger JF, Kim KZ, Thompson DH. Control of early postoperative pain with bupivacaine in adult local tonsillectomy. *Arch Otolaryngol Head Neck Surg.* 1993 Mar;119(3):292-3. DOI: 10.1001/archotol.1993.01880150040007
197. Orntoft S, Løngreen A, Møiniche S, Dhal JB. A comparison of pre- and postoperative tonsillar infiltration with bupivacaine on pain after tonsillectomy. A pre-emptive effect? *Anaesthesia.* 1994 Feb;49(2):151-4. DOI: 10.1111/j.1365-2044.1994.tb03375.x
198. Hollis LJ, Burton MJ, Millar JM. Perioperative local anaesthesia for reducing pain following tonsillectomy. *Cochrane Database Syst Rev.* 2000;(2):CD001874. DOI: 10.1002/14651858.CD001874
199. Fradis M, Goldsher M, David JB, Podoshin L. Life-threatening deep cervical abscess after infiltration of the tonsillar bed for tonsillectomy. *Ear Nose Throat J.* 1998 May;77(5):418-21.
200. Veit S, Müser HG, Böttcher E, Brückner JB. Zeichen einer schweren Myokardischämie nach peritonsillärer Infiltration mit Ornipressin (POR 8) [Signs of a severe myocardial ischemia following peritonsillar infiltration with ornipressin (POR 8)]. *Anaesthesist.* 1993 May;42(5):320-3.
201. Murakawa T, Koh H, Tsubo T, Ishihara H, Matsuki A. [Two cases of circulatory failure after local infiltration of epinephrine during tonsillectomy]. *Masui.* 1998 Aug;47(8):955-62.
202. Tajima K, Sato S, Miyabe M. A case of acute pulmonary edema and bulbar paralysis after local epinephrine infiltration. *J Clin Anesth.* 1997;9:236-38. DOI: 10.1016/S0952-8180(97)00028-7
203. Bean-Lijewski JD. Glossopharyngeal nerve block for pain relief after pediatric tonsillectomy: retrospective analysis and two cases of life-threatening upper airway obstruction from an interrupted trial. *Anesth Analg.* 1997 Jun;84(6):1232-8.
204. Roseburg B. Gaumensegelparesen durch Depotanaesthetie bei Tonsillektomien [Paresis of the soft palate produced by depot anesthesia in tonsillectomy]. *HNO.* 1964 Jul;12:201-5.
205. Richardson GS. Bilateral abductor paralysis of vocal cords during local tonsillectomy; report of a case and its management. *Laryngoscope.* 1953 Dec;63(12):1197-8. DOI: 10.1288/00005537-195312000-00004
206. Neta L. Facial paralysis during local regional (Procaine) anesthesia for total tonsillectomy. *Rev Bras Oto Rhino.* 1949;17:105
207. Alsarraf R, Sie KC. Brain stem stroke associated with bupivacaine injection for adenotonsillectomy. *Otolaryngol Head Neck Surg.* 2000;122(4):572-3. DOI: 10.1016/S0194-5998(00)70103-3
208. Harlowe HD. Congestive heart failure and pulmonary edema following local tonsillectomy. Report of two cases. *Laryngoscope.* 1972 Jan;82(1):139-40.
209. Albrecht W. Über eine tödlich verlaufene Tonsillektomie. *Zentralbl Hals-, Nasen-, Ohren-Hlk.* 1934;35:620
210. Chahine AN, Chiniara J. Cécité bilatérale totale consécutive a une amygdalectomie traitement par la novocaine intraveineuse guérison. *Ann Otolaryngol Chir Cervicofac.* 1951;68:722-6.
211. Ellis PP. Visual loss following tonsillectomy; possible association with injections in tonsillar fossae. *Arch Otolaryngol.* 1968 Apr;87(4):436-8. DOI: 10.1001/archotol.1968.00760060438020
212. Korneev ST. Vremennaia slepota posle tonzilléktomii [Temporary blindness after a tonsillectomy]. *Vestn Otorinolaringol.* 1980 Mar-Apr;(2):70-1.
213. Zhemchyev VI, Chashchina DA, Korzun EP. Kratkovremennaia odnostoronnaia slepota posle tonzillektomii [Short-term unilateral blindness after tonsillectomy]. *Zh Ushn Nos Gori Bolezn.* 1973 Jul-Aug;33(4):103.
214. Forschner L, Loos S. Zur Erklärung der bei der Anästhesierung der Tonsillen vorkommenden Fazialisparese. *Mschr Ohrenheilk.* 1927;61:231.
215. Shlizerman L, Ashkenazi D. Peripheral facial nerve paralysis after peritonsillar infiltration of bupivacaine: a case report. *Am J Otolaryngol.* 2005 Nov-Dec;26(6):406-7. DOI: 10.1016/j.amjoto.2005.02.019
216. Tezel EB. Seltene Komplikationen bei und nach Tonsillektomie. *Zentralbl Hals-, Nasen-, Ohren-Hlk.* 1953;48:327.
217. Stutz E. Fluchtige Facialisparese nach Tonsillektomie [Transient facial paralysis after tonsillectomy]. *HNO.* 1953 Dec;4(3):90.
218. Neto I. Facialislähmung bei Loco-Regionalanästhesie für totale Tonsillektomie. *Zbl Hals-, Nasen-, Ohren-Hlk.* 1951;42:222.
219. Urbantschitsch E. Über Tonsillektomie-Komplikationen. Hypoglossus-Facialis-Parese nach Mandelausschälung. *Wien Med Wochenschr.* 1931;48:1600-2.
220. Gerlings PG. Facialislähmung durch Lokalanästhesie bei Tonsillektomie. *Acta Otolaryngol.* 1932;17(4):420-3. DOI: 10.3109/00016483209134882
221. Fischer G. Rekurrensparese nach Tonsillektomie [Recurrent vocal cord nerve paralysis after tonsillectomy]. *Monatsschr Ohrenheilkd Laryngorhinol.* 1956 Dec;90(6):348-53.
222. Zöllner B, Herrmann IF. Horner-, Hypoglossus- und Rekurrensparese als entzündliche Spätkomplikation nach Tonsillektomie [Horner's syndrome hypoglossal and laryngeal nerve paralyse as inflammatory late complications following tonsillectomy]. *Monatsschr Ohrenheilkd Laryngorhinol.* 1971;105(5):228-32.
223. Del castillo L. Un casi di paralisi degli ultimi quattro nervi cranici consecutiva ad anestesia locale per tonsillectomia. *Zentralbl Hals-, Nasen-, Ohren-Hlk.* 1940;33:263.
224. Baglione L. [Considerations on 2 cases of paralysis of a vocal cord after tonsillectomy]. *Ann Laringol Otol Rinol Faringol.* 1961 Sep-Oct;60:652-63.

225. Weksler N, Nash M, Rozentsveig V, Schwartz JA, Schily M, Gurman GM. Vocal cord paralysis as a consequence of peritonsillar infiltration with bupivacaine. *Acta Anaesthesiol Scand*. 2001 Sep;45(8):1042-4. DOI: 10.1034/j.1399-6576.2001.450820.x
226. Hammer C. Einseitiger Hornerischer Symptomenkomplex nach beiderseitiger Gaumenmandelausschälung. *Klin Monatsbl Augenheilk*. 1933;90:79.
227. Hobson JC, Malla JV, Kay NJ. Horner's syndrome following tonsillectomy. *J Laryngol Otol*. 2006 Sep;120(9):800-1. DOI: 10.1017/S0022215106002209
228. Shissias CG, Golnik KC. Horner's syndrome after tonsillectomy. *Am J Ophthalmol*. 1994 Jun;117(6):812-3.
229. Novoselitskiĭ EM. Sindrom Kloda Bernara-Gornera, vznikshiĭ posle tonzilléktomii [Claude Bernard-Horner syndrome following tonsillectomy]. *Zh Ushn Nos Gorl Bolezn*. 1979 Jul-Aug;(4):82-3.
230. Boku E, Eiton F. Hornerisches Syndrom nach Lokalanästhesie bei der Tonsillektomie. *Zentralbl Hals-, Nasen-, Ohren-Hlk*. 1937;27:620.
231. Kreuzbauer FH. [On a case history of complications after tonsillectomy]. *Monatsschr Ohrenheilkd Laryngorhinol*. 1960 Jun;94:164-8.
232. Link R. Eigenartiger Zwischenfall nach Infiltrationsanästhesie bei Tonsillektomie. *Hals-, Nasen-, Ohrenarzt*. 1941;31:368-72.
233. Malik V, Belloso A, Khwaja S, et al. Posttonsillectomy Horner's Syndrome. *Laryngoscope*. 2006;116:494-5 (withdrawn).
234. Bolliger E. Geschmacksstörungen nach Tonsillektomie. *Zentralbl Hals-, Nasen-, Ohren Hlk*. 1950;40:187-8.
235. Williams MD, Brown HM. The adequacy of gross pathological examination of routine tonsils and adenoids in patients 21 years old and younger. *Hum Pathol*. 2003 Oct;34(10):1053-7. DOI: 10.1053/S0046-8177(03)00408-8
236. Dohar JE, Bonilla JA. Processing of adenoid and tonsil specimens in children: a national survey of standard practices and a five-year review of the experience at the Children's Hospital of Pittsburgh. *Otolaryngol Head Neck Surg*. 1996;115(1):94-7. DOI: 10.1016/S0194-5998(96)70143-2
237. Dost P. Histologie nach Adeno-Tonsillektomie? In Deutschland kein einheitliches Vorgehen bei Patienten bis zum Alter von 10 Jahren [Histology after adenoidectomy/tonsillectomy? No conformity in Germany concerning the histopathological examination of adenoids or tonsils in children up to the age of 10 years]. *HNO*. 2007 Feb;55(2):100-3. DOI: 10.1007/s00106-006-1431-6
238. Kalcioğlu MT, Gurses I, Erdem T. Is the pathological examination of routine tonsillectomy and adenoidectomy specimens necessary? A retrospective study of 559 adenoidectomy and 1132 tonsillectomy specimens and a literature review. *B-ENT*. 2010;6(2):91-5.
239. Alvi A, Vartanian AJ. Microscopic examination of routine tonsillectomy specimens: is it necessary? *Otolaryngol Head Neck Surg*. 1998 Oct;119(4):361-3. DOI: 10.1016/S0194-5998(98)70079-8
240. Dell'Aringa AR, Juarez AJ, Melo C, et al. Histological analysis of tonsillectomy and adenoidectomy specimens - January 2001 to May 2003. *Rev Bras Otorrinolaringol (Engl Ed)*. 2005;71:18-22. DOI: 10.1590/S0034-72992005000100004
241. Erdag TK, Ecevit MC, Guneri EA, Dogan E, Ikiz AO, Sutay S. Pathologic evaluation of routine tonsillectomy and adenoidectomy specimens in the pediatric population: is it really necessary? *Int J Pediatr Otorhinolaryngol*. 2005 Oct;69(10):1321-5. DOI: 10.1016/j.ijporl.2005.05.005
242. Faramarzi A, Ashraf MJ, Hashemi B, Heydari ST, Saif I, Azarpira N, Shishegar M, Eghtedari F, Khademi B, Kaviani M, Kumar PV. Histopathological screening of tonsillectomy and/or adenoidectomy specimens: a report from southern Iran. *Int J Pediatr Otorhinolaryngol*. 2009 Nov;73(11):1576-9. DOI: 10.1016/j.ijporl.2009.08.008
243. Enoki AM, Testa JR, Morais Mde S, Fernandes DP, Tamiso SM. Foreign body in the tonsillary region as a complication of tonsillectomy. *Braz J Otorhinolaryngol*. 2010 Nov-Dec;76(6):796. DOI: 10.1590/S1808-86942010000600022
244. Gündüz K, Celenk P, Kayipmaz S. An unusual foreign body (suturing needle) in the tonsillar region. *J Contemp Dent Pract*. 2004 Nov;5(4):148-54.
245. Sicherheits-Checkliste Chirurgie. Available from: http://www.dgch.de/fileadmin/media/texte_pdf/servicemeldungen/Sicherheitschecklist.pdf
246. OLG München 20.09.1988 24 U 806/87.
247. OLG Saarbrücken U.
248. Leuwer R, Petri S, Schulz F, et al. Todesfälle nach Tonsillektomie und Adenotomie. *LaryngoRhinoOtol*. 1998;77:669-72. DOI: 10.1055/s-2007-997063
249. OLG Celle 07.05.2001 1 U 15/00.
250. BGH 20.09.2011 VI ZR 55/09.
251. Wienke A, Janke K. Anästhesiologische Verantwortlichkeiten bei Nachblutungen nach einer Tonsillektomie. Urteil des OLG München vom 22.01.2009 - 1 U 2357/06 [Anaesthesiological responsibility at bleeding after tonsillectomy]. *Laryngorhinootologie*. 2010 Feb;89(2):100-2. DOI: 10.1055/s-0029-1224114
252. Herrmann A. Gefahren bei den Eingriffen an den Tonsillen und im Rachen. In: *Gefahren bei Operationen an Hals, Ohr und Gesicht und die Korrektur fehlerhafter Eingriffe* Berlin, Heidelberg, New York: Springer; 1968. p. 566-7. DOI: 10.1007/978-3-642-86802-3_13
253. DeFatta RJ, Verret DJ, Bauer P. Extracranial internal carotid artery pseudoaneurysm. *Int J Pediatr Otorhinolaryngol*. 2005 Aug;69(8):1135-9. DOI: 10.1016/j.ijporl.2005.03.001
254. Heyn G, Metz L, Olthoff G. Das Aneurysma der extrakraniellen Arteria carotis interna [Aneurysm of the extracranial internal carotid artery]. *Zentralbl Chir*. 1986;111(21):1312-20.
255. Hoff M, Graumüller S, Pau HW. Arterielle Aneurysmen als Ursache schwallartiger Nachblutungen nach Tonsillektomie [Arterial aneurysms as cause of gushing post-tonsillectomy hemorrhage]. *Laryngorhinootologie*. 2005;84(9):680-2. DOI: 10.1055/s-2005-861400
256. Karas DE, Sawin RS, Sie KC. Pseudoaneurysm of the external carotid artery after tonsillectomy. A rare complication. *Arch Otolaryngol Head Neck Surg*. 1997 Mar;123(3):345-7. DOI: 10.1001/archotol.1997.01900030133017
257. Laage G, Beuthner D. Über eine Carotisaneurysma nach Tonsillektomie und seine plastische Behandlung [Carotid aneurysm following tonsillectomy and its plastic treatment]. *HNO*. 1972 May;20(5):152-3.
258. Maurer J, Beck C, Mann W. Aneurysma der A. lingualis als Ursache wiederholter Spätblutungen nach Tonsillektomie [Aneurysms of the lingual artery as a cause of recurrent late hemorrhage following tonsillectomy]. *Laryngorhinootologie*. 1989;68(5):301-3. DOI: 10.1055/s-2007-998339
259. Menauer F, Suckfüll M, Stäbler A, Grevers G. Pseudoaneurysma der Arteria lingualis nach Tonsillektomie. Eine seltene Komplikation [Pseudoaneurysm of the lingual artery after tonsillectomy. A rare complication]. *Laryngorhinootologie*. 1999;78(7):405-7. DOI: 10.1055/s-2007-996897

260. Mitchell RB, Pereira KD, Lazar RH, Long TE, Fournier NF. Pseudoaneurysm of the right lingual artery: an unusual cause of severe hemorrhage during tonsillectomy. *Ear Nose Throat J*. 1997 Aug;76(8):575-6.
261. Simoni P, Bello JA, Kent B. Pseudoaneurysm of the lingual artery secondary to tonsillectomy treated with selective embolization. *Int J Pediatr Otorhinolaryngol*. 2001;59(2):125-8. DOI: 10.1016/S0165-5876(01)00478-5
262. Tovi F, Leiberman A, Hertzanu Y, Golcman L. Pseudoaneurysm of the internal carotid artery secondary to tonsillectomy. *Int J Pediatr Otorhinolaryngol*. 1987;13(1):69-75. DOI: 10.1016/0165-5876(87)90009-7
263. Pourhassan S, Grotemeyer D, Fokou M, Heinen W, Balzer K, Ramp U, Sandmann W. Extracranial carotid arteries aneurysms in children: single-center experiences in 4 patients and review of the literature. *J Pediatr Surg*. 2007;42(11):1961-8. DOI: 10.1016/j.jpedsurg.2007.07.052
264. van Cruijssen N, Gravendeel J, Dijkers FG. Severe delayed posttonsillectomy haemorrhage due to a pseudoaneurysm of the lingual artery. *Eur Arch Otorhinolaryngol*. 2008;265(1):115-7. DOI: 10.1007/s00405-007-0391-0
265. Veysier P, Biou C, Langman JC, Vilain G. Complication inhabituelle d'une amygdaléctomie [An unusual complication after tonsillectomy]. *Rev Stomatol Chir Maxillofac*. 1976 Sep;77(6):861-4.
266. Walshe P, Ramos E, Low C, et al. An unusual complication of tonsillectomy. *Surgeon*. 2005;3:296-298. DOI: 10.1016/S1479-666X(05)80096-4
267. Weber R, Keerl R, Hendus J, Kahle G. Der Notfall: Das traumatische Aneurysma im Kopf-Hals-Bereich [The emergency: traumatic aneurysm in the area of the head-neck]. *Laryngorhinologie*. 1993;72(2):86-90. DOI: 10.1055/s-2007-997861
268. Windfuhr JP, Sesterhenn AM, Schloendorff G, Kremer B. Post-tonsillectomy pseudoaneurysm: an underestimated entity? *J Laryngol Otol*. 2010;124(1):59-66. DOI: 10.1017/S0022215109990922
269. Juszkat R, Korytowska A, Lukomska Z, Zarzecka A. Facial artery pseudoaneurysm and severe bleeding after tonsillectomy - endovascular treatment with PVA particle embolization. *Pol J Radiol*. 2010 Jan;75(1):88-91.
270. Vávrová M, Slezáček I, Vávra P, Karlová P, Procházka V. Pseudoaneurysm of the left internal carotid artery following tonsillectomy. *VASA*. 2011;40(6):491-4. DOI: 10.1024/0301-1526/a000153
271. Bundesärztekammer. Querschnitts-Leitlinien (BÄK) zur Therapie mit Blutkomponenten und Plasmaderivaten. Available from: http://www.bundesaerztekammer.de/downloads/Querschnittsleitlinie_Gesamtdokument-deutsch_07032011.pdf
272. Heck M, Fresenius M. Repetitorium Anästhesiologie: Für die Facharztprüfung und das Europäische Diplom. 6. Auflage. Berlin, Heidelberg: Springer; 2010.
273. Dressler D, Conrad B. Geschmacksstörungen nach Tonsillektomie. Seltene Komplikation einer häufigen Operation [Taste disorders following tonsillectomy. A rare complication of a common operation]. *Nervenarzt*. 1989 Sep;60(9):572-5.
274. Donati F, Pfammatter JP, Mauderli M, Vassella F. Neurologische Komplikationen nach Tonsillektomie [Neurological complications following tonsillectomy]. *Schweiz Med Wochenschr*. 1991 Nov;121(44):1612-7.
275. Laskiewicz A. Some clinical observations of disturbances of the taste sensation. *Rev Laryngol Otol Rhinol (Bord)*. 1954;75:448-66.
276. Vories AA. Dysgeusia associated with tonsillectomy. *Otolaryngol Head Neck Surg*. 1999;121(3):303-4. DOI: 10.1016/S0194-5998(99)70200-7
277. Bicknell JM, Wiggins RV. Taste disorder from zinc deficiency after tonsillectomy. *West J Med*. 1988 Oct;149(4):457-60.
278. Collet S, Eloy P, Rombaux P, Bertrand B. Taste disorders after tonsillectomy: case report and literature review. *Ann Otol Rhinol Laryngol*. 2005 Mar;114(3):233-6.
279. Fleischer K. Geschmacksverlust nach Tonsillektomie. *Dtsch Med Wochenschr*. 1981;106:1274-5.
280. Fowler R. Stylohyoid ossification, bilateral, and injury of ninth nerve after tonsillectomy. *Laryngoscope*. 1933;43:287-90. DOI: 10.1288/00005537-193304000-00008
281. Berendes J, Theissing G. Geschmacksstörungen nach Tonsillektomie [Ageusia after tonsillectomy]. *HNO*. 1953 Aug;4(1):15-8.
282. Ford LC, Cruz RM. Bilateral glossopharyngeal nerve paralysis after tonsillectomy: case report and anatomic study. *Laryngoscope*. 2004;114(12):2196-9. DOI: 10.1097/01.mlg.0000149457.13877.d5
283. Goins MR, Pitovski DZ. Posttonsillectomy taste distortion: a significant complication. *Laryngoscope*. 2004;114(7):1206-13. DOI: 10.1097/00005537-200407000-00015
284. Rieder C. Eine seltene Komplikation: Geschmacksstörung nach Tonsillektomie. *Laryngol Rhinol Otol*. 1981;60:342. DOI: 10.1055/s-2007-1008734
285. Gessini L, Valente V. Nevralgia del linguale ed ageusia permanente dopo tonsillectomia. Caso clinico [Lingual neuralgia and permanent ageusia after tonsillectomy. Clinical case]. *Ann Laringol Otol Rinol Faringol*. 1966 Sep-Oct;65(5):650-3.
286. Holzlöhner. Geschmacksstörungen nach Operationen im Mund- und Rachenbereich. *HNO*. 1956;6:91-2.
287. Beck C. N. glossopharyngeus und Tonsillektomie. *Laryngol Rhinol Otol*. 1979;58:463-5.
288. Haas E. Kasuistischer Beitrag zum Thema: Geschmacksstörungen nach Tonsillektomie [Casuistic contribution to the topic of parosmia after tonsillectomy]. *Z Laryngol Rhinol Otol*. 1953 Jul-Aug;32(7-8):413-4.
289. Dehnen T. Geschmacksstörungen nach Tonsillektomie [Gustatory disorders following tonsillectomy]. *Z Laryngol Rhinol Otol*. 1950 Nov;29(11):546-51.
290. Uzun C, Adali MK, Karasalioglu AR. Unusual complication of tonsillectomy: taste disturbance and the lingual branch of the glossopharyngeal nerve. *J Laryngol Otol*. 2003;117(4):314-7. DOI: 10.1258/00222150360600968
291. Vories AA. Dysgeusia associated with tonsillectomy. *Otolaryngol Head Neck Surg*. 1999;121(3):303-4. DOI: 10.1016/S0194-5998(99)70200-7
292. Goins MR, Pitovski DZ. Posttonsillectomy taste distortion: a significant complication. *Laryngoscope*. 2004;114(7):1206-13. DOI: 10.1097/00005537-200407000-00015
293. Arnhold-Schneider M, Bernemann D. Über die Häufigkeit von Geschmacksstörungen nach Tonsillektomie [Incidence of taste disorders following tonsillectomy]. *HNO*. 1987 May;35(5):195-8.
294. Tomofuji S, Sakagami M, Kushida K, Terada T, Mori H, Kakibuchi M. Taste disturbance after tonsillectomy and laryngomicrosurgery. *Auris Nasus Larynx*. 2005 Dec;32(4):381-6. DOI: 10.1016/j.anl.2005.05.005
295. Sakuma A, Kobayashi Y, Takahashi F. Taste disorders after tonsillectomy. *Jpn J Tonsil*. 1990;29:99-103.

296. Tarab S. Troubles de la gustation apres tonsillectomie. *Pract Otorhinolaryngol*. 1955;17:260-2.
297. Müller CA, Khatib S, Landis BN, et al. Gustatory function after tonsillectomy. *Arch Otolaryngol Head Neck Surg*. 2007;133.
298. Oluwasanmi AF. Unusual complication of tonsillectomy: taste disturbance and the lingual branch of the glossopharyngeal nerve. *J Laryngol Otol*. 2004;118:248-249.
299. Uzun C, Adali MK, Karasalihoglu AR. Unusual complication of tonsillectomy: taste disturbance and the lingual branch of the glossopharyngeal nerve. *J Laryngol Otol*. 2003;117(4):314-7. DOI: 10.1258/00222150360600968
300. Tomita H, Ohtuka K. Taste disturbance after tonsillectomy. *Acta Otolaryngol Suppl*. 2002;(546):164-72. DOI: 10.1080/00016480260046571
301. Lowe DA, Hajioff D, Jayaraj SM, et al. Taste disturbance following adult tonsillectomy. *CME Bull Otorhinolaryngol Head Neck Surg*. 2002;6:102-103.
302. Heiser C, Landis BN, Giger R, Cao Van H, Guinand N, Hörmann K, Stuck BA. Taste disorders after tonsillectomy: a long-term follow-up. *Laryngoscope*. 2012;122(6):1265-6. DOI: 10.1002/lary.23270
303. Heiser C, Landis BN, Giger R, Cao Van H, Guinand N, Hörmann K, Stuck BA. Taste disturbance following tonsillectomy—a prospective study. *Laryngoscope*. 2010;120(10):2119-24. DOI: 10.1002/lary.20971
304. Stathas T, Mallis A, Naxakis S, Mastronikolis NS, Gkiogkis G, Xenoudakis D, Armenakis NS, Goumas PD. Taste function evaluation after tonsillectomy: a prospective study of 60 patients. *Eur Arch Otorhinolaryngol*. 2010;267(9):1403-7. DOI: 10.1007/s00405-010-1224-0
305. Windfuhr JP, Sack F, Sesterhenn AM, Landis BN, Chen YS. Post-tonsillectomy taste disorders. *Eur Arch Otorhinolaryngol*. 2010;267(2):289-93. DOI: 10.1007/s00405-009-1057-x
306. Mueller C, Kallert S, Renner B, Stiassny K, Temmel AF, Hummel T, Kobal G. Quantitative assessment of gustatory function in a clinical context using impregnated "taste strips". *Rhinology*. 2003 Mar;41(1):2-6.
307. Ohtsuka K, Tomita H, Murakami G. Anatomy of the tonsillar bed: topographical relationship between the palatine tonsil and the lingual branch of the glossopharyngeal nerve. *Acta Otolaryngol Suppl*. 2002;(546):99-109. DOI: 10.1080/00016480260046472
308. Windfuhr JP, Cao Van H, Landis BN. Recovery from long-lasting post-tonsillectomy dysgeusia. *Oral Surg Oral Med Oral Pathol Oral Radiol Endod*. 2010 Jan;109(1):e11-4. DOI: 10.1016/j.tripleo.2009.08.031
309. Wienke A. Schädigung des Geschmackesempfindens und Aufklärungsumfang bei Tonsillektomien [Impairment of taste perception and extent of patient education in tonsillectomy]. *Laryngorhinootologie*. 1992 Sep;71(9):487-8. DOI: 10.1055/s-2007-997339
310. Hultcrantz E. Personal communication.
311. Personal communication of the surgeon.
312. Boy, 5, dies following tonsil surgery. Available from: <http://www.youtube.com/watch?v=gk5rQEUpJU>
313. Cohen D, Dor M. Morbidity and mortality of post-tonsillectomy bleeding: analysis of cases. *J Laryngol Otol*. 2007;1-5.
314. Pratt LW, Gallagher RA. Tonsillectomy and adenoidectomy: incidence and mortality, 1968–1972. *Otolaryngol Head Neck Surg*. 1979 Mar-Apr;87(2):159-66.
315. Pratt LW. Tonsillectomy and adenoidectomy: mortality and morbidity. *Trans Am Acad Ophthalmol Otolaryngol*. 1970 Nov-Dec;74(6):1146-54.
316. Becker W. Erfahrungen als Gutachter bei Vorwürfen wegen mangelnder Aufklärung und Fahrlässigkeit. *Laryngol Rhinol*. 1974;53.
317. Lackner F, Slatin HP. Zwei Fälle von Gefäßkomplikation nach Tonsillektomie [2 cases of vascular complications following tonsillectomy]. *Monatsschr Ohrenheilkd Laryngorhinol*. 1970;104(3):130-5.
318. Zweighaft JF. Hemiplegia following tonsillectomy. *Anesthesiology*. 1949 Nov;10(6):729-32. DOI: 10.1097/0000542-194911000-00008
319. Sonne JE, Kim SB, Frank DK. Cervical necrotizing fasciitis as a complication of tonsillectomy. *Otolaryngol Head Neck Surg*. 2001;125(6):670-2. DOI: 10.1067/mhn.2001.119970
320. Sagowski C, Koch U. Lemierre-Syndrom. Septische Jugularvenenthrombose nach Tonsillektomie [Lemierre syndrome: thrombosis of the internal jugular vein after tonsillectomy]. *HNO*. 2004 Mar;52(3):251-4. DOI: 10.1007/s00106-003-0846-6
321. Nix PA. Jugular thrombosis following tonsillectomy. *J Laryngol Otol*. 2001 Mar;115(3):238-9. DOI: 10.1258/0022215011907082
322. Reilly MJ, Milmo G, Pena M. Three extraordinary complications of adenotonsillectomy. *Int J Pediatr Otorhinolaryngol*. 2006;70(5):941-6. DOI: 10.1016/j.ijporl.2005.09.023
323. Baker LL, Bower CM, Glasier CM. Atlanto-axial subluxation and cervical osteomyelitis: two unusual complications of adenoidectomy. *Ann Otol Rhinol Laryngol*. 1996 Apr;105(4):295-9.
324. Bocciolini C, Dall'Olio D, Cunsolo E, Cavazzuti PP, Laudadio P. Grisel's syndrome: a rare complication following adenoidectomy. *Acta Otorhinolaryngol Ital*. 2005 Aug;25(4):245-9.
325. Dagtekin A, Kara E, Vayisoglu Y, Koseoglu A, Avci E, Talas D, Bagdatoglu C. The importance of early diagnosis and appropriate treatment in Grisel's syndrome: report of two cases. *Turk Neurosurg*. 2011;21(4):680-4. DOI: 10.5137/1019-5149.JTN.3120-10.1
326. Feldmann H, Meister EF, Küttner K. Aus der Gutachtenpraxis: Atlantoaxiale Subluxation mit spastischem Schiefhals (Grisel-Syndrom) nach Adenotomie bzw. Tonsillektomie am hängenden Kopf - Fehler des Operateurs oder des Anästhesisten [From the expert's office. Atlanto-axial subluxation with spastic torticollis after adenoid-ectomy resp. tonsillectomy in rose position - malpractice of the surgeon or the anaesthesiologist?]. *Laryngorhinootologie*. 2003 Nov;82(11):799-804. DOI: 10.1055/s-2003-44536
327. Yu KK, White DR, Weissler MC, Pillsbury HC. Nontraumatic atlantoaxial subluxation (Grisel syndrome): a rare complication of otolaryngological procedures. *Laryngoscope*. 2003;113(6):1047-9. DOI: 10.1097/00005537-200306000-00024
328. Durst F, Staudenmaier R, Pilge H, Lauen J, Prodingler P, Holzapfel K, Pickhard A. Grisel-Syndrom nach Anthelexplastik [Grisel's syndrome after otoplasty]. *HNO*. 2012;60(2):135-40. DOI: 10.1007/s00106-011-2315-y
329. Samuel D, Thomas DM, Tierney PA, Patel KS. Atlanto-axial subluxation (Grisel's syndrome) following otolaryngological diseases and procedures. *J Laryngol Otol*. 1995 Oct;109(10):1005-9. DOI: 10.1017/S0022215100131883
330. The Result of Tonsillectomy on the Health of Children. *Can Med Assoc J*. 1924 Aug;14(8):745.
331. Rudack C, Eikenbusch G, Stoll W, Hermann W. Therapeutisches Management nekrotisierender Weichteilinfektionen des Halses [Therapeutic management of necrotizing neck infections]. *HNO*. 2003 Dec;51(12):986-92. DOI: 10.1007/s00106-003-0854-6

332. Tami TA, Burkus JK, Strom CG. Cervical osteomyelitis. An unusual complication of tonsillectomy. *Arch Otolaryngol Head Neck Surg.* 1987 Sep;113(9):992-4. DOI: 10.1001/archotol.1987.01860090090027
333. Sancho LM, Minamoto H, Fernandez A, Sennes LU, Jatene FB. Descending necrotizing mediastinitis: a retrospective surgical experience. *Eur J Cardiothorac Surg.* 1999;16(2):200-5. DOI: 10.1016/S1010-7940(99)00168-2
334. Kaiser A. Results of tonsillectomy. A comparative study of twenty-two hundred tonsillectomized children with an equal number of controls three and ten years after operation. *JAMA.* 1930;95:837-842. DOI: 10.1001/jama.1930.02720120005003
335. Bonding P. Tonsillectomy à chaud. *J Laryngol Otol.* 1973 Dec;87(12):1171-82. DOI: 10.1017/S0022215100078142
336. Nielsen VM, Greisen O. Peritonsillar abscess. II. Cases treated with tonsillectomy à chaud. *J Laryngol Otol.* 1981 Aug;95(8):805-7.
337. Nielsen VM, Greisen O. Peritonsillar abscess. I. Cases treated by incision and drainage: a follow-up investigation. *J Laryngol Otol.* 1981 Aug;95(8):801-5. DOI: 10.1017/S0022215100091441
338. OLG Karlsruhe 08.03.1974 7 U 171/71.
339. Riemann M. "Resttonsillen"-ein Kunstfehler oder eine irreführende Bezeichnung? *HNO-Mitteilungen.* 1996;46:19-20.
340. Lehmann K. *Der postoperative Schmerz. Bedeutung, Diagnose und Behandlung.* Berlin, Heidelberg: Springer; 1990. DOI: 10.1007/978-3-662-06539-6
341. Cardwell M, Siviter G, Smith A. Non-steroidal anti-inflammatory drugs and perioperative bleeding in paediatric tonsillectomy. *Cochrane Database Syst Rev.* 2005;(2):CD003591. DOI: 10.1002/14651858.CD003591.pub2
342. Møiniche S, Rømsing J, Dahl JB, Tramèr MR. Nonsteroidal anti-inflammatory drugs and the risk of operative site bleeding after tonsillectomy: a quantitative systematic review. *Anesth Analg.* 2003 Jan;96(1):68-77, table of contents. DOI: 10.1213/00000539-200301000-00015
343. Krishna S, Hughes LF, Lin SY. Postoperative hemorrhage with nonsteroidal anti-inflammatory drug use after tonsillectomy: a meta-analysis. *Arch Otolaryngol Head Neck Surg.* 2003;129(10):1086-9. DOI: 10.1001/archotol.129.10.1086
344. Iyer S, DeFoor W, Grocela J, Kamholz K, Varughese A, Kenna M. The use of perioperative antibiotics in tonsillectomy: does it decrease morbidity? *Int J Pediatr Otorhinolaryngol.* 2006;70(5):853-61. DOI: 10.1016/j.ijporl.2005.09.021
345. Mathew R, Asimacopoulos E, Walker D, Gutierrez T, Valentine P, Pitkin L. Analysis of clinical negligence claims following tonsillectomy in England 1995 to 2010. *Ann Otol Rhinol Laryngol.* 2012 May;121(5):337-40.
346. Nuara MJ, Park AH, Alder SC, Smith ME, Kelly S, Muntz H. Perioral burns after adenotonsillectomy: a potentially serious complication. *Arch Otolaryngol Head Neck Surg.* 2008 Jan;134(1):10-5. DOI: 10.1001/archoto.2007.5
347. Wienke A. Hypoglossusparese nach beidseitiger Tonsillektomie [Paralysis of the hypoglossal nerve after bilateral tonsillectomy]. *Laryngorhinootologie.* 1992 Jun;71(6):332-3. DOI: 10.1055/s-2007-997307
348. Betow K. Ein Fall von Arrosionsblutung nach Tonsillektomie (Communisunterbindung) [A case of erosion hemorrhage after tonsillectomy (ligation of the common carotid artery)]. *Z Laryngol Rhinol Otol.* 1964 May;43:296-300.
349. Simonsen AR, Duncavage JA, Becker SS. A review of malpractice cases after tonsillectomy and adenoidectomy. *Int J Pediatr Otorhinolaryngol.* 2010;74(9):977-9. DOI: 10.1016/j.ijporl.2010.05.029
350. Nuara MJ, Park AH, Alder SC, Smith ME, Kelly S, Muntz H. Perioral burns after adenotonsillectomy: a potentially serious complication. *Arch Otolaryngol Head Neck Surg.* 2008;134(1):10-5. DOI: 10.1001/archoto.2007.5
351. Zinder DJ, Parker GS. Electrocautery burns and operator ignorance. *Otolaryngol Head Neck Surg.* 1996;115(1):145-9. DOI: 10.1016/S0194-5998(96)70152-3
352. Shah UK. A simple suggestion to reduce perioral burns during adenotonsillectomy. *Arch Otolaryngol Head Neck Surg.* 2008 Jun;134(6):673. DOI: 10.1001/archotol.134.6.673-b
353. Mistry D, Kelly G. Consent for tonsillectomy. *Clin Otolaryngol Allied Sci.* 2004;29(4):362-8. DOI: 10.1111/j.1365-2273.2004.00818.x
354. Monroy A, Behar P, Brodsky L. Revision adenoidectomy—a retrospective study. *Int J Pediatr Otorhinolaryngol.* 2008 May;72(5):565-70. DOI: 10.1016/j.ijporl.2008.01.008
355. Morris LG, Lieberman SM, Reitzen SD, Edelstein DR, Ziff DJ, Katz A, Komisar A. Characteristics and outcomes of malpractice claims after tonsillectomy. *Otolaryngol Head Neck Surg.* 2008 Mar;138(3):315-20. DOI: 10.1016/j.otohns.2007.11.024
356. Nikoghosyan-Bossen G, Hauberg A, Homøe P. Systematic analysis of ear-nose-throat malpractice complaints may be beneficial for patient safety. *Dan Med J.* 2012 May;59(5):A4422.
357. Matthias C. Chirurgie des Nasenseptums und der Nasenmuscheln [Surgery of the nasal septum and turbinates]. *Laryngorhinootologie.* 2007 Apr;86 Suppl 1:S1-14. DOI: 10.1055/s-2007-966303
358. Baumann I. Septumplastik - ein Update [Septoplasty update]. *Laryngorhinootologie.* 2010 Jun;89(6):373-84. DOI: 10.1055/s-0030-1252057
359. Hellmich S. Septumplastik [Septoplasty]. *Laryngorhinootologie.* 1997 Nov;76(11):663-6. DOI: 10.1055/s-2007-997502
360. Mlynski G. Gestörte Funktion der oberen Atemwege. Wiederherstellende Verfahren der gestörten Funktion der oberen Atemwege, Nasale Atmung [Impaired function of the upper respiratory tract. Restorative procedures for upper airway dysfunction, nasal breathing]. *Laryngorhinootologie.* 2005 May;84 Suppl 1:S101-17. DOI: 10.1055/s-2005-861133
361. Schultz-Coulon HJ. Anmerkungen zur Septumplastik [Comments on septoplasty]. *HNO.* 2006 Jan;54(1):59-69; quiz 70. DOI: 10.1007/s00106-005-1355-6
362. Siegel NS, Gliklich RE, Taghizadeh F, Chang Y. Outcomes of septoplasty. *Otolaryngol Head Neck Surg.* 2000;122(2):228-32. DOI: 10.1016/S0194-5998(00)70244-0
363. Neumann A, Lehmann N, Stange T, Unkel C, Pearson MD, Gostian T, Jahnke K, Schultz-Coulon HJ. Ergebnisse einer Umfrage zur Patientenzufriedenheit nach Nasenseptumplastik und Muschelbehandlung [Patients' satisfaction after nasal septal and turbinate surgery. Results of a questionnaire]. *Laryngorhinootologie.* 2007 Oct;86(10):706-13. DOI: 10.1055/s-2007-966196
364. Stewart MG, Smith TL, Weaver EM, Witsell DL, Yueh B, Hannley MT, Johnson JT. Outcomes after nasal septoplasty: results from the Nasal Obstruction Septoplasty Effectiveness (NOSE) study. *Otolaryngol Head Neck Surg.* 2004 Mar;130(3):283-90. DOI: 10.1016/j.otohns.2003.12.004
365. Cottle MH, Loring RM, Fischer GG, Gaynon IE. The maxilla-premaxilla approach to extensive nasal septum surgery. *AMA Arch Otolaryngol.* 1958 Sep;68(3):301-13. DOI: 10.1001/archotol.1958.00730020311003
366. OLG Stuttgart 14.11.1996 14 U 6/96.
367. OLG Frankfurt 13.04.1989 1 U 97/88.

368. Baumann I, Baumann H. A new classification of septal deviations. *Rhinology*. 2007 Sep;45(3):220-3.
369. Guyuron B, Uzzo CD, Scull H. A practical classification of septonasal deviation and an effective guide to septal surgery. *Plast Reconstr Surg*. 1999 Dec;104(7):2202-9; discussion 2210-2.
370. Sciuto S, Bernardeschi D. Excision and replacement of nasal septum in aesthetic and functional nose surgery: setting criteria and establishing indications. *Rhinology*. 1999 Jun;37(2):74-9.
371. Masing H. *Chirurgie des Nasenseptums*. Stuttgart: Thieme; 1977.
372. LG Bremen 27.05.1993 8 O 2775/90.
373. Rettinger G. *HNO-Operationslehre. Mit allen wichtigen Eingriffen*. 4.Auflage. Stuttgart/New York: Thieme; 2006.
374. Rettinger G, Kirsche H. Complications in septoplasty. *Facial Plast Surg*. 2006 Nov;22(4):289-97. DOI: 10.1055/s-2006-954847
375. LG Berlin 20.08.2003 6 O 343/02.
376. Sautter NB, Smith TL. Endoscopic septoplasty. *Otolaryngol Clin North Am*. 2009 Apr;42(2):253-60, viii. DOI: 10.1016/j.otc.2009.01.010
377. Hwang PH, McLaughlin RB, Lanza DC, Kennedy DW. Endoscopic septoplasty: indications, technique, and results. *Otolaryngol Head Neck Surg*. 1999;120(5):678-82. DOI: 10.1053/hn.1999.v120.a93047
378. Gubisch W. Extracorporeal septoplasty for the markedly deviated septum. *Arch Facial Plast Surg*. 2005 Jul-Aug;7(4):218-26. DOI: 10.1001/archfaci.7.4.218
379. Gubisch W. Twenty-five years experience with extracorporeal septoplasty. *Facial Plast Surg*. 2006 Nov;22(4):230-9. DOI: 10.1055/s-2006-954841
380. Gubisch W, Constantinescu MA. Refinements in extracorporeal septoplasty. *Plast Reconstr Surg*. 1999 Sep;104(4):1131-9; discussion 1140-2.
381. Boenisch M, Tamás H, Nolst Trenité GJ. Influence of polydioxanone foil on growing septal cartilage after surgery in an animal model: new aspects of cartilage healing and regeneration (preliminary results). *Arch Facial Plast Surg*. 2003 Jul-Aug;5(4):316-9. DOI: 10.1001/archfaci.5.4.316
382. Boenisch M, Nolst Trenité GJ. Reconstruction of the nasal septum using polydioxanone plate. *Arch Facial Plast Surg*. 2010 Jan-Feb;12(1):4-10. DOI: 10.1001/archfacial.2009.103
383. Boenisch M, Nolst Trenité GJ. Reconstructive septal surgery. *Facial Plast Surg*. 2006 Nov;22(4):249-54. DOI: 10.1055/s-2006-954843
384. Petropoulos I, Nolst Trenité G, Boenisch M, Nousios G, Kontzoglou G. External septal reconstruction with the use of polydioxanone foil: our experience. *Eur Arch Otorhinolaryngol*. 2006;263(12):1105-8. DOI: 10.1007/s00405-006-0127-6
385. Mayer B, Henkes H. Miniseptumplastik-für Funktion und Form [Mini-septoplasty-for function and form]. *Laryngorhinootologie*. 1990 Jun;69(6):303-7. DOI: 10.1055/s-2007-998195
386. Kamami YV, Pandraud L, Bougara A. Laser-assisted outpatient septoplasty: results in 703 patients. *Otolaryngol Head Neck Surg*. 2000 Mar;122(3):445-9.
387. Leclère FM, Petropoulos I, Buys B, Mordon S. Laser assisted septal cartilage reshaping (LASCR): A prospective study in 12 patients. *Lasers Surg Med*. 2010;42(8):693-8. DOI: 10.1002/lsm.20958
388. Huizing E, de Groot J. *Functional reconstructive nasal surgery*. Stuttgart, New York: Thieme; 2003.
389. Windfuhr JP, Chen YS, Güldner C, Neukirch D. Rib cartilage harvesting in rhinoplasty procedures based on CT radiological data. *Acta Otolaryngol*. 2011;131(1):67-71. DOI: 10.3109/00016489.2010.502185
390. Jang YJ, Yeo NK, Wang JH. Cutting and suture technique of the caudal septal cartilage for the management of caudal septal deviation. *Arch Otolaryngol Head Neck Surg*. 2009;135(12):1256-60. DOI: 10.1001/archoto.2009.171
391. Pirsig W. Die Regeneration des kindlichen Septumknorpels nach Septumplastiken. Eine histologische Studi [Regeneration of septal cartilage in children after septoplasty. A histological study]. *Acta Otolaryngol*. 1975 May-Jun;79(5-6):451-9. DOI: 10.3109/00016487509124711
392. Pirsig W. Septal plasty in children: influence on nasal growth. *Rhinology*. 1977 Dec;15(4):193-204.
393. Pirsig W. Operative Eingriffe an der kindlichen Nase. In: Berendes J, Link F, Zöllner F, eds. *Hals-Nasen-Ohren-Heilkunde in Praxis und Klinik*. Stuttgart:Thieme; 1977. p. 28-39.
394. Pirsig W, Kern EB, Verse T. Reconstruction of anterior nasal septum: back-to-back autogenous ear cartilage graft. *Laryngoscope*. 2004;114(4):627-38. DOI: 10.1097/00005537-200404000-00007
395. Monteiro ML. Unilateral blindness as a complication of nasal septoplasty: case report. *Arq Bras Oftalmol*. 2006 Mar-Apr;69(2):249-50. DOI: 10.1590/S0004-27492006000200020
396. Shihada R, Fradis M, Vardizer Y, Braun J, Luntz M. Unilateral blindness following septoplasty. *Ann Otol Rhinol Laryngol*. 2008 Jul;117(7):528-30.
397. Heermann J. Temporäre Amaurose bei mikrochirurgischer endonasaler Ethmoid- und Saccus-lacrimalis-Operation in Lokalanästhesie. *Laryngo Rhino Otol*. 1980;59:433-7. DOI: 10.1055/s-2007-1008882
398. BGH VI ZR 217/91.
399. OLG Nürnberg 09.04.1991 3 U 2178/90.
400. Rettinger G, Christ P, Meythaler FH. Erblindung durch Zentralarterienverschluss nach Septumkorrektur [Blindness caused by central artery occlusion following nasal septum correction]. *HNO*. 1990 Mar;38(3):105-9.
401. Schwalm JD, Hamstra J, Mulji A, Velianou JL. Cardiogenic shock following nasal septoplasty: a case report and review of the literature. *Can J Anaesth*. 2008;55(6):376-9. DOI: 10.1007/BF03021494
402. Stoksted P, Vase P. Perforations of the nasal septum following operative procedures. *Rhinology*. 1978 Sep;16(3):123-38.
403. Onerci TM, Ayhan K, Oğretmenoğlu O. Two consecutive cases of cerebrospinal fluid rhinorrhea after septoplasty operation. *Am J Otolaryngol*. 2004 Sep-Oct;25(5):354-6. DOI: 10.1016/j.amjoto.2004.03.005
404. Schwab JA, Pirsig W. Complications of septal surgery. *Facial Plast Surg*. 1997;13(1):3-14. DOI: 10.1055/s-2008-1064461
405. Wienke A, Mündnich A. Schmerzensgeld bei vergessener Tamponade [Compensation in forgotten tamponade]. *Laryngorhinootologie*. 2011 Aug;90(8):489-90. DOI: 10.1055/s-0031-1277221
406. Bateman ND, Woolford TJ. Informed consent for septal surgery: the evidence-base. *J Laryngol Otol*. 2003;117(3):186-9. DOI: 10.1258/002221503321192476
407. Kaygusuz I, Kizirgil A, Karlidağ T, Yalçın S, Keles E, Yakupoğullari Y, Alpay C. Bacteriemia in septoplasty and septorhinoplasty surgery. *Rhinology*. 2003 Jun;41(2):76-9.
408. Leonard DW, Thompson DH. Unusual septoplasty complication: *Streptococcus viridans* endocarditis. *Ear Nose Throat J*. 1998;77:827, 830-1.

409. Fjermedal O, Saunte C, Pedersen S. Septoplasty and/or submucous resection? 5 years nasal septum operations. *J Laryngol Otol*. 1988 Sep;102(9):796-8. DOI: 10.1017/S0022215100106486
410. Koçak A, Gürlek A, Kutlu R, Celbiş O, Aydın NE. An unusual complication of septorhinoplasty: massive subarachnoid hemorrhage. *Ann Plast Surg*. 2004 Nov;53(5):492-5. DOI: 10.1097/01.sap.0000120290.25592.2f
411. Riederer A, Wilmes E. Eine seltene Komplikation der Septumoperation: Arteria interna-Sinus cavernosus-Fistel. *Laryngo Rhino Otol*. 1978;66:583-5. DOI: 10.1055/s-2007-998740
412. Miller T. Immediate postoperative complications of septoplasties and septorhinoplasties. *Trans Pac Coast Otoophthalmol Soc Annu Meet*. 1976;57:201-5.
413. Tzadik A, Gilbert SE, Sade J. Complications of submucous resections of the nasal septum. *Arch Otorhinolaryngol*. 1988;245(2):74-6. DOI: 10.1007/BF00481439
414. Muhammad IA, Nabil-ur Rahman . Complications of the surgery for deviated nasal septum. *J Coll Physicians Surg Pak*. 2003 Oct;13(10):565-8. DOI: 10.2003/JCPSP.565568
415. White A, Murray JA. Intranasal adhesion formation following surgery for chronic nasal obstruction. *Clin Otolaryngol Allied Sci*. 1988;13:139-143. DOI: 10.1111/j.1365-2273.1988.tb00754.x
416. OLG München 22.12.2011 1 U 2466/11.
417. Vuyk HD, Langenhuijsen KJ. Aesthetic sequelae of septoplasty. *Clin Otolaryngol Allied Sci*. 1997;22:226-32. DOI: 10.1046/j.1365-2273.1997.00035.x
418. Stevens CN, Stevens MH. Quantitative effects of nasal surgery on olfaction. *Am J Otolaryngol*. 1985;6:264-7. DOI: 10.1016/S0196-0709(85)80053-3
419. Kimmelman CP. The risk to olfaction from nasal surgery. *Laryngoscope*. 1994;104(8 Pt 1):981-8. DOI: 10.1288/00005537-199408000-00012
420. MacDougall G, Sanderson RJ. Altered dental sensation following intranasal surgery. *J Laryngol Otol*. 1993 Nov;107(11):1011-3. DOI: 10.1017/S0022215100125125
421. Rettinger G, Engelbrecht-Schnür S. Palatinale Gefühlsstörungen nach Septumkorrektur [Palatal sensory impairment after setoplasty]. *Laryngorhinootologie*. 1995 May;74(5):282-5. DOI: 10.1055/s-2007-997740
422. Issing PR, Ernst A, Heermann R, Lenarz T. Zahnverfärbung als seltene Komplikation einer Septorhinoplastik [Tooth discoloration as a rare complication of septorhinoplasty]. *Laryngorhinootologie*. 1996 Jan;75(1):59-62. DOI: 10.1055/s-2007-997534
423. Spillman D. Medico-legaler Beitrag zum Thema Fremdkörperaspiration. Aspiration von Nasentamponaden mit Todesfolge. *Laryngol Rhinol Otol (Stuttg)*. 1981;60:56 DOI: 10.1055/s-2007-1008673
424. Minnigerode B. Hirnanoxie mit Todesfolge durch Aspiration von Nasentamponade [Cerebral anoxia with a fatal sequela caused by aspiration of a nasal tamponade]. *HNO*. 1984 Dec;32(12):521-2.
425. Koudounarakis E, Chatzakis N, Papadakis I, Panagiotaki I, Velegarakis G. Nasal packing aspiration in a patient with Alzheimer's disease: a rare complication. *Int J Gen Med*. 2012;5:643-5. DOI: 10.2147/IJGM.S34676
426. Robbins KT, Clayman G, Levine PA, Medina J, Sessions R, Shaha A, Som P, Wolf GT; American Head and Neck Society; American Academy of Otolaryngology-Head and Neck Surgery. Neck dissection classification update: revisions proposed by the American Head and Neck Society and the American Academy of Otolaryngology-Head and Neck Surgery. *Arch Otolaryngol Head Neck Surg*. 2002 Jul;128(7):751-8. DOI: 10.1001/archotol.128.7.751
427. Werner J. Lymphknotenerkrankungen im Kopf-Hals-Bereich. *Onkologie und Differenzialdiagnostik*. Berlin, Heidelberg, New York: Springer; 2002. DOI: 10.1007/978-3-642-55923-5
428. Hao SP, Chang PT. Stress fracture of the clavicle after selective neck dissection. *Otolaryngol Head Neck Surg*. 1998 May;118(5):732-3.
429. Ord RA, Langdon JD. Stress fracture of the clavicle. A rare late complication of radical neck dissection. *J Maxillofac Surg*. 1986;14(5):281-4. DOI: 10.1016/S0301-0503(86)80305-8
430. Denecke H. Die oto-rhino-laryngologischen Operationen im Mund- und Halsbereich. *Operationslehre V*. Berlin, Heidelberg, New York: Springer; 1980.
431. Thumfart W, Platzer W, Gunkel A, et al. *Operative Zugangswege in der HNO-Heilkunde*. Stuttgart, New York: Thieme; 1998.
432. Werner J. *HNO-Operationslehre. Mit allen wichtigen Eingriffen*. Stuttgart, New York: Thieme; 2006.
433. AWMF. Hodgkin-Lymphom. Interdisziplinäre Leitlinie der Deutschen Krebsgesellschaft und der Gesellschaft für Pädiatrische Onkologie und Hämatologie. Available from: http://www.awmf.org/uploads/tx_szleitlinien/025-012_S1_Hodgkin-Lymphom_abgelaufen.pdf
434. AWMF. Non-Hodgkin-Lymphom. Interdisziplinäre Leitlinie der Deutschen Krebsgesellschaft und der Gesellschaft für Pädiatrische Onkologie und Hämatologie. Available from: http://www.awmf.org/uploads/tx_szleitlinien/025-013_S1_Non-Hodgkin-Lymphome_abgelaufen.pdf
435. AWMF. Lymphadenitis. Leitlinie der Deutschen Gesellschaft für Mund-Kiefer-Gesichtschirurgie. Available from: http://www.awmf.org/uploads/tx_szleitlinien/007-087_S2_Lymphadenitis_abgelaufen.pdf
436. Griffith DE, Aksamit T, Brown-Elliott BA, Catanzaro A, Daley C, Gordin F, Holland SM, Horsburgh R, Huitt G, Iademarco MF, Iseman M, Olivier K, Ruoss S, von Reyn CF, Wallace RJ Jr, Winthrop K; ATS Mycobacterial Diseases Subcommittee; American Thoracic Society; Infectious Disease Society of America. An official ATS/IDSA statement: diagnosis, treatment, and prevention of nontuberculous mycobacterial diseases. *Am J Respir Crit Care Med*. 2007 Feb;175(4):367-416. DOI: 10.1164/rccm.200604-571ST
437. OLG Düsseldorf 21.05.1992 8 U 16/90.
438. Prim MP, De Diego JI, Verdaguer JM, Sastre N, Rabanal I. Neurological complications following functional neck dissection. *Eur Arch Otorhinolaryngol*. 2006;263(5):473-6. DOI: 10.1007/s00405-005-1028-9
439. Ferencsik M, Piukovics K, Borbényi Z, Varga G. Perifériás idegek sérülése, mint a diagnosztikus nyaki nyirokcsomó excisio ritka szövödménye [Peripheral nerve injuries as a rare complication of cervical lymph node excision for diagnostic purposes]. *Orv Hetil*. 1990 Jul;131(27):1465-7.
440. OLG Frankfurt 23.11.1954 1 U 89/53.
441. OLG Frankfurt 24.01.1980 9 U 38/79.
442. OLG Dresden 18.09.1997 4 U 1165/1197.
443. LG Bremen 21.05.1987 2 O 1977/84.
444. OLG Köln 06.08.1981 7 U 105/80.

445. Hashimoto Y, Otsuki N, Morimoto K, Saito M, Nibu K. Four cases of spinal accessory nerve passing through the fenestrated internal jugular vein. *Surg Radiol Anat.* 2012 May;34(4):373-5. DOI: 10.1007/s00276-011-0875-x
446. Krmptović-Nemanić J, Valković V, Nemanić G. Analysis of trace elements in the human labyrinth by using proton microprobe. *Acta Otolaryngol.* 1985 Mar-Apr;99(3-4):466-8. DOI: 10.1007/978-3-662-11319-6
447. Werner J. Eingriffe am äußeren Hals. In: Theissing J, Rettinger G, Werner J, Hrsg. HNO-Operationslehre Mit allen wichtigen Eingriffen. Stuttgart, New York: Thieme; 2006. p. 271.
448. Werner J. Eingriffe am äußeren Hals. In: Theissing J, Rettinger G, Werner J, eds. HNO-Operationslehre Mit allen wichtigen Eingriffen Stuttgart, New York. Thieme; 2006. p. 273
449. Santaolalla F, Anta JA, Zabala A, Del Rey Sanchez A, Martinez A, Sanchez JM. Management of chylous fistula as a complication of neck dissection: a 10-year retrospective review. *Eur J Cancer Care (Engl).* 2010;19(4):510-5. DOI: 10.1111/j.1365-2354.2009.01086.x
450. Eufinger H, Lehmbruck J. Lebensbedrohliche und letale Komplikationen der Neck dissection. *Mund Kiefer Gesichtschir.* 2001;5:193-7. DOI: 10.1007/s100060100292
451. Merante Boschin I, Meduri F, Toniato A, Pagetta C, Casalide E, Rubello D, Pelizzo MR. Linforrea cervicale dopo svuotamento linfonodale: ruolo del digiuno basato sull'evidenza clinica [Cervical lymphorrea after nodal dissection: role of fasting based on clinical evidence]. *Minerva Chir.* 2006 Feb;61(1):57-62.
452. Bozzetti F, Arullani A, Baticci F, Terno G, Ammatuna M, Cappello G. Management of lymphatic fistulas by total parenteral nutrition. *JPEN J Parenter Enteral Nutr.* 1982 Nov-Dec;6(6):526-7. DOI: 10.1177/0148607182006006526
453. Gregor RT. Management of chyle fistulization in association with neck dissection. *Otolaryngol Head Neck Surg.* 2000 Mar;122(3):434-9.
454. de Gier HH, Balm AJ, Bruning PF, Gregor RT, Hilgers FJ. Systematic approach to the treatment of chylous leakage after neck dissection. *Head Neck.* ;18(4):347-51. DOI: 10.1002/(SICI)1097-0347(199607/08)18:4<347::AID-HEAD6>3.0.CO;2-Y
455. al-Khayat M, Kenyon GS, Fawcett HV, Powell-Tuck J. Nutritional support in patients with low volume chylous fistula following radical neck dissection. *J Laryngol Otol.* 1991 Dec;105(12):1052-6. DOI: 10.1017/S0022215100118171
456. Thawley SE. "How I do it" - head and neck. A targeted problem and its solution. Chylous fistula prevention and management. *Laryngoscope.* 1980;90:522-5. DOI: 10.1002/lary.5540900321
457. Crumley RL, Smith JD. Postoperative chylous fistula prevention and management. *Laryngoscope.* 1976 Jun;86(6):804-13. DOI: 10.1288/00005537-197606000-00008
458. Nowak K, Wierzbička M, Szyfyer W. Chylous leakage - rare but still dangerous complication after neck surgery. *Otolaryngol Pol.* 2011;65:128-31. DOI: 10.1016/S0030-6657(11)70642-4
459. Izzard ME, Crowder VL, Southwell KE. The use of Monogen in the conservative management of chylous fistula. *Otolaryngol Head Neck Surg.* 2007;136(4 Suppl):S50-3. DOI: 10.1016/j.otohns.2006.11.017
460. Martin IC, Marinho LH, Brown AE, et al. Medium chain triglycerides in the management of chylous fistulae following neck dissection. *Br J Oral Maxillofac Surg.* 1993;31:236-8. DOI: 10.1016/0266-4356(93)90146-N
461. Mallen RW, Kudryk WH. Case report: Chylous fistula following right radical neck dissection. *Can J Otolaryngol.* 1975;4(1):177-9.
462. Myers EN, Dinerman WS. Management of chylous fistulas. *Laryngoscope.* 1975 May;85(5):835-40. DOI: 10.1288/00005537-197505000-00008
463. Yoshimura Y, Kondoh T. Treatment of chylous fistula with fibrin glue and clavicular periosteal flap. *Br J Oral Maxillofac Surg.* 2002;40(2):138-9. DOI: 10.1054/bjom.2001.0653
464. Velegrakis GA, Prokopakis EP, Papadakis CE, Bizakis JG, Kyrizakis DE, Helidonis ES. Management of chylous fistula using the fibrin adhesive set. *ORL J Otorhinolaryngol Relat Spec.* 1998 Jul-Aug;60(4):230-2. DOI: 10.1159/000027600
465. Rollon A, Salazar C, Mayorga F, Marin R, Infante P. Severe cervical chyle fistula after radical neck dissection. *Int J Oral Maxillofac Surg.* 1996;25(5):363-5. DOI: 10.1016/S0901-5027(06)80031-7
466. Nussenbaum B, Liu JH, Sinard RJ. Systematic management of chyle fistula: the Southwestern experience and review of the literature. *Otolaryngol Head Neck Surg.* 2000;122(1):31-8. DOI: 10.1016/S0194-5998(00)70140-9
467. Jortay A, Bisschop P. Bilateral chylothorax after left radical neck dissection. *Acta Otorhinolaryngol Belg.* 2001;55(4):285-9.
468. Har-El G, Segal K, Sidi J. Bilateral chylothorax complicating radical neck dissection: report of a case with no concurrent external chylous leakage. *Head Neck Surg.* 1985 Jan-Feb;7(3):225-30. DOI: 10.1002/hed.2890070307
469. Yaddanapudi S, Shah SC. Bilateral phrenic nerve injury after neck dissection: an uncommon cause of respiratory failure. *J Laryngol Otol.* 1996 Mar;110(3):281-3.
470. Jabbar AS, al-Abdulkareem A. Bilateral chylothorax following neck dissection. *Head Neck.* 1995 Jan-Feb;17(1):69-72. DOI: 10.1002/hed.2880170115
471. de Jong AA, Manni JJ. Phrenic nerve paralysis following neck dissection. *Eur Arch Otorhinolaryngol.* 1991;248(3):132-4.
472. Metson R, Alessi D, Calcaterra TC. Tetracycline sclerotherapy for chylous fistula following neck dissection. *Arch Otolaryngol Head Neck Surg.* 1986 Jun;112(6):651-3. DOI: 10.1001/archotol.1986.03780060063009
473. Kirse DJ, Suen JY, Stern SJ. Phrenic nerve paralysis after doxycycline sclerotherapy for chylous fistula. *Otolaryngol Head Neck Surg.* 1997;116(6 Pt 1):680-3. DOI: 10.1016/S0194-5998(97)70249-3
474. Valtonen EJ, Lilius HG. Late sequelae of iatrogenic spinal accessory nerve injury. *Acta Chir Scand.* 1974;140(6):453-5.
475. Umeda M, Shigeta T, Takahashi H, Oguni A, Kataoka T, Minamikawa T, Shibuya Y, Komori T. Shoulder mobility after spinal accessory nerve-sparing modified radical neck dissection in oral cancer patients. *Oral Surg Oral Med Oral Pathol Oral Radiol Endod.* 2010 Jun;109(6):820-4. DOI: 10.1016/j.tripleo.2009.11.027
476. Morris LG, Ziff DJ, DeLacure MD. Malpractice litigation after surgical injury of the spinal accessory nerve: an evidence-based analysis. *Arch Otolaryngol Head Neck Surg.* 2008;134(1):102-7. DOI: 10.1001/archotol.134.1.102
477. Hansis M, Kienzle H. Wer definiert den Medizinischen Standard? Unwägbarkeiten in der Begutachtung vorgeworfener Behandlungsfehler am Beispiel der Schädigung des Nervus accessorius anlässlich der Lymphknoten-Probeexzision am Hals. *Vers Med* 2004. 2004;148 (über juris)
478. OLG Köln 12.01.1994 27 U 104/92.
479. LG Duisburg 15.12.1983 9 O 239/81.
480. Bird S. Accessory nerve injury. *Aust Fam Physician.* 2006 Jul;35(7):535-6.

481. Bodner G, Harpf C, Gardetto A, Kovacs P, Gruber H, Peer S, Mallhoui A. Ultrasonography of the accessory nerve: normal and pathologic findings in cadavers and patients with iatrogenic accessory nerve palsy. *J Ultrasound Med.* 2002 Oct;21(10):1159-63.
482. Harpf C, Rhombert M, Rumer A, Rainer C, Hussli H. Iatrogene Läsion des Nervus accessorius bei der cervicalen Lymphknotenbiopsie [Iatrogenic lesion of the accessory nerve in cervical lymph node biopsy]. *Chirurg.* 1999 Jun;70(6):690-3. DOI: 10.1007/s001040050706
483. Nason RW, Abdulrauf BM, Stranc MF. The anatomy of the accessory nerve and cervical lymph node biopsy. *Am J Surg.* 2000;180(3):241-3. DOI: 10.1016/S0002-9610(00)00449-9
484. Bänzner UM, Braun V, Richter HP, Antoniadis G. Management iatrogener N.-accessorius-Läsionen [Management of iatrogenic lesions of the spinal accessory nerve]. *Nervenarzt.* 2005 Apr;76(4):462-6. DOI: 10.1007/s00115-004-1796-2
485. Hopf H, Guerra W. Widersprüchliche Gutachteraussagen und Rechtsprechung. Entscheidungen zu iatrogenen Schäden des Nervus accessorius. *MedSach.* 2010;240-4.
486. OLG Düsseldorf 26.01.1984 8 U 161/81.
487. BVerfG 25.07.1979 2 BVR 878/74.
488. OLG Düsseldorf 10.11.1994 8 U 89/92.
489. OLG Celle 20.03.1989 1 U 51/88.
490. Wienke A. Aufklärung vor Tumorexstirpation am Hals [Information before tumor extirpation at the neck]. *Laryngorhinootologie.* 2006 Sep;85(9):665-6. DOI: 10.1055/s-2006-925243
491. OLG Hamm 28.09.1994 3 U 292/93.
492. OLG Stuttgart 30.05.2000 14 U 71/99.
493. BGH 07.05.1985 VI ZR 224/83
494. Werner J. Eingriffe am äußeren Hals. In: Theissing J, Rettinger G, Werner J, eds. *HNO-Operationslehre Mit allen wichtigen Eingriffen.* Stuttgart, New York, Tokyo: Thieme; 2006. p. 267-75.
495. Midwinter K, Willatt D. Accessory nerve monitoring and stimulation during neck surgery. *J Laryngol Otol.* 2002 Apr;116(4):272-4. DOI: 10.1258/0022215021910735
496. Tatla T, Kanagalingam J, Majithia A, Clarke PM. Upper neck spinal accessory nerve identification during neck dissection. *J Laryngol Otol.* 2005;119(11):906-8. DOI: 10.1258/002221505774783511
497. Symes A, Ellis H. Variations in the surface anatomy of the spinal accessory nerve in the posterior triangle. *Surg Radiol Anat.* 2005 Dec;27(5):404-8. DOI: 10.1007/s00276-005-0004-9
498. Hinsley ML, Hartig GK. Anatomic relationship between the spinal accessory nerve and internal jugular vein in the upper neck. *Otolaryngol Head Neck Surg.* 2010;143(2):239-41. DOI: 10.1016/j.otohns.2010.03.033
499. LG Bremen O.
500. Alexander RJ, Kukreja R, Ford GR. Secondary post-tonsillectomy haemorrhage and informed consent. *J Laryngol Otol.* 2004 Dec;118(12):937-40. DOI: 10.1258/0022215042790619
501. Alexiou VG, Salazar-Salvia MS, Jervis PN, Falagas ME. Modern technology-assisted vs conventional tonsillectomy: a meta-analysis of randomized controlled trials. *Arch Otolaryngol Head Neck Surg.* 2011 Jun;137(6):558-70. DOI: 10.1001/archoto.2011.93
502. Amir I, Belloso A, Broomfield SJ, Morar P. Return to theatre in secondary post-tonsillectomy haemorrhage: a comparison of coblation and dissection techniques. *Eur Arch Otorhinolaryngol.* 2012 Feb;269(2):667-71. DOI: 10.1007/s00405-011-1678-8
503. Attner P, Haraldsson PO, Hemlin C, Hessén Soderman AC. A 4-year consecutive study of post-tonsillectomy haemorrhage. *ORL J Otorhinolaryngol Relat Spec.* 2009;71(5):273-8. DOI: 10.1159/000245160
504. Brigger MT, Brietzke SE. Outpatient tonsillectomy in children: a systematic review. *Otolaryngol Head Neck Surg.* 2006;135(1):1-7. DOI: 10.1016/j.otohns.2006.02.036
505. Chiang TM, Sukis AE, Ross DE. Tonsillectomy performed on an outpatient basis. Report of a series of 40,000 cases performed without a death. *Arch Otolaryngol.* 1968 Sep;88(3):307-10. DOI: 10.1001/archotol.1968.00770010309020
506. Dhiwakar M, Clement WA, Supriya M, McKerrow W. Antibiotics to reduce post-tonsillectomy morbidity. *Cochrane Database Syst Rev.* 2010;(7):CD005607. DOI: 10.1002/14651858.CD005607.pub3
507. Diakos EA, Gallos ID, El-Shunnar S, Clarke M, Kazi R, Mehanna H. Dexamethasone reduces pain, vomiting and overall complications following tonsillectomy in adults: a systematic review and meta-analysis of randomised controlled trials. *Clin Otolaryngol.* 2011;36(6):531-42. DOI: 10.1111/j.1749-4486.2011.02373.x
508. Evans AS, Khan AM, Young D, Adamson R. Assessment of secondary haemorrhage rates following adult tonsillectomy—a telephone survey and literature review. *Clin Otolaryngol Allied Sci.* 2003 Dec;28(6):489-91. DOI: 10.1046/j.1365-2273.2003.00763.x
509. Guida RA, Mattucci KF. Tonsillectomy and adenoidectomy: an inpatient or outpatient procedure? *Laryngoscope.* 1990;100(5):491-3. DOI: 10.1288/00005537-199005000-00009
510. Handler SD, Miller L, Richmond KH, Baranak CC. Post-tonsillectomy hemorrhage: incidence, prevention and management. *Laryngoscope.* 1986 Nov;96(11):1243-7.
511. Heidemann CH, Wallén M, Aakesson M, Skov P, Kjeldsen AD, Godballe C. Post-tonsillectomy hemorrhage: assessment of risk factors with special attention to introduction of coblation technique. *Eur Arch Otorhinolaryngol.* 2009;266(7):1011-5. DOI: 10.1007/s00405-008-0834-2
512. Hessén Söderman AC, Ericsson E, Hemlin C, Hultcrantz E, Månsson I, Roos K, Stalfors J. Reduced risk of primary postoperative hemorrhage after tonsil surgery in Sweden: results from the National Tonsil Surgery Register in Sweden covering more than 10 years and 54,696 operations. *Laryngoscope.* 2011;121(11):2322-6. DOI: 10.1002/lary.22179
513. Kristensen S, Tveterås K. Post-tonsillectomy haemorrhage. A retrospective study of 1150 operations. *Clin Otolaryngol Allied Sci.* 1984 Dec;9(6):347-50. DOI: 10.1111/j.1365-2273.1984.tb01519.x
514. Laureyns G, Lemkens P, Jorissen M. Tonsillectomy as a day-case surgery: a safe procedure? *B-ENT.* 2006;2(3):109-16.
515. Marret E, Flahault A, Samama CM, Bonnet F. Effects of postoperative, nonsteroidal, antiinflammatory drugs on bleeding risk after tonsillectomy: meta-analysis of randomized, controlled trials. *Anesthesiology.* 2003 Jun;98(6):1497-502. DOI: 10.1097/00000542-200306000-00030
516. Møiniche S, Rømsing J, Dahl JB, Tramèr MR. Nonsteroidal antiinflammatory drugs and the risk of operative site bleeding after tonsillectomy: a quantitative systematic review. *Anesth Analg.* 2003 Jan;96(1):68-77, table of contents. DOI: 10.1213/00000539-200301000-00015
517. Moralee SJ, Murray JA. Would day-case adult tonsillectomy be safe? *J Laryngol Otol.* 1995 Dec;109(12):1166-7. DOI: 10.1017/S0022215100132347

518. Mösges R, Hellmich M, Allekotte S, Albrecht K, Böhm M. Hemorrhage rate after coblation tonsillectomy: a meta-analysis of published trials. *Eur Arch Otorhinolaryngol*. 2011;268(6):807-16. DOI: 10.1007/s00405-011-1535-9
519. Mowatt G, Cook JA, Fraser C, McKerrow WS, Burr JM. Systematic review of the safety of electrosurgery for tonsillectomy. *Clin Otolaryngol*. 2006 Apr;31(2):95-102. DOI: 10.1111/j.1749-4486.2006.01162.x
520. Ovesen T, Kamarauskas G, Dahl M, Mainz J. Pain and bleeding are the main determinants of unscheduled contacts after outpatient tonsillectomy. *Dan Med J*. 2012 Feb;59(2):A4382.
521. Salonen A, Kokki H, Nuutinen J. Recovery after tonsillectomy in adults: a three-week follow-up study. *Laryngoscope*. 2002;112(1):94-8. DOI: 10.1097/00005537-200201000-00017
522. Tomkinson A, De Martin S, Gilchrist CR, Temple M. Instrumentation and patient characteristics that influence postoperative haemorrhage rates following tonsil and adenoid surgery. *Clin Otolaryngol*. 2005 Aug;30(4):338-46. DOI: 10.1111/j.1365-2273.2005.01045.x
523. Tomkinson A, Harrison W, Owens D, Harris S, McClure V, Temple M. Risk factors for postoperative hemorrhage following tonsillectomy. *Laryngoscope*. 2011;121(2):279-88. DOI: 10.1002/lary.21242
524. Wagner GA. Ambulatory adult tonsillectomy. *J Otolaryngol*. 1991 Feb;20(1):33-4.
525. McSeveryn WR. A report on an inquiry into the death of a 5 years old boy during an operation for removal of tonsils and adenoids. *Lamp*. 1977 Aug;34(8):23.
526. McRae R, Weissburg A, Chang K. Iatrogenic hyponatremia: a cause of death following pediatric tonsillectomy. *Int J Pediatr Otorhinolaryngol*. 1994;30:227-32. DOI: 10.1016/0165-5876(94)90064-7
527. Peeters A, Claes J, Saldien V. Lethal complications after tonsillectomy. *Acta Otorhinolaryngol Belg*. 2001;55(3):207-13.
528. Byard RW. Tonsillitis and sudden childhood death. *J Forensic Leg Med*. 2008 Nov;15(8):516-8. DOI: 10.1016/j.jflm.2008.04.005
529. Smith ME. Death from tonsillectomy. *Lancet*. 1959;1:671-2. DOI: 10.1016/S0140-6736(59)92416-X
530. Taylor GW. Death following tonsillectomy. *AMA Arch Otolaryngol*. 1950 Oct;52(4):642-5. DOI: 10.1001/archotol.1950.00700030666012
531. Windfuhr JP. Lethal post-tonsillectomy hemorrhage. *Auris Nasus Larynx*. 2003 Dec;30(4):391-6. DOI: 10.1016/j.anl.2003.07.004
532. Morris LG, Lieberman SM, Reitzen SD, Edelstein DR, Ziff DJ, Katz A, Komisar A. Characteristics and outcomes of malpractice claims after tonsillectomy. *Otolaryngol Head Neck Surg*. 2008;138(3):315-20. DOI: 10.1016/j.otohns.2007.11.024
533. Cohen D, Dor M. Morbidity and mortality of post-tonsillectomy bleeding: analysis of cases. *J Laryngol Otol*. 2008 Jan;122(1):88-92. DOI: 10.1017/S0022215107006895
534. Silverman JJ, Talbot TJ, McClean RW. Mediastinal emphysema following tonsillectomy. *Dis Chest*. 1953 Apr;23(4):397-402. DOI: 10.1378/chest.23.4.397
535. Miman MC, Ozturan O, Durmus M, Kalcioğlu MT, Gedik E. Cervical subcutaneous emphysema: an unusual complication of adenotonsillectomy. *Paediatr Anaesth*. 2001 Jul;11(4):491-3. DOI: 10.1046/j.1460-9592.2001.00707.x
536. Hampton SM, Cinnamon MJ. Subcutaneous emphysema as a complication of tonsillectomy. *J Laryngol Otol*. 1997 Nov;111(11):1077-8. DOI: 10.1017/S0022215100139398
537. Vos GD, Marres EH, Heineman E, Janssens M. Tension pneumoperitoneum as an early complication after adenotonsillectomy. *J Laryngol Otol*. 1995 May;109(5):440-1. DOI: 10.1017/S0022215100130385
538. Gillot C, Tombu S, Crestani V, Huvellet P, Moreau P. Subcutaneous emphysema and mediastinitis: unusual complications of tonsillectomy. *B-ENT*. 2005;1(4):197-200.
539. Hung MH, Shih PY, Yang YM, Lan JY, Fan SZ, Jeng CS. Cervicofacial subcutaneous emphysema following tonsillectomy: implications for anesthesiologists. *Acta Anaesthesiol Taiwan*. 2009 Sep;47(3):134-7. DOI: 10.1016/S1875-4597(09)60040-0
540. Lima WL, Correa NS, de Campos JL, Navarro PM, Correia Lde O. Subcutaneous emphysema after tonsillectomy: case report. *Rev Bras Anestesiol*. 2005 Aug;55(4):441-4.
541. Luk'ianenko VT, Bol'shakov VI, Kniazhanskiĭ ES. Emfizema dna polostirta posle tonzilléktomii [Emphysema of the floor of the mouth after a tonsillectomy]. *Vestn Otorinolaringol*. 1978 Nov-Dec;(6):74-5.
542. Marion G, De Filippis C, Tregnaghi A, Gaio E, Staffieri A. Cervical emphysema and pneumomediastinum after tonsillectomy: it can happen. *Otolaryngol Head Neck Surg*. 2003 Feb;128(2):298-300. DOI: 10.1067/mhn.2003.25
543. Matsching F. Zur Genese des Hautemphysems nach Tonsillektomie und Adenotomie [Pathogenesis of cutaneous emphysema following tonsillectomy and adenotomy]. *Monatsschr Ohrenheilkd Laryngorhinol*. 1950 Jul-Sep;84(7-8-9):208-10.
544. McGreevy EJ, McGreevy JV. Subcutaneous emphysema following tonsillectomy. *SD J Med Pharm*. 1957 May;10(5):160-1; passim.
545. Nishino H, Kenmochi M, Kasugai S, et al. Subcutaneous emphysema secondary to tonsillectomy: a case report. *Auris Nasus Larynx*. 2003;(30 Suppl):S135-S136. DOI: 10.1016/S0385-8146(02)00142-6
546. Panerari AC, Soter AC, Silva FL, et al. Onset of subcutaneous emphysema and pneumomediastinum after tonsillectomy: a case report. *Rev Bras Otorrinolaringol (Engl Ed)*. 2005;71:94-6. DOI: 10.1590/S0034-72992005000100017
547. Patel N, Brookes G. Surgical emphysema following tonsillectomy. *Ear Nose Throat J*. 2005 Oct;84(10):660-1.
548. Podoshin L, Persico M, Fradis M. Posttonsillectomy emphysema. *Ear Nose Throat J*. 1979;58 (73-76) 81-72.
549. Pratt LW, Hornberger HR, Moore VJ. Mediastinal emphysema complicating tonsillectomy and adenoidectomy. *Ann Otol Rhinol Laryngol*. 1962 Mar;71:158-69.
550. Prupas HM, Fordham SD. Emphysema secondary to tonsillectomy. *Laryngoscope*. 1977 Jul;87(7):1134-6. DOI: 10.1288/00005537-197707000-00014
551. Ramachandran M, Dulay VC, Lobo ZA, Kuriyan JB. Bilateral pneumothorax with pneumomediastinum under anaesthesia in a healthy female. *Can Anaesth Soc J*. 1982 Jul;29(4):391-4. DOI: 10.1007/BF03007533
552. Richter GT, Bower CM. Cervical complications following routine tonsillectomy and adenoidectomy. *Curr Opin Otolaryngol Head Neck Surg*. 2006 Dec;14(6):375-80. DOI: 10.1097/01.moo.0000247525.56076.54
553. Shine NP, Sader C, Coates H. Cervicofacial emphysema and pneumomediastinum following pediatric adenotonsillectomy: a rare complication. *Int J Pediatr Otorhinolaryngol*. 2005 Nov;69(11):1579-82. DOI: 10.1016/j.ijporl.2005.04.014
554. Smelt GJ. Subcutaneous emphysema: pathological and anaesthetic, but not surgical. *J Laryngol Otol*. 1984 Jun;98(6):647-54. DOI: 10.1017/S0022215100147231

555. Stewart AE, Brewster DF, Bernstein PE. Subcutaneous emphysema and pneumomediastinum complicating tonsillectomy. *Arch Otolaryngol Head Neck Surg.* 2004 Nov;130(11):1324-7. DOI: 10.1001/archotol.130.11.1324
556. Swanson CL. Pulmonary emphysema following T & A. *SD J Med Pharm.* 1958 Jan;11(1):1-2.
557. Watanabe K, Kunitomo M, Yamauchi Y, Kimura M, Masuno S, Aoki H, Yagi T. Subcutaneous emphysema after tonsillectomy: a case report. *J Nippon Med Sch.* 2004 Apr;71(2):111-3. DOI: 10.1272/jnms.71.111
558. Yammine NV, Alherabi A, Gerin-Lajoie J. Post-tonsillectomy subcutaneous emphysema and pneumomediastinum. *J Otolaryngol.* 2004 Dec;33(6):403-4. DOI: 10.2310/7070.2004.04061
559. Shi ZP, Wang CC, Lee JC, Lin YS. Post-tonsillectomy hematoma of the mouth floor. *Eur Arch Otorhinolaryngol.* 2006;263(11):1041-3. DOI: 10.1007/s00405-006-0101-3
560. Nix PA. Jugular thrombosis following tonsillectomy. *J Laryngol Otol.* 2001 Mar;115(3):238-9. DOI: 10.1258/0022215011907082
561. Sia KJ, Tang IP, Kong CK, Nasriah A. Grisel's syndrome: a rare complication of tonsillectomy. *J Laryngol Otol.* 2012 May;126(5):529-31. DOI: 10.1017/S0022215112000175
562. Battiatia AP, Pazos G. Grisel's syndrome: the two-hit hypothesis-a case report and literature review. *Ear Nose Throat J.* 2004 Aug;83(8):553-5.
563. Hekster RE, Norden AA. Non-traumatic atlanto-axial displacement after tonsillectomy. A case report. *Radiol Clin Biol.* 1970;39(4):357-65.
564. Pamaar CG, Ahmad I, Marsh NJ. Accidental burn during tonsillectomy. *Anesthesiology.* 1992 May;76(5):869. DOI: 10.1097/00000542-199205000-00042
565. Shah UK. A simple suggestion to reduce perioral burns during adenotonsillectomy. *Arch Otolaryngol Head Neck Surg.* 2008;134(6):673. DOI: 10.1001/archotol.134.6.673-b
566. Lowry TR, Workman JR. Avoiding oral burns during electrocautery tonsillectomy. *Ear Nose Throat J.* 2009 Feb;88(2):790-2.
567. McLaughlin KE, Jacobs IN, Todd NW, Gussack GS, Carlson G. Management of nasopharyngeal and oropharyngeal stenosis in children. *Laryngoscope.* 1997 Oct;107(10):1322-31. DOI: 10.1097/00005537-199710000-00006
568. Woolf RM, Broadbent TR. Nasopharyngeal stenosis following tonsillectomy and adenoidectomy. *Plast Reconstr Surg.* 1970;45(4):352-5. DOI: 10.1097/00006534-197004000-00007
569. McDonald TJ, Devine KD, Hayles AB. Nasopharyngeal stenosis following tonsillectomy and adenoidectomy. Report of six cases and their repair. *Arch Otolaryngol.* 1973 Jul;98(1):38-41. DOI: 10.1001/archotol.1973.00780020042010
570. Giannoni C, Sulek M, Friedman EM, Duncan NO 3rd. Acquired nasopharyngeal stenosis: a warning and review. *Arch Otolaryngol Head Neck Surg.* 1998 Feb;124(2):163-7. DOI: 10.1001/archotol.124.2.163
571. Johnson LB, Elluru RG, Myer CM 3rd. Complications of adenotonsillectomy. *Laryngoscope.* 2002 Aug;112(8 Pt 2 Suppl 100):35-6. DOI: 10.1002/lary.5541121413
572. Feinerman IL, Tan HK, Roberson DW, et al. Necrotizing fasciitis of the pharynx following adenotonsillectomy. *Int J Pediatr Otorhinolaryngol.* 1999;48:1-7. DOI: 10.1016/S0165-5876(98)00148-7
573. Sonne JE, Kim SB, Frank DK. Cervical necrotizing fasciitis as a complication of tonsillectomy. *Otolaryngol Head Neck Surg.* 2001;125(6):670-2. DOI: 10.1067/mhn.2001.119970
574. Meher R, Singhal D, Girhotra M, et al. Palatal Perforation After Tonsillectomy. *The Internet Journal of Otorhinolaryngology.* 2003;2. DOI: 10.5580/5589e5588
575. Guirguis M, Berkowitz RG. Meningococcal septicemia post adenotonsillectomy in a child: case report. *Int J Pediatr Otorhinolaryngol.* 2001;57:161-4. DOI: 10.1016/S0165-5876(00)00454-7
576. Papadakis CE, Nikolidakis AA, Bizakis JG, Skoulakis CE, Velegrakis GA, Kokori HG, Helidonis ES. Meningitis as a complication of tonsillectomy. *Int J Pediatr Otorhinolaryngol.* 1998;45(3):243-7. DOI: 10.1016/S0165-5876(98)00096-2
577. Esposito S, Marchisio P, Capaccio P, Bellasio M, Semino M, Dusi E, Colombo R, Pignataro L, Principi N. Risk factors for bacteremia during and after adenoidectomy and/or adenotonsillectomy. *J Infect.* 2009 Feb;58(2):113-8. DOI: 10.1016/j.jinf.2008.12.003
578. François M, Bingen EH, Lambert-Zechovsky NY, Mariani-Kurkdjian P, Nottet JB, Narcy P. Bacteremia during tonsillectomy. *Arch Otolaryngol Head Neck Surg.* 1992 Nov;118(11):1229-31. DOI: 10.1001/archotol.1992.01880110097017
579. Gaffney RJ, Walsh MA, McShane DP, Cafferkey MT. Post-tonsillectomy bacteraemia. *Clin Otolaryngol Allied Sci.* 1992 Jun;17(3):208-10. DOI: 10.1111/j.1365-2273.1992.tb01828.x
580. Kaygusuz I, Gök U, Yalçın S, Keleş E, Kizirgil A, Demirbağ E. Bacteremia during tonsillectomy. *Int J Pediatr Otorhinolaryngol.* 2001;58(1):69-73. DOI: 10.1016/S0165-5876(00)00471-7
581. Klug TE, Henriksen JJ, Rusan M, Fursted K, Ovesen T. Bacteremia during quinsy and elective tonsillectomy: an evaluation of antibiotic prophylaxis recommendations for patients undergoing tonsillectomy. *J Cardiovasc Pharmacol Ther.* 2012 Sep;17(3):298-302. DOI: 10.1177/1074248411423023
582. Rhoads PS, Sibley JR, Billings CE. Bacteremia following tonsillectomy; effect of preoperative treatment with antibiotics in postoperative bacteremia and in bacterial content of tonsils. *J Am Med Assoc.* 1955 Mar;157(11):877-81. DOI: 10.1001/jama.1955.02950280001001
583. Yildirim I, Okur E, Ciragil P, Aral M, Kilic MA, Gul M. Bacteraemia during tonsillectomy. *J Laryngol Otol.* 2003;117(8):619-23. DOI: 10.1258/002221503768199951
584. Walsh RM, Kumar BN, Tse A, Jones PW, Wilson PS. Post-tonsillectomy bacteraemia in children. *J Laryngol Otol.* 1997 Oct;111(10):950-2. DOI: 10.1017/S0022215100139040
585. Agut Fuster MA, del Campo Biosca J, Ferrer Rodríguez A, Ramos Martínez MJ, Viel Martínez JM, Agullas Fornés MJ. Hiponatremia post-adenotonsilectomía en ni-os: una posible complicación letal. [Post-tonsillectomy hyponatremia: a posible lethal complication]. *Acta Otorrinolaringol Esp.* 2006;57(5):247-50. DOI: 10.1016/S0001-6519(06)78701-5
586. Weinstein RE, Bona RD, Altman AJ, Quinn JJ, Weisman SJ, Bartolomeo A, Rickles FR. Severe hyponatremia after repeated intravenous administration of desmopressin. *Am J Hematol.* 1989 Dec;32(4):258-61. DOI: 10.1002/ajh.2830320405
587. Hydri AS, Malik SM. Reduced mouth opening following tonsillectomy in children: myth or reality. *J Coll Physicians Surg Pak.* 2010 Dec;20(12):781-4.
588. Maini S, Osborne JE, Fadl HM, Spyridakou C, Ogunyemi L, Hill P. Temporomandibular joint dysfunction following tonsillectomy. *Clin Otolaryngol Allied Sci.* 2002 Feb;27(1):57-60. DOI: 10.1046/j.0307-7772.2001.00528.x
589. Alabidi A. Aspiration of an incisor tooth after adenotonsillectomy in a 10-year-old Saudi boy. *East Mediterr Health J.* 2008 Jan-Feb;14(1):228-30.

590. Ozer C, Ozer F, Sener M, Yavuz H. A forgotten gauze pack in the nasopharynx: an unfortunate complication of adenotonsillectomy. *Am J Otolaryngol.* 2007 May-Jun;28(3):191-3. DOI: 10.1016/j.amjoto.2006.07.009

Please cite as

Windfuhr JP. Malpractice claims and unintentional outcome of tonsil surgery and other standard procedures in otorhinolaryngology. *GMS Curr Top Otorhinolaryngol Head Neck Surg.* 2013;12:Doc08. DOI: 10.3205/cto000100, URN: urn:nbn:de:0183-cto0001003

Erratum

In the initial publication the article was erroneously designated as "Review Article".

This article is freely available from

<http://www.egms.de/en/journals/cto/2013-12/cto000100.shtml>

Published: 2013-12-13

Published with erratum: 2015-06-08

Corresponding author:

Jochen P. Windfuhr, MD, PhD
Department of Otorhinolaryngology, Plastic Head and Neck Surgery, Kliniken Maria Hilf, Sandradstr. 43, 41061 Mönchengladbach, Germany, Phone: +49-(0)2161-358-1601, Fax: +49-(0)2161-358-1603
jochen.windfuhr@mariahilf.de

Copyright

©2013 Windfuhr. This is an Open Access article distributed under the terms of the Creative Commons Attribution License. You are free: to Share - to copy, distribute and transmit the work, provided the original author and source are credited. See license information at <http://creativecommons.org/licenses/by-nc-nd/3.0/>.