

Clinical Characteristics and Endovascular Treatment for Spinal Dural Arteriovenous Fistula in Japan: Japanese Registry of Neuroendovascular Therapy 2 and 3

Wataro TSURUTA,¹ Yuji MATSUMARU,² Koji IIHARA,³ Tetsu SATOW,⁴ Nobuyuki SAKAI,⁵ Masahiro KATSUMATA,¹ Hisayuki HOSOO,¹ Masayuki SATO,⁶ Yoshiro ITO,⁶ Aiki MARUSHIMA,² Mikito HAYAKAWA,² Eiichi ISHIKAWA,⁶ and Akira MATSUMURA⁶

¹Department of Endovascular Neurosurgery, Toranomon Hospital, Tokyo, Japan;

²Division for Stroke, Department of Neurosurgery, Faculty of Medicine, University of Tsukuba, Tsukuba, Ibaraki, Japan;

³Department of Neurosurgery, Graduate School of Medical Sciences, Kyushu University, Fukuoka, Fukuoka, Japan;

⁴Department of Neurosurgery, National Cerebral and Cardiovascular Center, Suita, Osaka, Japan;

⁵Department of Neurosurgery, Kobe City Medical Center General Hospital, Kobe, Hyogo, Japan;

⁶Department of Neurosurgery, Faculty of Medicine, University of Tsukuba, Tsukuba, Ibaraki, Japan

Abstract

A subgroup analysis of spinal vascular lesions registered in the Japanese Registry of Neuroendovascular Therapy 2 (JR-NET2) and JR-NET3 was performed. About 172 analyzable cases of spinal dural arteriovenous fistula (SDAVF) were assessed, including the characteristics, treatment strategy, and treatment outcome. SDAVF was more common in middle-aged and older males. The most commonly affected area was the thoracolumbosacral region (83.7%), and most cases had a non-hemorrhagic onset (89.0%). Complete obliteration was achieved in 54.7%. Treatment-related complications occurred in three patients (7.0%). Post-treatment neurological improvement was achieved in 48.3%. The primary endpoint [modified Rankin Scale (mRS) score of 0–2 on postoperative day 30] was achieved in 60.5% of the cases. As a new discovery, the incidence of cervical SDAVF increased from 1.8% in JR-NET2 to 19.7% in JR-NET3. Compared with non-cervical SDAVF, cervical SDAVF was characterized by a higher proportion of hemorrhagic onset ($P < 0.01$), incomplete obliteration of the shunt ($P < 0.01$), and embolization-related complications ($P = 0.01$). Overall, a mRS of 0–2 on postoperative day 30 was correlated with a pre-treatment mRS of 0–2 ($P < 0.01$) in a univariate analysis. Complete obliteration of the shunt was the only predictor of postoperative neurological improvement ($P = 0.001$) in a multivariate analysis. Endovascular treatment for SDAVF has been safely administered in Japan. The incidence of cervical SDAVF, which has more aggressive features, appears to be increasing. Early diagnosis and complete obliteration of the shunt are important for improving the treatment outcomes of patients with SDAVF.

Key words: spinal dural arteriovenous fistula, clinical characteristics, endovascular treatment

Introduction

The Japanese Society for Neuroendovascular Therapy (JSNET) conducted a “Study for preparing guidelines

Received February 22, 2019; Accepted August 27, 2019

Copyright© 2019 by The Japan Neurosurgical Society This work is licensed under a Creative Commons Attribution-NonCommercial-NoDerivatives International License.

for safe catheter intervention and physician training: Japanese Registry of Neuroendovascular Therapy (JR-NET1)” to investigate the general status of neuroendovascular therapy in Japan, with patients enrolled in 2005 and 2006.¹⁾ JR-NET1 was followed by a “Study for construction and efficacy of education and training systems for catheter intervention: JR-NET2 and 3,” and patients who underwent neuroendovascular therapy between 2007 and 2009 were included

in JR-NET2, while those who underwent treatment between 2010 and 2014 were included in JR-NET3. In this article, the current status of the endovascular treatment of spinal vascular lesions in Japan will be reviewed based on the results of JR-NET2 and 3. Our previous report mentioned the current status of endovascular treatment for all spinal vascular lesions in Japan. In this study, we focused on SDAVF, which is the most common spinal vascular lesion, and parameters such as patient characteristics and treatment outcome were analyzed.²⁾

Subjects and Methods

JR-NET2 included all patients treated by JSNET board-certified physicians between January 2007 and December 2009 (Fig. 1). Medical information of the patients was anonymized and registered. JR-NET3 included and registered between January 2010 and December 2014 in the same manner. Data were collected at the Translational Research Informatics Center (<http://www.tri-kobe.org/>). The study protocol, which is summarized briefly here, is available online with the full text of this article (<https://jr-net.tri-kobe.net/jr-net/>).

A total of 122 spinal lesions were included in JR-NET2. After excluding two lesions with incomplete data for multiple registration parameters or the primary endpoint, 120 spinal vascular lesions were analyzed: 55 cases of spinal dural arteriovenous fistula (SDAVF), 31 cases of spinal perimedullary arteriovenous fistula (SPAVF), and 17 cases of spinal

intramedullary arteriovenous malformation (SIAVM). A total of 229 spinal lesions were included in JR-NET3. After excluding two lesions with incomplete data, the following 227 vascular lesions were analyzed: 117 cases of SDAVF, 53 cases of SPAVF, and 18 cases of SIAVM. All the data from JR-NET2 and 3 were combined for analysis. In this study, we focused on SDAVF, and parameters regarding patient characteristics and the treatment outcome of SDAVF were analyzed, including sex, age, pre-treatment modified Ranking Scale (mRS) score, location, number of feeders, embolic material, technical success, treatment-related complications, postoperative neurological findings, mRS ≤ 2 on day 30, symptomatology, treatment strategy, and obliteration of shunt. A Chi-square test was used to determine the correlation between each variable except for age and the primary endpoint, defined as a mRS score of 0–2 on day 30 and postoperative neurological improvement. The Student's *t*-test was used to compare age. Subsequently, a multivariate analysis (logistic regression analysis) was performed, including variables with a probability value (*P*) of <0.1 in the Chi-square test, sex, and age. A significance level of $P \leq 0.05$ was used. SPSS Statistics Version 20 software (IBM SPSS, Chicago, IL, USA) was used for the statistical analysis.

Results

Characteristics of SDAVF

Spinal dural arteriovenous fistula was more common among elderly patients (mean age: 62.5 ± 15 years)

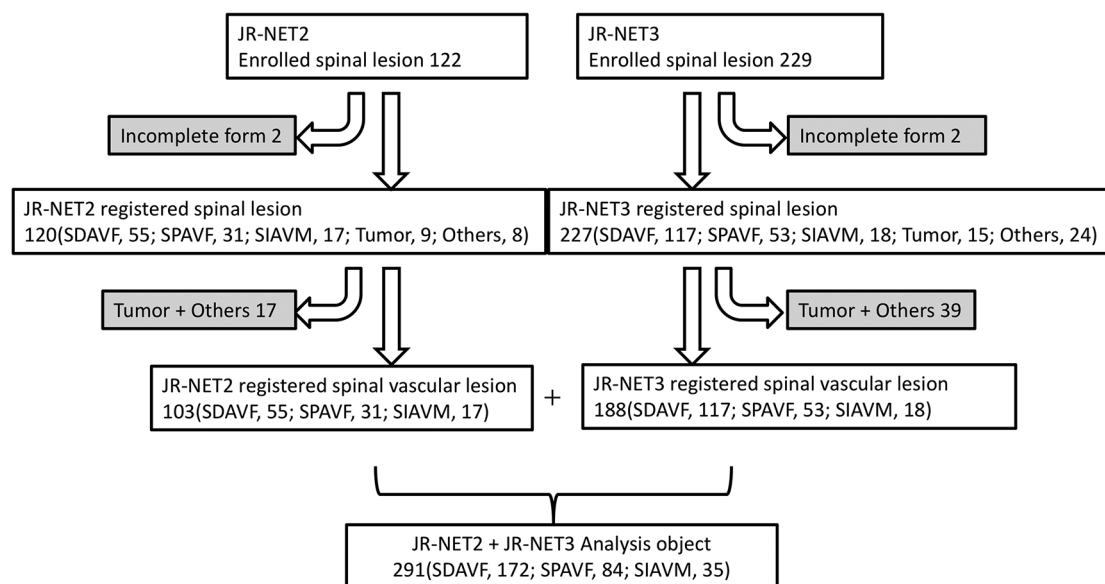


Fig. 1 172 cases of SDAVFs enrolled in JR-NET 2 and 3 were assessed in this study. SDAVF: spinal dural arteriovenous fistula, SPAVF: spinal perimedullary arteriovenous fistula, SIAVM: spinal intramedullary arteriovenous malformation, JR-NET: Japanese Registry of Neuroendovascular Therapy.

and men (77.3%) (Table 1). A pre-treatment mRS score of 0–2 in 66.3% of the SDAVF cases suggested a pre-treatment deterioration in activities of daily living (ADL). Regarding the location, SDAVF affected the neck region in 24 cases (14.0%) and the thoracolumbosacral region in 148 cases (86%). A single feeder was present in 48% of the cases. Regarding symptomatology, 153 cases (89.0%) were non-hemorrhagic, 15 cases (8.7%) were hemorrhagic, and only three cases (1.7%) were asymptomatic.

Treatment of SDAVF

A curative treatment strategy was adopted in the majority of cases (79.1%). *N*-butyl-cyanoacrylate was the most common embolic material. Technical success was achieved in 90.1% of the cases, and obliteration of the shunt was achieved in 57.0%. Treatment-related complications occurred in 12 cases (7.0%), including three cases with vessel perforation, two with draining vein occlusion, two with

distal embolism, two with normal vessel occlusion, and three other cases. Symptomatic complications occurred in five cases (2.9%). Postoperative neurological improvement was achieved in 48.3% of the patients. The primary endpoint, defined as a mRS score of 0–2 on day 30, was achieved in 60.5% of the cases.

Cervical SDAVF

Spinal dural arteriovenous fistula affecting the cervical region was seen in one out of 55 cases (1.8%) in JR-NET2 and 23 out of 117 cases (19.7%) in JR-NET3, representing an obvious increase in incidence. Compared with non-cervical SDAVF, cervical SDAVF was characterized by a higher proportion of women ($P = 0.03$). A pre-treatment mRS score of 0–2 was more common among cervical SDAVF patients than among those with non-cervical SDAVF ($P = 0.03$). Regarding symptomatology, a hemorrhagic onset was more common among cervical SDAVF

Table 1 Comparison of characteristics between cervical SDAVF and other locations

Diagnosis (<i>n</i>)		Total SDAVF	Cervical (<i>n</i> = 24)	Non-cervical (<i>n</i> = 148)	Univariate analysis
Sex	M	133	15	118	0.03
	F	39	9	30	
Age		62.5	54.7	63.8	0.22
Pre-symptomatic mRS 0–2		114 (66.3)	21	93	0.03
	C	24 (14.0)	24	-	
	Th	80 (46.5)	-	80	
Location (%)	L or S	64 (37.2)	-	64	
	Multiple	4 (2.3)	-	4	
	Single	68 (39.5)	6	62	
Number of feeders (%)	Multiple	100 (58.1)	17	83	<0.01
	Hemorrhagic	15 (8.7)	10	5	
Symptom (%)	Non-hemorrhagic	153 (89.0)	11	142	0.03
	Asymptomatic	3 (1.7)	3	0	
	Radical	136 (79.1)	15	121	
Strategy of embolization (%)	Palliative	33 (19.2)	9	24	<0.01
	Presurgical	3 (1.7)	0	3	
	Total	94 (54.7)	6	88	
Obliteration of nidus* (%)	Subtotal	38 (22.1)	9	29	0.03
	Partial	20 (11.6)	7	14	
	Unchanged	8 (4.7)	1	7	
Neurological outcome (%)	Improved	83 (48.3)	6	77	0.03
	Stable	81 (47.1)	14	67	
	Worsen	5 (2.9)	4	1	
Complication (%)		12 (7.0)	6	6	<0.01
30 Days mRS 0–2 (%)		104 (60.5)	17	87	0.37

SDAVF: spinal dural arteriovenous fistula.

than among non-cervical SDAVF ($P < 0.01$). Radical embolization was less common than that for non-cervical SDAVF ($P = 0.03$). Complete obliteration of the shunt was less common ($P < 0.01$), and the rate of complications was higher ($P = 0.01$), compared with non-cervical SDAVF. The postoperative neurological improvement rate was also lower than that for non-cervical SDAVF ($P = 0.03$).

Prognostic factors for SDAVF

A mRS score of 0–2 on day 30, which was the primary endpoint of this study, was the only factor correlated with a pre-treatment mRS of 0–2 ($P < 0.01$) in univariate analyses (Table 2). Postoperative neurological improvement was correlated with a non-cervical region ($P = 0.01$), a non-hemorrhagic onset ($P = 0.01$), radical embolization ($P < 0.01$), and complete obliteration of the shunt ($P < 0.01$) in univariate analyses. Complete obliteration of the shunt was the only factor that was correlated with a postoperative neurological improvement in a multivariate analysis ($P = 0.001$) (Table 3).

Discussion

Spinal dural arteriovenous fistula was most commonly observed in the thoracolumbar spine of middle-aged and older men with non-hemorrhagic onset,^{3–5} as previously reported. Endovascular treatment was safely performed for SDAVF. A new finding of this study is that the incidence of cervical lesions, which have more aggressive features than non-cervical lesions, had obviously increased in JR-NET3, compared with JR-NET2.

Table 2 Analysis of SDAVF factors correlated with mRS of 0–2 on day 30

	Univariate analysis (P)
Sex (female)	0.98
Age	0.78
Pre-symptomatic mRS (0–2)	<0.01
Location (cervical)	0.56
Number of feeders (single)	0.3
Symptom (non-hemorrhagic)	0.22
Strategy of embolization (radical)	0.19
Technical outcome (success)	0.85
Obliteration of nidus (total occlusion)	0.36
Neurological outcome (improved)	0.79
Complication (-)	0.26

SDAVF: spinal dural arteriovenous fistula.

Table 3 Analysis of SDAVF factors correlated with post-operative neurological improvement

	Univariate analysis (P)	Multivariate logistic regression test
Sex (female)	0.89	
Age	0.22	
Pre-symptomatic mRS (0–2)	0.93	
Location (non-cervical)	0.012	$P = 0.48$, OR 0.63, 95% CI 0.18–2.24
Number of feeders (single)	0.62	
Symptom (non-hemorrhagic)	0.01	$P = 0.11$, OR 0.23, 95% CI 0.04–1.37
Strategy of embolization (radical)	<0.01	$P = 0.14$, OR 2.32, 95% CI 0.75–7.19
Technical outcome (success)	0.13	
Obliteration of nidus (total occlusion)	<0.01	$P = 0.001$, OR 4.35, 95% CI 1.84–10.31
Complication (-)	0.92	

Characteristics and treatment outcome of SDAVF

Spinal dural arteriovenous fistula is the most common spinal vascular lesion^{3,6,7} and predominantly affects the thoracolumbar spine in middle-aged and older males, typically with a non-hemorrhagic onset in the majority of cases, as previously reported. Most non-hemorrhagic symptoms are caused by venous congestion, and early shunt obliteration can alleviate symptoms.⁸

Several reports have described the use of endovascular treatment to cure SDAVF.^{7,9} The rate of complete obliteration with liquid embolic agents is reported to be 55–90%.^{7,9–13} Treatment-related complications are 3.7–6.9%.^{14,15} As for postoperative neurological improvement, gait improvement is reported to be 40–100%,^{7,9,12} while urinary symptoms and sensory disturbance are less likely to improve.⁷

In the present study, total shunt obliteration was achieved in 54% of the cases, while subtotal obliteration was attained in an additional 22.1% of the cases. Treatment-related symptomatic complications occurred in 2.9% of the cases. An improvement in symptoms was obtained in 48.3%, and the symptoms were stabilized in 47.1%. Thus, the treatment outcome of the present study was comparable to those of previous reports.

On the other hand, the rate of complete obliteration by surgical treatment is reported to be 83–100%, stably higher than endovascular treatment.^{4,5,10,11,13,14} Treatment-related complications are reported to be low, ranged from 3.7 to 7.7%.^{14,15}

The rate of improvement or stabilization in neurological symptoms after surgical treatment is reported to be high with 89–93% of SDAVF cases.^{12,14)}

Postoperative neurological improvement was correlated with complete shunt obliteration in the presently reported series of patients. The goal of embolization for SDAVF should be complete obliteration. SDAVF is highly curable with surgical treatment and thus should be radically treated if complete obliteration cannot be achieved by endovascular means.^{4,5,14)}

The incidence of cervical lesions, which have more aggressive features than non-cervical lesions, obviously increased in JR-NET3, compared with JR-NET2. Postoperative neurological improvement was inversely correlated with occurrence in the cervical region. Since cervical SDAVF has different features, it should be considered separately.

Cervical SDAVF

Compared with non-cervical SDAVF, cervical SDAVF was characterized by a higher proportion of female patients ($P = 0.03$), a higher proportion of hemorrhagic onset ($P < 0.01$), fewer cases treated with radical embolization ($P = 0.03$), fewer cases with complete obliteration of the shunt ($P < 0.01$), more complications because of embolization ($P = 0.01$), and a smaller degree of post-treatment neurological improvement ($P = 0.03$).

Since spinal vascular lesions in the cranio-cervical junction (CCJ) to the upper cervical level are very complicated, a correct diagnosis might not have been made in many cases. Recently, the inclusion of high-resolution cone-beam CT in angiography machines has become popular, and this modality is very helpful for visualizing the detailed vascular structure. Advancements in imaging modalities may have contributed to the increased detection and recognition of cervical AVFs. Furthermore, disease concept of this area have been spread in Japanese neurosurgeons by educational activities and clinical researches. Hiramatsu et al.¹⁶⁾ reported a multicenter cohort study of 54 cases of CCJ AVFs. The authors analyzed the angiographic and clinical data of CCJ AVFs from 20 participating centers belonging to the JSNET. They divided CCJ AVFs into five angiographic types. Among patients with type 1 SDAVF, 82% were men and 50% had a subarachnoid hemorrhage onset. Endovascular surgery was performed in only 23%. The characteristics of a higher proportion of hemorrhagic onset and a lower percentage of cases treated with radical embolization are consistent with our results, except for the difference in the sex distribution. Further clarification of the characteristics of cervical vascular lesions are likely with additional improvements in diagnostic accuracy.

Prognostic factors for SDAVF

A mRS score of 0–2 on day 30 was achieved in 60.5% of the SDAVF cases, suggesting that endovascular treatment of symptomatic lesions does not result in a complete recovery of spinal cord function. A mRS score of 0–2 on day 30 was significantly correlated with only a pre-treatment mRS of 0–2 in univariate analyses. Thus, timely diagnosis and the early treatment of mild symptoms are important.

Study limitation

Our study had some limitations. Since this study was a subgroup analysis of the JR-NET2 and 3, the follow-up period was set at 30 days, corresponding to the follow-up period for various cerebrovascular disease. However, a follow-up period of 30 days might have been too short to evaluate neurological symptoms definitively in patients with spinal vascular lesions. The diagnosis of the vascular lesions was performed by the participating centers, and the angioarchitectures of the lesions were not examined by central investigators. Thus, some of the lesions might have been incorrectly diagnosed because of the complexity of these lesions. Kiyosue et al.¹⁷⁾ and the JSNET Spinal AV Shunts Study Group reported a retrospective analysis of the angiographic and clinical characteristics of 168 cases of thoracolumbar spinal epidural and DAVF in Japan. They found that 49% of spinal epidural AVFs were incorrectly diagnosed as SDAVF at individual centers.

Conclusion

Spinal dural arteriovenous fistula is the most common spinal vascular lesion in Japan, and endovascular treatment has been safely administered. The incidence of cervical SDAVF, which has more aggressive features than non-cervical lesions, has been increasing. Complete obliteration of the shunt was the only predictor of postoperative neurological improvement. Early diagnosis and complete obliteration of the shunt are important for improving the treatment outcome of SDAVF.

Acknowledgments

This study was supported in part by a Grant-in-Aid (Junkanki-Kaihatsu H24-4-3) from the National Cerebral and Cardiovascular Center, Japan and by Hatazaki Foundation, Kobe, Japan.

The JR-NET3 Study Group: Co-Principle investigator; Nobuyuki Sakai, Kobe City Medical Center General Hospital, Kobe, Japan; Koji Iihara, Kyushu University, Fukuoka, Japan, Tetsu Satow, National Cerebral and Cardiovascular Center, Suita, Japan; Investigators;

Masayuki Ezura, Sendai Medical Center, Sendai, Japan, Akio Hyodo, Dokkyo Medical University Saitama Medical Center, Koshigaya, Japan, Shigeru Miyachi, Aichi Medical University, Aichi, Japan, Susumu Miyamoto, Kyoto University, Kyoto, Japan, Yoji Nagai, Kobe University, Kobe, Japan, Kunihiro Nishimura, National Cerebral and Cardiovascular Center, Suita, Japan, Kazunori Toyoda, National Cerebral and Cardiovascular Center, Suita, Japan; Co-investigators; Toshiyuki Fujinaka, Osaka Medical Center, Osaka, Japan, Toshio Higashi, Fukuoka University, Fukuoka, Japan, Masaru Hirohata, Kurume University, Kurume, Japan, Akira Ishii, Kyoto University, Kyoto, Japan, Hirotohi Imamura, Kobe City Medical Center General Hospital, Kobe, Japan, Yasushi Ito, Shinrakuen Hospital, Niigata, Japan, Naoya Kuwayama, Toyama University, Toyama, Japan, Hidenori Oishi, Juntendo University, Tokyo, Japan, Yuji Matsumaru, Tsukuba University, Tsukuba, Japan, Yasushi Matsumoto, Konan Hospital, Sendai, Japan, Ichiro Nakahara, Fujita Medical University, Aichi, Japan, Chiaki Sakai, Hyogo College of Medicine, Nishinomiya, Japan, Kenji Sugi, Okayama University, Okayama, Japan, Tomoaki Terada, Showa University Fujigaoka Hospital, Kanagawa, Japan, Shinichi Yoshimura, Hyogo College of Medicine, Nishinomiya, Japan, and Certified Specialist of Japanese Society of Neuroendovascular Therapy.

Conflicts of Interest Disclosure

The authors report no conflict of interest relevant to the research. All authors who are members of The Japan Neurosurgical Society have registered online Self-reported COI Disclosure Statement Forms.

References

- 1) Sakai N, Yoshimura S, Taki W, et al.: Recent trends in neuroendovascular therapy in Japan: analysis of a nationwide survey—Japanese Registry of Neuroendovascular Therapy (JR-NET) 1 and 2. *Neurol Med Chir (Tokyo)* 54: 1–8, 2014
- 2) Tsuruta W, Matsumaru Y, Miyachi S, Sakai N: Endovascular treatment of spinal vascular lesion in Japan: Japanese Registry of Neuroendovascular Therapy (JR-NET) and JR-NET2. *Neurol Med Chir (Tokyo)* 54: 72–78, 2014
- 3) Berenstein A, Lasjaunias P, ter Brugge KG: Spinal dural arteriovenous fistulae. In Berenstein A, Lasjaunias P, ter Brugge KG (eds): *Surgical Neuroangiography*, ed 2. Vol. 2.2, Berlin Heidelberg, 2004, Springer-Verlag, pp. 849–872
- 4) Narvid J, Hetts SW, Larsen D, et al.: Spinal dural arteriovenous fistulae: clinical features and long-term results. *Neurosurgery* 62: 159–166; discussion 166–167, 2008

- 5) Saladino A, Atkinson JL, Rabinstein AA, et al.: Surgical treatment of spinal dural arteriovenous fistulae: a consecutive series of 154 patients. *Neurosurgery* 67: 1350–1357; discussion 1357–1358, 2010
- 6) Gilbertson JR, Miller GM, Goldman MS, Marsh WR: Spinal dural arteriovenous fistulas: MR and myelographic findings. *AJNR Am J Neuroradiol* 16: 2049–2057, 1995
- 7) Sivakumar W, Zada G, Yashar P, Giannotta SL, Teitelbaum G, Larsen DW: Endovascular management of spinal dural arteriovenous fistulas. A review. *Neurosurg Focus* 26: E15, 2009
- 8) Safaee MM, Clark AJ, Burkhardt JK, Winkler EA, Lawton MT: Timing, severity of deficits, and clinical improvement after surgery for spinal dural arteriovenous fistulas. *J Neurosurg Spine* 29: 85–91, 2018
- 9) Niimi Y, Berenstein A, Setton A, Neophytides A: Embolization of spinal dural arteriovenous fistulae: results and follow-up. *Neurosurgery* 40: 675–682; discussion 682–683, 1997
- 10) Bretonnier M, Hénaux PL, Gaberel T, et al.: Spinal dural arteriovenous fistulas: clinical outcome after surgery versus embolization: a retrospective study. *World Neurosurg* 127: e943–e949, 2019
- 11) Durnford AJ, Hempenstall J, Sadek AR, et al.: Degree and duration of functional improvement on long-term follow-up of spinal dural arteriovenous fistulae occluded by endovascular and surgical treatment. *World Neurosurg* 107: 488–494, 2017
- 12) Open and endovascular treatment of spinal dural arteriovenous fistulas: a 10-year experience. *J Neurosurg Spine* 26: 519–523, 2017
- 13) Bakker NA, Uyttenboogaart M, Luijckx GJ, et al.: Recurrence rates after surgical or endovascular treatment of spinal dural arteriovenous fistulas: a meta-analysis. *Neurosurgery* 77: 137–144, 2015
- 14) Steinmetz MP, Chow MM, Krishnaney AA, et al.: Outcome after the treatment of spinal dural arteriovenous fistulae: a contemporary single-institution series and meta-analysis. *Neurosurgery* 55: 77–87; discussion 87–88, 2004
- 15) Goyal A, Cesare J, Lu VM, et al.: Outcomes following surgical versus endovascular treatment of spinal dural arteriovenous fistula: a systematic review and meta-analysis. *J Neurol Neurosurg Psychiatry* 90: 1139–1146, 2019
- 16) Hiramatsu M, Sugiu K, Ishiguro T, et al.: Angioarchitecture of arteriovenous fistulas at the craniocervical junction: a multicenter cohort study of 54 patients. *J Neurosurg* 128: 1839–1849, 2018
- 17) Kiyosue H, Matsumaru Y, Niimi Y, et al.: Angiographic and clinical characteristics of thoracolumbar spinal epidural and dural arteriovenous fistulas. *Stroke* 48: 3215–3222, 2017

Address reprint requests to: Yuji Matsumaru, MD, PhD, Division for Stroke, Department of Neurosurgery, Faculty of Medicine, University of Tsukuba, 2-1-1, Amakubo, Tsukuba, Ibaraki 305-8576, Japan.
e-mail: yujimatsumaru@md.tsukuba.ac.jp