



Contents lists available at ScienceDirect

International Journal of Surgery Case Reports

journal homepage: www.casereports.com

Uterine preservation in pelvic organ prolapse and urinary stress incontinence using robot-assisted laparoscopic surgery. Case report

Gaspere Cucinella^a, Silvia Culmone^a, Ettore Guastella^a, Francesco Gentile^a,
Francesca De Maria^a, Roberto Granà^a, Bruno Carlisi^a, Stefano Rotolo^{b,c}, Gloria Calagna^{a,*}

^a Obstetrics and Gynecology, “Villa Sofia Cervello” Hospital, University of Palermo, Italy

^b Department of Surgical, Oncological and Oral Sciences (Di.Chir.On.S.), University of Palermo, Italy

^c Division of General Surgery, Fondazione, Policlinico Universitario A. Gemelli IRCCS, Rome, Italy

ARTICLE INFO

Article history:

Received 20 June 2020

Received in revised form 27 August 2020

Accepted 27 August 2020

Available online 4 September 2020

Keywords:

Sacrohysteropexy

Robot-assisted laparoscopy

Retropubic colposuspension

Pelvic organ prolapse

Robotic

ABSTRACT

INTRODUCTION: To report a case of uterine preservation in pelvic organ prolapse robot-assisted laparoscopic surgery.

PRESENTATION OF CASE: The patient is a 42-year old Caucasian woman with pelvic organ prolapse. She previously had undergone a pelvic floor reconstruction with vaginal surgical approach, she had suffered from anorexia nervosa and she had two childbirths with vaginal deliveries. The woman was treated with robotic-assisted laparoscopic sacrohysteropexy and retropubic colposuspension.

DISCUSSION: Data suggest that abdominal surgery, typically with an abdominal sacralcolpopexy, provides better objective anatomic outcomes, than vaginal procedures, despite the longer operating times and greater delay in the resumption of activities which can be mitigated by the use of laparoscopic or robotic surgery. Several studies about vaginal approaches suggest that uterus-preserving surgery with vaginal procedures have similar success rates, less blood loss and shorter surgical time compared with hysterectomy. A multicenter study compared laparoscopic sacrohysteropexy with vaginal mesh hysteropexy reported similar one-year cure rates, improvement in pelvic floor symptoms, improvement in sexual function, and satisfaction rates.

CONCLUSION: We found robotic-assisted laparoscopic sacrohysteropexy to be a feasible and successful procedure. Combining robotic retropubic colposuspension to sacrohysteropexy is a safe and efficient approach for the treatment of stress urinary incontinence. Further studies are needed to define the standard surgical steps and confirm the efficacy and the advantages of this procedure.

© 2020 Published by Elsevier Ltd on behalf of IJS Publishing Group Ltd. This is an open access article under the CC BY-NC-ND license (<http://creativecommons.org/licenses/by-nc-nd/4.0/>).

1. Introduction

Pelvic organ prolapse (POP) represents a common and bothersome condition in parous women. Studies on the subjective symptoms estimate the prevalence between 2.9% and 8.3% while data based on objective gynecological examination estimate the prevalence as high as 50% [1,2]. For many years, abdominal sacralcolpopexy was considered the gold standard of care. More recently, major concerns about fertility or the rising wish to preserve body integrity have questioned the need to perform hysterectomy at the time of POP surgery [3]. The refinements in the operative technique and the introduction of minimally invasive surgery, have

also encouraged surgeons to reconsider uterine preservation and implement “saving” uterus techniques [4].

Here we reported a case of a woman with recurrent POP, treated with a robotic-assisted laparoscopic sacrohysteropexy (RALHSP) to preserve the uterus for future fertility.

2. Case report

A 42-year-old Caucasian woman presented to our Obstetrics and Gynecology Unit complaining utero-vaginal bulging, intermittent dyspareunia, constipation and stress urinary incontinence (SUI) from about one year. Her medical history revealed two childbirths with vaginal delivery and previous anorexia nervosa (when she was adolescent). After the first delivery, the patient showed a 2nd degree prolapse, strangely symptomatic (also persistent after pelvic rehabilitation) and, consequently, she required surgery; she underwent pelvic floor reconstruction surgery for symptomatic POP by vaginal surgical approach with the use of transvaginal mesh:

* Corresponding author at: Obstetrics and Gynecology, “Villa Sofia Cervello” Hospital, University of Palermo – via Trabucco 180, 90100 Palermo, Italy.
E-mail address: gloria.calagna83@gmail.com (G. Calagna).

symptoms of prolapse reappeared after the second delivery. The case was reported in line with the SCARE 2018 criteria [5].

The woman performed the pre-operative diagnostic tests. The physical examination demonstrated a three-stage utero-vaginal prolapse using the POP-Q classification system [6]. SUI was diagnosed based on urodynamic study. Her body mass index was 31 kg/m². HPV DNA was negative and the Papanicolaou smear test was normal. On transvaginal ultrasound, the dimensions of the uterus were compatible with the patient's age, and no myometrial or adnexal pathology was detected. As a prolapse recurrence, other options such as pelvic exercises or pessary were not taken into account. Surgical options were explained to the patients; however, despite age and her obstetrical history, she was strongly motivated to preserve the uterus for her sexual health, as well as for a possible future pregnancy. In fact, the sexual well-being and related quality of life were central aspects in the decision making process, mainly focusing on the possible psychological repercussions in case of hysterectomy. Written informed consent was obtained from the patient prior to surgery.

2.1. Surgical technique

The surgery was performed with the DaVinci Si Surgical System (Intuitive Surgical, Inc., CA, USA). The patient was placed, under general endotracheal anaesthesia, in a lithotomy position. After the disinfection of abdominal, vaginal and external genitalia, a sterile catheter was placed in the bladder and a ClearView™ - disposable uterine manipulator (Clinical Innovations LLC, Murray, UT, USA) was placed, to mobilize the uterus during the procedure. After a vertical skin incision was made in the umbilicus, the abdominal cavity was entered using the open technique. We used one camera port (12-mm umbilical port for the laparoscope with a 0° camera) and two robotic arms (two 8-mm robotic ports placed 2 cm lower umbilical line and 10 cm on either side of the midline); a fourth 10 mm trocar was placed in the right upper quadrant as an assistant laparoscopic port. A 20° Trendelenburg position was obtained to ensure the visibility of the whole pelvis. The robot was placed to the left of the patient and docked.

After mobilization of small bowel out of the pelvis and lateral traction of the sigmoid colon, surgeons performed the incision of the peritoneum above the sacral promontory and the adequate dissection of underlying tissue as follows; identification of the right ureter and the superior hypogastric plexus with its two distal branches division of the overlying tissue of the sacral periosteum and creation of a peritoneal tunnel from the sacral promontory to the uterosacral ligament. This step aims to prepare the way to pass the mesh once fixed to vaginal walls.

The bladder was mobilized from the cervix to expose about 3 cm of the underlying pubo-cervical fascia; the rectovaginal space was developed using blunt dissection to expose the rectovaginal fascia. Two windows were made into the broad ligaments of both sides at the level of the cervico-uterine junction (lateral and ventral to the uterine artery), taking care to avoid damage to the uterine arteries and fallopian tubes. We used a titanium-coated polypropylene mesh in a "T" shaped (Covidien Surgipro). The arms of the mesh were pulled through the bilateral windows in the broad ligaments and anchored with non-absorbable monofilament sutures to the anterior and posterior vaginal walls (Fig. 1A,B). The anterior and posterior arms of the meshes are then combined and drawn through the peritoneal tunnel, which was created earlier; the distal end of the mesh is finally fixed without tension to the anterior longitudinal ligament of the sacrum with a non-absorbable suture (Fig. 1C,D). The peritoneum was closed over the mesh with an absorbable multifilament suture.

Based on the preoperative diagnosis of SUI, the retropubic colposuspension was successively performed. The Retzius's space

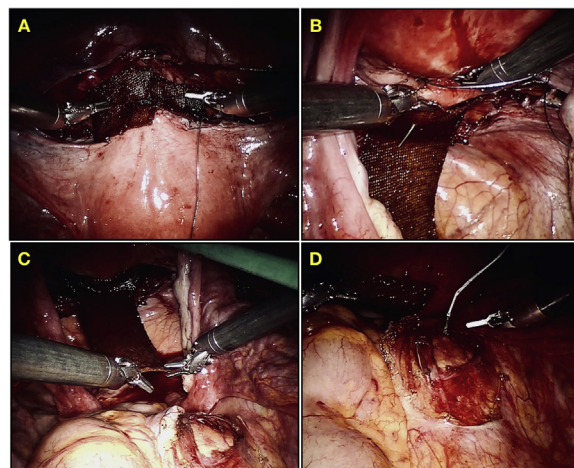


Fig. 1. Procedures of robotic sacrohysteropexy. Fixation of the mesh on the anterior (A) and posterior (B) vaginal wall. Positioning and fixation of the mesh at sacral promontory (C-D).

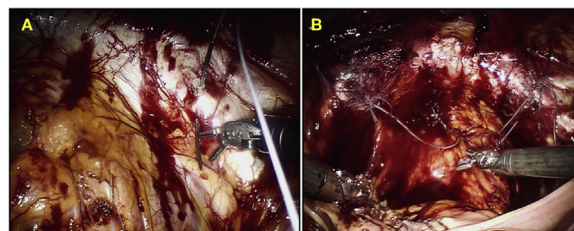


Fig. 2. Retropubic colposuspension. Passage of suture through right Cooper ligament (A) and final view of end result (B).

was dissected bilaterally after opening the anterior parietal peritoneum; two non-absorbable stitches were then placed through the endopelvic and vaginal fascial complex, using the index finger to determine the appropriate depth (care should be taken to not violate the vaginal mucosa). The most cephalad suture is usually placed at the level of the bladder neck (2 cm lateral), and sutures are placed about 1 cm apart caudally. The vaginal sutures are then passed through Cooper ligament and tied with an appropriate tension (2 to 4 cm suture bridge between vagina and Cooper ligament) (Fig. 2A,B). The peritoneum then was closed with absorbable multifilament suture. The operating time was 115 minutes and there was only minimal blood loss (250 cc).

The patient was discharged on the third day in good general conditions, afebrile, without any symptom/sign of prolapse and with negative lab tests. Patient returned to daily activities 9 days after surgery. The patient follow-up and physical examination were performed at 6 weeks and 6 months, showing good general condition, no abdominal pain and no recurrence of prolapse nor symptoms of urinary incontinence.

3. Discussion

Hysterectomy is a reasonable option in women with symptomatic and/or advanced POP (or in presence of risk factors for prolapse progression), and in patients who have exhausted their reproductive desire [7] and abdominal sacralcolpopexy, traditionally performed in association with hysterectomy, was considered the standard of care in these cases. However, the longer operative times, the greater delay in the resumption of activities, a relatively high degree of morbidity, and the need for uterine conservation contributed to the turning up of the vaginal approaches for POP surgery [8]. While most of these limitations have been mitigated

by the increased use of laparoscopy or robot-assisted surgery, the demand to “save” the uterus has fuelled a renewal of the surgical technique [9–11]. Indeed, based on the encouraging outcomes of minimal invasive sacrohysteropexy, the advantages of an abdominal pelvic reconstructive surgery with uterine preservation were emphasized: these include respect of pelvic anatomical support, reduced intraoperative blood loss and faster recovery time; moreover, sacrohysteropexy is associated with less mesh exposure as it avoids placing a foreign body near the colpotomy site [3,12,13]. Besides, maintaining reproductive potential is a major concern and must be considered for all those women who express this desire. Finally, hysterectomy poses an increased risk of pelvic neuropathy [14] and may adversely affect self-sexuality and self-confidence. Barranger et al. reported pregnancy after uterus-sparing surgery for prolapse in 3 young patients; moreover, Lewis and Culligan reported a case report of a 35-year-old patient, para 2, undergoing laparoscopic sacrohysteropexy and sub-urethral sling, who conceived 6 months after the procedure and with no signs of prolapse at follow-up [15,16].

Robotic surgery was conceived with the intent to overcome the limitations of laparoscopic surgery (magnified 3-dimensional image, robotic manoeuvrability, tremor filtration) maintaining the positive aspects of mini-invasive surgery [11,17,18]. In the last years, several authors proposed the use of robotic surgery in the conservative management of POP with promising results [19–21]. In 2012, Vitobello et al. Described their initial experience on RALHSP in two 35-year-old women who had POP stage III without urodynamic abnormalities. The procedures were successfully completed in 120 and 135 min, respectively, with negligible blood loss; at a follow-up of 18 and 6 months, no woman showed POP recurrence without any mesh exposure or vaginal erosion [22]. More recently, Cerruto et al reported the results and complication rates in a first series of fifteen female patients with uterine prolapse stage \geq II and urodynamic SUI, who had undergone RALHSP. They confirmed that RALHSP is easy to perform, with satisfying mid-term outcomes and a low complication rate [19]. Our first experience resulted in a feasible and successful procedure, performed in experienced hands; operative time was similar to those reported in the literature as it was the postoperative course. Concerning, the type of mesh, tetanized polypropylene lightweight mesh could be considered a further aspect noteworthy, generally associated to a lower inflammatory response and has a better histocompatibility than conventional polypropylene ones. Larger studies with adequate follow-up are needed, however, to determine recurrence rates and complications of this procedure.

4. Conclusion

There are few studies about conservative management of POP using RALHSP. The characteristics of the robotic system, with more precise and careful movements and lower damage of tissues, would help surgeons perform easy and precise surgery. Further studies are necessary to standardization and to confirm the advantage of this technique.

Declaration of Competing Interest

All authors have no conflicts of interest to disclose.

Funding

In this study, sponsors had no such involvement.

Ethical approval

No specific ethical approval was necessary.

Consent

Written informed consent was obtained from the patient for publication of this case report and accompanying images. A copy of the written consent is available for review by the Editor-in-Chief of this journal on request.

Author contribution

Cucinella G: study concept, data interpretation.
Calagna G: study design, writing the paper.
Culmone S: writing paper.
Guastella E, Gentile F: data analysis.
De Maria F, Granà R, Carlisi B: data collection.
Rotolo S: data interpretation.

Registration of research studies

N/A.

Guarantor

Cucinella Gaspare, Calagna Gloria.

Provenance and peer review

Not commissioned, externally peer-reviewed.

Acknowledgement

This article is part of a supplement entitled Case reports from Italian young surgeons, published with support from the Department of Surgical, Oncological and Oral Sciences – University of Palermo.

This research did not receive any specific grant from funding agencies in the public, commercial, or not-for-profit sectors.

References

- [1] I. Nygaard, M.D. Barber, K.L. Burgio, K. Kenton, S. Meikle, J. Schaffer, et al., Prevalence of symptomatic pelvic floor disorders in US women, *JAMA* 300 (11) (2008) 1311–1316.
- [2] M.D. Barber, C. Mather, Epidemiology and outcome assessment of pelvic organ prolapse, *Int. Urogynecol. J.* 24 (11) (2013) 1783–1790.
- [3] N.B. Korbly, N.C. Kassis, M.M. Good, M.L. Richardson, N.M. Book, S. Yip, et al., Patient preferences for uterine preservation and hysterectomy in women with pelvic organ prolapse, *Am. J. Obstet. Gynecol.* 209 (5) (2013) 470.e1–6.
- [4] M.F. Paraiso, J.E. Jelovsek, A. Frick, C.C. Chen, M.D. Barber, Laparoscopic compared with robotic sacrocolpopexy for vaginal prolapse: a randomized controlled trial, *Obstet. Gynecol.* 118 (5) (2011) 1005–1013.
- [5] R.A. Agha, M.R. Borrelli, R. Farwana, K. Koshy, A. Fowler, D.P. Orgill, For the SCARE Group, The SCARE 2018 Statement: Updating Consensus Surgical Case Report (SCARE) Guidelines, *Int. J. Surg.* 60 (2018) 132–136.
- [6] C. Persu, C.R. Chapple, V. Cauni, S. Gutue, P. Geavlete, Pelvic Organ Prolapse Quantification System (POP-Q) – a new era in pelvic prolapse staging, *J. Med. Life* 4 (1) (2011) 75–81.
- [7] F.J. Smith, C.D. Holman, R.E. Moorin, N. Tsokos, Lifetime risk of undergoing surgery for pelvic organ prolapse, *Obstet. Gynecol.* 116 (5) (2010) 1096–1100.
- [8] N.Y. Siddiqui, C.L. Grimes, E.R. Casiano, H.T. Abed, P.C. Jeppson, C.K. Olivera, et al., Mesh sacrocolpopexy compared with native tissue vaginal repair: a systematic review and meta-analysis, *Obstet. Gynecol.* 125 (1) (2015) 44–55.
- [9] P. Szymczak, M.E. Grzybowska, D.G. Wydra, Comparison of laparoscopic techniques for apical organ prolapse repair – a systematic review of the literature, *Neurourol. Urodyn.* 38 (8) (2019) 2031–2050.
- [10] M.F. Paraiso, M.D. Walters, R.R. Rackley, S. Melek, C. Hugney, Laparoscopic and abdominal sacral colpopexies: a comparative cohort study, *Am. J. Obstet. Gynecol.* 192 (5) (2005) 1752–1758.

- [11] G. Cucinella, G. Calagna, G. Romano, G. Di Buono, G. Gugliotta, S. Saitta, et al., Robotic versus laparoscopic sacrocolpopexy for apical prolapse: a case-control study, *G Chir.* 37 (3) (2016) 113–117.
- [12] B.M. Ridgeway, Does prolapse equal hysterectomy? The role of uterine conservation in women with uterovaginal prolapse, *Am. J. Obstet. Gynecol.* 213 (6) (2015) 802–809.
- [13] R. Gutman, C. Maher, Uterine-preserving POP surgery, *Int. Urogynecol. J.* 24 (11) (2013) 1803–1813.
- [14] R.E. Nesbitt, Uterine preservation in the surgical management of genuine stress urinary incontinence associated with uterovaginal prolapse, *Surg. Gynecol. Obstet.* 168 (2) (1989) 143–147.
- [15] E. Barranger, X. Fritel, A. Pigne, Abdominal sacrohysteropexy in young women with uterovaginal prolapse: long-term follow-up, *Am. J. Obstet. Gynecol.* 189 (5) (2003) 1245–1250.
- [16] C.M. Lewis, P. Culligan, Sacrohysteropexy followed by successful pregnancy and eventual reoperation for prolapse, *Int. Urogynecol. J.* 23 (7) (2012) 957–959.
- [17] E.J. Geller, N.Y. Siddiqui, J.M. Wu, A.G. Visco, Short-term outcomes of robotic sacrocolpopexy compared with abdominal sacrocolpopexy, *Obstet. Gynecol.* 112 (6) (2008) 1201–1206.
- [18] G. Corrado, G. Calagna, G. Cutillo, S. Insinga, E. Mancini, E. Baiocco, et al., The patient and observer scar assessment scale to evaluate the cosmetic outcomes of the robotic single-site hysterectomy in endometrial cancer, *Int. J. Gynecol. Cancer* 28 (1) (2018) 194–199.
- [19] M.A. Cerruto, C. D'Elia, F.M. Cavicchioli, S. Cavalleri, M. Balzarro, A.B. Porcaro, et al., Outcomes and postoperative complications of robot-assisted laparoscopic hysterectomy: initial experience, *Urol. Int.* 95 (1) (2015) 44–49.
- [20] J. Paek, M. Lee, B.W. Kim, Y. Kwon, Robotic or laparoscopic sacrohysteropexy versus open sacrohysteropexy for uterus preservation in pelvic organ prolapse, *Int. Urogynecol. J.* 27 (4) (2016) 593–599.
- [21] O. Ramm, K. Kenton, Robotic/laparoscopic prolapse repair: role of hysteropexy: a urogynecology perspective, *Urol. Clin. North Am.* 39 (3) (2012) 343–348.
- [22] D. Vitobello, G. Siesto, C. Bulletti, Robotic sacral hysteropexy for pelvic organ prolapse, *Int. J. Med. Robot.* 8 (1) (2012) 114–117.

Open Access

This article is published Open Access at [sciencedirect.com](https://www.sciencedirect.com). It is distributed under the [IJSCR Supplemental terms and conditions](#), which permits unrestricted non commercial use, distribution, and reproduction in any medium, provided the original authors and source are credited.