

# Cerebral monitoring during carotid endarterectomy by transcranial Doppler ultrasonography

Woo-Sung Yun

Division of Transplantation and Vascular Surgery, Department of Surgery, Yeungnam University Medical Center, Yeungnam University College of Medicine, Daegu, Korea

**Purpose:** To evaluate the efficacy and safety of cerebral monitoring by transcranial Doppler ultrasonography (TCD) for the detection of cerebral ischemia during carotid endarterectomy (CEA).

**Methods:** From August 2004 to December 2013, 159 CEAs were performed in a tertiary hospital. All procedures were performed under general anesthesia. Intraoperative TCD was routinely used to detect cerebral ischemia. Of the 159 patients, 102 patients were included in this study, excluding 27 patients who had a poor transtemporal isonation window and 30 patients who used additional cerebral monitoring systems such as electroencephalography or somatosensory evoked potentials. When mean flow velocity in the ipsilateral middle cerebral artery decreased by >50% versus baseline during carotid clamping carotid shunting was selectively performed. The carotid shunt rate and incidence of perioperative (<30 days) stroke or death were investigated by reviewing medical records.

**Results:** Carotid shunting was performed in 31 of the 102 patients (30%). Perioperative stroke occurred in 2 patients (2%); a minor ischemic stroke caused by embolism in one and an intracerebral hemorrhage in the other. Perioperative death developed in the latter patient.

**Conclusion:** TCD is a safe cerebral monitoring tool to detect cerebral ischemia during CEA. It can reduce use of carotid shunt.

[Ann Surg Treat Res 2017;92(2):105-109]

**Key Words:** Carotid endarterectomy, Transcranial Doppler ultrasonography

## INTRODUCTION

Based on the results of large-scale clinical studies [1-5], carotid endarterectomy (CEA) has been recommended for symptomatic and asymptomatic patients with high-grade carotid artery stenosis [6]. Safety has been emphasized during the procedure, because of the possibilities of disabling or nondisabling stroke. The majority of patients tolerate temporary interruption of cerebral blood flow during CEA, but cerebral ischemia may develop in patients with inadequate collateral channels. Carotid shunting guarantees adequate cerebral blood flow during carotid clamping, but its routine use is controversial [7].

Selective shunting has theoretical advantages over routine shunting, because of possible adverse effects, which include intimal damage or dissection, distal embolization, and acute occlusion. Furthermore, shunt placement requires more distal exposure of the ICA, and this may be challenging in patients with a high lesion. Neurologic monitoring of awake patients under local or regional anesthesia provides the most reliable means of identifying candidates for selective shunting [8-11], but it cannot be used under general anesthesia. Accordingly, many surgeons that favor general anesthesia adopt routine shunting. On the other hand, other surgeons use selective shunting and intraoperative monitoring by transcranial

Received July 8, 2016, Revised September 6, 2016,

Accepted September 19, 2016

**Corresponding Author: Woo-Sung Yun**

Division of Transplantation and Vascular Surgery, Department of Surgery, Yeungnam University Medical Center, Yeungnam University College of Medicine, 170 Hyeonchung-ro, Nam-gu, Daegu 42415, Korea

Tel: +82-53-620-3580, Fax: +82-53-624-1213

E-mail: wsyun@ynu.ac.kr

Copyright © 2017, the Korean Surgical Society

© Annals of Surgical Treatment and Research is an Open Access Journal. All articles are distributed under the terms of the Creative Commons Attribution Non-Commercial License (<http://creativecommons.org/licenses/by-nc/4.0/>) which permits unrestricted non-commercial use, distribution, and reproduction in any medium, provided the original work is properly cited.

Doppler ultrasonography (TCD), electroencephalography (EEG), somatosensory evoked potential (SSEP), near infrared spectroscopy, or carotid stump pressure. However, optimal methods for detection of cerebral ischemia remain controversial [12].

The aim of this study was to evaluate efficacy and safety of cerebral monitoring by TCD for the detection of cerebral ischemia during CEA.

## METHODS

### Patients

One hundred fifty-nine patients that underwent CEA from August 2004 to December 2013 were retrospectively reviewed. All CEA were done under general anesthesia. Intraoperative TCD was routinely used to detect cerebral ischemia. Of these 159 patients, 27 patients were excluded for a poor transtemporal isonation window and 30 because additional cerebral monitoring systems, such as, EEG or SSEP, were used. Accordingly, 102 patients constituted the study cohort. Patients with monocular blindness or that had experienced a transient ischemic attack or ischemic stroke within the previous 6 months were regarded as symptomatic. Patient and lesion characteristics are summarized in Table 1. Patient mean age was 66 years (43–78 years), 92% were male, 75% were symptomatic, and 81% had severe (>70%) internal carotid artery (ICA) stenosis. Nine patients had contralateral ICA stenosis exceeding 50%.

### Carotid endarterectomy

All CEAs were performed under general anesthesia with the use of nitrous oxide and halothane or isoflurane. Before carotid clamping, heparin was administered intravenously; protamine reversal was not used. The eversion technique was used in 56 patients (55%) and conventional CEA in 46 patients (45%, 36 primary closures and 10 patch closures).

### TCD monitoring

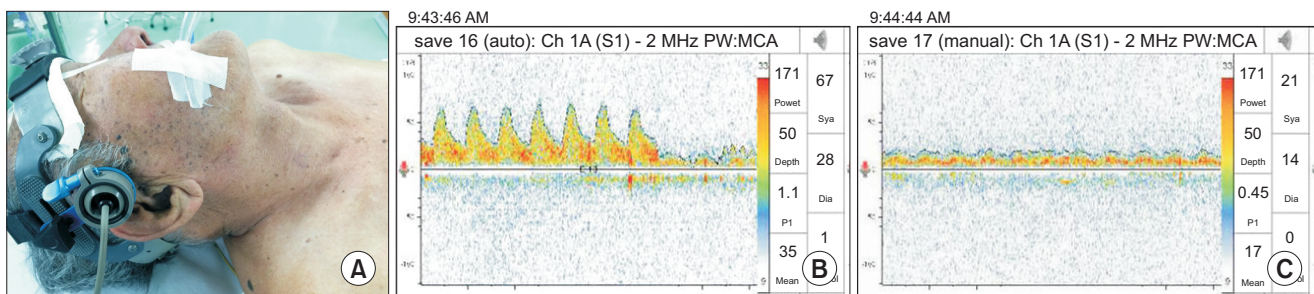
Intraoperative TCD monitoring was performed using a TC8080 (Pioneer TC 8080, Nicolet Vascular, Madison, WI, USA)

(Fig. 1A). Mean flow velocity (MFV) of the ipsilateral middle cerebral artery (MCA) was monitored before and after carotid clamping (Fig. 1B, C). And the mean blood pressure (MBP) was also checked at the same time. The criterion for selective shunting was a MFV reduction >50% after carotid clamping versus baseline.

**Table 1.** Patient demographic data and lesion characteristics

Variable	Value
Age (yr), mean (range)	66 (43–78)
Male sex	94 (92)
Smoking	50 (49)
Comorbidities	
Hypertension	73 (72)
Diabetes mellitus	42 (41)
Coronary artery disease	11 (11)
Hyperlipidemia	34 (33)
Indications	
Symptomatic	76 (75)
Asymptomatic	26 (26)
Lesion site	
Right	52 (51)
Left	50 (49)
Ipsilateral ICA stenosis degree (%)	
≥70	83 (81)
50–69	19 (19)
Level of stenosis	
C2	6 (6)
C2–3	18 (18)
C3	40 (39)
C3–4	22 (22)
≤C4	16 (16)
Ulcerative lesion	26 (26)
Contralateral ICA stenosis degree (%)	
≥70	2 (2)
50–69	7 (7)
<50	93 (90)

Values are presented as mean (range) or number (%). ICA, internal carotid artery.



**Fig. 1.** Intraoperative transcranial Doppler (TCD) monitoring. (A) A hands-free standard 2-MHz pulsed wave TCD transducer was positioned on the ipsilateral temporal bone window with head frame. Mean flow velocity of the ipsilateral middle cerebral artery (MCA) was measured before (B) and after (C) carotid clamping.

**Table 2.** Change of MFV of ipsilateral MCA after carotid clamping

Change of MFV	No (%)	Mean preclamp MBP (mmHg)	Mean postclamp MBP (mmHg)
<b>Decrease</b>			
91%–100%	7 (7)	93	83
81%–90%	2 (2)	85	86
71%–80%	4 (4)	78	101
61%–70%	4 (4)	94	99
51%–60%	14 (14)	79	90
41%–50%	4 (4)	95	92
31%–40%	13 (13)	90	88
21%–30%	18 (18)	89	91
11%–20%	12 (12)	86	80
0%–10%	13 (13)	91	97
<b>Increase</b>			
1%–10%	6 (6)	88	96
11%–20%	3 (3)	95	96
21%–30%	1 (1)	79	98
31%–40%	-	-	-
41%–50%	-	-	-
51%–60%	1 (1)	116	133

MFV, mean flow velocity; MCA, middle cerebral artery; MBP, mean blood pressure.

## Outcomes

Shunt rate and the incidences of early postoperative (<30 days) stroke or death were used to evaluate the efficacy and safety of TCD monitoring.

## RESULTS

Mean preclamp ipsilateral MCA MFV and MBP were 50 cm/sec (21–123 cm/sec) and 88 mmHg (47–130 mmHg), and mean postclamp ipsilateral MFV and MBP were 32 cm/sec (0–106 cm/sec) and 91 (60–144 mmHg). Table 2 shows MFV change after carotid clamping. The mean decrease in ipsilateral MFV was 33% (-56%–100%). Of the 102 patients, 31 (30%) showed an ipsilateral MFV decrease >50% after carotid clamping, and carotid shunting was performed in all these patients. Accordingly, the shunt rate was 30%.

Regarding early postoperative outcomes, perioperative stroke occurred in 2 patients (2%). One minor ischemic stroke caused by embolism occurred in a patient without a carotid shunt. The other was due to intracerebral hemorrhage (ICH) caused by hyperperfusion syndrome. One perioperative death developed in the patient with hyperperfusion syndrome.

## DISCUSSION

Type of anesthesia (general vs. locoregional) remains a controversial issued for CEA. A large randomized controlled

trial failed to identify a definite difference between general and local anesthesia with respect to the incidences of stroke, myocardial infarction, or death [13]. One of the theoretical benefits of locoregional anesthesia is a lower carotid shunt rate. Reported shunt rates from the awake test range from 4.4% to 14% [8-11], and patients with contralateral ICA occlusion required carotid shunting more frequently than those with a unilateral lesion [9,14]. To reduce shunt rates during general anesthesia, several intraoperative monitoring modalities have been introduced. TCD is one of these modalities and concerns have been expressed regarding its safety and efficacy.

TCD cannot determine the presence of cerebral ischemia precisely during carotid clamping. Reported values for the sensitivity and specificity of TCD for predicting the need for carotid shunting range from 75% to 83% and from 75% to 96%, respectively, although these values depend on the cutoff used [15,16]. Moritz et al. [17] investigated the accuracies of monitoring tools with respect to the detection of cerebral ischemia during CEA. In this previous study, the cutoff value for 100% sensitivity for TCD was determined to be a 48% reduction in ipsilateral MCA MFV versus baseline, the cutoff for 100% specificity was 70%. And the best fit cutoff value was 48%, which provided a sensitivity of 100% and a specificity of 86%, because safety is most important in carotid surgery. In the present study, our shunt criterion was similar to their result. No patient that did not undergo carotid shunting experienced cerebral ischemia during carotid clamping. Therefore, it would appear that a reduction in ipsilateral MCA MFV of >50% as determined by TCD is a safe criterion for shunt placement to prevent cerebral ischemia during carotid clamping. However, the overall shunt rate was 30%, which is greater than previously reported shunt rates from the awake test. This elevated rate was presumably due to false-positives. If the cutoff value is lowered, unnecessary shunting would be avoided. However, it will increase a risk of missing cerebral ischemia. Therefore, to determine an optimal TCD criterion that has lowest shunt rate and do not make cerebral ischemia during carotid clamp, additional large-scale clinical studies are necessary.

Delayed shunt occlusion is a complication of carotid shunting [18-20]. Kink of shunt or adhesion of the shunt stump to the arterial wall could cause shunt malfunction. Furthermore, carotid shunt occlusion would not be recognized in the absence of cerebral ischemia monitoring. If these anomalies are not corrected immediately, cerebral ischemia may result. On the other hand, continuous TCD monitoring can confirm shunt patency and represents an additional benefit of TCD.

TCD monitoring not only provides information on hemodynamic changes but also enables the detection of cerebral microembolism. Ackerstaff et al. [21] reported the outcomes of 1,058 patients that underwent CEA with TCD monitoring. They found 31 patients with ischemic stroke and 8 patients

with hemorrhagic stroke. TCD-detected microembolism during dissection and wound closure,  $\geq 90\%$  MCA velocity decrease at carotid clamping and  $\geq 100\%$  increase of pulsatile index (PI) were associated with perioperative stroke or stroke-related death. It was suggested that information on microembolization can caution surgeons regarding they need for more careful dissection or early carotid clamping and TCD monitoring is a sensitive tool for the prediction of postoperative hyperperfusion syndrome. In our series, the low sample size prevented our analyzing the association between microembolism and stroke. Regarding hyperperfusion syndrome, the patient that died of ICH showed an increase in PI of 92% after CEA.

Summarizing, TCD monitoring was found to be a safe modality for indicating the need for selective shunting during CEA. For patients that exhibited an ipsilateral MCA MFV

reduction of  $\leq 50\%$ , carotid clamping could be done without a carotid shunt. Although the technical limitations of TCD were apparent as 10%–15% of patients did not have an adequate temporal window [22], its use during general anesthesia can reduce shunt and shunt-related complication rates.

## CONFLICTS OF INTEREST

No potential conflict of interest relevant to this article was reported.

## ACKNOWLEDGEMENTS

This work was supported by a Yeungnam University Research Grant (2015).

## REFERENCES

1. North American Symptomatic Carotid Endarterectomy Trial Collaborators. Beneficial effect of carotid endarterectomy in symptomatic patients with high-grade carotid stenosis. *N Engl J Med* 1991;325:445-53.
2. Endarterectomy for asymptomatic carotid artery stenosis. Executive Committee for the Asymptomatic Carotid Atherosclerosis Study. *JAMA* 1995;273:1421-8.
3. Barnett HJ, Taylor DW, Eliasziw M, Fox AJ, Ferguson GG, Haynes RB, et al. Benefit of carotid endarterectomy in patients with symptomatic moderate or severe stenosis. North American Symptomatic Carotid Endarterectomy Trial Collaborators. *N Engl J Med* 1998;339:1415-25.
4. Randomised trial of endarterectomy for recently symptomatic carotid stenosis: final results of the MRC European Carotid Surgery Trial (ECST). *Lancet* 1998;351:1379-87.
5. Halliday A, Mansfield A, Marro J, Peto C, Peto R, Potter J, et al. Prevention of disabling and fatal strokes by successful carotid endarterectomy in patients without recent neurological symptoms: randomised controlled trial. *Lancet* 2004;363:1491-502.
6. Brott TG, Halperin JL, Abbara S, Bacharach JM, Barr JD, Bush RL, et al. 2011 ASA/ACCF/AHA/AANN/AANS/ACR/ASNR/CNS/SAIP/SCAI/SIR/SNIS/SVM/SVS guideline on the management of patients with extracranial carotid and vertebral artery disease: executive summary. A report of the American College of Cardiology Foundation/American Heart Association Task Force on Practice Guidelines, and the American Stroke Association, American Association of Neuroscience Nurses, American Association of Neurological Surgeons, American College of Radiology, American Society of Neuroradiology, Congress of Neurological Surgeons, Society of Atherosclerosis Imaging and Prevention, Society for Cardiovascular Angiography and Interventions, Society of Interventional Radiology, Society of NeuroInterventional Surgery, Society for Vascular Medicine, and Society for Vascular Surgery. *Circulation* 2011;124:489-532.
7. Liapis CD, Bell PR, Mikhailidis D, Sivenius J, Nicolaidis A, Fernandes e Fernandes J, et al. ESVS guidelines. Invasive treatment for carotid stenosis: indications, techniques. *Eur J Vasc Endovasc Surg* 2009;37(4 Suppl):1-19.
8. Hans SS, Jareunpoon O. Prospective evaluation of electroencephalography, carotid artery stump pressure, and neurologic changes during 314 consecutive carotid endarterectomies performed in awake patients. *J Vasc Surg* 2007;45:511-5.
9. Lawrence PF, Alves JC, Jicha D, Bhirangi K, Dobrin PB. Incidence, timing, and causes of cerebral ischemia during carotid endarterectomy with regional anesthesia. *J Vasc Surg* 1998;27:329-34.
10. McCarthy RJ, Walker R, McAteer P, Budd JS, Horrocks M. Patient and hospital benefits of local anaesthesia for carotid endarterectomy. *Eur J Vasc Endovasc Surg* 2001;22:13-8.
11. Stoughton J, Nath RL, Abbott WM. Comparison of simultaneous electroencephalographic and mental status monitoring during carotid endarterectomy with regional anesthesia. *J Vasc Surg* 1998;28:1014-21.
12. Chongruksut W, Vaniyapong T, Rerkasem K. Routine or selective carotid artery shunting for carotid endarterectomy (and different methods of monitoring in selective shunting). *Cochrane Database Syst Rev* 2014;(6):CD000190.
13. GALA Trial Collaborative Group, Lewis SC, Warlow CP, Bodenham AR, Colam B, Rothwell PM, et al. General anaesthesia

- versus local anaesthesia for carotid surgery (GALA): a multicentre, randomised controlled trial. *Lancet* 2008;372:2132-42.
14. Hafner CD, Evans WE. Carotid endarterectomy with local anesthesia: results and advantages. *J Vasc Surg* 1988;7:232-9.
15. Cao P, Giordano G, Zannetti S, De Rango P, Maghini M, Parente B, et al. Transcranial Doppler monitoring during carotid endarterectomy: is it appropriate for selecting patients in need of a shunt? *J Vasc Surg* 1997;26:973-9.
16. Ali AM, Green D, Zayed H, Halawa M, El-Sakka K, Rashid HI. Cerebral monitoring in patients undergoing carotid endarterectomy using a triple assessment technique. *Interact Cardiovasc Thorac Surg* 2011;12:454-7.
17. Moritz S, Kasprzak P, Arlt M, Taeger K, Metz C. Accuracy of cerebral monitoring in detecting cerebral ischemia during carotid endarterectomy: a comparison of transcranial Doppler sonography, near-infrared spectroscopy, stump pressure, and somatosensory evoked potentials. *Anesthesiology* 2007;107:563-9.
18. Artru AA, Strandness DE Jr. Delayed carotid shunt occlusion detected by electroencephalographic monitoring. *J Clin Monit* 1989;5:119-22.
19. Blackshear WM Jr, Di Carlo V, Seifert KB, Connar RG. Advantages of continuous electroencephalographic monitoring during carotid artery surgery. *J Cardiovasc Surg (Torino)* 1986;27:146-53.
20. Cho I, Smullens SN, Streletz LJ, Fariello RG. The value of intraoperative EEG monitoring during carotid endarterectomy. *Ann Neurol* 1986;20:508-12.
21. Ackerstaff RG, Moons KG, van de Vlasakker CJ, Moll FL, Vermeulen FE, Algra A, et al. Association of intraoperative transcranial doppler monitoring variables with stroke from carotid endarterectomy. *Stroke* 2000;31:1817-23.
22. Pennekamp CW, Moll FL, de Borst GJ. The potential benefits and the role of cerebral monitoring in carotid endarterectomy. *Curr Opin Anaesthesiol* 2011;24:693-7.