

Case Report

Paraneoplastic Limbic Encephalitis Complicated with Small Cell Lung Cancer at the Time of Recurrence

Hironori Sadamatsu Yuki Kurihara Koichiro Takahashi
Kazutoshi Komiya Shinsuke Ogusu Haruki Hirakawa Hiroki Tashiro
Chiho Nakashima Tomomi Nakamura Naoko Sueoka-Aragane

Division of Haematology, Respiratory Medicine and Oncology, Department of Internal Medicine, Faculty of Medicine, Saga University, Saga, Japan

Keywords

Paraneoplastic limbic encephalitis · Small cell lung cancer · Anti-glutamic acid decarboxylase antibody · Anti-amphiphysin antibody

Abstract

Paraneoplastic limbic encephalitis (PLE) is a rare neurologic disorder that can complicate various malignancies, including lung cancer. PLE is most frequently found the initial presentation of lung cancer. In this study, we reported the case of a 74-year-old Japanese woman who developed PLE after partial remission of small cell lung cancer (SCLC) by first-line systemic chemotherapy. Brain magnetic resonance imaging showed no metastatic tumor or cerebrovascular disease. Anti-glutamic acid decarboxylase (GAD) and anti-amphiphysin antibodies were detected in her serum. She was diagnosed as having PLE related to the recurrence of SCLC and received high-dose glucocorticoid, and sequentially systemic chemotherapy with amrubicin. Unfortunately, these treatments did not improve her disease progression and she died 4 months later. Although PLE rarely occurs at the time of SCLC recurrence, physicians should pay attention to PLE onset even after chemotherapy.

© 2019 The Author(s)
Published by S. Karger AG, Basel

Introduction

Paraneoplastic neurologic syndrome (PNS) can be defined as the remote effects of cancer that are not caused by the tumor and its metastasis [1]. PNS is rare, complicating only 0.01–1% of cancers, and had been closely linked with paraneoplastic antibodies. The most common PNS is Lambert-Eaton myasthenic syndrome, which accounts for 60% [2]. On the other hand, paraneoplastic limbic encephalitis (PLE) accounts for about 20% of PNS and had been characterized by a subacute onset of confusion, with marked reduction of short-term memory [3]. Small cell lung cancer (SCLC) is the most common tumor associated with PLE and accounts for 50% of cancers [4]. Herein, we reported a case of PLE complicated with SCLC at the time of recurrence.

Case Presentation

A 74-year-old Japanese woman visited our hospital because of chronic cough and weight loss for 2 months. She had a 30-pack-year smoking history but had no dust exposure. She had no underlying disease and was not on any medications. In physical examination, crackles were not audible on chest auscultation. Other physical examinations, including assessment of consciousness, abdomen and superficial lymph node were normal.

Chest radiography showed a mass on the right hilar region (Fig. 1A), which was confirmed on chest computed tomography (CT) with contrast as an 80-mm lobulated mass on the right hilar region, with multiple lymphadenopathies in the right hilum, mediastinum, and right supraclavicular fossa (Fig. 1B, C). Laboratory findings showed increase in the levels of pro-gastrin-releasing peptide (Pro-GRP) at 1,530 pg/mL and neuron-specific enolase (NSE) at 38.4 ng/mL. Bronchoscopy with endobronchial ultrasound-guided transbronchial needle aspiration was performed on the mediastinal lymph nodes and showed pathological findings of small cell carcinoma and immunostaining that was CD56-positive and chromogranin-negative (Fig. 2).

She was diagnosed as having SCLC, clinical stage IIIB (cT4N3M0, extensive disease) and received chemotherapy. The dose of irinotecan was reduced to 50% because her *UGT1A1* polymorphism was *6/*6 homozygous. She was administered 1 cycle of cisplatin (60 mg/m²) and irinotecan (30 mg/m²) therapy and 3 cycles of cisplatin (64 mg/m²) and etoposide (100 mg/m²) therapy; irinotecan was changed to etoposide because of grade 3 nausea. After 4 cycles of the first-line chemotherapy, the tumors decreased in size, and the pro-GRP (123 ng/mL) and NSE (9.2 ng/mL) levels also decreased. After that, she was carefully followed up.

However, 2 months after the last chemotherapy, she suddenly had cramps and loss of unconsciousness. Brain magnetic resonance imaging showed no metastatic tumors or cerebrovascular disease (Fig. 3A, B). Chest CT showed an increase in the size of the right hilar mass and mediastinal lymph node (Fig. 3C–F). Laboratory findings showed an increase in pro-GRP (362 ng/mL). Anti-glutamic acid decarboxylase (GAD) and anti-amphiphysin antibodies were detected in her serum. Examination of the cerebrospinal fluid showed clear appearance, pressure at 15 cm H₂O, protein at 44 mg/dL, glucose at 78 mg/dL, and no malignant cells on cytology.

Based on the above, she was diagnosed as PLE. Steroid pulse therapy was administered but had no effect. She was administered 1 cycle of amrubicin (32 mg/m²) as second-line chemotherapy, but this had no effect. Chemotherapy was discontinued and she was switched to

palliative care because the frequency of cramps increased and control of the disease was considered difficult. She died 4 months after the onset of PLE.

Discussion

PLE accounts for about 20% of PNS cases [5] and had been most commonly associated with SCLC [4]. In fact, a previous study showed that PLE complicated 1.5% of SCLC patients [2]. In a majority of patients, this neurologic disorder develops before the cancer is clinically found [3]. The present case was rare because PLE occurred at the time of SCLC recurrence.

PNS is associated with paraneoplastic antibodies directed against the antigens expressed by both the tumor and the nervous system. Anti-Hu antibody had been found in up to 50% of patients with PLE and lung cancer [6]. In the present case, anti-GAD and anti-amphiphysin antibodies were detected. The detection of anti-GAD antibody had been reported in type 1 diabetes, stiff person syndrome, cerebellar ataxia, limbic encephalitis, and temporal lobe epilepsy [7]. A previous study reported that the prevalence of the anti-GAD antibody in SCLC patients with PNS was 4.2% [2]. On the other hand, anti-amphiphysin antibody had been frequently detected in stiff person syndrome with breast cancer and limbic encephalitis with SCLC; however, the comorbid tumors and neurologic symptoms may vary [8]. The prevalence of anti-amphiphysin antibody in SCLC patients with PNS was reported to be 3.9% [5]. Therefore, the detection of both anti-GAD and anti-amphiphysin antibodies in SCLC patients with PNS had not been common.

Paraneoplastic antibodies are divided into those against intracellular antigens or those against cell surface antigens [9]. A PNS that produces the former antibodies is resistant to immunosuppressive therapy, whereas a PNS that produces the latter antibodies responds to immunosuppressive therapy [10]. Both anti-GAD and anti-amphiphysin antibodies are classified as antibodies against intracellular antigens. Therefore, the present case might have been resistant to immunosuppressive therapy. Paraneoplastic antibodies may serve as markers, not only for the diagnosis of PNS but also for predicting treatment response.

In conclusion, physicians should pay attention to PLE onset even after chemotherapy because PLE can develop at the time of SCLC recurrence. Paraneoplastic antibodies may be useful for the diagnosis of PNS and the prediction of treatment response.

Statement of Ethics

The authors have no ethical conflicts to disclose. The family of this patient have given written informed consent to publish of this case report (including publication of images).

Disclosure Statement

All authors declare that there is no conflict of interest regarding the publication of this paper.

References

- 1 Giometto B, Grisold W, Vitaliani R, Graus F, Honnorat J, Bertolini G; PNS Euronetwork. Paraneoplastic neurologic syndrome in the PNS Euronetwork database: a European study from 20 centers. *Arch Neurol*. 2010 Mar;67(3):330–5.
- 2 Gozzard P, Woodhall M, Chapman C, Nibber A, Waters P, Vincent A, et al. Paraneoplastic neurologic disorders in small cell lung carcinoma: A prospective study. *Neurology*. 2015 Jul;85(3):235–9.
- 3 Honnorat J, Antoine JC. Paraneoplastic neurological syndromes. *Orphanet J Rare Dis*. 2007 May;2(1):22.
- 4 Gultekin SH, Rosenfeld MR, Voltz R, Eichen J, Posner JB, Dalmau J. Paraneoplastic limbic encephalitis: neurological symptoms, immunological findings and tumour association in 50 patients. *Brain*. 2000 Jul;123(Pt 7):1481–94.
- 5 Saiz A, Dalmau J, Butler MH, Chen Q, Delattre JY, De Camilli P, et al. Anti-amphiphysin I antibodies in patients with paraneoplastic neurological disorders associated with small cell lung carcinoma. *J Neurol Neurosurg Psychiatry*. 1999 Feb;66(2):214–7.
- 6 Graus F, Dalmau J. Paraneoplastic neurological syndromes: diagnosis and treatment. *Curr Opin Neurol*. 2007 Dec;20(6):732–7.
- 7 Saiz A, Blanco Y, Sabater L, González F, Bataller L, Casamitjana R, et al. Spectrum of neurological syndromes associated with glutamic acid decarboxylase antibodies: diagnostic clues for this association. *Brain*. 2008 Oct;131(Pt 10):2553–63.
- 8 Pittock SJ, Lucchinetti CF, Parisi JE, Benarroch EE, Mokri B, Stephan CL, et al. Amphiphysin autoimmunity: paraneoplastic accompaniments. *Ann Neurol*. 2005 Jul;58(1):96–107.
- 9 Graus F, Saiz A, Dalmau J. Antibodies and neuronal autoimmune disorders of the CNS. *J Neurol*. 2010 Apr;257(4):509–17.
- 10 Höftberger R, Rosenfeld MR, Dalmau J. Update on neurological paraneoplastic syndromes. *Curr Opin Oncol*. 2015 Nov;27(6):489–95.

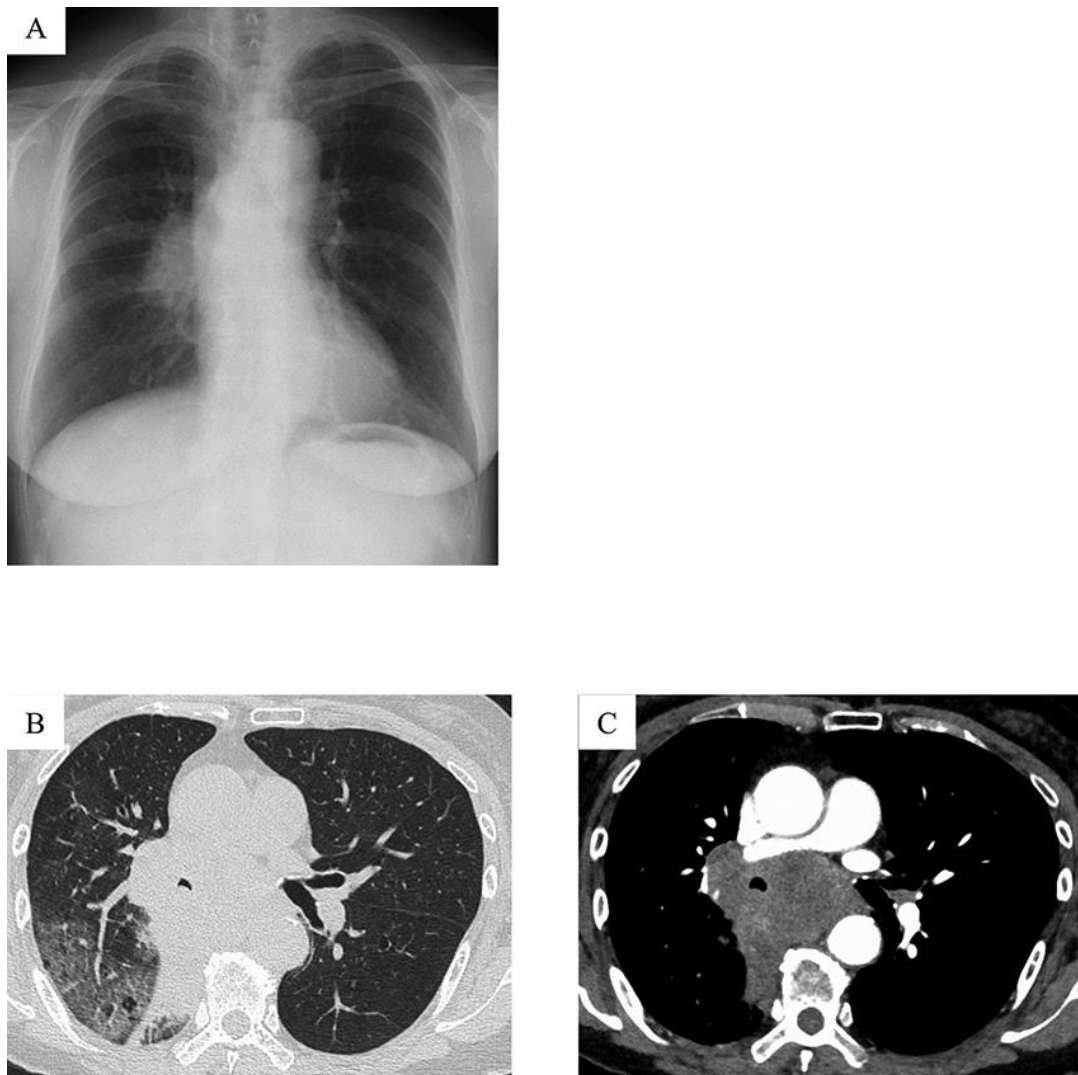


Fig. 1. Findings on chest radiography and CT. **(A)** Chest radiography shows a mass on the right hilar region. **(B, C)** Chest CT shows an 80-mm lobulated mass on the right hilar region and multiple lymphadenopathies in the right hilum, mediastinum, and right supraclavicular fossa. CT, computed tomography.

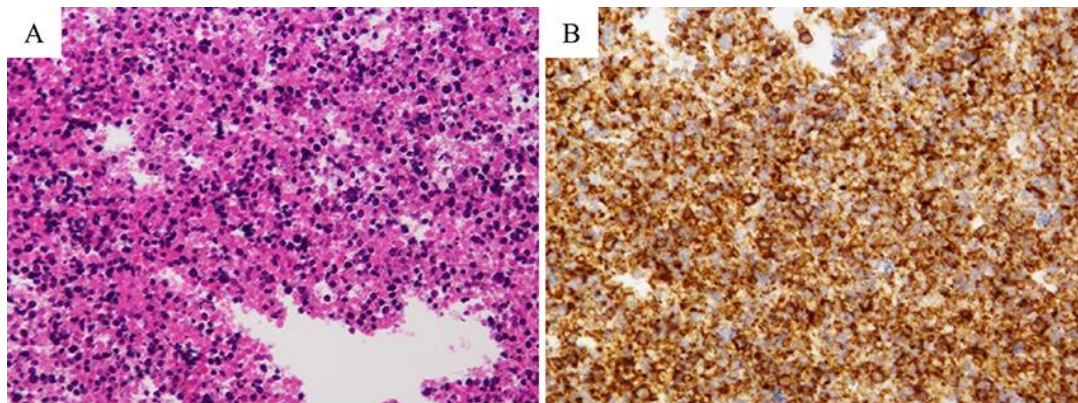


Fig. 2. Pathological findings of the mediastinal lymph node biopsy specimen by EBUS-TBNA. There is invasion of numerous cells with atypical naked nuclei on (A) Haematoxylin and Eosin stain ($\times 200$) and (B) CD56 immunostaining ($\times 200$). EBUS-TBNA, endobronchial ultrasound-guided transbronchial needle aspiration.

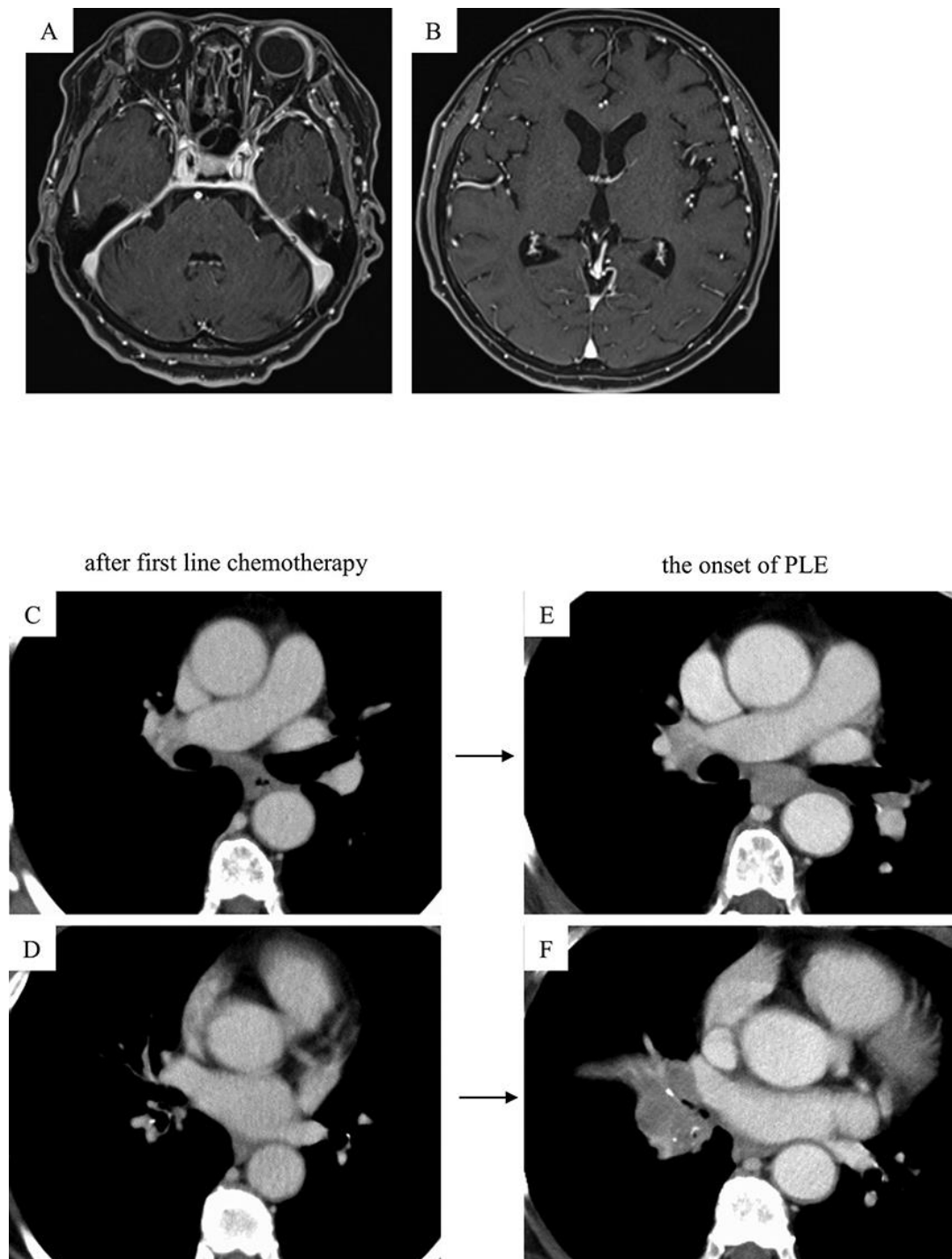


Fig. 3. Findings on head MRI and follow-up chest CT. (A, B) Upon the onset of paraneoplastic limbic encephalitis (PLE), head MRI shows no metastatic tumors or stroke. Chest CT shows that compared with the images after first-line chemotherapy (C, D), the images at the onset of PLE (E, F) show increase in the sizes of the right hilar mass and mediastinal lymph node. MRI, magnetic resonance imaging; CT, computed tomography.