

Cite this article as: Asou T, Kawataki M, Takeda Y, Asai H, Tachibana T, Toyoshima K *et al.* Rapid two-stage Starnes approach in high-risk neonates with Ebstein anomaly. *Eur J Cardiothorac Surg* 2020;58:957–63.

Rapid two-stage Starnes approach in high-risk neonates with Ebstein anomaly

Toshihide Asou ^{a,*}, Motoyoshi Kawataki ^{b,†}, Yuko Takeda ^{a,†}, Hidetsugu Asai ^{a,†}, Tsuyoshi Tachibana ^{a,†}, Katsuaki Toyoshima ^{b,†}, Ki-Sung Kim ^{c,†} and Hideaki Ueda ^{c,†}

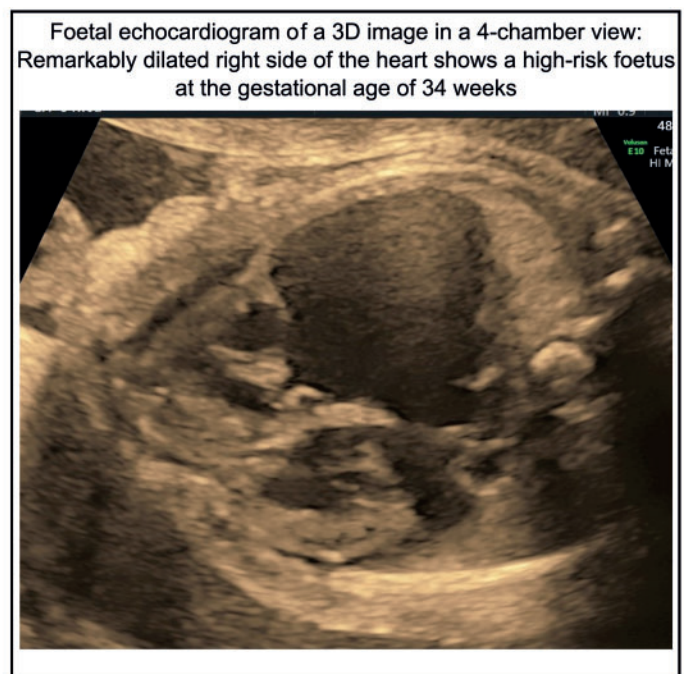
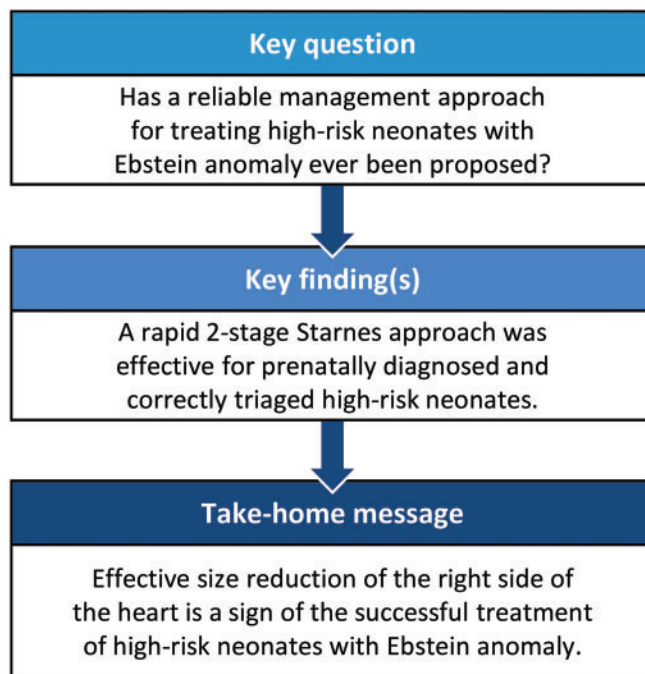
^a Department of Cardiovascular Surgery, Kanagawa Children's Medical Center, Yokohama, Japan

^b Department of Neonatology, Kanagawa Children's Medical Center, Yokohama, Japan

^c Department of Cardiology, Kanagawa Children's Medical Center, Yokohama, Japan

* Corresponding author. Department of Cardiovascular Surgery, Kanagawa Children's Medical Center, 2-138-4, Mutsukawa, Minami-ku, Yokohama 232-8555, Japan. Tel: +81-45-7112351; fax: +81-45-7213324; e-mail: toshisurgeonfamily@live.jp (T. Asou).

Received 23 December 2019; received in revised form 18 March 2020; accepted 20 March 2020



Abstract

OBJECTIVES: The purpose of this study is to review the short- and long-term outcomes of high-risk neonates with Ebstein anomaly treated with a newly developed rapid 2-stage Starnes procedure, which is aimed at reducing the size of the enlarged right side of the heart.

METHODS: Fifty-two fetuses with Ebstein anomaly were analysed in this study and divided into 2 groups. The control group comprised 25 fetuses, referred to us before 2008, and the study group was composed of 27 fetuses, referred to us after 2009. The right atrial area index was defined as high risk when it was >1.5. We applied our management approach to 6 high-risk neonates in the study group. This approach consisted of reducing the size of the right side of the heart through a 2-stage process: (i) right atrial plication without the use of a bypass and (ii) a Starnes procedure. Cox proportional hazards models were used to evaluate the effects of our management approach on the survival rates of the neonates.

[†]These authors contributed equally to this study.

© The Author(s) 2020. Published by Oxford University Press on behalf of the European Association for Cardio-Thoracic Surgery.

This is an Open Access article distributed under the terms of the Creative Commons Attribution Non-Commercial License (<http://creativecommons.org/licenses/by-nc/4.0/>), which permits non-commercial re-use, distribution, and reproduction in any medium, provided the original work is properly cited. For commercial re-use, please contact journals.permissions@oup.com

RESULTS: The mean follow-up period was 7.5 ± 3.3 years. All 6 high-risk neonates in the study group survived. The overall hazard ratio was 0.12 (95% confidence interval of 0.03–0.43) in the study group as compared with the control group ($P = 0.0007$). A Fontan operation was completed in all but 1 case, with the remaining case awaiting a Fontan operation.

CONCLUSIONS: We suggest that a rapid 2-stage Starnes approach can be effective in the treatment of high-risk neonates with Ebstein anomaly.

Keywords: Ebstein anomaly • Neonate • Foetus • Right ventricle exclusion • Volume reduction

ABBREVIATIONS

BCPS	Bidirectional cavopulmonary shunt
EF	Ejection fraction
LV	Left ventricle
PA	Pulmonary artery
RA	Right atrium
RV	Right ventricle
VAD	Ventricular assist device

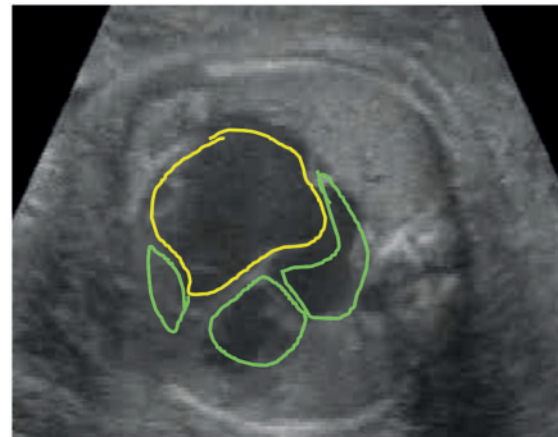
INTRODUCTION

The rate of survival of neonates with Ebstein anomaly continues to increase with the improvement in conservative management and the development of novel surgical management approaches. During the 1990s, neonatal mortality ranged from 56% to 85% [1–6]. Today, these outcomes have improved and mortality rates range from 19% to 36% [7–14], as deduced from a review of recent articles. Nevertheless, this is a high mortality rate and the treatment of neonatal Ebstein anomaly continues to be a challenge. To elucidate a solution to this issue, we have focused on high-risk neonates in this study. Among very high-risk foetuses, there may be no survivors. Using the criteria for high-risk neonates proposed by McElhinney of a right atrium (RA) area index score >1.0 , 1 study reported only 2 survivors out of 23 high-risk foetuses [7]. Andrew developed a prognostic score (SAS score) in which 5 variables were combined and weighted to obtain a best-guide prognosis [8]; of 12 foetuses in the high-risk category, none survived. Barre *et al.* [9] also reported 2 survivors and 12 non-survivors triaged by SAS score as high risk. Elzein *et al.* [14] performed surgical interventions in 5 neonates with a circular shunt, which was considered to be a high-risk variable, and 2 of them survived. Although the selection criteria were different, of 54 neonates associated with high risk, only 8 neonates (14.8%) survived more than 30 days of life [1, 7–11, 14].

Therefore, our target for rescue surgery was a group of patients with high-risk factors who exhibited extreme signs of the disease. Previously, we reported a novel surgical strategy, a rapid 2-stage Starnes procedure [10]. This was a rescue surgery performed within 24 h after birth, triaged based on the foetal echocardiographic findings. Due to this success, we have applied our newly developed procedure to 5 other high-risk neonates. We used an RA area index of >1.5 as a selection criterion for the triage of neonates with high risks [1, 2, 7]. The purpose of this study was to assess the short- and long-term outcomes in these 6 neonates with a severe form of Ebstein anomaly.

PATIENTS AND METHODS

The Institutional Review Board of the Kanagawa Children's Medical Center Research Ethics Board approved this study (ID:



$$\text{RA area index} = \frac{\text{RA} + \text{atrialized RV}}{\text{RV} + \text{LA} + \text{LV}}$$

Figure 1: RA area index calculated by echocardiographic measurements. The ratio of the combined area (yellow line) of the RA and the atrialized RV to that of the remaining chambers (3 areas surrounded with green lines) was obtained. LA: left atrium; LV: left ventricle; RA: right atrium; RV: right ventricle.

107-7) on 11 May 2018 and waived the need for patient consent. The medical records of the patients and their mothers were reviewed. We obtained echocardiographic data from a review of stored images whenever possible.

Study design

Celermajer *et al.* [1, 2] developed the RA area index and demonstrated it as a significant predictor to death when >1.5 . RA area index was obtained by calculation using echocardiographic measurements (Fig. 1). Twenty-five foetuses with Ebstein anomaly were referred to us before 2008. We divided them into 2 groups depending on the RA area index, <1.5 vs >1.5 , and analysed the Kaplan–Meier survival (Fig. 2). A significant difference existed between the 2 curves, with a hazard ratio of 7.56 ($P = 0.0034$). Considering these poor survival outcomes, we defined the foetuses with RA index >1.5 as a high-risk group. Abrupt decline in survival in the high-risk group was prominent, with foetuses dying *in utero* or immediately after birth. Since 2009, therefore, the strategy of the treatment of neonatal Ebstein anomaly changed from conservative to planned aggressive. A flow diagram depicting the perinatal outcomes in 52 foetuses including 25 before 2008 (control) and 27 after 2009 (study) is shown in Fig. 3.

Management approach during foetal life. A multidisciplinary team, which included obstetricians, neonatologists, paediatric cardiologists and paediatric cardiac surgeons, discussed a

plan for the management of the foetuses. After confirming the diagnosis, frequent follow-up foetal echocardiograms were performed to assess the progress of the disease. At the same time, we provided family counselling and obtained informed consent. To minimize the chance of not being able to perform the surgical intervention in the appropriate time frame, we planned for an elective Caesarean section at the gestational age of 38 weeks. Depending on the haemodynamic and metabolic instabilities of the newborn, the first stage of the procedure was performed within 24 h of birth.

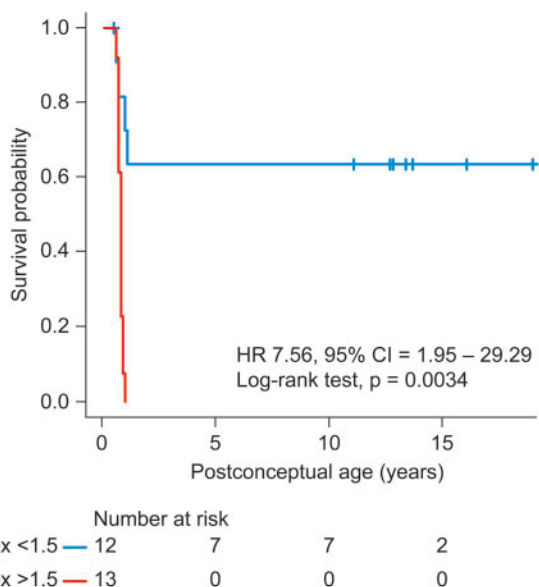


Figure 2: Kaplan-Meier survival curves. The HR for neonates with RA index <1.5, as compared with those with RA >1.5, was 7.56 (95% CI 1.95-29.29; $P=0.0034$), with 12 neonates with RA index <1.5 and 13 with RA index >1.5. The RA index of >1.5 was more indicative of high-risk patients. CI: confidence interval; HR: hazard ratio; RA: right atrium.

Surgical approach

The main purpose of the rapid 2-stage approach is resuscitating the severely unstable high-risk neonates with Ebstein anomaly without the use of cardiopulmonary bypass as a first-stage procedure and delaying the risk of the major open heart surgery after stabilization of these patient's physiology as a second-stage procedure.

First stage. The main goal of the first stage of the procedure for high-risk neonates with Ebstein anomaly is to stabilize haemodynamic and metabolic derangements in a minimally invasive manner without the use of a cardiopulmonary bypass [10]. Our surgical management strategy was associated with the concept that the enlarged right side of the heart compressed the left ventricle (LV), effectively limiting the filling of the LV. Consequently, the first stage of our management approach was aimed at reducing the right side of the heart as much as possible in a minimally invasive manner.

The first stage of the procedure consisted of the following steps: (i) ligation of the main pulmonary artery (PA) to abolish a circular shunt and noting the abrupt rise of systemic arterial pressure by 5–10 mmHg, (ii) plication or imbrications of the dilated right atrium, (iii) creation of a pulmonary blood flow source with a modified Blalock-Taussig shunt using a small-calibre graft ($\phi 3.0$ mm in diameter, W. L. Gore & Associates, Inc., Flagstaff, Arizona, USA) interposed between the brachiocephalic artery and the PA or bilateral PA banding (exceptional) and (iv) ligation of the duct after modified Blalock-Taussig shunt. On the contrary, the duct was left open with an intravenous drip infusion of Prostaglandin when both PAs were banded. The first-stage palliative procedure was performed within 24 h of an elective Caesarean section.

Second stage (modified Starnes). Once the first stage of the procedure had stabilized the patient's haemodynamics, we determined the appropriate timing for the second stage. This was done by observing the haemodynamic and metabolic changes

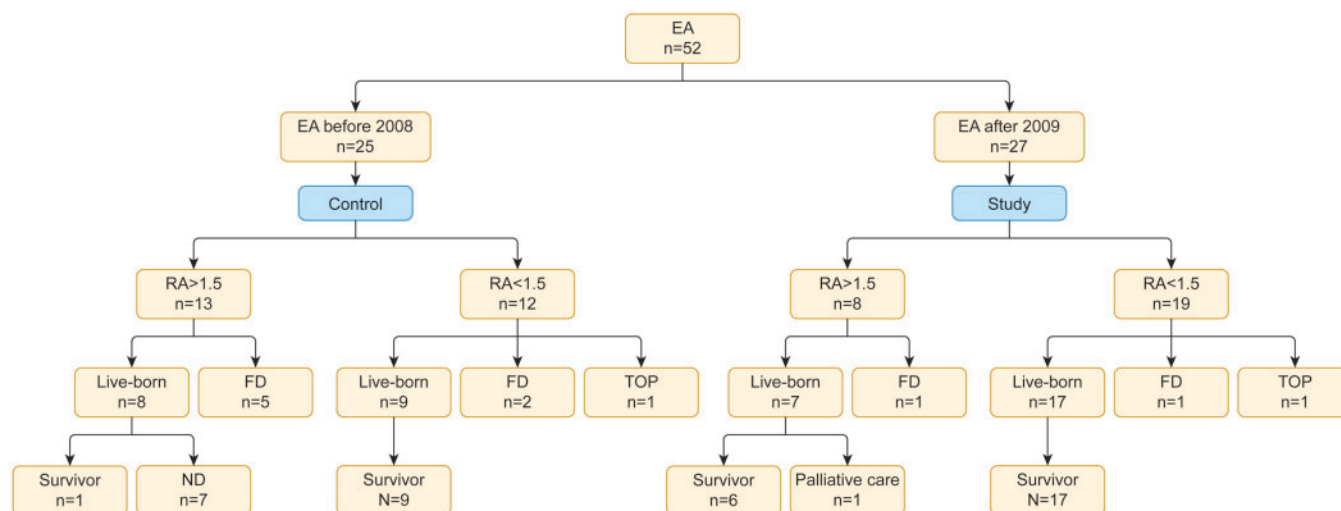


Figure 3: Flow diagrams depicting perinatal outcomes for the foetuses with prenatally diagnosed Ebstein anomaly. A conservative strategy was applied in all foetuses before 2008 (control), and surgical intervention was applied in high-risk foetuses after 2009 (study). RA >1.5 was defined as high risk. There were high-risk foetuses in 13 of 25 cases in the control group. Only one neonate survived to infancy; of the remaining 12, 7 were neonatal deaths and 5 were foetal deaths. After induction of our current strategy for high-risk foetuses, there were 6 survivors among 8 high-risk neonates, with 1 foetal death and 1 parent choosing palliative care (study group). FD: foetal death; ND: neonatal death; RA: right atrium; TOP: termination of pregnancy.

via close follow-up of patients and frequent echocardiograms that focused on the paradoxical septal motion, which disappeared immediately after the first stage but reappeared within several hours or days. With the appearance of paradoxical septal motion, peripheral perfusion became poor; once this occurred, we decided to proceed to the second stage. With the standard cannulation for systemic perfusion and venous drainage, cardiopulmonary bypass was commenced and all procedures were performed with the heart beating. We used transoesophageal echocardiography in all 6 neonates but 1 to monitor cardiac function and detect microbubbles in the LV. Aortic venting was also used to remove air from the cardiac chambers. During the bypass, the RA was incised longitudinally and the right ventricle (RV) cavity was made smaller using the technique of internal RV exclusion described below. Then, a modified Starnes procedure [6] was performed to close the tricuspid valve using a glutaraldehyde (0.625%)-treated pericardial patch with a 3-mm fenestration. The RA incision was trimmed and closed.

Internal right ventricle exclusion technique. We did not perform the RV exclusion technique on our first patient [10]. The residual RV cavity was not particularly large but could have been problematic. Moving forwards, we applied a new 'internal RV exclusion' method to reduce the RV cavity as much as possible without being too invasive. Through the tricuspid valve, 2 pairs of pledgeted stitches were anchored to the interventricular septum at both the RV outflow and inflow tracts, and these stitches penetrated the RV free wall from inside to outside. These stitches were tied so that the RV free wall and the interventricular septum were approximated to each other (i.e. the interventricular septum and the RV free wall were held together as 1 thicker structure, becoming a part of the LV free wall). We believe that internal RV exclusion might be simpler and less invasive than the original procedure [15–17].

Statistical analysis

All statistical analyses were performed with EZR (version 1.41, Saitama Medical Center, Jichi Medical University, Saitama, Japan), which is a graphical user interface for R (version 2.6-1; The R Foundation for Statistical Computing, Vienna, Austria) [18, 19]. More precisely, it is a modified version of R Commander designed to add statistical functions frequently used in biostatistics. We generated Kaplan–Meier survival curves for the different

clinical subgroups. The estimated postconception age was used to determine the survival curves for the foetuses. When an elective termination of pregnancy occurred, the foetus was censored as it lost follow-up. A log-rank test was performed to compare the survival of the 2 groups. The Cox regression model was used to investigate the effect of the RA area index and the management approach on survival rates in the cohort of neonates with Ebstein anomaly.

RESULTS

Outcomes of rapid 2-stage Starnes procedure

Outcomes in the perinatal period. Before 2008, there was only one early survivor among 8 live-born patients. This baby later died of congestive heart failure at 50 days of life. As shown in Fig. 3, however, after 2009, there were 6 survivors in the high-risk group with an RA area index of >1.5. These neonates in the study group were managed surgically with our newly developed management approach. Table 1 summarizes the preoperative characteristics of the 6 neonates who met the criteria for and underwent the rapid 2-stage Starnes procedure. Foetal echocardiography showed an RA area index of >1.5 and a low velocity of tricuspid regurgitation of <3.0 m/s across the tricuspid valve and pulmonary regurgitation, leading to a circular shunt in all 6 high-risk neonates. All but 1 neonate were delivered by Caesarean section. All were intubated immediately after birth due to respiratory distress (Table 1). We noted low cardiac output syndrome, with a maximum serum lactate level of 7.3 ± 3.1 mmol/l and a minimum base excess of -7.0 ± 5.3 before the first stage (Table 2). The diagnosis was confirmed using transthoracic echocardiography. A chest X-ray revealed a 'wall-to-wall' figure of the heart in all 6 neonates. Haemodynamics rapidly deteriorated after birth.

First stage. The first stage of the surgical procedure commenced a median of 10 h (3–22 h) after birth (Table 2). The sternum was primarily closed at the first stage in all but 1 case. Haemodynamics were stabilized concomitantly with echocardiographic findings in that the septal motion became normalized. However, the beneficial effects of the first procedure on haemodynamics and septal motion were not particularly long-lasting, probably because of tricuspid regurgitation, which may continue to enlarge the right side of the heart, leading to impairment of

Table 1: Preoperative characteristics of patients with RA area index >1.5

Case	GA at birth	RA area index	PR	TR (m/s)	Delivery	BW (g)	Intubated (min)
1	38w 5d	1.9	+	2.0	Vaginal	2700	4
2	36w 0d	2.5	+	2.5	CS	2064	10
3	39w 0d	1.8	+	2.6	CS	3006	3
4	37w 3d	1.6	+	2.7	CS	2168	5
5	36w 6d	1.7	+	3.0	CS	2314	3
6	38w 2d	2.1	+	2.5	CS	2786	4
Mean (SD)		1.9 (0.3)		2.6 (0.3)		2506 (377)	
Median	38w 0d	1.9		2.6		2507	4

BW: body weight; CS: caesarean section; d: day; GA: gestational age; PR: pulmonary regurgitation; RA: right atrium; SD: standard deviation; TR: tricuspid regurgitation; w: week.

Table 2: Preoperative conditions of high-risk patients and timing of surgical intervention

Case	Maximum lactate (mmol/l)	Minimum BE	First stage (h)	Second stage (days)	Age at BCPS (months)	Age at TCPC (months)
1	4.3	-5.0	16	12	4.3	12
2	12.7	-17.0	20	7	4.6	14
3	5.9	-3.0	5	1	3.3	16
4	6.7	-8.1	3	0	2.2	40
5	5.1	-6.0	4	0	3.5	18
6	9.0	-2.6	22	1	4.0	Waiting
Median	6.3	-5.5	10	1	3.7	16

BCPS: bidirectional cavopulmonary shunt; BE: base excess; TCPC: total cavopulmonary connection.

the LV filling. Within several hours or days of the completion of the first stage, the serum lactate level gradually increased, and the septal motion started to become paradoxical on the echocardiogram. The appropriate time to begin the second stage was thus determined by observing the signs of low cardiac output and the appearance of the paradoxical septal motion. Concerned with the duration of times between 2 stages, there appeared to be 2 patterns, 1 for a shorter, 15–25 h (case 3–6 in Table 2), and the other for a longer, several days or more.

Second stage. All 6 of the high-risk neonates underwent the rapid 2-stage Starnes approach. There were 6 neonatal survivors out of 7 high-risk live-borns with 1 palliative care in the study group and only one survivor out of 8 live-born babies in the control group, showing an early survival rate of 6/7 (85.7%) and 1/8 (12.5%), respectively ($P=0.004$). A bidirectional cavopulmonary shunt (BCPS) was performed at a median age of 3.7 months in all 6 patients, and all but 1 patient completed the staged Fontan at a median age of 16 months. The remaining patient is awaiting a Fontan operation (Table 2). The overall hazard ratio in the study group was 0.12 (95% confidence interval 0.03–0.43) compared with the control group ($P=0.0007$) (Fig. 4). After the follow-up period of 7.5 ± 3.3 years (range 1.2–10.4 years, median 8.5 years), all patients are currently in the New York Heart Association class I.

Changes in paradoxical septal motion. One of the most important echocardiographic findings in this study may be a change in septal motion, from paradoxical to normal during each procedure and vice versa after the procedure (Video 1). Consequently, echocardiographic changes were compatible with clinical sequelae. After the first stage of our management approach, the septal motion and haemodynamic stabilization were normalized, which shows that the serum lactate level was also normalized for a while. Several hours or days after the first stage, however, the septal motion gradually became paradoxical and the serum lactate level increased. In contrast, the second-stage procedure resulted in a completely normalized septal motion, with an improvement of the haemodynamics in all but 1 patient (case 4).

Case 4. The patient's mother was referred to us at the gestational age of 31 weeks, with an RA area index of 1.6 on her foetal echocardiogram. When she came to us for further observation, however, the foetal status appeared to be dangerous [20], which meant that an emergency Caesarean section had to be

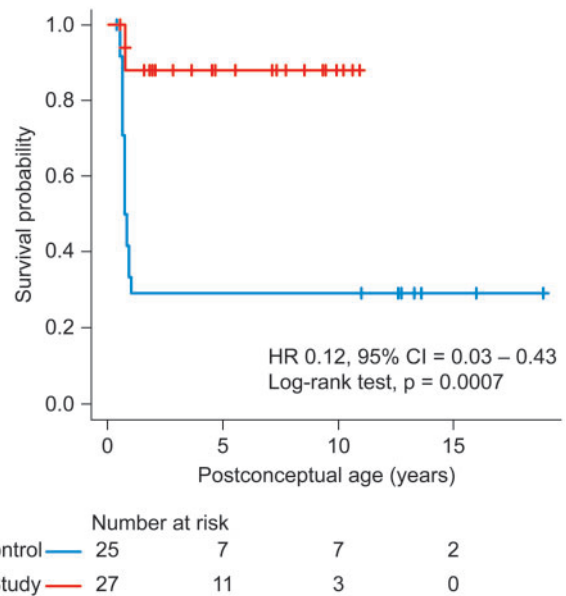
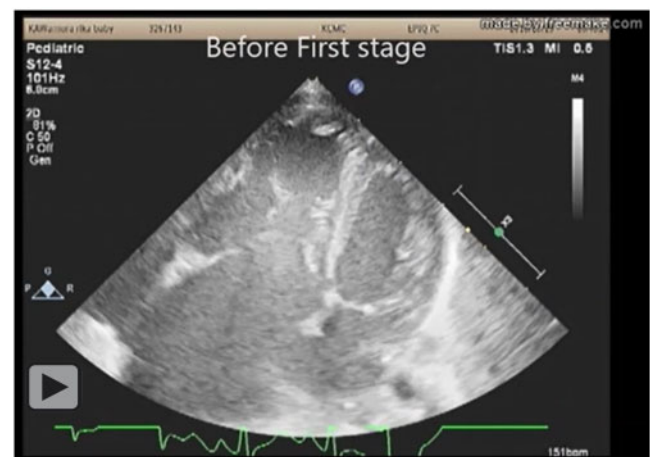


Figure 4: Overall outcomes of Kaplan-Meier survival. The survival of the study group ($n=27$) was remarkably improved compared with that of the control group ($n=25$) as a whole. The HR for foetuses in the study group, compared with the control group, was 0.12 (95% CI 0.03–0.43; $P=0.0007$). These excellent results could be attributed to the newly developed, rapid 2-stage Starnes procedure. CI: confidence interval; HR: hazard ratio.



Video 1: Remarkable improvement in the echocardiographic septal motion in the video of case 6. In the first half of the video, the paradoxical septal motion is prominent immediately after birth. The video in the latter half shows the remarkable improvement of the septal motion after the second stage.

performed to save the baby's life. After this, the RA area index increased to 2.7, which signalled foetal hydrops with pericardial effusion and myocardial oedema. The LV ejection fraction (EF) was ~10% with severely affected paradoxical septal motion. After the emergency Caesarean section, the baby was carried to the operating room for the first stage of the procedure; the paradoxical septal motion improved, but only temporarily. The haemodynamics became unstable shortly after the first stage of the procedure. Eighteen hours later, we carried the baby to the operating room to perform the second stage of the procedure, which led to a normalized septal motion. However, the LV EF was unchanged at ~10%. To restore the LV systolic function, 7 days of ventricular assist device (VAD) assistance was required. The modified Blalock–Taussig shunt was used as a PA blood source. As the respiratory function of the native lungs was kept stable, the VAD could work well without an oxygenator. The LV EF improved to 50% on the seventh day, and then, the baby was successfully weaned from VAD. However, the patient was respirator dependent because of congestive heart failure, which was in turn caused by a high PA blood flow due to their small body weight (<2.2 kg). Extubation became possible only after 2 months. BCPS was performed at the age of 77 days; this process helped result in volume unloading, and the patient was successfully extubated 2 days after BCPS. In addition, BCPS was performed via a right thoracotomy due to a superficial sternal wound infection. The patient was discharged from hospital on the 15th postoperative day.

DISCUSSION

A newly developed rapid 2-stage Starnes approach was successfully applied to 6 high-risk neonates who were prenatally diagnosed with Ebstein anomaly. This approach resulted in excellent survival rates, with no deaths. All but 1 patient completed the Fontan operation, and the remaining 1 is awaiting Fontan. The overall hazard ratio in the study group was 0.12 ($P=0.0007$), as compared with the control group (Fig. 4). Thus, our management approach can be effective in high-risk neonates with Ebstein anomaly.

Six articles in this past decade that focused on high-risk neonates with Ebstein anomaly reported a survival rate of ~10–20% of patients that survived more than 30 days [7–11, 14]. Our approach in the treatment of high-risk and critically ill neonates with Ebstein anomaly is feasible and thus holds promise.

The possible mechanism underlying the successful surgery for high-risk neonates with Ebstein anomaly needs to be addressed. Excessive RV volume loading impedes LV filling and impairs global ventricular function through the mechanism of ventricular interdependence [21, 22]. In this regard, it is important to reduce the size of a dilated right side of the heart to improve LV filling and increase cardiac output. To achieve maximum benefits, the internal RV exclusion technique was added to reinforce the present procedure.

Notwithstanding the beneficial effects of the procedure on LV diastolic function, little was known regarding the effects of the procedure on LV systolic function. Concerned with the action of ventricular interdependence, Fukamachi *et al.* [22] demonstrated in an *in vivo* experiment that LV volume unloading during left VAD had a positive effect on the RV diastolic function and, in contrast, a negative impact on RV systolic function. Taking both

negative systolic and positive diastolic function into consideration, they showed that RV pump performance, as a net effect, improved. Their experimental results thus may better our understanding of the impact of the volume unloading of 1 ventricle on the systolic and diastolic function as well as the global ventricular performance of the opposite ventricle. In case 4, however, the pathogenesis of the ventricular dysfunction seemed different from that of the remaining 5 patients and, thus, the beneficial effect of our procedure was limited. Severely depressed LV systolic function (EF = 10%) is most probably caused by myocardial swelling, which was associated with intrauterine hydrops. VAD was thus required to support systemic perfusion and help recover ventricular systolic function.

Biventricular repair can be the surgery of choice, whenever anatomically feasible. The treatment of choice for a safe and effective approach in our high-risk patients, however, can be univentricular palliation rather than biventricular repair. Because of severely depressed clinical conditions as shown in Table 2 and remarkably poor short-term outcomes as shown in Fig. 2, surgical insults of biventricular repair and the time required for evaluating the ability of biventricular circulation seemed hardly tolerable [14]. We thus decided to pursue a univentricular pathway for high-risk neonates. On the other hand, among 17 live-born patients with RA area index <1.5 in the study group, 16 had biventricular physiology with stable RV function.

Finally, the excellent outcomes presented here can be attributed to the planned approach, including a scheduled delivery and prompt initiation of the rescue surgery triaged by selection criteria derived from foetal echocardiographic findings. It is uncertain, however, to what extent the 2-stage approach could contribute to success in the rescue surgery for critically ill neonates. As described in Table 2, the interval between the 2 stages in 4 neonates (case 3–6) was shorter than we expected. A rapid 1-stage Starnes procedure could arguably provide the same excellent results; this may warrant a subsequent clinical trial of a planned rapid 1-stage Starnes approach. Our proposal in the present study was just the start in the treatment of this challenging disease, but we believe that it could inform further improvement in desperately poor outcomes in the treatment of high-risk neonates with Ebstein anomaly.

CONCLUSIONS

We found that the planned management strategy, focusing on the reduction in the size of the right side of the heart, led to improving LV diastolic function and LV pump performance and thus yielded excellent short- and long-term outcomes for high-risk neonates with Ebstein anomaly.

ACKNOWLEDGEMENTS

The authors are significantly indebted to their multidisciplinary team members, discussed in the paper, for their contribution to decision-making concerning fetuses with Ebstein anomaly. The authors also would like to thank Tom R. Karl for his valuable comment on an earlier draft and Albert T. Lopolisa for helping prepare video imaging.

Conflict of interest: none declared.

Author contributions

Toshihide Asou: Conceptualization; Data curation; Formal analysis; Investigation; Methodology; Supervision; Visualization. **Motoyoshi Kawataki:** Data curation; Methodology; Project administration; Visualization. **Yuko Takeda:** Data curation; Methodology. **Hidetsugu Asai:** Data curation; Methodology. **Tsuyoshi Tachibana:** Methodology. **Katsuaki Toyoshima:** Data curation; Methodology; Validation. **Ki-Sung Kim:** Data curation; Investigation; Methodology; Visualization. **Hideaki Ueda:** Supervision.

Reviewer information

The European Journal of Cardio-Thoracic Surgery thanks René Prêtre, Shunji Sano and the other anonymous reviewer(s) for their contribution to the peer review process of this article.

REFERENCES

- [1] Celermajer DS, Cullen S, Sullivan ID, Spiegelhalter DJ, Wyse RKH, Deanfield JE. Outcome in neonates with Ebstein's anomaly. *J Am Coll Cardiol* 1992;19:1041–6.
- [2] Celermajer DS, Bull C, Till JA, Cullen S, Vassilikos VP, Sullivan ID *et al.* Ebstein's anomaly: presentation and outcome from fetus to adult. *J Am Coll Cardiol* 1994;23:170–6.
- [3] Hornberger LK, Sahn DJ, Kleinman CS, Copel JA, Reed KL. Tricuspid valve disease with significant tricuspid insufficiency in the fetus: diagnosis and outcome. *J Am Coll Cardiol* 1991;17:167–73.
- [4] Sharland GK, Chita SK, Allan LD. Tricuspid valve dysplasia or displacement in intrauterine life. *J Am Coll Cardiol* 1991;17:944–9.
- [5] Yetman AT, Freedom RM, McCrindle BW. Outcome in cyanotic neonates with Ebstein's anomaly. *Am J Cardiol* 1998;81:749–54.
- [6] Starnes VA, Pitlick PT, Bernstein D, Griffin ML, Choy M, Shumway NE. Ebstein's anomaly appearing in the neonate: a new surgical approach. *J Thorac Cardiovasc Surg* 1991;101:1082–7.
- [7] McElhinney DB, Salvin JW, Colan SD, Thiagarajan R, Crawford EC, Marcus EN *et al.* Improving outcomes in fetuses and neonates with congenital displacement (Ebstein's malformation) or dysplasia of the tricuspid valve. *Am J Cardiol* 2005;96:582–6.
- [8] Andrews RE, Tibby SM, Sharland GK, Simpson JM. Prediction of outcome of tricuspid valve malformations diagnosed during fetal life. *Am J Cardiol* 2008;101:1046–50.
- [9] Barre E, Durand I, Hazelzet T, David N. Ebstein's anomaly and tricuspid valve dysplasia: prognosis after diagnosis in utero. *Pediatr Cardiol* 2012; 33:1391–6.
- [10] Kajihara N, Asou T, Takeda Y, Kosaka Y, Onakatomi Y, Miyata D *et al.* Rapid two-stage Starnes procedure for a symptomatic neonate with Ebstein's anomaly. *Ann Thorac Surg* 2010;90:2073–5.
- [11] Tsukimori K, Morihana E, Fusazaki N, Takahata Y, Oda S, Kado H. Critical Ebstein's anomaly in a fetus successfully managed by elective preterm delivery and surgical intervention without delay after birth. *Pediatr Cardiol* 2012;33:343–6.
- [12] Davies RR, Pasquali SK, Jacobs ML, Jacobs JJ, Wallace AS, Pizarro C. Current spectrum of surgical procedures performed for Ebstein's malformation: an analysis of The Society of Thoracic Surgeons Congenital Heart Surgery database. *Ann Thorac Surg* 2013;96:1703–10.
- [13] Freud LR, Escobar-Diaz MC, Kalish BT, Komarlu R, Puchalski MD, Jaeggi ET *et al.* Outcomes and predictors of perinatal mortality in fetuses with Ebstein anomaly of tricuspid valve dysplasia in the current era: a multi-centre study. *Circulation* 2015;132:481–9.
- [14] Elzein C, Subramanian S, Ilbawi M. Surgical management of neonatal Ebstein's anomaly associated with circular shunt. *World J Pediatr Congenit Heart Surg* 2019;10:116–20.
- [15] Sano S, Ishino K, Kawada M, Kasahara S, Kohmoto T, Takeuchi M *et al.* Total right ventricular exclusion procedure: an operation for isolated congestive right ventricular failure. *J Thorac Cardiovasc Surg* 2002;123: 640–7.
- [16] Takagaki M, Ishino K, Kawada M, Ohtsuki S, Hirota M, Tedoriya T *et al.* Total right ventricular exclusion improves left ventricular function in patients with end-stage congestive right ventricular failure. *Circulation* 2003;108(Suppl 1):II226–9.
- [17] Sano S, Fujii Y, Kasahara S, Kuroko Y, Tateishi A, Yoshizumi K *et al.* Repair of Ebstein's anomaly in neonates and small infants: impact of right ventricular exclusion and its indications. *Eur J Cardiothorac Surg* 2013;45:449–55.
- [18] Kanda Y. Investigation of the freely available easy-to-use software 'EZ' for medical statistics. *Bone Marrow Transplant* 2013;48:452–8.
- [19] The Comprehensive R Archive Network. <https://cran.r-project.org/> (10 December 2019, date last accessed).
- [20] Gravett C, Eckert LO, Gravett MG, Dudley DJ, Stringer EM, Bodjick T *et al.* Non-reassuring fetal status: case definition & guidelines for data collection, analysis, and presentation of immunization safety data. *Vaccine* 2016;34:6084–92.
- [21] Anastasiadis K, Antonitis P, Westaby S. Physiology of the failing right heart. In: Anastasiadis K, Westaby S, Antonitis P (eds). *The Failing Right Heart*. Heidelberg: Springer International Publishing, Switzerland, 2015, 15–32.
- [22] Fukamachi K, Asou T, Nakamura Y, Oe M, Sakamoto M, Kishizaki K *et al.* Effects of left heart bypass on right ventricular performance. Evaluation of the right ventricular end-systolic and end-diastolic pressure-volume relation in the in situ normal canine heart. *J Thorac Cardiovasc Surg* 1990;99:725–34.