



## Case report

# An unusual case of splenomegaly and increased lactate dehydrogenase heralding acute myeloid leukemia with eosinophilia and RUNX1–MECOM fusion transcripts



Fabio Forghieri\*, Sara Bigliardi, Monica Morselli, Leonardo Potenza, Valeria Fantuzzi, Laura Faglioni, Vincenzo Nasillo, Andrea Messerotti, Ambra Paolini, Mario Luppi

Department Medical and Surgical Sciences, Section of Hematology, University of Modena and Reggio Emilia, Azienda Ospedaliero-Universitaria Policlinico, Modena, Italy

## ARTICLE INFO

## Article history:

Received 9 July 2014

Received in revised form

28 August 2014

Accepted 21 September 2014

Available online 30 September 2014

## Keywords:

Acute myeloid leukemia

t(3;21)(q26;q22)

RUNX1–MECOM

Eosinophilia

Splenomegaly

Myeloproliferative neoplasm

## ABSTRACT

We report the first case of acute myeloid leukemia (AML) with RUNX1–MECOM fusion transcripts, showing marked eosinophilia. A 63-year old man admitted in August 2013, had previously been observed in April 2013, because of persisting homogeneous splenomegaly and increased LDH, which were initially attributed to both minor  $\beta$ -thalassemia and previous acute myocardial infarction. However, based upon the retrospective analysis of clinical features combined with the documentation of both JAK2 V617F and c-KIT D816V mutations at AML diagnosis, an aggressive leukemic transformation with eosinophilia of a previously unrecognized myeloproliferative neoplasm, rather than the occurrence of *de novo* AML, may be hypothesized.

© 2014 The Authors. Published by Elsevier Ltd. This is an open access article under the CC BY-NC-ND license (<http://creativecommons.org/licenses/by-nc-nd/3.0/>).

The t(3;21)(q26;q22) is a rare cytogenetic abnormality, reported in approximately 1% of all myelodysplastic syndrome (MDS) or acute myeloid leukemia (AML) cases and mainly occurring in therapy-related myeloid neoplasms, in accelerated or blast phase of chronic myeloid leukemia or other myeloproliferative neoplasms (MPN), and, rarely, in *de novo* AML [1–6]. Previous treatment with hydroxycarbamide or other antimetabolites is strongly implicated as a contributory cause [4]. The presence of t(3;21)(q26;q22), isolated or associated with other chromosomal abnormalities, is associated with a very poor prognosis [5]. In this translocation, portions of the RUNX1 gene have been reported to be variably fused to MECOM (currently preferred designation for the genes located within the 3q26 region, namely RPL22, MDS1, EVI1), as a result of alternative intergenic splicing, with production of multiple fusion transcripts [1–3]. RUNX1–MECOM (formerly AML1–MDS1–EVI1) fusion products directly contribute to leukemogenesis or leukemic transformation, can block myeloid differentiation and promote proliferation by exerting a dominant-negative effect over RUNX1-induced normal transcriptional activation, antagonize the growth-inhibitory effects of transforming growth factors, block JNK activity and therefore prevent

stress-induced apoptosis, and enhance AP-1 activity [7,8]. We report here the unusual case of an elderly patient observed because of persisting splenomegaly and increased lactate dehydrogenase (LDH), heralding AML with eosinophilia and RUNX1–MECOM fusion transcripts.

In details, a 63-year old Caucasian man with previous history of minor  $\beta$ -thalassemia, arterial hypertension, hypothyroidism, fibromyalgia, benign prostatic hyperplasia and acute myocardial infarction in 2009 was admitted to our outpatient's Hematology Unit in April 2013 because of splenomegaly and persistently increased LDH, mainly LDH2 isoform, since 2009. The blood examinations documented white blood cell (WBC) count  $4.7 \times 10^9/L$ , with a differential count showing 47% neutrophils, 34% lymphocytes, 9% monocytes, 5% eosinophils, 5% basophils, hemoglobin (Hb) level 15.4 g/dl with MCV 76 fl, platelet (Plt) count  $338 \times 10^9/L$ , serum LDH 1053 IU/L. The morphological examination of the peripheral blood (PB) smear did not document cytological abnormalities, while neutrophil alkaline phosphatase activity was elevated. Neither abnormal myeloid cells nor atypical lymphocytes were detected by flow cytometry on PB samples. Microbiological, virological and autoimmunity examinations were negative. Homogeneous splenomegaly (bipolar diameter 16.2 cm) without signs of portal hypertension was observed on ultrasonography. Neither bone marrow (BM) examination nor cytogenetic and molecular analyses were performed at this time-point, whereas the morphological examination of a BM aspirate performed

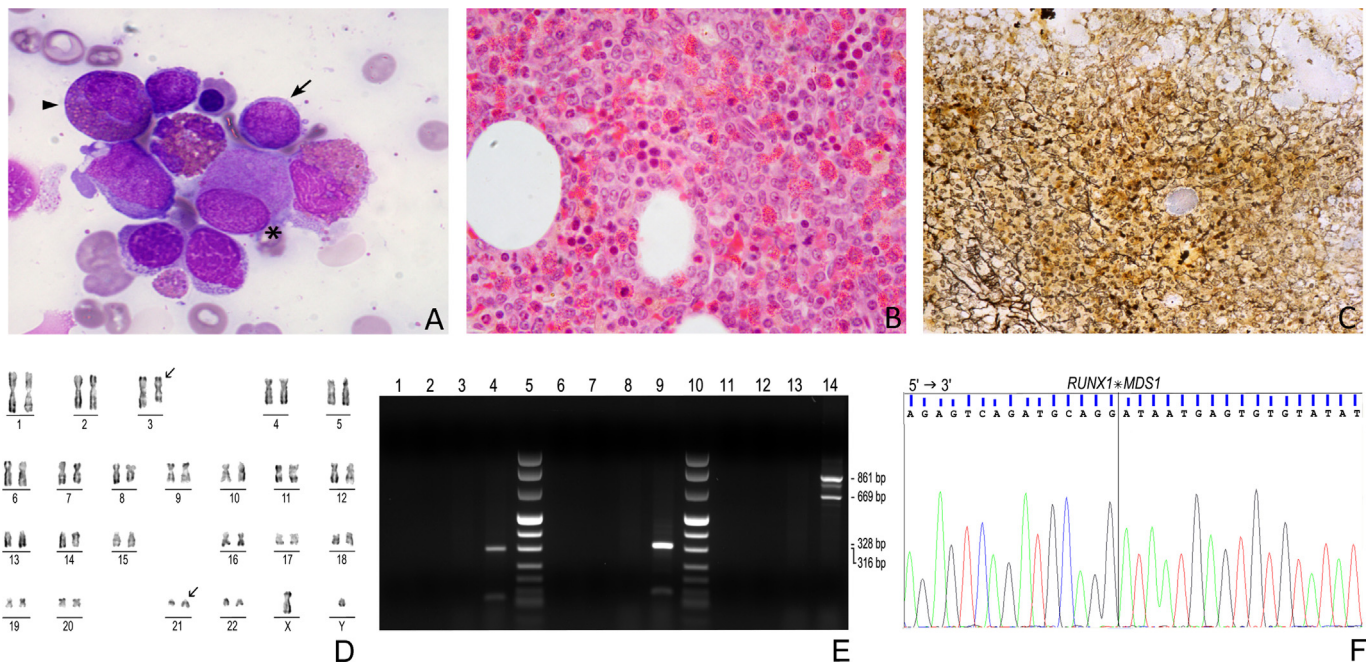
\* Correspondence to: Department of Medical and Surgical Sciences, University of Modena and Reggio Emilia, Azienda Ospedaliero-Universitaria Policlinico, Via del Pozzo 71, 41100 Modena, Italy. Tel.: +39 059 4222447; fax: +39 059 4222386.

E-mail address: [fabio.forghieri@unimore.it](mailto:fabio.forghieri@unimore.it) (F. Forghieri).

in 2008 because of transient mild neutropenia was unrevealing. In August 2013 the patient was subsequently admitted because of fever, fatigue, abdominal pain and drenching night sweats. The laboratory investigations revealed WBC count  $12.2 \times 10^9/L$  with a differential count showing 25% neutrophils, 11% lymphocytes, 2% monocytes, 43% eosinophils, 1% basophils and 18% blasts, Hb level 9.7 g/dl, Plt count  $17 \times 10^9/L$ , LDH 548 IU/L. Unfortunately, serum tryptase level was not measured. Homogeneous splenomegaly was worsened (bipolar diameter 20 cm), as observed on abdominal ultrasonography. The morphological examination of BM aspirate (Fig. 1A) and trephine biopsy (Fig. 1B) showed hypercellularity (90%), with marked proliferation of eosinophil granulocytopenia (40%), multilineage myelodysplastic features, especially with small hypolobated megakaryocytes, and a blast cell count 20–30%. Blast cells were minimally differentiated, with high nuclear/cytoplasmic ratio and basophilic cytoplasm. They were CD34+, CD33+/-, CD13+, CD117+, HLA-DR+, CD38+, c-MPO- by flow cytometry analysis performed on the BM aspirate. Moreover, mild BM fibrosis was documented on Gomori methenamine silver staining (Fig. 1C). The presence of dense mast cell collections or atypical spindle-shaped mast cells was morphologically excluded. Moreover, neither immunohistochemical examinations for CD68 and CD117 nor flow-cytometry analyses to investigate the expression of CD2, CD25 and CD117, performed on BM trephine biopsy and BM aspirate, respectively, documented atypical or aggregated mast cells (not shown). Unfortunately, immunostaining for tryptase was not performed. Based upon these features, AML with MDS-related changes and eosinophilia was thus diagnosed. Conventional G-banding showed 46,XY,t(3;21)(q26;q22) karyotype in all the 20 metaphase cells analyzed (Fig. 1D). Molecular examinations, namely reverse transcriptase (RT)-PCR (Fig. 1E) and subsequent sequencing analyses (Fig. 1F) performed on both PB and BM samples, also documented RUNX1-MECOM, alternatively spliced multiple fusion transcripts [1–3].

Further extensive FISH and molecular studies failed to detect either BCR-ABL, PDGFRA, PDGFRB and FGFR1 rearrangements or NPM1 and FLT3 mutations, whereas c-KIT D816V mutation was found on PB and BM mononuclear cells. Moreover, allele-specific PCR demonstrated JAK2 V617F mutation on both PB and BM polymorphonuclear cells, but JAK2 V617F allele burden was not assessed at AML diagnosis or during the subsequent course of the disease. An aggressive clinical behavior was observed. The patient was refractory to remission induction chemotherapy (cytarabine 100 mg/m<sup>2</sup> on days 1–7 and daunorubicin 45 mg/m<sup>2</sup> on days 1–3) and subsequent salvage chemotherapeutic FLAG regimen (fludarabine 30 mg/m<sup>2</sup> and cytarabine 2 g/m<sup>2</sup> on days 1–5, G-CSF, 5 mcg/kg/day from day -1 to day +5). Thereafter, he received best supportive care and was lost of follow-up.

To the best of our knowledge, we have described here the first case of AML with RUNX1-MECOM fusion transcripts and concurrent JAK2 V617F and c-KIT D816V mutations, showing marked peripheral and BM eosinophilia. AML with eosinophilia is usually found in core binding factor (CBF) leukemias, with cytogenetic abnormalities such as inv(16)(p13q22)/t(16;16)(p13;q22) resulting in CBFβ-MYH11 fusion transcript or t(8;21)(q22;q22) resulting in RUNX1-RUNX1T1 fusion transcript. However, it is also rarely associated with other translocations such as t(16;21)(q24;q22), which produces the RUNX1-CBFA2T3 fusion transcript [9]. Of interest, c-KIT mutations are documented in approximately 25–30% of cases of CBF leukemia, whereas they are infrequent in other AML subtypes [10]. It has also recently been reported that patients with t(8;21)-positive AML showed one or two additional gene mutations in up to 50% or 15% of the cases, respectively [11]. The most common mutated genes, in that series, were c-KIT (23/139 patients; 16.5%), NRAS (18/139 patients; 12.9%) and ASXL1 (16/139 patients; 11.5%), but also FLT3, CBL, KRAS, IDH2 and JAK2 were mutated in 2.9–5% of the cases [11]. Of note, our patient was



**Fig. 1.** (A–F) Morphological examination of bone marrow (BM) aspirate, showing minimally differentiated myeloid blasts (arrow) and abnormal eosinophil precursors (arrowhead), concurrently with small hypolobated megakaryocytes (\*) (A, May Grunwald Giemsa, magnification 400 ×). BM trephine biopsy, showing hypercellularity with marked proliferation of eosinophil granulocytopenia, a blast cell count 20–30% (B, hematoxylin-eosin, magnification 200 ×) and mild BM fibrosis (C, Gomori methenamine silver staining, magnification 100 ×). Conventional G-banding showing 46,XY,t(3;21)(q26;q22) karyotype (D). Reverse-transcriptase PCR (E) confirmed the presence of RUNX1-MECOM fusion transcripts. Alternatively spliced multiple fusion transcripts including RUNX1-RPL22 (316 bp, lane 4), RUNX1-MDS1 (328 bp, lane 9) and RUNX1-MDS1-EV11 (861 and 669 bp, lane 14) products were detected. Lanes 1–3, lanes 6–8 and lanes 11–13 refer to negative controls. Lanes 5 and 10 refer to molecular weight marker VIII. Subsequent sequencing analyses confirmed breakpoints of RUNX1-MECOM fusion transcripts. Diagrammatic representation of RUNX1-MDS1 fusion product with detailed sequencing results at the fusion junction site is shown (F).

previously observed, a few months before AML diagnosis, because of persisting homogeneous splenomegaly and increased LDH, which, in the absence of any other features suspected for hematologic malignancy, except for a mild increase of morphologically normal basophils, were initially attributed to both minor  $\beta$ -thalassemia and previous acute myocardial infarction. However, based upon the retrospective analysis of the clinical features combined with the documentation of both JAK2 V617F and c-KIT D816V mutations on PB and BM samples at AML diagnosis, an aggressive leukemic transformation with eosinophilia and t(3;21)(q26;q22) translocation of a previously unrecognized MPN, rather than the occurrence of a *de novo* AML, may be hypothesized in our case [4,5]. Unfortunately, PB samples adequate for molecular examinations were not stored in April 2013, so we could not retrospectively investigate the presence of JAK2 and KIT mutations at first patient's observation. In the absence of available samples for BM morphological examinations or cytogenetic/molecular analyses before AML diagnosis, we cannot have confirmation of a potential MPN diagnosis preceding AML. Furthermore, neither JAK2 V617F allele burden at different time-points nor JAK2 V617F mutation analysis on purified myeloid blasts were available, so that we cannot exclude that such mutation would have been limited to polymorphonuclear cells. Of note, the latter possibility would not be surprising, because it has previously been reported that leukemic blasts are frequently negative for the JAK2 V617F mutation in transformed JAK2 V617F-positive MPN [12]. The unusual clinical picture of our patient may suggest the need to perform either BM morphological examinations or cytogenetic/molecular analyses, at least on PB samples, to rule out MPN in similar cases observed for persisting/worsening splenomegaly and increased LDH, even in the absence of significant morphological and immunophenotypic abnormalities on PB. Furthermore, we have reported the association of AML with eosinophilia with another chromosomal translocation involving RUNX1, located at 21q22 region, suggesting the need to further investigate molecular mechanisms underlying the presence of abnormal eosinophilia in hematologic malignancies.

#### Conflict of interest

The authors indicated no potential conflicts of interest.

#### Authors' contributions

FF and SB analyzed clinical, cytogenetic and molecular data and wrote the manuscript; MM, LP, VF, LF, VN, AM, AP took care of the

patient, collected and analyzed clinical data and critically revised the manuscript; ML critically revised the manuscript. All authors approved the final version of the manuscript.

FF and SB equally contributed to the work.

#### Acknowledgments

This work was supported by grants from the Associazione Italiana Lotta alle Leucemie, Linfoma e Mieloma (AIL) – Sezione 'Luciano Pavarotti' Modena-ONLUS (to FF and LP) and from the Associazione Italiana per la Ricerca sul Cancro (AIRC, IG 14797-2013 to ML).

#### References

- [1] Nucifora G, Begy CR, Kobayashi H, Roulston D, Claxton D, Pedersen-Bjergaard J, et al. Consistent intergenic splicing and production of multiple transcripts between AML1 at 21q22 and unrelated genes at 3q26 in (3;21)(q26;q22) translocations. *Proc Natl Acad Sci USA* 1994;91:4004–8.
- [2] Park TS, Choi JR, Yoon S, Song J, Kim J, Kim SJ, et al. Acute promyelocytic leukemia relapsing as secondary acute myelogenous leukemia with translocation t(3;21)(q26;q22) and RUNX1–MDS1–EVI1 fusion transcript. *Cancer Genet Cytogenet* 2008;187:61–79.
- [3] Yang JJ, Cho SY, Suh JT, Lee HJ, Lee WI, Yoon HJ, et al. Detection of RUNX1–MECOM fusion gene and t(3;21) in a very elderly patient having acute myeloid leukemia with myelodysplasia-related changes. *Ann Lab Med* 2012;32:362–5.
- [4] Yin CC, Cortes J, Barkoh B, Hayes K, Kantarjian H, Jones D. t(3;21)(q26;q22) in myeloid leukemia: an aggressive syndrome of blast transformation associated with hydroxyurea or antimetabolite therapy. *Cancer* 2006;106:1730–8.
- [5] Li SL, Yin CC, Medeiros J, Bueso-Ramos C, Lu GL, Lin P. Myelodysplastic syndrome/acute myeloid leukemia with t(3;21)(q26.2;q22) is commonly a therapy-related disease associated with poor outcome. *Am J Clin Pathol* 2012;138:146–52.
- [6] Mitelman F, Johansson B, Mertens F., editors. *Mitelman Database of Chromosome Aberrations and Gene Fusions in Cancer*. Available at (<http://cgap.nci.nih.gov/Chromosomes/Mitelman>); 2013 [accessed 27.12.13].
- [7] Lo Coco F, Pisegna S, Diverio D. The AML1 gene: a transcription factor involved in the pathogenesis of myeloid and lymphoid leukemias. *Haematologica* 1997;82:364–70.
- [8] Mitani K. Molecular mechanisms of leukemogenesis by AML1/EVI-1. *Oncogene* 2004;23:4263–9.
- [9] Park IJ, Park JE, Kim HJ, Jung HJ, Lee WG, Cho SR. Acute myeloid leukemia with t(16;21)(q24;q22) and eosinophilia: case report and review of the literature. *Cancer Genet Cytogenet* 2010;196:105–8.
- [10] Paschka P, Dohner K. Core-binding factor acute myeloid leukemia: can we improve on HiDAC consolidation? *Hematol Am Soc Hematol Educ Program* 2013:209–19.
- [11] Krauth MT, Eder C, Alpermann T, Bacher U, Nadarajah N, Kern W, et al. High number of additional genetic lesions in acute myeloid leukemia with t(8;21)/RUNX1–RUNX1T1: frequency and impact on clinical outcome. *Leukemia* 2014;28:1449–58.
- [12] Theoharides A, Boissinot M, Girodon F, Garand R, Teo SS, Lippert E, et al. Leukemic blasts in transformed JAK2-V617F-positive myeloproliferative disorders are frequently negative for the JAK2-V617F mutation. *Blood* 2007;110:375–9.