

Intramedullary Metastasis to the Cervical Spinal Cord from Malignant Pleural Mesothelioma: Review of the Literature and Case Reports

Abstract

Context: Malignant mesothelioma is an aggressive tumor; median survival of patients following diagnosis is 12 months. **Aims:** Pleural malignant mesothelioma tends to spread along preexisting tissue planes and has the rare ability to spread along the nerve root into the spinal cord. In our case, there is an evidence of exceptional direct hematogenous spread to the spinal cord by the spinal branch of the intercostal arteries or the veins of Batson's plexus. **Settings and Design:** The authors report a case of intramedullary hematogenous metastasis to the cervical spinal cord from malignant mesothelioma, with a review of the literature. **Materials and Methods:** A 68-year-old male was admitted to our department because of a slowly progressive mild weakness of both low extremities, more pronounced on the left side. The patient has been treated for a malignant mesothelioma with left thoracotomy and subsequently underwent radiotherapy. Magnetic resonance imaging of the cervical-thoracic spine revealed a contrast-enhancing intramedullary expansive lesion of the left half of the spinal cord at the C6–C7 level. **Results:** The patient underwent surgical treatment through a C6–C7 laminectomy. Through a median posterior spinal cord incision, an intramedullary grayish lesion was completely removed. The paraparesis progressively improved and 20 days after surgery, the patient had regained normal lower extremity function. **Conclusions:** Malignant mesothelioma can spread to the spinal canal by the direct extension through the intervertebral foramina, by hematogenous spread to the spinal meninges, and by perineural growth along a single nerve root. The cleavage plane of the tissue may determine whether a successful gross total resection can be achieved with a good outcome for the patient.

Keywords: Cervical spinal cord, intramedullary metastasis, malignant mesothelioma, surgery

Introduction

Malignant mesothelioma is aggressive cancer arising from the mesothelial surfaces of the pleural in 80% of all cases.^[1] The prognosis of pleural malignant mesothelioma (PMM) is dismal even with multimodal therapy; median survival is 12 months after symptom onset.^[1-5] PMM has an increasing incidence due to environmental factors and has been strongly related to inhalational exposure to asbestos^[1,4,6-8] but also inhalation of other mineral fibers, such as erionite, a fibrous crystal found in Turkey, has also been identified as a risk factor.^[3] Although malignant mesothelioma is a rare disease, the lack of effectiveness in treatment and the increasing incidence through the world have led to improve the clinical research in this field.^[1,9]

This is an open access journal, and articles are distributed under the terms of the Creative Commons Attribution-NonCommercial-ShareAlike 4.0 License, which allows others to remix, tweak, and build upon the work non-commercially, as long as appropriate credit is given and the new creations are licensed under the identical terms.

For reprints contact: reprints@medknow.com

Mesothelioma has a predilection for local spread into adjacent tissues.^[10] Sites of spread are most thoracic lymph nodes, the contralateral pleura, the abdominal cavity, and distant organs through hematogenous dissemination in the later stages of the disease.^[2,11-14]

Spinal involvement of a PMM is exceptional with only a few reported cases.^[11-33]

The authors report a case of a hematogenous intramedullary metastasis to the cervical spinal cord from malignant mesothelioma. Six articles with cranial or spinal meningeal infiltration of a mesothelioma without intradural tumor were found in literature.^[28,30,34-36] Ten reports [Table 1] were retrieved with one case of intradural mesothelioma each,^[12,13,17-23,25] two of which were in intradural extramedullary location,^[23,24] and eight of which showed intramedullary

**Fotios Kalfas,
Claudia Scudieri¹**

Department of Neurological Surgery, Galliera Hospitals, Genova, ¹Department of Neurosurgery and Gamma Knife Radiosurgery, IRCCS San Raffaele Scientific Institute, Vita-Salute University, Milan, Italy

Address for correspondence:

Dr. Fotios Kalfas,
Department of Neurological Surgery, Galliera Hospitals, Via delle Cappuccine, 16128, Genova, Italy.
E-mail: fkalfas@fiscali.it
Dr. Claudia Scudieri,
Department of Neurosurgery and Gamma Knife Radiosurgery, IRCCS San Raffaele Scientific Institute, Vita-Salute University, Via Olgettina, 60 20132, Milan, Italy.
E-mail: claudiascudieri@gmail.com

Access this article online

Website: www.asianjns.org

DOI: 10.4103/ajns.AJNS_234_18

Quick Response Code:



How to cite this article: Kalfas F, Scudieri C. Intramedullary metastasis to the cervical spinal cord from malignant pleural mesothelioma: Review of the literature and case reports. Asian J Neurosurg 2020;15:70-5.

Submission: 10-10-2018 **Accepted:** 20-08-2019
Published: 25-02-2020

growth^[12,13,17-22,25] [Table 2]. These eight cases were analyzed and together with the current case, serve as the basis for the discussion of intradural intramedullary metastasis from PMM.

Case Report

On March 2000, a 68-year-old, right-handed male with a history of malignant mesothelioma was admitted to our department after 3 weeks of progressive mild bilateral low extremity weakness, more pronounced on the left side. The patient had previous occupational exposure to asbestos working at a fiber cement factory for 20 years, and in 1989, he was diagnosed with asbestosis. He had undergone a left thoracotomy for tumor resection and subsequently treated with local radiotherapy 1 year ago.

Neurological examination revealed a paraparesis of lower extremities (4/5 on the right and 3/5 on the left side), decreased light touch, pain, and temperature sensation on the right side below T1, without sphincter disturbance. Increased reflexes in the lower extremities, while the joint position and vibration sense were normal. He had upgoing toes bilaterally (partial Brown-Sèquard syndrome).

Cervical X-rays film did not show any bony abnormalities. Magnetic resonance imaging (MRI) of the cervical-thoracic spine revealed a hypointense left intramedullary anterolateral lesion at the level

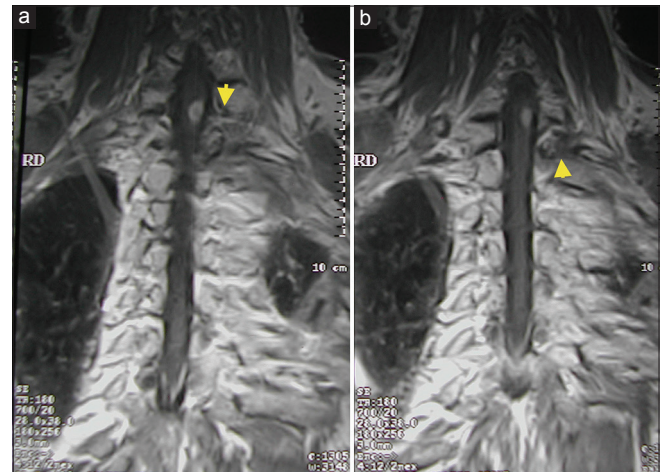


Figure 1: Coronal T1-weighted magnetic resonance images of the cervicothoracic spine after gadolinium injection demonstrating a well-shaped enhancing mass in the spinal cord at the C6–C7 level. Images showing no evidence of (a) perimedullary or paravertebral (b) mass (yellow arrowheads)

Table 1: Intradural spinal cord metastasis from pleural malignant mesothelioma

Author	Patient age/sex	Location	Neurological examination (history of PMM)	Therapy	Histology	Neurological outcome
Steel	54/male	Extramedullary level T1	Partial Brown-Sèquard syndrome (36 months)	Surgical removal	Malignant epithelial mesothelioma	Complete recovery
Cooper D.	67/male	Intramedullary level T8	Paraplegia (not indicated)	Autopsy findings	Not indicated	Unchanged
Lee A.W.	55/female	Intramedullary level T9	Slight paraparesis (18 months)	Not indicated	Not indicated	Not indicated
Hillard V. H.	61/male	Intramedullary level C7/T1	Right Horner syndrome, paraparesis (24 months)	Extradural decompression, intradural exploration	Malignant mesothelioma	Slight improvement
Payer M.	50/male	Intramedullary level T5	Partial Brown-Sèquard syndrome (28 months)	Extradural decompression, intradural exploration	Sarcomatous type malignant mesothelioma	Unchanged, progressive worsening
Okura H.	61/male	Intramedullary level T4	Paraparesis, sphincter dysfunction (10 months)	Intradural exploration	Sarcomatous type malignant mesothelioma	Unchanged, progressive worsening
Chamberlain M. C.	67/male	Intramedullary level T1-T3, invasion T4 root	Paraparesis (6 months)	CyberKnife radiosurgery	Sarcomatous type malignant mesothelioma	Unchanged
Dewas S.	68/female	Intramedullary level T8-T9	Paraplegia (1 month)	CyberKnife radiosurgery	Sarcomatous type malignant mesothelioma	Unchanged
Richter H.	64/male	Extramedullary level T1-T3, invasion of the nerve roots	Spastic paraplegia (5 months)	Surgical removal, extradural decompression	Desmoplastic type malignant mesothelioma	Initial improvement, subsequent progressive worsening
Yamamoto J	62/male	Intramedullary level C3, invasion C5 root	Brown-Sèquard syndrome, C5 radiculopathy (1 month)	Surgical removal, extradural decompression	Sarcomatous type malignant mesothelioma	Initial improvement, subsequent progressive worsening

Clinical, histological characteristics and neurological outcome. PMM – Pleural malignant mesothelioma

Table 2: Overall review of intramedullary metastasis from pleural malignant mesothelioma

Author (year)	Age/sex	Location	Method of spread	Neurological examination (history of PMM)	Therapy	Histology	Clinical outcome	Survival after treatment
Cooper D. (1974)	67/male	T8	Hematogenous (leptomeningeal spread)	Paraplegia (not indicated)	Autopsy findings	Not indicated	Unchanged	Not indicated
Lee A.W. (2005)	55/female	T9	Direct perineural spread	Slight paraparesis (18 months)	Not indicated	Not indicated	Not indicated	Not indicated
Hillard V. H. (2007)	61/male	C7/T1	Direct perineural spread (along C8-T1 nerve roots)	Right Horner syndrome, paraparesis (24 months)	Extradural decompression, intradural exploration	Malignant mesothelioma	Slight improvement	Not indicated
Payer M. (2007)	50/male	T5	Direct perineural spread (along T4 nerve root)	Partial Brown-Sèquard syndrome (28 months)	Extradural decompression, intradural exploration	Sarcomatous type malignant mesothelioma	Unchanged, progressive worsening	6 months
Okura H. (2009)	61/male	T4	Direct perineural spread (along T4 nerve root)	Paraparesis, sphincter dysfunction (10 months)	Intradural exploration	Sarcomatous type malignant mesothelioma	Unchanged, progressive worsening	3 months
Chamberlain M. C (2009)	67/male	T1-T3	Direct perineural spread (along T4 nerve root)	Paraparesis (6 months)	CyberKnife radiosurgery	Sarcomatous type malignant mesothelioma	Unchanged	Not indicated
Dewas S. (2011)	68/female	T8-T9	Not indicated	Paraplegia (1 month)	CyberKnife radiosurgery	Sarcomatous type malignant mesothelioma	Unchanged	11 months
Yamamoto J. (2013)	62/male	C3 and C5	Hematogenous (without leptomeningeal spread)	Brown-Sèquard syndrome, C5 radiculopathy (1 month)	Intradural exploration, extradural decompression	Sarcomatous type malignant mesothelioma	Initial improvement/ progressive worsening	5 months
Present case	68/male	C6-C7	Hematogenous (without leptomeningeal spread)	Partial Brown-Sèquard syndrome (13 months)	Intradural exploration	Sarcomatous type malignant mesothelioma	Complete recovery	8 months

PMM – Pleural malignant mesothelioma

of C6–C7 strongly enhancing after gadolinium administration [Figures 1 and 2].

The patient underwent surgery through median posterior short incision and C6–C7 laminectomy. Opening the dura and the arachnoid, the spinal cord appeared bulky on the left side by an intramedullary grayish lesion that was completely removed, even though a clear plane was difficult to identify between the tumor and surrounding spinal cord. No intradural or extradural nerve involvement was seen. Pathological examination of the specimen revealed malignant mesothelioma. The cells exhibited large irregular nuclei with prominent nucleoli, small-to-moderate amounts of pale-staining cell cytoplasm, and mitotic figures [Figure 3]. Immunohistochemical staining was positive for keratin, vimentin, epithelial membrane antigen, and cytokeratin 5/6 and was negative for S100, CD15 (LeuM1), and carcinoembryonic antigen. This staining profile was consistent with sarcomatous-type malignant mesothelioma.

The postoperative course was favorable. The patient's neurological condition improved and 20 days after surgery, he had completely regained normal lower extremity

function. Eight months after surgery, the patient died due to the progression of the thoracic disease.

Materials and Methods

Intradural mesothelioma is highly uncommon and has been reported in 11 cases, including the present case, so far^[12,13,17-25] [Tables 1 and 2]. In two cases,^[23,24] the lesion was extramedullary. In one of those two cases,^[23] a thoracic roots invasion by desmoplastic malignant mesothelioma without intramedullary tumor localization were reported.

Discussion

Overhauling our analysis [Tables 1 and 2], spinal involvement of a malignant PMM is in general exceptional and occurs most commonly as involvement of the vertebral body or epidural space.^[3,11,27,33,37,38] Spinal metastasis can be considered as a direct centrifugal extension into the nerve root through the intervertebral foramen, or as a result of hematogenous spread to the meninges through the intercostal arteries or the veins of Batson's plexus.^[21,28,30] A characteristic way of spreading

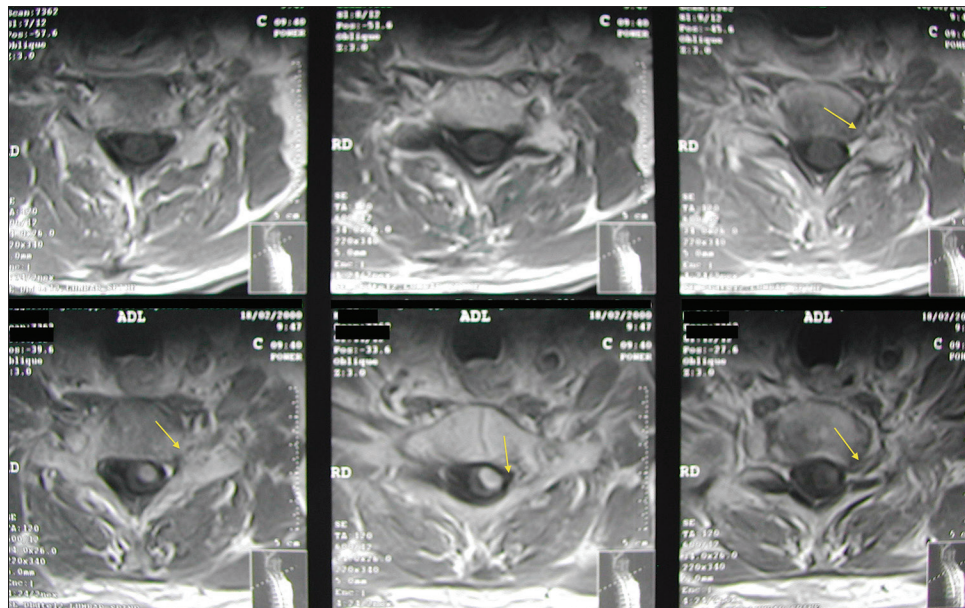


Figure 2: Axial T1-weighted magnetic resonance images after gadolinium injection, showing intradural enhancing mass, with no evidence of transdural extension or foramina involvement (yellow arrows)

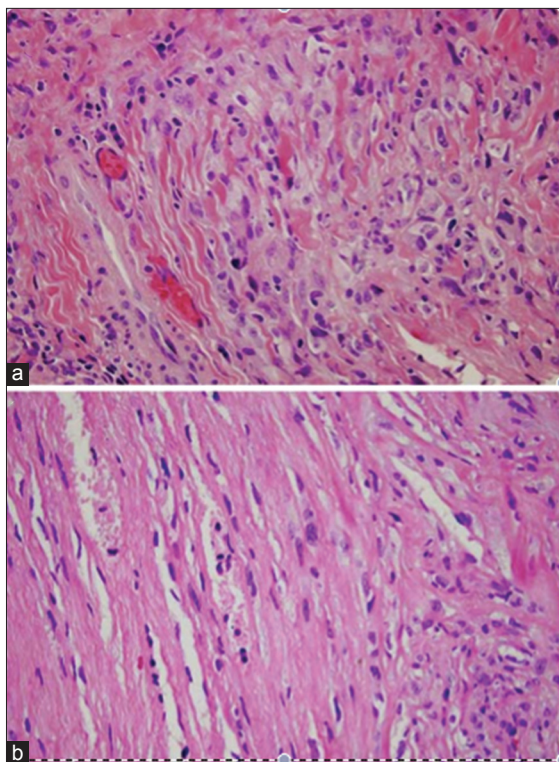


Figure 3: Hematoxylin and eosin staining (a and b) showing mesothelioma cells with large irregular nuclei and prominent nucleoli, pale staining cell cytoplasm, and mitotic figures

is perineural or “neurotropic” growth along nerve roots due to primary tumors neurotropism.^[11,24] Extension along the pia matter or arachnoid membrane surrounding the nerve root, known as leptomeningeal spread, can be interpreted as one of the hematogenous metastases. Eight previous case reports document intramedullary

spinal cord metastasis due to PMM. Compared to all cases reported above, in only three cases (including our case), intramedullary tumors were considered resulted from hematogenous or leptomeningeal spread, without continuity with the pleural lesion.

Due to the paucity of cases, no prediction can be made for which histological type of mesotheliomas has a tendency for intradural spread. Sarcomatous desmoplastic malignant mesotheliomas constitute approximately 10% of malignant mesotheliomas^[1,9,33] and have been more frequently associated with metastasis and shorter survival in one series.^[1]

In six^[17-19,22,25] of the 11 cases reported so far, including the present case, a sarcomatous type malignant mesothelioma was detected in the histological examination suggesting a strong tendency of this type of mesothelioma for intradural spread.

However, it may be hypothesized that a protracted course of disease may leave enough time for a mesothelioma to slowly transgress the dura and infiltrate the spinal cord; concordantly, Lee’s case has a 18-month history,^[38] Hillard’s case a 24-month history,^[12] and Payer’s case a 28-month history of pleural mesothelioma prior to spinal infiltration.^[19] In our case, diagnosis of intradural mesothelioma occurred in a patient with a 14-month history of PMM. The median time from symptom/treatment of PMM to diagnosis of intramedullary mesothelioma is 13.3 months, in the cases reported so far.

In our case, the tumor appeared as an intramedullary localized mass at the C6–C7 level and like in Cooper^[15] and Yamamoto *et al.*^[25] reports, there is an evidence of direct hematogenous spread to the spinal cord by the spinal

branch of the intercostal arteries or the veins of Batson's plexus. Hence, in our case, no leptomeningeal spread or neoplastic deposits to the arachnoid sheath was found. Furthermore, no epidural spinal canal, no nerve roots, or extramedullary involvement was found.

Intramedullary involvement is extremely rare,^[6,12,13,17-22,25] with nine cases including the present case. The majority of reports indicate that the thoracic spinal cord is most often involved, followed by one case of the junction cervical/thoracic cord. Our case is the second reported one of intramedullary cervical spine cord metastasis from PMM^[6,12,13,17-25] [Table 2]. No multiple metastases to the spinal cord are reported so far.

Most patients present with rapid onset of symptoms referable to the spinal cord, including pain, weakness, sensory loss, and incontinence. Weakness is the most common presenting symptom and resembles a Brown-Sèquard syndrome. Sensory symptoms are often difficult to characterize but are frequent and may be contralateral to the weak extremity. In one case (Yamamoto *et al.*^[25]), a Brown-Sèquard syndrome was associated to a C5 radiculopathy. Contrast-enhanced spine MRI is the most sensitive and reliable radiographic means to diagnose intramedullary mesothelioma.

As the disease progresses, patients often deteriorate and manifest a complete spinal cord transection with paraplegia. In most patients reported with intramedullary metastatic mesothelioma who underwent surgery did not achieve any improvement in their neurological condition. In our case, a favorable surgical outcome was achieved with normal lower extremity function. However, patient's preoperative neurological examination (partial Brown-Sèquard syndrome without sphincter disturbance) and short-time diagnosis to surgical treatment, were crucial for the outcome.

If the patient suffers neurological deterioration with possible preservable function, and preoperative imaging not indicates definitively whether the intraspinal involvement is intradural, surgical decompression with intradural exploration is recommended. Extradural tumor can be removed safely in most cases. Intradural tumor's cleavage plane of the tissue may determine whether successful gross total resection can be achieved. In selected cases, partial spinal decompression may be sufficient to prevent further neurological deterioration.^[6]

The treatment of intramedullary metastasis from PMM is poorly defined, as there have been no prospective trials due in large part to the infrequency of occurrence. As a consequence, the literature reflects expert opinion, case series, and review of the literature. Two general approaches have been suggested: resective surgery and CyberKnife stereotactic radiotherapy. In the majority of the cases reported neither of these approaches or improve function. Although not in all cases of intramedullary metastasis due

to PMM, a follow-up is available, an average survival period following diagnosis and treatment of intramedullary mesothelioma is settled between 3 and 11 months [Table 2].

New concept management of patients with PMM has used antifolate (pemetrexed or raltitrexed) platinum combinations and new radiotherapy techniques such as intensity-modulated radiation therapy.^[39]

There are some reports that radiation therapy only is an effective treatment for intramedullary spinal cord metastasis in terms of clinical symptoms and radiological findings.^[17,22,40,41] However, there is no standard treatment for spinal cord metastasis. In case of undiagnosed or limited cases such as radioresistant tumors and rapid neurological deterioration, surgical resection is recommended. In our case, surgical resection was undertaken due to the moderate neurological symptoms, rapidly progressive neurological deterioration, and to confirm the definitive diagnosis.

Conclusions

Spinal metastasis must be considered if a patient with PMM shows neurological worsening, and MRI shows an abnormal lesion in the cervical or more common in the thoracic cord. Sarcomatous-type PMM should be considered propended for intradural metastasis.

Despite the natural history of the disease and the management of the intradural mesothelioma both disappointing, we advocate surgical excision for the extradural localization. However, if the patient has neurological deterioration with possible preservable function, with a short time history of neurological sequelae, we recommend a neurologic decompression with intradural exploration. The cleavage plane of the tissue may determine whether a successful gross total resection can be achieved with a good outcome for the patient.

Declaration of patient consent

The authors certify that they have obtained all appropriate patient consent forms. In the form the patient(s) has/have given his/her/their consent for his/her/their images and other clinical information to be reported in the journal. The patients understand that their names and initials will not be published and due efforts will be made to conceal their identity, but anonymity cannot be guaranteed.

Financial support and sponsorship

Nil.

Conflicts of interest

There are no conflicts of interest.

References

1. Serman DH, Albelda SM. Advances in the diagnosis, evaluation, and management of malignant pleural mesothelioma. *Respirology* 2005;10:266-83.

2. Robinson BW, Musk AW, Lake RA. Malignant mesothelioma. *Lancet* 2005;366:397-408.
3. Pistolesi M, Rusthoven J. Malignant pleural mesothelioma: Update, current management, and newer therapeutic strategies. *Chest* 2004;126:1318-29.
4. West SD, Lee YC. Management of malignant pleural mesothelioma. *Clin Chest Med* 2006;27:335-54.
5. Edwards JG, Abrams KR, Leverment JN, Spyt TJ, Waller DA, O'Byrne KJ. Prognostic factors for malignant mesothelioma in 142 patients: Validation of CALGB and EORTC prognostic scoring systems. *Thorax* 2000;55:731-5.
6. Bourdès V, Boffetta P, Pisani P. Environmental exposure to asbestos and risk of pleural mesothelioma: Review and meta-analysis. *Eur J Epidemiol* 2000;16:411-7.
7. Mohr S, Keith G, Rihn B. Asbestos and malignant pleural mesothelioma: Molecular, cellular and physiopathological aspects. *Bull Cancer* 2005;92:959-76.
8. Pass HI, Lott D, Lonardo F, Harbut M, Liu Z, Tang N, *et al.* Asbestos exposure, pleural mesothelioma, and serum osteopontin levels. *N Engl J Med* 2005;353:1564-73.
9. Hughes RS. Malignant pleural mesothelioma. *Am J Med Sci* 2005;329:29-44.
10. Boutin C, Schlessler M, Frenay C, Astoul P. Malignant pleural mesothelioma. *Eur Respir J* 1998;12:972-81.
11. Gijtenbeek JM, Brouwer HI, Boerman RH, Wiggenraad RG, Vecht CJ, Smitt PA. Extensive epidural cufflike growth of malignant pleural mesothelioma causing spinal cord compression. *J Thorac Cardiovasc Surg* 2002;124:200-2.
12. Hillard VH, Liu JK, Kwok A, Schmidt MH. Perineural spread of malignant mesothelioma resulting in an intradural spinal cord mass: Case report. *J Neurooncol* 2007;81:185-9.
13. Lee AW, Nikitins I, Pozza C, Koblar SA. Pleural mesothelioma with extension into the thoracic spinal cord. *Intern Med J* 2005;35:195-6.
14. Lee YC, Light RW, Musk AW. Management of malignant pleural mesothelioma: A critical review. *Curr Opin Pulm Med* 2000;6:267-74.
15. Semb G. Diffuse malignant pleural mesothelioma: A clinicopathological study of 10 fatal cases. *Acta Chir Scand* 1963;126:78-91.
16. Au VW, Thomas M. Radiological manifestations of malignant pleural mesothelioma. *Australas Radiol* 2003;47:111-6.
17. Chamberlain MC, Eaton KD, Fink JR, Tredway T. Intradural intramedullary spinal cord metastasis due to mesothelioma. *J Neurooncol* 2010;97:133-6.
18. Okura H, Suga Y, Akiyama O, Kudo K, Tsutsumi S, Abe Y, *et al.* Pleural malignant mesothelioma causing cord infiltration through the nerve root. Case report. *Neurol Med Chir (Tokyo)* 2009;49:167-71.
19. Payer M, von Briel T. Intradural pleural malignant mesothelioma. *Acta Neurochir (Wien)* 2007;149:1053-6.
20. Newlin HE, Morris CG, Amdur RJ, Mendenhall WM. Neurotropic melanoma of the head and neck with clinical perineural invasion. *Am J Clin Oncol* 2005;28:399-402.
21. Cooper D. Malignant mesothelioma invading the spinal canal. *Postgrad Med J* 1974;50:718-23.
22. Dewas S, Le Rhun E, Duhem R, Dansin E, Prevost B, Lartigau E. Solitary intramedullary metastasis from malignant pleural mesothelioma treated with cyberKnife®: A case report. *Rev Neurol (Paris)* 2011;167:185-6.
23. Richter H, Hildebrandt G, Heilbronner R. Intradural perineural spread of mesothelioma causing myelopathy by tethering of the spinal cord. *J Neurol Surg A Cent Eur Neurosurg* 2012;73:111-5.
24. Steel TR, Allibone J, Revesz T, D'Arrigo C, Crockard HA. Intradural neurotropic spread of malignant mesothelioma. Case report and review of the literature. *J Neurosurg* 1998;88:122-5.
25. Yamamoto J, Ueta K, Takenaka M, Takahashi M, Nishizawa S. Sarcomatoid malignant mesothelioma presenting with intramedullary spinal cord metastasis: A case report and literature review. *Global Spine J* 2014;4:115-20.
26. Margery J, Grassin F, Le Moulec S, Ruffié P. Spinal cord compression from a malignant pleural mesothelioma. *Rev Pneumol Clin* 2005;61:112-4.
27. Mikhael MA, Paige ML, Thayer C. Computerized tomography of malignant pleural mesothelioma with spinal canal invasion. *Comput Radiol* 1982;6:11-5.
28. Murray JB, Neilly JB, Hadley D, Moran F, McKean M. Diffuse meningeal thickening associated with pleural mesothelioma. *Thorax* 1990;45:70-1.
29. Nixon PF, Wolfenden WH, Hirst E. Paraplegia and destruction of ribs. *Med J Aust* 1964;1:207-12.
30. de Pangher Manzini V, Chizzola A, Brollo A, Bianchi C. Diffuse neoplastic infiltration of leptomeninges by malignant pleural mesothelioma. *Recenti Prog Med* 1989;80:16-7.
31. Rojas JL, Alfageme I, De la Cruz I, Reyes N, Muñoz J. Radicular involvement and medullary invasion from a malignant mesothelioma. *Respiration* 2001;68:106-8.
32. Taryle DA, Lakshminarayan S, Sahn SA. Pleural mesotheliomas – An analysis of 18 cases and review of the literature. *Medicine (Baltimore)* 1976;55:153-62.
33. Hirano H, Maeda H, Sawabata N, Okumura Y, Takeda S, Maekura R, *et al.* Desmoplastic malignant mesothelioma: Two cases and a literature review. *Med Electron Microsc* 2003;36:173-8.
34. Oksüzöğlü B, Yalçın S, Erman M, Dağdelen S. Leptomeningeal infiltration of malignant mesothelioma. *Med Oncol* 2002;19:167-9.
35. Petit BM, Ruffie P, Varlet P, Ciolocca C. Meningeal metastasis of pleural mesothelioma. *Rev Mal Respir* 2001;18:661-3.
36. Petrovic BD, Kozic DB, Semnic RR, Prvulovic M, Djilas-Ivanovic D, Sener RN, *et al.* Leptomeningeal metastasis from malignant pleural mesothelioma. *AJNR Am J Neuroradiol* 2004;25:1223-4.
37. Cheng WF, Berkman AW. Malignant mesothelioma with bone metastases. *Med Pediatr Oncol* 1990;18:165-8.
38. Ishikawa R, Kikuchi E, Jin M, Fujita M, Itoh T, Sawa H, *et al.* Desmoplastic malignant mesothelioma of the pleura: Autopsy reveals asbestos exposure. *Pathol Int* 2003;53:401-6.
39. Ceresoli GL, Gridelli C, Santoro A. Multidisciplinary treatment of malignant pleural mesothelioma. *Oncologist* 2007;12:850-63.
40. Endo S, Hida K, Yano S, Ito M, Yamaguchi S, Kashiwazaki D, *et al.* Intramedullary spinal cord metastasis treated with radiation therapy: Report of 3 cases. *No Shinkei Geka* 2008;36:345-9.
41. Villegas AE, Guthrie TH. Intramedullary spinal cord metastasis in breast cancer: Clinical features, diagnosis, and therapeutic consideration. *Breast J* 2004;10:532-5.