

Letters

Cholethorax following Percutaneous Transhepatic Biliary Drainage

Editor,

We report the case of a 51 year old man who developed the unusual complication of a bilious pleural effusion, or 'Cholethorax' following percutaneous transhepatic biliary drainage.

Case Report: A 51 year old man with locally advanced gastric adenocarcinoma presented with painless jaundice one year following the completion of palliative chemotherapy. Laboratory investigations revealed a bilirubin level of 299 $\mu\text{mol/L}$ with AST 117 U/L, ALT 134 U/L, GGT 2447 U/L, ALP 2159 U/L and an ultrasound of abdomen confirmed the presence of biliary obstruction. Percutaneous Transhepatic Cholangiography (PTC) was arranged as the presence of a gastric tumour precluded an approach using Endoscopic Retrograde Cholangiopancreatography (ERCP). The right hepatic duct was cannulated and contrast injected, demonstrating a complicated stricture of the common bile duct. An internal-external biliary drain was then inserted across this stricture to decompress the biliary tree and the position of the drain is shown in figure 1. Three days after the PTC our patient complained of severe right sided pleuritic chest pain and shortness of breath. A chest x-ray revealed right basal atelectasis and provisional diagnoses of a lower respiratory tract infection and possible pulmonary embolus were offered.

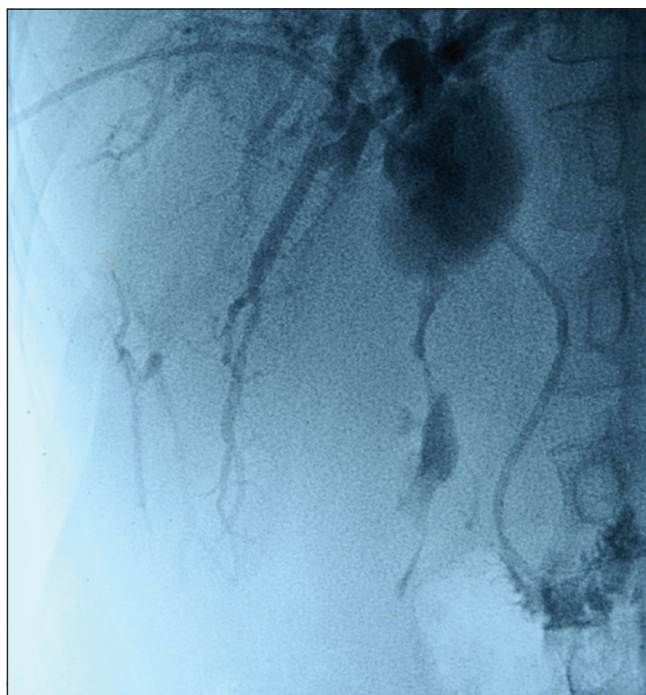

Fig 1.

Over the next 48 hours the patient became increasingly dyspnoeic, with signs of a right sided pleural effusion on

examination, and so a repeat chest radiograph was carried out (fig 2). The output of bile into the drainage bag had dramatically decreased and the bilirubin level had risen further to 387 $\mu\text{mol/L}$. A pleural aspiration was performed which yielded dark brown pleural aspirate with a bilirubin level of 766 $\mu\text{mol/L}$ (fig 3).

A diagnosis of a bilious pleural effusion (Cholethorax) as a complication of percutaneous transhepatic biliary drainage was made. The insertion of a 28F chest drain and rapid drainage of the bilious pleural fluid provided immediate relief of the shortness of breath and pleuritic chest pain. A further PTC was carried out urgently and three self-expanding metal stents were inserted across the complicated biliary stricture to provide adequate biliary drainage.

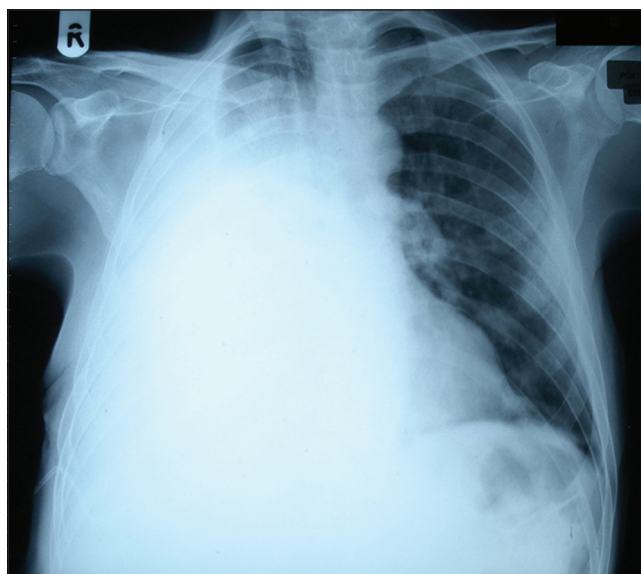


Fig 2.

Discussion: PTC and biliary drainage is used for the management of malignant biliary obstruction in cases where ERCP is inappropriate or has been unsuccessfully attempted. It involves the percutaneous cannulation of either hepatic duct followed by placement of a biliary drain to decompress the biliary tree and subsequent insertion of a stent during the initial procedure or a number of days later. During biliary cannulation it may be necessary to traverse the pleural cavity to gain access to either hepatic duct. An internal-external biliary drain is inserted consisting of a pig tail drain with a hole at the tip to allow the bile to exit into the duodenum and a number of side-holes along the distal length. These side-holes should be placed inside the common bile duct (Fig 1) to allow entry of the bile which then drains internally into the duodenum or externally into a drainage bag.

In our patient's case the drainage catheter became dislodged with the tip remaining in the right hepatic duct while the side-holes formed a direct communication with the pleural cavity. This occurred due to the trans-pleural approach taken during the PTC and as a result bile rapidly drained into the pleural cavity causing a 'Cholethorax'. Bile is an intense chemoirritant and so extensive pleural inflammation was established which also allowed the chest drain to be removed relatively quickly as it essentially caused a pleurodesis



Fig 3.

to occur. Bile also provides a good medium for bacterial growth and so infective sequelae often occur in the setting of a cholethorax.

Biliary pleural fistulas and the formation of bilious pleural effusions are known complications of hepatic trauma^{1,2}, parasitic liver disease³ and development of a subphrenic abscess in the setting of biliary obstruction. Iatrogenic causes include biliary stent migration⁴, radio-frequency ablation⁵ and following cholecystectomy⁶ and liver biopsy⁷ However, it is the increasing use of percutaneous biliary drainage which has led to the greatest number of cases.⁸⁻¹⁰ For a Cholethorax to arise disruption of the pleural space needs to have occurred and this may not necessarily be obvious during the procedure. Rapid thoracentesis, correction of the cause of the fistula, adequate analgesia and the treatment of infective sequelae are essential in the management of this group of patients.

The authors have no conflict of interest

Richard C Turkington,* *SpR, Oncology*

Julian J Leggett⁺, *Consultant in Respiratory Medicine*

Jane Hurwitz, *SpR Oncology*

Martin M Eatock, *Consultant in Medical Oncology*

Departments of Oncology and Respiratory Medicine⁺, Belfast City Hospital, 51 Lisburn Road, Belfast, BT9 7AB, United

Kingdom

* rcturkington@hotmail.com

REFERENCES:

1. Franklin DC, Mathai J. Biliary pleural fistula: a complication of hepatic trauma. *J Trauma* 1980;**20**(3):256-62.
2. Bamberger PK, Stojadinovic A, Shaked G, Golocovsky M. Biliary-pleural fistula presenting as a massive pleural effusion after thoracoabdominal penetrating trauma. *J Trauma* 1997;**43**(1):162-3.
3. Amir-Jahed AK, Sadrieh M, Farpour A, Azar H, Namdaran F. Thoracobilia: a surgical complication of hepatic echinococcosis and amebiasis. *Ann Thorac Surg* 1972;**14**(2):198-205.
4. Dasmahapatra HK, Pepper JR. Bronchopleurobiliary fistula. A complication of intrahepatic biliary stent migration. *Chest* 1988;**94**(4):874-5.
5. Liberale G, Delhaye M, Ansay J, Houben JJ, Coppens E, Gelin M, et al. Biliary pleural fistula as a complication of radiofrequency ablation for liver metastasis. *Acta Chir Belg* 2004;**104**(4):448-50.
6. Lehur PA, Guiberteau-Canfrere V, Bury A, Cloarec D, Le Borgne J. ["Cholethorax" revealing injury to the common bile duct after celioscopic cholecystectomy]. [French] *Ann Chir* 1992;**46**(5):450-2.
7. Pisani RJ, Zeller FA. Bilious pleural effusion following liver biopsy. *Chest* 1990;**98**(6):1535-7.
8. Armstrong CP, Taylor TV. Intrapleural leakage of bile complicating percutaneous transhepatic drainage of the obstructed biliary tree. *J R Coll Surg Edinb* 1982;**27**(5):308-9.
9. Herschman Z, Amin D, Lehrfield A. Bilious pleural effusion as a complication of attempted percutaneous biliary drainage. *Crit Care Med* 1991;**19**(1):128-9.
10. Strange C, Allen ML, Freedland PN, Cunningham J, Sahn SA. Biliopleural fistula as a complication of percutaneous biliary drainage: experimental evidence for pleural inflammation. *Am Rev Respir Dis* 1988;**137**(4):959-61.

Diffuse sclerosing variant of papillary thyroid carcinoma – a rare cause of goitre in a young patient

Editor,

Papillary thyroid carcinoma is the most common thyroid malignancy. We report a case of a rare variant - diffuse sclerosing papillary thyroid carcinoma (DSPC).

Case History: An 18 year old girl presented with a smooth symmetrical goitre. She was clinically euthyroid and had no palpable cervical lymph nodes. Thyroid function tests and anti-thyroid peroxidase level were normal. Ultrasound scan of thyroid showed marked nodular enlargement of the entire gland in keeping with a multinodular goitre. A hypoechoic 1cm nodule was identified at the right lobe which was found to be 'cold' on radio-isotope scanning. A fine needle aspiration of this 'cold' nodule was reported as papillary carcinoma.

She was booked for total thyroidectomy. At surgery she had an enlarged thyroid, with a gross appearance in keeping with a thyroiditis or lymphoma. Frozen section confirmed papillary carcinoma. The gland was hard and gritty. Several local lymph nodes were also excised. Post-operative recovery was uneventful.

Sectioning revealed a diffusely firm, white, gritty gland (fig 1). Histopathology showed this to be the rare diffuse sclerosing