

Tracheocutaneous Fistula Closure with Turnover Flap and Polydioxanone Plate

Justin R. Bryant, DO, MBA*
Thanapoom Boonipat, MD†
Kongkrit Chaiyasate, MD‡

Summary: An alternative surgical treatment is proposed for closure of tracheocutaneous fistulas. The authors present a new technique for reconstruction of persistent tracheocutaneous fistula resultant from temporary tracheostomy. The single-stage closure under local anesthesia involves a fistulous tract turnover flap with a perforated 0.15 mm polydioxanone plate between the flap and the subcutaneous closure. This article presents 3 cases of persistent tracheocutaneous fistula treated by this method. At follow-up examination after follow-up, no recurrent fistula formation had occurred, and no respiratory deformity was present. (*Plast Reconstr Surg Glob Open* 2017;5:e1515; doi: 10.1097/GOX.0000000000001515; Published online 10 October 2017.)

INTRODUCTION

Persistent tracheocutaneous fistula formation results from failure of spontaneous closure after temporary tracheostomy decannulation. The incidence of persistent tracheocutaneous fistula is known to increase to 70% for cannulation periods greater than 16 weeks.¹ Other known risk factors for persistent tracheocutaneous fistula formation include obesity, previous tracheostomy, previous neck irradiation, chronic aspiration/cough, local infections, and malnutrition.² Choices for treatment and closure of persistent tracheocutaneous fistula have included local debridement or chemical cauterization and closure by secondary intention, primary closure, fistulous tract excision and layered primary closure, local random flap closure, muscle flap closure, and free flaps. A depressed scar may form after closure by primary or secondary intent.³ One of the common complications of closure results from a collapse of the local flaps on inspiration causing a visible respiratory deformity.⁴

CASE REPORTS

Case 1

A 25-year-old male with a history of a gunshot wound to the mandible underwent attempted reconstruction with

*From the *Department of Plastic Surgery, Beaumont–Farmington Hills Plastic Surgery Fellowship, Farmington Hills, Mich.; †Department of Plastic Surgery, Mayo Clinic Plastic and Reconstructive Surgery, Rochester, Minn.; and ‡Department of Plastic Surgery, Beaumont – Royal Oak Plastic and Reconstructive Surgery, Royal Oak, Mich. Received for publication March 30, 2017; accepted August 11, 2017.*

Copyright © 2017 The Authors. Published by Wolters Kluwer Health, Inc. on behalf of The American Society of Plastic Surgeons. This is an open-access article distributed under the terms of the Creative Commons Attribution-Non Commercial-No Derivatives License 4.0 (CCBY-NC-ND), where it is permissible to download and share the work provided it is properly cited. The work cannot be changed in any way or used commercially without permission from the journal. DOI: 10.1097/GOX.0000000000001515

a nonvascularized bone graft and external fixation along with tracheostomy at a referring facility. He underwent staged mandibular reconstruction with a fibula osteocutaneous free flap 7 months after his initial injury. Reconstruction was completed 4 months after consultation and his tracheostomy was decannulated 1 month later. Persistent tracheocutaneous fistula 2 months after decannulation led to planned closure with polydioxanone (PDS) plate placement (see figure, Supplemental Digital Content 1, which displays a persistent tracheocutaneous fistula in patient 1, <http://links.lww.com/PRSGO/A555>). At follow-up 6 months after tracheocutaneous fistula repair, his tracheostomy site was well healed (see figure, Supplemental Digital Content 2, which displays patient 1 at 6-month follow-up after tracheocutaneous fistula closure with PDS plate placement, <http://links.lww.com/PRSGO/A556>). A computed tomography scan performed at 6-month follow-up also demonstrated maintenance of the closure with no further fistula formation (see figure, Supplemental Digital Content 3, which displays a computed tomography scan of patient 1 6 months after tracheocutaneous fistula closure with PDS plate placement, <http://links.lww.com/PRSGO/A557>).

Case 2

A 36-year-old male with a recurrent mass of the C2–C3 vertebral bodies underwent vertebral body resection via a trans-oral approach necessitating tracheostomy. He had been diagnosed with a malignancy of the cervical spine and treated with resection, radiation therapy, and chemo-

Disclosure: The authors have no financial interest to declare in relation to the content of this article. The Article Processing Charge was paid for by the authors.

Supplemental digital content is available for this article. Clickable URL citations appear in the text.

therapy 7 years prior. Postoperative complications including palatal fistula and exposed hardware necessitated a radial forearm free flap for coverage. His tracheostomy was decannulated 1 month after reconstruction was completed. Four months after decannulation, he presented with a persistent tracheocutaneous fistula and underwent closure with PDS plate placement 5 months later (see figure, Supplemental Digital Content 4, which displays a persistent tracheocutaneous fistula in patient 2, <http://links.lww.com/PRSGO/A558>). At follow-up 6 months after closure, his tracheocutaneous fistula was well healed (see figure, Supplemental Digital Content 5, which displays patient 2 at 6-month follow-up after tracheocutaneous fistula closure with PDS plate placement, <http://links.lww.com/PRSGO/A559>).

Case 3

A 53-year-old male with a 5-year history of osteoradionecrosis and chronic wound of the mandible presented in consultation for mandibular reconstruction. He had previously undergone adjuvant radiation therapy for head and neck cancer. After consultation, an elective tracheostomy was performed at the time of tissue expander placement for planned mandible resection with fibula free flap and supraclavicular flap. One month after expansion, a fibula osteocutaneous free flap was performed for mandible reconstruction. He completed his reconstruction 6 months later, and his tracheostomy was decannulated. Three months after decannulation, he presented with a persistent tracheocutaneous fistula and underwent closure with PDS plate placement (see figure, Supplemental Digital Content 6, which displays a persistent tracheocutaneous fistula in patient 3, <http://links.lww.com/PRSGO/A560>). At follow-up 7 months after closure, his tracheocutaneous fistula was well healed (see figure, Supplemental Digital Content 7, which displays patient 3 at 6-month follow-up after tracheocutaneous fistula closure with PDS plate placement, <http://links.lww.com/PRSGO/A561>).

Operative Procedure

Tracheocutaneous fistula closure with PDS plate placement was undertaken as a single-stage procedure performed under local anesthesia in the operating room. The average fistula size was 3×3 cm. Prepping and draping were done in the standard fashion. Local anesthetic (1% lidocaine with 1:100,000 epinephrine) was infiltrated around the area of the tracheocutaneous fistula. An incision was made circumferentially to separate the fistulous tract from the skin. The fistulous tract was dissected and the surrounding subcutaneous tissue undermined. The fistulous tract was turned inward upon itself as a turnover flap (Figs. 1, 2) to form the new lining of the anterior trachea wall. Absorbable monofilament sutures were utilized to secure this flap and thus close the fistulous tract. Confirmation of the absence of an air leak was performed with a small volume of irrigation solution. A thin fenestrated Ethicon™ Polydioxanone PDS™ Flexible Plate (Mentor Worldwide LLC, Irving, Tex.) was trimmed to fit snugly in the defect between the fistula turnover flap and subcutaneous tissue (Fig. 3). This was performed in an effort to increase




Fig. 1. Diagram of fistulous tract turnover flap—axial view.

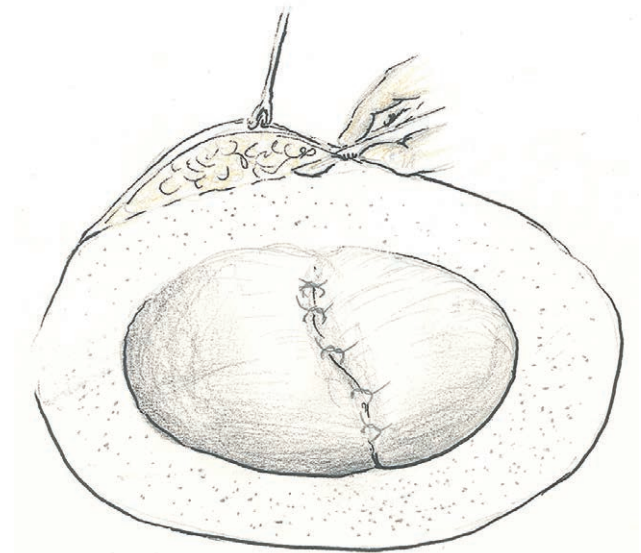


Fig. 2. Diagram of fistulous tract turnover flap—anterior view.

the strength of the anterior trachea wall, preventing retraction of the soft tissue on inspiration. Superior and inferior fasciocutaneous flaps were then fashioned of the external skin and platysma muscle and closure obtained with a combination of buried absorbable monofilament and nonabsorbable external sutures (Fig. 4). No drains were utilized.

DISCUSSION

No consensus exists on the treatment of tracheocutaneous fistula. Many methods of repair have been described varying from closure by secondary intention, primary closure, layered primary closure, local tissue and muscle flaps, tissue rearrangement, and free flaps. Rigid reinforcement

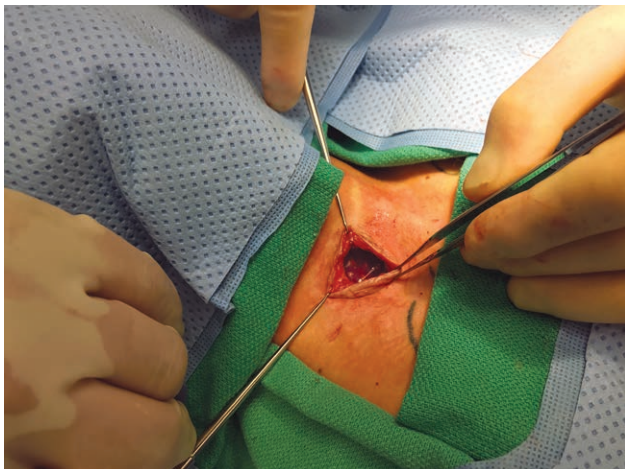


Fig. 3. Intraoperative polydioxanone plate in position.




Fig. 4. Diagram of fistulous tract turnover flap, polydioxanone plate in position, and fasciocutaneous flap closure.

of free flaps for tracheal defect reconstruction has been described using various prosthetic materials.⁵ Reconstruction with rib⁶ and conchal⁷ cartilage grafts have been described in larger tracheal defects. The use of a fistulous tract turnover flap has been reported as advantageous for its ability to provide immediate epithelial resurfacing of the anterior tracheal defect.⁴ Other methods of providing tracheal lining with grafts have been described but do not have the advantage of being a single-stage procedure and require a separate donor site.

PDS is a synthetic bioabsorbable polymer used in the production of suture, orthopedic implants, and implantable stents. This compound undergoes hydrolysis, retaining 70% tensile strength at 2 weeks and 25% tensile strength at 6 weeks.^{8–10} Complete biologic resorption occurs by 6 months, and PDS is known to illicit only a minimal local foreign body reaction.^{8–10} Ethicon™ Polydioxanone PDS™ Flexible Plate (Mentor Worldwide LLC, Irving, Tex.) is available as a 50×40 mm plate in 3 thicknesses: 0.15 mm with perforations, 0.25 mm, and 0.5 mm. The use of PDS plate in repair of nasal septal perforation¹¹ and to

enhance stability in nasal reconstruction has been well documented in the literature. In a study of the mechanical properties of cartilage-PDS plate composite grafts in septoplasty/rhinoplasty by Kim et al.,¹² the 0.15 mm PDS plate was preferred due to its optimal effect on flexural stiffness and the presence of perforations, which allow blood flow across the plate. We chose the 0.15 mm PDS plate due to the presence of perforations allowing better tissue incorporation.

In tracheocutaneous fistulas, the fistulous tract does not necessarily need to be excised; it may be incorporated into the repair. In this article, we describe a technique utilizing PDS plate reinforcement of a tracheocutaneous fistula turnover flap performed as a single-stage procedure with local anesthesia. In our case series of 3 patients, the duration of tracheostomy cannulation ranged from 7–12 months, placing all 3 patients at a higher likelihood of tracheocutaneous fistula.¹ The interval between decannulation and tracheocutaneous fistula repair ranged from 2–9 months. At the 6 month follow-up, none of our patients had recurrence of tracheocutaneous fistula nor respiratory deformity on inspiration or expiration. The development of respiratory deformity with skin flap collapse has been described,⁴ and our use of fistula turnover flap with PDS plate appears to eliminate this deformity in a 1-stage procedure under local anesthesia. This article represents only a small number of patients in a case series, and further follow-up and examination of future patients is necessary.

Justin R. Bryant, DO, MBA, CWSP

Beaumont – Farmington Hills Plastic and
Reconstructive Surgery Fellowship
3110 Telegraph Rd #280
Bingham Farms, MI 48025
E-mail: justinRbryant@gmail.com

PATIENT CONSENT

The patients provided written consent for the use of their images.

REFERENCES

1. Kulber H, Passy V. Tracheostomy closure and scar revisions. *Arch Otolaryngol.* 1972;96:22–26.
2. DE Virgilio A, Simonelli M, Greco A, et al. Tracheocutaneous fistula in patients undergoing supracricoid partial laryngectomy: the role of chronic aspiration. *Acta Otorhinolaryngol Ital.* 2015;35:9–14.
3. Hernot S, Wadhwa R, Kaintura M, et al. Tracheocutaneous fistula closure: comparison of rhomboid flap repair with Z plasty repair in a case series of 40 patients. *Aesthetic Plast Surg.* 2016;40:908–913.
4. Eliashar R, Sichel JY, Eliachar I. A new surgical technique for primary closure of long-term tracheostomy. *Otolaryngol Head Neck Surg.* 2005;132:115–118.
5. Yu P, Clayman GL, Walsh GL. Long-term outcomes of microsurgical reconstruction for large tracheal defects. *Cancer.* 2011;117:802–808.
6. Caronia FP, Fiorelli A, Santini M, et al. A persistent tracheocutaneous fistula closed with two hinged skin flaps and rib cartilage interpositional grafting. *Gen Thorac Cardiovasc Surg.* 2016;64:625–628.

7. Yawn RJ, Yawn JR, Gelbard A, et al. Tracheocutaneous fistula repair with autologous auricular cartilage cap graft. *Laryngoscope*. 2016;126:2085–2088.
8. Caughlin BP, Been MJ, Rashan AR, et al. The effect of polydioxanone absorbable plates in septorhinoplasty for stabilizing caudal septal extension grafts. *JAMA Facial Plast Surg*. 2015;17:120–125.
9. Ethicon PDS Flexible Plate [package insert]. Irving, TX: Mentor Worldwide LLC.; 2010.
10. Suuronen R, Kallela I, Lindqvist C. Bioabsorbable plates and screws: current state of the art in facial fracture repair. *J Craniomaxillofac Trauma*. 2000;6:19–27; discussion 28.
11. Hughes J, Paun S. Repair of nasal septal perforations using conjugate polydioxanone plate and autologous cartilage interpositional grafts. *Otolaryngol Head Neck Surg*. 2012;146:323–325.
12. Kim JH, Wong B. Analysis of cartilage-polydioxanone foil composite grafts. *Facial Plast Surg*. 2013;29:502–505.