

## Case Report

## Three distal anterior cerebral artery aneurysms in the same branch associated with five additional intracranial aneurysms

Danil A. Kozyrev<sup>1,2</sup>, Behnam Rezai Jahromi<sup>1</sup>, Peeraphong Thiarawat<sup>1</sup>, Joham Choque-Velasquez<sup>1</sup>, Christopher Ludtka<sup>1</sup>, Felix Goehre<sup>1</sup>, Juha Hernesniemi<sup>1</sup>

<sup>1</sup>Department of Neurosurgery, Helsinki University Central Hospital, Helsinki, Finland, <sup>2</sup>Department of Pediatric Neurology and Neurosurgery, North-Western State Medical University, Saint-Petersburg, Russia

E-mail: \*Danil A. Kozyrev - [danilkozyrev@gmail.com](mailto:danilkozyrev@gmail.com); Behnam Rezai Jahromi - [behnam.rezai@hus.fi](mailto:behnam.rezai@hus.fi); Peeraphong Thiarawat - [peeraphongt@gmail.com](mailto:peeraphongt@gmail.com); Joham Choque-Velasquez - [johchove@hotmail.com](mailto:johchove@hotmail.com); Christopher Ludtka - [chrmludt@vols.utk.edu](mailto:chrmludt@vols.utk.edu); Felix Goehre - [fgoehre@gmail.com](mailto:fgoehre@gmail.com); Juha Hernesniemi - [juha.hernesniemi@hus.fi](mailto:juha.hernesniemi@hus.fi)

\*Corresponding author

Received: 09 October 16 Accepted: 20 January 17 Published: 26 April 17

### Abstract

**Background:** Multiple distal anterior cerebral artery (DACA) aneurysms appear as rare findings. Simultaneous treatment of such lesions can be particularly challenging. A report of three aneurysms on the same parent artery has not been reported before. We report a case of three DACA aneurysms treated within one microsurgical operation in a patient with eight aneurysms.

**Case Description:** A 62-year-old woman incidentally presented with multiple various size saccular aneurysms, including tree on the left DACA. One of the DACA aneurysm was located on the A3 segment, and the other two were on the A4 and A5 segments. Ligation of all three of these aneurysms was planned in one operation. A standard anterior interhemispheric approach was utilized. Three aneurysms were successfully clipped using four clips. Intraoperative angiography confirmed aneurysm occlusion with parent artery patency preservation. The patient showed no new postoperative neurological deficit.

**Conclusion:** Clipping multiple DACA aneurysms within a single microneurosurgical operation is a feasible treatment option. Meticulous analysis of preoperative imaging features is crucial for selecting the best, patient-specific treatment strategy.

**Key Words:** Clipping, distal anterior cerebral artery, microneurosurgery, multiple aneurysms

#### Video Available on:

[www.surgicalneurologyint.com](http://www.surgicalneurologyint.com)

#### Access this article online

##### Website:

[www.surgicalneurologyint.com](http://www.surgicalneurologyint.com)

##### DOI:

10.4103/sni.sni\_394\_16

#### Quick Response Code:



## BACKGROUND

Most of the aneurysms occurring in the distal area of the anterior cerebral artery are described as “pericallosal.” Aneurysms that arise distal to the anterior communicating artery region are called distal anterior cerebral artery (DACA) aneurysms.<sup>[15]</sup> Thereby, DACA aneurysms include pericallosal aneurysms. The incidence of DACA aneurysms is low comprising approximately 2–9% of all intracranial aneurysms.<sup>[3,7,10,15,16]</sup>

This is an open access article distributed under the terms of the Creative Commons Attribution-NonCommercial-ShareAlike 3.0 License, which allows others to remix, tweak, and build upon the work non-commercially, as long as the author is credited and the new creations are licensed under the identical terms.

**For reprints contact:** [reprints@medknow.com](mailto:reprints@medknow.com)

**How to cite this article:** Kozyrev DA, Jahromi BR, Thiarawat P, Choque-Velasquez J, Ludtka C, Goehre F, et al. Three distal anterior cerebral artery aneurysms in the same branch associated with five additional intracranial aneurysms. *Surg Neurol Int* 2017;8:62.

<http://surgicalneurologyint.com/Three-distal-anterior-cerebral-artery-aneurysms-in-the-same-branch-associated-with-five-additional-intracranial-aneurysms/>

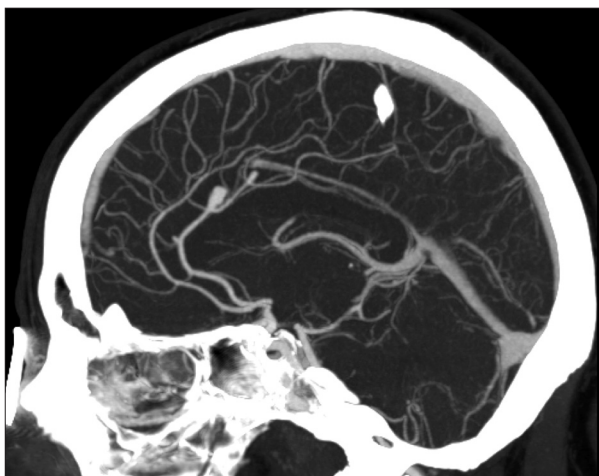
Multiple DACA aneurysms are relatively rare. Most of the reported cases show aneurysms arising from different arteries of DACA area. In the largest published series from our institution, 37 of the 427 patients (9%) had two or more aneurysms in this area.<sup>[7]</sup> According to our database with more than 600 DACA aneurysms, this is a unique case with three aneurysms on one parent artery. We report a case of a patient with multiple intracranial aneurysms including three on the left DACA on the A3, A4, and A5 segments. All pericallosal aneurysms were treated during one operation.

## CASE DESCRIPTION

### History

A 62-year-old woman developed tonsil changes. For malignancy screening, magnetic resonance imaging (MRI) was scheduled. MRI revealed a left middle cerebral artery (MCA) bifurcation aneurysm. Further, computed tomography angiography (CTA) showed eight intracranial aneurysms on the left side – MCA bifurcation, M2, A3, A4, and A5 segments; on right side – MCA and internal carotid artery bifurcations, and distal posterior cerebral artery aneurysms. The patient had multiple risk factors for intracranial aneurysm formation (family history of cerebral aneurysms, female gender, current smoking status). The decision of active multistage treatment was chosen. In the first stage, the left MCA bifurcation and left M2 aneurysms were successfully clipped. The postoperative period was uneventful and the patient was discharged on 4<sup>th</sup> postoperative day.

One month later, the patient was admitted again for clipping of the DACA aneurysms. Three DACA aneurysms were located on a left pericallosal artery [Figure 1 and Video 1]. All of them arose from the bifurcation sides. The smallest aneurysm was at the A3 segment (saccular, neck 2 mm, width 2 mm, length



**Figure 1: Preoperative image: sagittal computed tomography (CT) shows three saccular aneurysms of the left pericallosal artery**

2 mm), and the biggest was at the A4 segment (saccular, neck 3 mm, width 5 mm, length 8 mm). The most distal was the aneurysm at the A5 segment (saccular, neck 2 mm, width 3 mm, length 4 mm).

### Positioning and approach

The patient was placed in the supine position. The head was in the neutral position and slightly elevated above the heart level. Then, we performed a standard anterior interhemispheric approach with a one-layer flap.

### Intracranial dissection

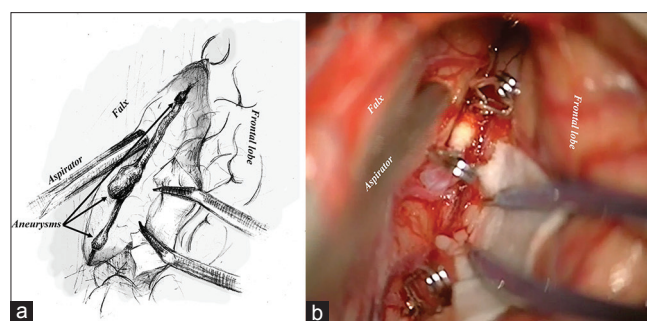
After opening the dura mater in a semicircular fashion around the superior sagittal sinus, dissection of the interhemispheric fissure was carefully performed. Bipolar with aspirator are very effective for dynamic retraction in this stage. All DACA aneurysms were explored under direct visual control. The key issue of navigating within the interhemispheric fissure is reaching the corpus callosum. Transverse fibers and white color are distinctive features of the corpus callosum that differentiate it from the cingulate gyrus.<sup>[6]</sup>

### Clip ligation

First, in the anterior part of the operative field, A3 aneurysm was clipped with one straight clip and the dome was coagulated. Following this, dissection around the A4 aneurysms was done. After utilizing proximal and distal temporary clipping (temporary trapping of A4 segment), we occluded the aneurysm with one curved clip. However, the wall of the aneurysm had sclerotic plaque content, and hence, clipping occlusion of the neck with a single clip proved ineffective and another curved clip was applied. Time of temporary artery occlusion was 110 seconds. The A5 aneurysm was dissected next. After verifying that no perforators were inside the clip, occlusion of the aneurysm with one straight clip and coagulation of the dome were performed.

### Artery patency control

Intraoperative indocyanine green proved patency preservation of the parent artery and surrounding branches. Three DACA aneurysms were completely excluded from the circulation [Figure 2a and b].



**Figure 2: Intraoperative images: illustration (a) shows three aneurysms of one parent artery and photography (b) shows aneurysms occlusion using four clips**

## Postoperative period

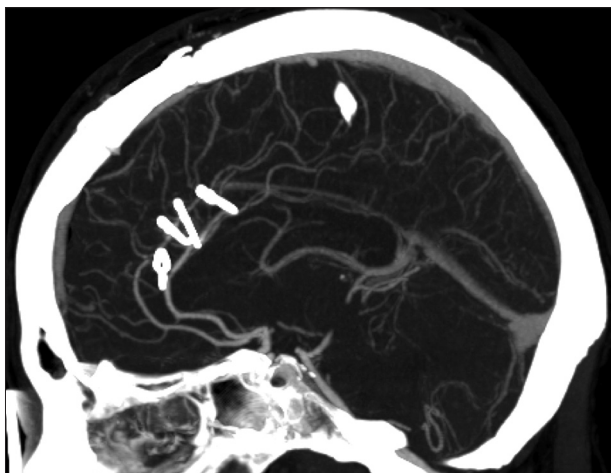
The patient awoke without any new neurological deficit. The postoperative period was smooth and uneventful. Control CTA showed occlusion of the three DACA aneurysms without any neck remnants and preserved flow in parent artery and its branches [Figure 3]. The patient was discharged on the 4<sup>th</sup> postoperative day.

Four months after the described operation, the patient underwent uneventful clipping of the right MCA and right ICA bifurcations aneurysms; 3 months later, clipping of the distal PCA aneurysm was done. One year after the previous operation, the patient showed a lack of any neurological deficit and demonstrated full daily activities (modified Rankin Scale 0).

## DISCUSSION

Here, we describe a rare case of multiple aneurysms arising from different parts of the left distal anterior cerebral artery. Segments of the DACA are classified considering their relationship with the genu of the corpus callosum; A2 is the most proximal segment and A5 the most distal. The border between the A2 and A3 segments is the region connecting the rostrum with the genu of the corpus callosum. A3 and A4 segments are separated by the region connecting the genu with the body of the corpus callosum. A4 and A5 are divided by a virtual plane drawn through the coronary suture.<sup>[8]</sup>

One of the features of DACA aneurysms is their coexistence with aneurysms at other locations.<sup>[5]</sup> Incidence of multiple aneurysms in this group is high, consisting of up to 50% of the cases.<sup>[8]</sup> However, the occurrence of multiple aneurysms within the same region is relatively rare. The vast majority of published reports describe mirror type lesions originating from different pericallosal arteries.<sup>[2,4,11,13]</sup> One report showed coexistence of four DACA aneurysms with frontal



**Figure 3: Postoperative image: sagittal CT scan shows occlusion of three aneurysms and patency preservation of the parent vessel**

arteriovenous malformation. Two aneurysms arose from the A2 segment of the right pericallosal artery, one from the right orbitofrontal artery, and another from the feeding vessel (frontopolar artery) of the malformation. All lesions were eliminated within one microsurgical operation.<sup>[14]</sup>

Several physical factors related to the hemodynamic microenvironment have been suggested as important causes that can lead to the occurrence of aneurysm. Alfano *et al.* showed that formation of intracranial aneurysms more often occurs at bifurcation sites.<sup>[1]</sup>

The diameter of the DACA at the A4 level is approximately 1 mm, which represents challenges for many endovascular microcatheters for the treatment of distally located aneurysms.<sup>[12]</sup> In addition, aneurysms often occur at places of major branches.<sup>[9]</sup> Therefore, unsuitable anatomy limits the application of endovascular technique in some cases. Despite significant improvements in endovascular techniques, open microsurgery remains one of the best options for DACA aneurysms, especially in the case of multiple aneurysms. In addition, common features of DACA aneurysms such as a broad base and sclerotic plaque content add to the difficulty of surgery. However, open microsurgical treatment in this region is performed through a deep, narrow route, and requires microsurgical experience. Neuronavigation can be a useful tool for locating an aneurysm, especially a distal one.

## CONCLUSION

Clipping multiple DACA aneurysms within a single microneurosurgical operation is a feasible treatment option. Meticulous analysis of preoperative imaging features is crucial for selecting the best, patient-specific treatment strategy.

## Acknowledgement

We would like to thank Yaroslava A. Kozyreva for the drawing in this article

## Financial support and sponsorship

Nil.

## Conflicts of interest

There are no conflicts of interest.

## REFERENCES

1. Alfano JM, Kolega J, Natarajan SK, Xiang J, Paluch RA, Levy EI, *et al.* Intracranial aneurysms occur more frequently at bifurcation sites that typically experience higher hemodynamic stresses. *Neurosurgery* 2013;73:497-505.
2. Choi CY, Han SR, Yee GT, Lee CH. Kissing aneurysms of the distal anterior cerebral artery. *J Clin Neurosci* 2011;18:260-2.
3. de Sousa AA, Dantas FL, de Cardoso GT, Costa BS. Distal anterior cerebral artery aneurysms. *Surg Neurol* 1999;52:128-35.
4. Enesi E, Rroji A, Demneri M, Vreto G, Petrela M. Mirror image distal anterior cerebral artery aneurysms treated with coil embolization: A report of two cases and literature review. *Interv Neuroradiol* 2013;19:49-55.

5. Hernesniemi J, Tapaninaho A, Vapalahti M, Niskanen M, Kari A, Luukkonen M. Saccular aneurysms of the distal anterior cerebral artery and its branches. *Neurosurgery* 1992;31:994-8.
6. Lehecka M, Laakso A, Hernesniemi J. Helsinki microneurosurgery basics and tricks. Germany: Aesculap AG; 2011.
7. Lehecka M, Lehto H, Niemela M, Juvela S, Dashti R, Koivisto T, et al. Distal anterior cerebral artery aneurysms: Treatment and outcome analysis of 501 patients. *Neurosurgery* 2008;62:590-601.
8. Lehecka M, Porras M, Dashti R, Niemela M, Hernesniemi JA. Anatomic features of distal anterior cerebral artery aneurysms: A detailed angiographic analysis of 101 patients. *Neurosurgery* 2008;63:219-28.
9. Lin N, Lanzino G, Lopes DK, Arthur AS, Ogilvy CS, Ecker RD, et al. Treatment of Distal Anterior Circulation Aneurysms With the Pipeline Embolization Device: A US Multicenter Experience. *Neurosurgery* 2016;79:14-22.
10. Menovsky T, van Rooij WJ, Sluzewski M, Wijinalda D. Coiling of ruptured pericallosal artery aneurysms. *Neurosurgery* 2002;50:11-4.
11. Mori T, Fujimoto M, Shimada K, Shin H, Sakakibara T, Yamaki T. Kissing aneurysms of distal anterior cerebral arteries demonstrated by magnetic resonance angiography. *Surg Neurol* 1995;43:497-9.
12. Navarro R, Chao K, Steinberg GK. Microsurgical management of distal anterior cerebral artery aneurysms: From basic to complex, a video review of four cases. *Acta Neurochir* 2013;155:2115-9.
13. Sousa J, Iyer V, Roberts G. 'Mirror image' distal anterior cerebral artery aneurysms. A case report of two patients with review of literature. *Acta Neurochir* 2002;144:933-5.
14. Xue MH, Chun HW, Li J, Song YL. Multiple aneurysms of distal anterior cerebral artery associated with a cerebral arteriovenous malformation. *Neurol India* 2010;58:968-70.
15. Yasargil MG, Carter LP. Saccular aneurysms of the distal anterior cerebral artery. *J Neurosurg* 1974;40:218-23.
16. Yoshimoto T, Uchida K, Suzuki J. Surgical treatment of distal anterior cerebral artery aneurysms. *J Neurosurg* 1979;50:40-4.