



Case Report

Oro-mandibular dystonia in pediatric moyamoya disease: Two cases report

Yuichiro Koga, Daina Kashiwazaki, Emiko Hori, Naoki Akioka, Satoshi Kuroda

Department of Neurosurgery, University of Toyama, Toyama, Japan.

E-mail: Yuichiro Koga - uichiro.koga@gmail.com; Daina Kashiwazaki - dkashiwa@med.u-toyama.ac.jp; Emiko Hori - emihori@med.u-toyama.ac.jp; Naoki Akioka - akioka@med.u-toyama.ac.jp; *Satoshi Kuroda - skuroda@med.u-toyama.ac.jp



*Corresponding author:

Satoshi Kuroda,
Department of Neurosurgery,
University of Toyama, Toyama,
Japan.

skuroda@med.u-toyama.ac.jp

Received : 01 July 2021
Accepted : 19 August 2021
Published : 06 September 2021

DOI
10.25259/SNI_661_2021

Quick Response Code:



ABSTRACT

Background: In this report, we describe rare two pediatric cases that developed oro-mandibular dystonia due to moyamoya disease.

Case Description: A 7-year-old boy presented with oro-mandibular dystonia and transient weakness of the left extremities, and was diagnosed as moyamoya disease. Another 7-year-old boy developed oro-mandibular dystonia alone and was diagnosed as moyamoya disease. In both, cerebral blood flow (CBF) was markedly decreased in the involved hemispheres, including the basal ganglia and cerebral cortex. They successfully underwent combined bypass surgery and experienced no further attacks of oromandibular dystonia during follow-up periods. CBF almost normalized through surgical collaterals through direct and indirect bypass.

Conclusion: When treating patients with oro-mandibular dystonia, moyamoya disease should be listed as one of the differential diseases. The underlying mechanism of oro-mandibular dystonia in moyamoya disease is still unclear, but persistent cerebral ischemia in the basal ganglia and/or parietal lobe may play a key role to induce this rare symptom.

Keywords: Bypass surgery, Cerebral blood flow, Involuntary movement, Moyamoya disease, Oromandibular dystonia

INTRODUCTION

Moyamoya disease causes various presentations, but most of the pediatric patients develop transient ischemic attack (TIA) and ischemic stroke.^[7,18] Involuntary movements are the most uncommon among all which only 1–6% of patients develop in their initial presentation or clinical course. Symptoms usually include chorea, dystonia, and/or dyskinesia, although the underlying mechanisms are not fully understood.^[1,3,6,11,16]

This report first describes two pediatric cases of moyamoya disease that manifested involuntary movements in the oro-mandibular area.

CASE DESCRIPTION

Case 1

A 7-year-old boy suddenly experienced transient loss of the ability to close his mouth while he was eating. This symptom of jaw opening lasted for about 5 min, followed by transient weakness of the

This is an open-access article distributed under the terms of the Creative Commons Attribution-Non Commercial-Share Alike 4.0 License, which allows others to remix, tweak, and build upon the work non-commercially, as long as the author is credited and the new creations are licensed under the identical terms.

©2021 Published by Scientific Scholar on behalf of Surgical Neurology International

left extremities for a few minutes. Neurological examination on admission revealed no abnormalities. No parenchymal lesions were observed on FLAIR image. MRA and cerebral angiography showed the narrowing of the carotid forks and their branches on both sides. SPECT demonstrated a marked decrease in cerebral blood flow (CBF), including the striatum and cortex, in the right cerebral hemisphere [Figure 1]. He was diagnosed as moyamoya disease and successfully underwent superficial temporal artery to middle cerebral artery (STA-MCA) anastomosis combined with indirect bypass, encephalo-duro-myo-arterio-pericranial synangiosis (EDMAPS) onto the right hemisphere.^[8,9] Follow-up cerebral angiography taken 4 months after surgery revealed well-developed surgical collaterals through both direct and indirect bypass. CBF improved markedly after surgery [Figure 1]. During 1 year after surgery, he has experienced no further attack, including involuntary movements and TIA.

Case 2

A 7-year-old boy suddenly experienced involuntary movements of the jaw and tongue. Characteristically, dystonic and dyskinetic motions were seen, including jaw opening and the jaw and throat making clicking sounds. Neurological examination on admission showed no abnormalities. No parenchymal lesions were observed on FLAIR image. MRA and cerebral angiography demonstrated severe stenosis of the carotid forks on both sides. SPECT showed a decreased in CBF in the left hemisphere, including the striatum and cortex [Figure 2]. He was diagnosed as moyamoya disease and successfully underwent STA-MCA anastomosis and EDMAPS on the left side and then on the right side 3 weeks later. Follow-up cerebral angiography taken 6 months after surgery revealed well-developed surgical collaterals through both direct and indirect bypass. CBF significantly improved after surgery [Figure 2]. During these 7 years after surgery, he has experienced no further attack of involuntary movement.

DISCUSSION

In the present cases, unique movement disorder around their jaw is considered consistent to oromandibular dystonia. Dystonia is defined as involuntary lasting severe muscle contractions and is defined as oromandibular dystonia when the oral cavity such as the mouth, face, and jaw is involved.^[15]

The mechanisms of involuntary movements in moyamoya disease are still unclear, but it is most likely that the basal ganglia may be largely involved in the occurrence, where the dilated moyamoya vessels are often found.^[1] Thus, moyamoya disease may lead to profound ischemia in the basal ganglia, causing involuntary movements.^[3,14] The function of basal ganglia-thalamocortical circuit may be disturbed and extrapyramidal symptoms such as chorea, dyskinesia, and

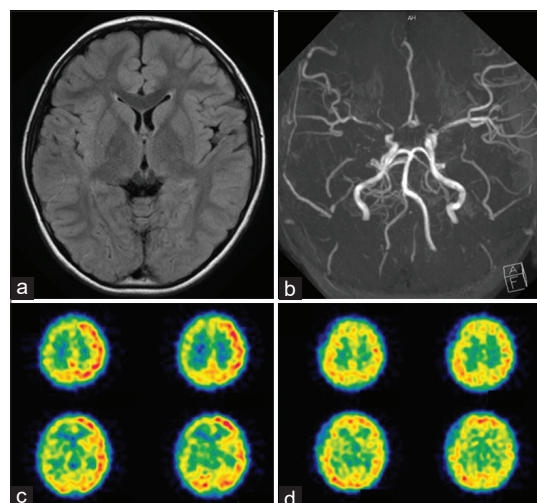


Figure 1: Radiological findings of a 7-year-old boy who developed oro-mandibular dystonia and transient ischemic attack (Case 1). (a) No parenchymal lesions were observed on FLAIR image (b) Magnetic resonance angiography showed the narrowing of the carotid forks and their branches on both sides. Moyamoya vessels were more apparent in the right side. (c) ¹²³I-IMP SPECT demonstrated a marked decrease in cerebral blood flow (CBF) on the right side, including the striatum and cortex. (d) On follow-up SPECT at 4 months after superficial temporal artery to middle cerebral artery anastomosis and encephalo-duro-myo-arterio-pericranial synang onto the right side, CBF markedly improved on the operated hemisphere.

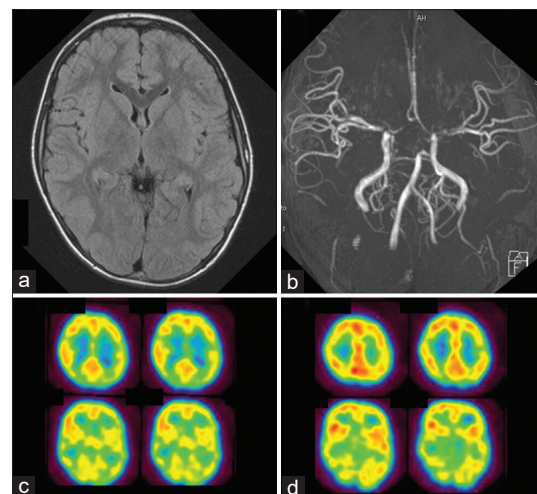


Figure 2: Radiological findings of a 7-year-old boy who developed oro-mandibular dystonia (Case 2). (a) No parenchymal lesions were observed on FLAIR image (b) Magnetic resonance angiography showed the stenosis of the carotid forks and their branches on both sides. (c) ¹²³I-IMP SPECT demonstrated a significant decrease in cerebral blood flow (CBF) on the left side, including the striatum and cortex. (d) On follow-up SPECT at 6 months after superficial temporal artery to middle cerebral artery anastomosis and encephalo-duro-myo-arterio-pericranial synang on both sides, CBF markedly improved on the operated hemispheres.

dyskinesia may develop.^[12] Furthermore, blood flow studies identified CBF reduction or impaired vascular reserve in the basal ganglia.^[3] In fact, in the two cases presented here, CBF was decreased in the basal ganglia as well as in the cerebral cortex, and involuntary movements disappeared and CBF improved after surgical revascularization.

Second, the hypertrophied moyamoya vessels in the basal ganglia may physically compress the neurons and/or the extrapyramidal tract in the basal ganglia, causing involuntary movements.^[16] However, as observed in the present cases, most of the moyamoya patients with involuntary movements had the dilated moyamoya vessels on both sides, but their involuntary movements occurred only on one side. These facts strongly suggest that many other factors may contribute to the occurrence of involuntary movements.

Finally, involuntary movement may develop through hypermetabolic state in the striatum due to the dilated moyamoya vessels. Thus, glucose metabolism was reported to increase in the striatum responsible for unilateral chorea in two pediatric patients who developed involuntary movements “after” bypass surgery, although they did not experience it before surgery.^[17] They speculated that impaired vascular autoregulation in the basal ganglia could induce this unique phenomenon. Very specific conditions such as Group A streptococcal infections, hyperthyroidism, and hyperglycemia can elevate glucose metabolism in the striatum and induce involuntary movements such as chorea.^[17]

Alternatively, recent studies have shown that dystonia is not only caused by an abnormality of the basal ganglia alone, but also by a functional impairment of other brain regions such as the cerebellum, thalamus, midbrain/brainstem, and cerebral cortex. For example, some investigators have largely focused on the cerebello-thalamo-cortical network.^[5,10] In fact, oro-mandibular dystonia can occur in a patient with cerebellar ischemic stroke.^[2] The speculation has been supported by recent neuroimaging studies, which show functional abnormalities in the cerebellum, but not in the basal ganglia, in a significant number of patients with dystonia.^[13] Especially, the parietal lobe has been the focus of attention as a region responsible for dystonia. A variety of lesions in the parietal lobe are known to induce dystonia.^[4] In Case 1, furthermore, a jaw opening attack was followed by a hemiparesis attack, strongly suggesting that both attacks were caused through cerebral ischemia in the area close to each other, i.e., parietal lobe and primary motor cortex. Previous studies have shown that the failure to process sensory information such as body positions in the parietal lobe may lead to the occurrence of dystonia.^[13] In fact, in the two cases presented here, SPECT before surgery showed extensive cerebral ischemia in the cerebral cortex including the parietal lobe. After successful

surgery, CBF markedly improved and recovered to the normal level.

CONCLUSION

We report rare two cases that developed oro-mandibular dystonia due to moyamoya disease. The underlying mechanism of oromandibular dystonia in moyamoya disease is still unclear, but persistent cerebral ischemia in the basal ganglia and/or parietal lobe may play a key role in this rare symptom.

Declaration of patient consent

Institutional Review Board (IRB) permission obtained for the study.

Financial support and sponsorship

Ministry of Health, Labor, and Welfare of Japan.

Conflicts of interest

There are no conflicts of interest.

REFERENCES

1. Ahn ES, Scott RM, Robertson RL Jr, Smith ER. Chorea in the clinical presentation of moyamoya disease: Results of surgical revascularization and a proposed clinicopathological correlation. *J Neurosurg Pediatr* 2013;11:313-9.
2. Akin A, Yilmaz R, Selcuk F, Akbostanci MC. Sudden onset of oromandibular dystonia after cerebellar stroke. *Tremor Other Hyperkinet Mov (NY)* 2014;4:262.
3. Baik JS, Lee MS. Movement disorders associated with moyamoya disease: A report of 4 new cases and a review of literatures. *Mov Disord* 2010;25:1482-6.
4. Burguera JA, Bataller L, Valero C. Action hand dystonia after cortical parietal infarction. *Mov Disord* 2001;16:1183-5.
5. Hoshi E, Tremblay L, Feger J, Carras PL, Strick PL. The cerebellum communicates with the basal ganglia. *Nat Neurosci* 2005;8:1491-3.
6. Im SH, Oh CW, Kwon OK, Cho BK, Chung YS, Han DH. Involuntary movement induced by cerebral ischemia: Pathogenesis and surgical outcome. *J Neurosurg* 2004;100:877-82.
7. Kuroda S, Houkin K. Moyamoya disease: Current concepts and future perspectives. *Lancet Neurol* 2008;7:1056-66.
8. Kuroda S, Houkin K, Ishikawa T, Nakayama N, Iwasaki Y. Novel bypass surgery for moyamoya disease using pericranial flap: Its impacts on cerebral hemodynamics and long-term outcome. *Neurosurgery* 2010;66:1093-101; discussion 1101.
9. Kuroda S, Nakayama N, Yamamoto S, Kashiwazaki D, Uchino H, Saito H, *et al.* Late (5-20 years) outcomes after STA-MCA anastomosis and encephalo-duro-myo-arterio-pericranial synangiosis in patients with moyamoya disease. *J Neurosurg* 2020;134:909-16.

10. LeDoux MS, Lorden JF, Ervin JM. Cerebellectomy eliminates the motor syndrome of the genetically dystonic rat. *Exp Neurol* 1993;120:302-10.
11. Lee JY, Kim SK, Wang KC, Chae JH, Cheon JE, Choi JW, *et al.* Involuntary movement in pediatric moyamoya disease patients: Consideration of pathogenetic mechanism using neuroimaging studies. *Childs Nerv Syst* 2014;30:885-90.
12. Mink JW. Basal ganglia mechanisms in action selection, plasticity, and dystonia. *Eur J Paediatr Neurol* 2018;22:225-9.
13. Neychev VK, Gross RE, Lehericy S, Hess EJ, Jinnah HA. The functional neuroanatomy of dystonia. *Neurobiol Dis* 2011;42:185-201.
14. Pandey P, Bell-Stephens T, Steinberg GK. Patients with moyamoya disease presenting with movement disorder. *J Neurosurg Pediatr* 2010;6:559-66.
15. Raoofi S, Khorshidi H, Najafi M. Etiology, diagnosis and management of oromandibular dystonia: An update for stomatologists. *J Dent (Shiraz)* 2017;18:73-81.
16. Scott RM, Smith JL, Robertson RL, Madsen JR, Soriano SG, Rockoff MA. Long-term outcome in children with moyamoya syndrome after cranial revascularization by pial synangiosis. *J Neurosurg* 2004;100 Suppl 2:142-9.
17. Sugita Y, Funaki T, Takahashi JC, Takagi Y, Fushimi Y, Kikuchi T, *et al.* Reversible striatal hypermetabolism in chorea associated with moyamoya disease: A report of two cases. *Childs Nerv Syst* 2016;32:2243-7.
18. Suzuki J, Takaku A. Cerebrovascular “moyamoya” disease. Disease showing abnormal net-like vessels in base of brain. *Arch Neurol* 1969;20:288-99.

How to cite this article: Koga Y, Kashiwazaki D, Hori E, Akioka N, Kuroda S. Oro-mandibular dystonia in pediatric moyamoya disease: Two cases report. *Surg Neurol Int* 2021;12:449.