

2023

Cryoglobulinemia Leading to the Diagnosis of Low Grade Serous Ovarian Carcinoma

Garo Hagopian

Department of Medicine, University of California Irvine Medical Center, hagopiag@hs.uci.edu

Christopher Grant

Department of Medicine, University of California Irvine Medical Center

Jerry Lou

Division of Pathology, University of California Irvine Medical Center

Cary Johnson

Division of Pathology, University of California Irvine Medical Center

Zahra Pakbaz

Department of Medicine, University of California Irvine Medical Center

Follow this and additional works at: <https://scholarlycommons.gbmc.org/jchimp>

Recommended Citation

Hagopian, Garo; Grant, Christopher; Lou, Jerry; Johnson, Cary; and Pakbaz, Zahra (2023)

"Cryoglobulinemia Leading to the Diagnosis of Low Grade Serous Ovarian Carcinoma," *Journal of Community Hospital Internal Medicine Perspectives*: Vol. 13: Iss. 6, Article 4.

DOI: 10.55729/2000-9666.1247

Available at: <https://scholarlycommons.gbmc.org/jchimp/vol13/iss6/4>

This Case Report is brought to you for free and open access by the Journal at GBMC Healthcare Scholarly Commons. It has been accepted for inclusion in Journal of Community Hospital Internal Medicine Perspectives by an authorized editor of GBMC Healthcare Scholarly Commons. For more information, please contact GBMCcommons@gbmc.org.

Cryoglobulinemia Leading to the Diagnosis of Low Grade Serous Ovarian Carcinoma

Garó Hagopian ^a, Christopher Grant ^a, Jerry Lou ^b, Cary Johnson ^b, Zahra Pakbaz ^{a,c,d,*}

^a Department of Medicine, University of California Irvine Medical Center, United States

^b Division of Pathology, University of California Irvine Medical Center, United States

^c Division of Hematology/Oncology, University of California Irvine School of Medicine, United States

^d Chao Family Comprehensive Cancer Center, University of California Irvine Medical Center, United States

Abstract

We present the case of a 64-year-old female who was referred by her oncologist to benign hematology clinic for persistent asymptomatic cryoglobulinemia. Workup led to diagnosis of a rare low grade ovarian serous carcinoma. We briefly review the pathophysiology and clinical significance of cryoglobulinemia and the diagnosis and management of low grade serous ovarian carcinoma.

Keywords: Cryoglobulinemia, Low grade serous ovarian carcinoma

1. Introduction

Cryoglobulins are abnormal immunoglobulins that precipitate at temperatures lower than 37 °C and dissolve upon rewarming.¹ Cryoglobulinemia is rare and clinically significant in 1 per every 100,000 patients.² The exact pathogenesis of cryoglobulin formation is poorly understood but is thought to be multifactorial to genetic, environmental, and immunologic factors.^{3,4} Cryoglobulinemia is classified into three subtypes based on the type of immunoglobulin present. Type 1 consists of monoclonal immunoglobulins which are often associated with monoclonal gammopathies such as multiple myeloma, monoclonal gammopathy of undetermined significance (MGUS), and Waldenstroms macroglobulinemia. Type 1 often presents with vascular symptoms including digital ischemia, livedo reticularis, and skin necrosis.⁵ Type 2 consists of monoclonal IgM with rheumatoid factor activity and polyclonal IgG. Type 2 can result from hepatitis C or connective tissue diseases. Type 3 cryoglobulinemia is associated with polyclonal IgM with RF activity and polyclonal IgG and can be secondary to connective

tissue disorders or infections.⁵ Type 2 and type 3 often present with arthralgias, fatigue, myalgias, and peripheral neuropathy.^{6,7} Symptoms of cryoglobulinemia can range from completely asymptomatic to incredibly debilitating.^{8,9} Treatment of cryoglobulinemia depends on the type of cryoglobulinemia, underlying etiology, and symptom severity.¹⁰ In general, treatment of cryoglobulinemia is treatment of the underlying cause. For example, HCV related cryoglobulinemia would need treatment of hepatitis C with antivirals¹¹ while those with connective tissue disorders would receive immunosuppressive medications.¹² The association between cryoglobulinemia and infection, rheumatologic, lymphoproliferative disorders has been well described in literature. However, the association between cryoglobulins and solid tumors are rare and poorly understood. This case illustrates one of those rare cases of a rare ovarian neoplasm as the etiology of cryoglobulinemia.

2. Case

A 64-year-old female with a past medical history significant for breast cancer in remission was referred to benign hematology clinic by her breast

Received 6 April 2023; revised 21 July 2023; accepted 3 August 2023.
Available online 4 November 2023

* Corresponding author.

E-mail addresses: hagopiag@hs.uci.edu (G. Hagopian), crgrant1@hs.uci.edu (C. Grant), jjlou@hs.uci.edu (J. Lou), caryj@hs.uci.edu (C. Johnson), zpakbaz@hs.uci.edu (Z. Pakbaz).

<https://doi.org/10.55729/2000-9666.1247>

2000-9666/© 2023 Greater Baltimore Medical Center. This is an open access article under the CC BY-NC license (<http://creativecommons.org/licenses/by-nc/4.0/>).

cancer oncologist for asymptomatic cryoglobulinemia. She had initially undergone a hematologic evaluation after she was told by phlebotomists in multiple occasions that her blood samples hemolyzed in the collecting tubes and required redraws. She had a normal hemoglobin of 12.8 g/dL but initial work up was significant for a haptoglobin less than 8 mg/dL, a positive cryoglobulin, and a positive poly-specific direct antiglobulin screening with negative anti-complement or anti-IgG. Lab work for monoclonal gammopathies were negative and rheumatoid factor (RF), anti-nuclear antibody (ANA), c-reactive protein (CRP), erythrocyte sedimentation rate (ESR), serology for hepatitis A virus (HAV), hepatitis B virus (HBV), hepatitis C virus (HCV), and human immunodeficiency virus (HIV) were unremarkable. Given that she was asymptomatic, and no etiology was found, it was concluded that her cryoglobulin was a false positive.

Upon presentation to hematology clinic, a thorough history and physical examination were obtained. The patient denied musculoskeletal or mucocutaneous symptoms. Her past medical history was remarkable for osteoporosis, glaucoma and estrogen receptor positive breast cancer that was in remission after lumpectomy, radiation therapy and ten years of aromatase inhibition. She denied any history of blood transfusions. Her social history was also unremarkable, and she denied tobacco or drug use. Her family history was positive for lupus in her niece and heart disease in her grandmother but was otherwise unremarkable for hematologic disease. Her physical exam was unremarkable. Additional lab work including ANA, serum viscosity, PCR for Epstein–Barr virus (EBV), cytomegalovirus (CMV), HBV, HCV, and HIV were negative. DAT was only positive for anti-complement; however, cold agglutinin was negative. Repeat labs for monoclonal gammopathy remained negative. She was found to have iron and B12 deficiency with negative intrinsic factor. A CT chest, abdomen, and pelvis demonstrated a 4.1 cm tubular shaped cystic lesion within the left pelvis arising from the left adnexa versus a small bowel loop. However, serum tumor markers were negative (CA125 of 29, CEA of 0.5, Inhibin A of 1, Inhibin B less than 1, and AFP of 7.1). Transvaginal ultrasound confirmed a left ovarian mass measuring 3 cm. A subsequent MRI demonstrated an irregular endometrium and a 3.1 cm mixed cystic and solid mass of the left ovary that was concerning for neoplasm. The biopsy of her endometrium was unremarkable. A PET/CT scan did not demonstrate any FDG-avid lesions outside the pelvis but did show activity in bilateral pelvis/ovary.

Subsequent exploratory laparoscopy and ovarian biopsy demonstrated a low-grade serous proliferation with differential including a serous borderline tumor implant, implant associated with a low-grade serous carcinoma, and primary peritoneal borderline tumor. Therefore, the patient underwent a total abdominal hysterectomy and bilateral salpingo-oophorectomy (TAH-BSO). Pathologic evaluation of multiple tissue biopsies demonstrated bilateral ovarian serous borderline tumors with involvement of the uterine serosal surface and pelvic peritoneum. Immunohistochemical stains were positive for WT-1 and PAX-8, patchy wild type P53 positivity and Ki-67 with increased proliferative index (of 20%). Stains for GATA-3 and mammaglobin were negative. Expert consultation confirmed a stage 3B low grade serous ovarian carcinoma (Fig. 1). Following surgery, the patient was started on maintenance letrozole. Her CA-125 and CT scan after surgery were negative for recurrence. Additionally, after her surgery, her serum was checked for cryoglobulins twice. She tested positive once and negative the next time. Throughout her course her cryoglobulinemia remained asymptomatic. She is planned for routine monitoring every 6 months with CT imaging and CA-125.

3. Discussion

Here we discuss the unique case of a 64-year-old female who presented with persistently positive asymptomatic cryoglobulinemia. Extensive workup for the etiology led to diagnosis of a stage 3b low grade serous ovarian carcinoma (LGSOC) which was the likely culprit for her cryoglobulinemia. This was concluded as other etiologies were negative and her cryoglobulin did not clearly fit any of the three cryoglobulinemia subtypes as her cryoglobulins were polyclonal and without RF activity. To our knowledge, our patient is the only published case of ovarian cancer associated cryoglobulinemia. Of note her initial history of “recurrent hemolysis of blood samples in the tubes during blood collection” for her annual routine physical visit is a typical scenario for patients with asymptomatic cryoglobulinemia that health care providers need to be aware of.

LGSOC is a morphologically distinct subtype of ovarian cancer that accounts for less than 5% of ovarian tumors.^{13,14} LGSOC is designated as low grade or high-grade carcinoma based primarily on nuclear atypia. Low-grade serous carcinomas are indolent, exhibit low-grade nuclei with infrequent mitotic figures, and have typical micropapillary architecture. They have frequent mutations of the KRAS, BRAF, or ERBB2 genes (not obtained in our

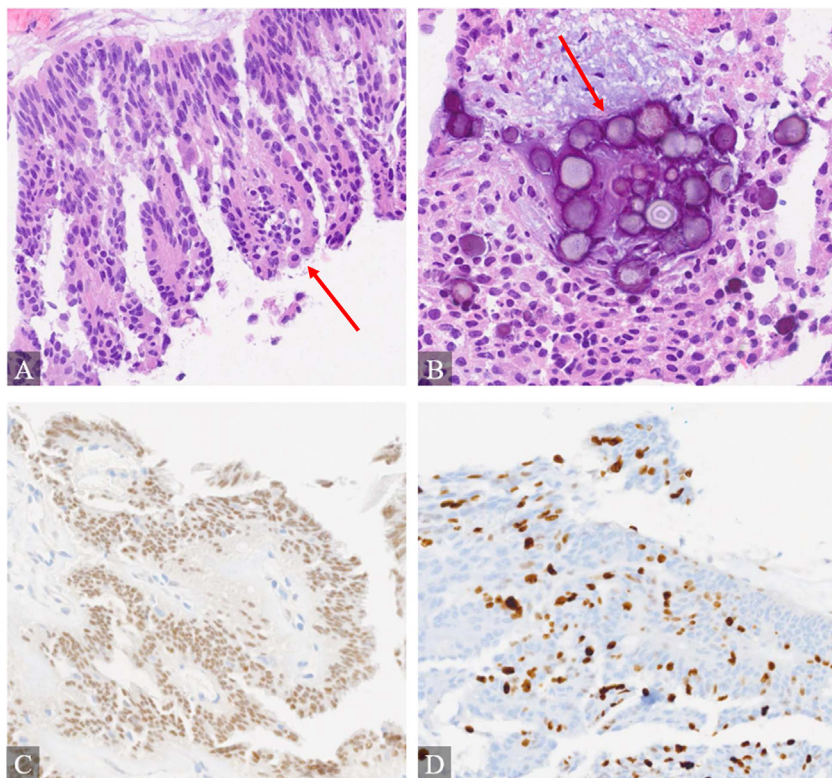


Fig. 1. The lesion displayed (A) micropapillary features and (B) psammomatous calcifications (H&E). (C) Positive WT-1. (D) The Ki-67 proliferation index was about 20%.

case) but are generally without a TP53 mutation. On the other hand, high-grade serous carcinomas exhibit high-grade nuclei with many mitotic figures and generally have a TP53 mutation.¹⁵ LGSOC carries a better survival rate compared to its high-grade counterpart.¹⁶ Surveillance of LGSOC is similar to other ovarian cancers with routine monitoring of CA-125 and CT imaging.^{13,14} Surgery is the primary treatment for LGSOC. Patients with Stage I-IIa can be treated with surgery alone. Patients with stage IIB-IV disease can receive adjuvant chemotherapy followed by endocrine therapy or adjuvant endocrine therapy alone.¹⁷ Given its indolent nature, LGSOC is less responsive to chemotherapy compared to high grade serous carcinoma.¹⁸ As a result, neoadjuvant chemotherapy is less favored. The commonly used adjuvant chemotherapy regimens are Carboplatin and paclitaxel for 6 cycles followed by maintenance hormone therapy such as aromatase inhibition.¹³ One study found that patients with stage II–IV LGSOC who received maintenance hormone therapy after cytoreductive surgery and platinum-based chemotherapy had a longer progression free survival compared to those who did not receive maintenance hormone therapy

(median PFS, 64.9 vs. 26.4 months; $P < .001$).¹⁹ Another study suggests that chemotherapy may not be necessary in patients with advanced-stage disease who have received adjuvant hormone therapy.²⁰ A randomized trial comparing paclitaxel/carboplatin followed by maintenance hormonal therapy versus hormonal therapy alone in patients with LGSOC is underway at the time of this publication.²¹ Our patient had a TAH-BSO and adjuvant aromatase inhibition. She has been monitored routinely with CT imaging and CA-125 which remain negative. Her cryoglobulin is intermittently positive after treatment; however, this is not unusual as many patients continue to have a positive cryoglobulin after treatment of underlying etiology.²² Her cryoglobulinemia was not treated with immunosuppressive medications given her asymptomatic disease course. The association of cryoglobulinemia and solid tumors remains poorly understood. There have been cases of cryoglobulinemia secondary to prostate cancer in patients who have tested negative for HCV.^{23,24} It has also been reported in a patient with a thymic tumor.²⁵ One retrospective review of 493 patients with solid tumors only found two cases to have

cryoglobulinemia.²⁶ There is no data to suggest that one solid tumor may lead to cryoglobulinemia at an increased frequency compared to another.

4. Conclusion

Cryoglobulinemia is generally associated with infection, rheumatologic disorders, and hematological malignancies especially lymphoproliferative disorders and monoclonal gammopathies. It is vital to consider evaluation for solid tumors if initial diagnostic workup inconclusive.

Disclaimers

The authors have no disclaimers.

Conflicts of Interest

The authors have no conflicts of interest to disclose.

References

- Akriadiadis EA, Xanthakis I, Navrozidou C, Papadopoulos A. Prevalence of cryoglobulinemia in chronic hepatitis C virus infection and response to treatment with interferon-alpha. *J Clin Gastroenterol*. Dec 1997;25(4):612–618. <https://doi.org/10.1097/00004836-199712000-00013>.
- Napodano C, Gulli F, Rapaccini GL, Marino M, Basile U. Cryoglobulins: identification, classification, and novel biomarkers of mysterious proteins. *Adv Clin Chem*. 2021;104:299–340. <https://doi.org/10.1016/bs.acc.2020.09.006>.
- Bhandari J, Awais M, Aeddula NR. *Cryoglobulinemia*. StatPearls. StatPearls publishing copyright © 2022. StatPearls Publishing LLC.; 2022.
- Ramos-Casals M, Trejo O, García-Carrasco M, Cervera R, Font J. Mixed cryoglobulinemia: new concepts. *Lupus*. 2000; 9(2):83–91. <https://doi.org/10.1191/096120300678828127>.
- Terrier B, Karras A, Kahn JE, et al. The spectrum of type I cryoglobulinemia vasculitis: new insights based on 64 cases. *Medicine (Baltimore)*. Mar 2013;92(2):61–68. <https://doi.org/10.1097/MD.0b013e318288925c>.
- Muchtar E, Magen H, Gertz MA. How I treat cryoglobulinemia. *Blood*. Jan 19 2017;129(3):289–298. <https://doi.org/10.1182/blood-2016-09-719773>.
- Gorevic PD, Kassab HJ, Levo Y, et al. Mixed cryoglobulinemia: clinical aspects and long-term follow-up of 40 patients. *Am J Med*. Aug 1980;69(2):287–308. [https://doi.org/10.1016/0002-9343\(80\)90390-3](https://doi.org/10.1016/0002-9343(80)90390-3).
- Maire MA, Mittey M, Lambert PH. The presence of cryoprecipitable immunoglobulins in normal human sera may reflect specific molecular interactions. *Autoimmunity*. 1989; 2(2):155–164. <https://doi.org/10.3109/08916938909019952>.
- Schamberg NJ, Lake-Bakaar GV. Hepatitis C virus-related mixed cryoglobulinemia: pathogenesis, clinical manifestations, and new therapies. *Gastroenterol Hepatol*. Sep 2007;3(9):695–703.
- Brouet JC, Clauvel JP, Danon F, Klein M, Seligmann M. Biologic and clinical significance of cryoglobulins. A report of 86 cases. *Am J Med*. Nov 1974;57(5):775–788. [https://doi.org/10.1016/0002-9343\(74\)90852-3](https://doi.org/10.1016/0002-9343(74)90852-3).
- Schott P, Hartmann H, Ramadori G. Hepatitis C virus-associated mixed cryoglobulinemia. Clinical manifestations, histopathological changes, mechanisms of cryoprecipitation and options of treatment. *Histol Histopathol*. Oct 2001;16(4): 1275–1285. <https://doi.org/10.14670/hh-16.1275>.
- Terrier B, Krastinova E, Marie I, et al. Management of noninfectious mixed cryoglobulinemia vasculitis: data from 242 cases included in the CryoVas survey. *Blood*. Jun 21 2012; 119(25):5996–6004. <https://doi.org/10.1182/blood-2011-12-396028>.
- Elsherif S, Javadi S, Viswanathan C, Faria S, Bhosale P. Low-grade epithelial ovarian cancer: what a radiologist should know. *Br J Radiol*. Mar 2019;92(1095):20180571. <https://doi.org/10.1259/bjr.20180571>.
- Bodurka DC, Deavers MT, Tian C, et al. Reclassification of serous ovarian carcinoma by a 2-tier system: a gynecologic oncology group study. *Cancer*. Jun 15 2012;118(12):3087–3094. <https://doi.org/10.1002/cncr.26618>.
- Vang R, Shih Ie M, Kurman RJ. Ovarian low-grade and high-grade serous carcinoma: pathogenesis, clinicopathologic and molecular biologic features, and diagnostic problems. *Adv Anat Pathol*. Sep 2009;16(5):267–282. <https://doi.org/10.1097/PAP.0b013e3181b4fffa>.
- Malpica A, Deavers MT, Lu K, et al. Grading ovarian serous carcinoma using a two-tier system. *Am J Surg Pathol*. Apr 2004; 28(4):496–504. <https://doi.org/10.1097/0000478-200404000-00009>.
- Gadducci A, Cosio S. Therapeutic approach to low-grade serous ovarian carcinoma: state of art and perspectives of clinical research. *Cancers*. May 23 2020;12(5). <https://doi.org/10.3390/cancers12051336>.
- Schlumbrecht MP, Sun CC, Wong KN, Broaddus RR, Gershenson DM, Bodurka DC. Clinicodemographic factors influencing outcomes in patients with low-grade serous ovarian carcinoma. *Cancer*. Aug 15 2011;117(16):3741–3749. <https://doi.org/10.1002/cncr.25929>.
- Gershenson DM, Bodurka DC, Coleman RL, Lu KH, Malpica A, Sun CC. Hormonal maintenance therapy for women with low-grade serous cancer of the ovary or peritoneum. *J Clin Oncol*. Apr 1 2017;35(10):1103–1111. <https://doi.org/10.1200/jco.2016.71.0632>.
- Fader AN, Bergstrom J, Jernigan A, et al. Primary cytoreductive surgery and adjuvant hormonal monotherapy in women with advanced low-grade serous ovarian carcinoma: reducing overtreatment without compromising survival? *Gynecol Oncol*. Oct 2017;147(1):85–91. <https://doi.org/10.1016/j.ygyno.2017.07.127>.
- Nickles Fader A, Gien LT, Miller A, Covens A, Gershenson DM. A randomized phase III, two-arm trial of paclitaxel, carboplatin, and maintenance letrozole versus letrozole monotherapy in patients with stage II-IV, primary low-grade serous carcinoma of the ovary or peritoneum. *J Clin Oncol*. 2021/05/20 2021;39(15_suppl):TP55601. https://doi.org/10.1200/JCO.2021.39.15_suppl.TP55601.
- Bonacci M, Lens S, Mariño Z, et al. Long-Term outcomes of patients with HCV-associated cryoglobulinemic vasculitis after virologic cure. *Gastroenterology*. Aug 2018;155(2): 311–315.e6. <https://doi.org/10.1053/j.gastro.2018.04.024>.
- Albawaliz A, Bahaj W, Abughanimeh OK, Noman A, Kujtan L. A case of prostate cancer presenting with rash. *Cureus*. May 23 2019;11(5):e4734. <https://doi.org/10.7759/cureus.4734>.
- Spatola L, Angelini C, Selmi C, et al. HCV-negative mixed cryoglobulinemic glomerulonephritis and solid malignancy: a case report and review of the literature. *Nephro-Urol Mon*. 2017; 9(5):e5814. In Press doi: <https://doi.org/10.5812/numonthly.58142>.
- Athanassiou P, Ioakimidis D, Weston J, Georganas K, Kontomerkos T, Davies KA. Type 1 cryoglobulinaemia associated with a thymic tumour: successful treatment with plasma exchange. *Br J Rheumatol*. Mar 1995;34(3):285–289. <https://doi.org/10.1093/rheumatology/34.3.285>.
- Rullier P, Le Quellec A, Cognot C. Cryoglobulins not HCV-related and solid tumors: retrospective analysis from a series of 493 patients. *Eur J Intern Med*. 2009;8:e158.