

## CASE REPORT

# Sliding Amyand's hernia: a case report and review of literature

Amr Elgazar<sup>1</sup>, Ahmed K. Awad<sup>1,\*</sup>, Debvarsha Mandal<sup>2</sup>, Raid M. Faddah<sup>3</sup>, Zachary Elder<sup>4</sup> and Sheref A. Elseidy<sup>5</sup>

<sup>1</sup>Department of General Surgery, Ain Shams University, Cairo, Egypt, <sup>2</sup>Caribbean Medical University, Chicago, IL, USA, <sup>3</sup>Detroit Medical Center, Heart and Vascular Institute, Detroit, Michigan, USA, <sup>4</sup>American University of the Caribbean School of Medicine, USA and <sup>5</sup>Department of Cardiovascular Diseases, Ain Shams University, Cairo, Egypt

\*Correspondence address: General Surgery Department, Ain-Shams University, Cairo, Egypt. Tel: 00201067071734; E-mail: ahmedkawad@gmail.com

## Abstract

First operated by Claudius Amyand in 1735. Amyand's hernia is a rare presentation and accounts for only 1% of all inguinal hernias. Amyand's hernia is described when the appendix is trapped within an inguinal hernia. In most cases, Amyand's hernia is an incidental finding intra-operatively due to variable clinical manifestations, and features. Amyand's hernia has variable theories explaining its pathophysiology besides having multiple proposed surgical approaches either via laparoscopic or open repair and with the latter being in a debate of pro and against mesh repair. We present a case of a sliding Amyand's hernia in which the vermiform appendix and part of the cecum were adherents to the wall of a right inguinal hernial sac. Amyand's hernia is a rare form of inguinal hernias and its presentation is widely variable. However, in most cases, it is non-complicated and is found as an incidental intraoperative finding. Many studies debate among different diagnostic and management approaches to serve a better outcome with fewer operative complications.

## INTRODUCTION

Hernia is a protrusion of an organ or its fascia through the wall of a containing cavity [1]. When an organ is contained within a non-reducible hernia, it is termed an incarcerated hernia. While a strangulated hernia is when the blood supply to the edematous, incarcerated bowel is compromised secondary to venous and lymphatic obstruction, Amyand's hernia is when the appendix is trapped within the inguinal hernia. Amyand's hernia is a rare presentation and accounts for only 1% of all inguinal hernias [1]. In most cases, Amyand's hernia is an incidental finding intra-operatively due to non-specific clinical manifestations and various clinical features. Moreover, as the clinical presentations differ from one condition to another, surgical approaches vary

accordingly to the condition in which the vermiform appendix is present [2].

## CASE PRESENTATION

A 47-year-old male patient presented to our outpatient clinic complaining of 4 years duration of right groin swelling. No associated comorbidities were found. On examination inspection of the swelling, it was about 5 × 7 cm, oval in shape, soft inconsistency, with well-defined edges and smooth surface and gives an expansible impulse on coughing. On scrotal neck test, it was inguinoscrotal (funicular type). The hernia was completely reducible with no signs of obstruction or strangulation. The patient was scheduled for open hernia repair.

Received: May 1, 2021. Accepted: June 15, 2021

Published by Oxford University Press and JSCR Publishing Ltd. © The Author(s) 2021.

This is an Open Access article distributed under the terms of the Creative Commons Attribution License (<http://creativecommons.org/licenses/by/4.0/>), which permits unrestricted reuse, distribution, and reproduction in any medium, provided the original work is properly cited.

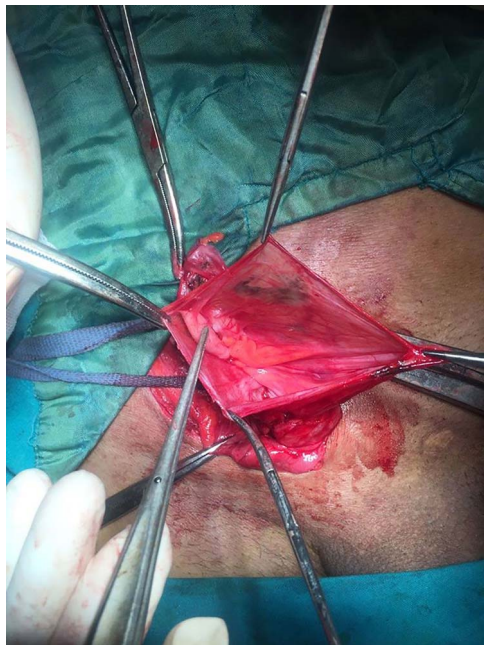


Figure 1: Sliding Amyand's hernia.

Routine pre-operative laboratory workup was done including TLC, ESR and CRP showed no abnormalities. Intra-operatively, the hernial sac was identified and dissected from the spermatic cord down to the internal ring; upon opening the hernia sac, a vermiform appendix with its mesoappendix and part of the cecum were completely adherent to the wall of the sac Fig. 1. The appendix was not inflamed and the decision of sac closure and reduction into the abdominal cavity through the internal ring with performing the usual Liechtenstein tension-free hernioplasty was made.

The post-operative course was uneventful and the patient was discharged from the hospital on next day. Follow-up examinations and imaging showed no complications.

## DISCUSSION

Claudius Amyand was the first to operate and report a case of inguinal hernia harboring a vermiform appendix in 1735 [3]. The incidence of Amyand's hernia is rarely ranging from 0.19 to 1.7%. Appendicitis in inguinal hernia is rarer and range from 0.07 to 0.13%. Perforated appendix within the inguinal hernia is less common and it accounts for only 0.1% of all cases of appendicitis [4–6]. Most of Amyand's hernia occurs on the right side due to the normal anatomical position of the appendix; however, left-sided Amyand's hernias have been reported [6]. Johnson *et al.* suggested that appendicitis in such cases could be due to extraluminal compression rather than intraluminal obstruction; several theories on the pathophysiology of this rare disorder have been reported however an exact cause is still unclear [7].

Losanoff and Basson classify the Amyand's hernia into four types according to the condition of the vermiform appendix; Type 1: Normal appendix within inguinal hernia; Type 2: Acute appendicitis within inguinal hernia with no abdominal sepsis; Type 3: Acute appendicitis within the inguinal hernia, abdominal wall or peritoneal sepsis; Type 4: Acute appendicitis within an inguinal hernia, related or unrelated abdominal pathology [8]. Rikki modified this classification and add type 5 to it which included incisional and it is subdivided into (5A): Normal appendix within an incisional hernia; (5B): Acute appendicitis

within an incisional hernia, no abdominal sepsis, and (5C): Acute appendicitis within an incisional hernia, abdominal wall or peritoneal sepsis or with previous surgery [9].

Imaging studies are seldom requested to diagnose inguinal hernias and diagnosis depends primarily on clinical examination especially in completely reducible uncomplicated cases. Ultrasound can detect vermiform appendix within the hernia sac [10]. Computed tomography (CT) scan with contrast is more specific and sensitive than ultrasound especially in complicated cases [11]. All of this can guide the pre-operative diagnosis; however, the final management is undertaken on an intra-operative basis. With mortality ranging from 14 to 30% and mostly owed to the peritoneal spread of sepsis, Amyand's hernia requires proper surgical management—surgery is both therapeutic and diagnostic, yet the definitive surgical management is still unclear.

While many authors do not recommend mesh repair in cases where there is acute appendicitis and appendectomy is needed to be performed, others see that it is safe and it could reduce the rate of recurrence of inguinal hernia even in the presence of a septic environment [12]. Ivashchuk *et al.* recommended that the presence of appendicitis and hence appendectomy should not limit the use of mesh in the repair and the best management option should be according to surgical preference [2]. Laparoscopic management of Amyand's hernia has also been proposed as when Rehman *et al.* and Vermillion *et al.* were the first to use laparoscopy in Amyand's hernia management reporting low septic environment, better outcomes and better recovery [13, 14]. The best management strategy for Amyand's hernia is debatable, yet its answer lay behind these questions: is appendectomy required? which approach should be used? What form of repair should be undertaken?

In our case, the appendix and part of the cecum were adherent to the hernia sac wall. The appendix was not inflamed—type 1—therefore not requiring appendectomy. Mesh repair was done without evidence of recurrence of hernia at 1-year follow-up. Green and Gutwein reported the only similar case to ours: a type 1 Amyand's hernia to which herniotomy with hernioplasty was performed without the need of appendectomy [15]. On the other side, Shamim reported a case in a 27-year-old male in which the appendix—7.5 cm in length—was a sliding component of the sac but not adherent to the wall. Although he performed appendectomy as it looked inflamed with mesh repair, the appendix was normal in specimen final histopathology [16].

## CONCLUSION

Amyand's hernia is a rare entity and its presentation differs from case to case. The diagnosis is very difficult owed due to the uncomplicated presentations which are mostly seen in these patients. Management modalities are debatable and provide many plausible and rationally accepted pros and cons that steer the approach toward one surgical modality versus the other. However, in our opinion, open repair with mesh without the need for an appendectomy should be the definitive strategy in absence of inflammation, sepsis, provided by a clean intra-operative environment and skilled surgical expertise.

## REFERENCES

1. Ali SM, Malik KA, Al-Qadhi H. Amyand's hernia: study of four cases and literature review. *Sultan Qaboos Univ Med J* 2012;12:232–6.
2. Ivashchuk G, Cesmebasi A, Sorenson EP, Blaak C, Tubbs SR, Loukas M. Amyand's hernia: a review. *Med Sci Mon Int Med J Exp Clin Res* 2014;20:140.

3. Amyand CVIII. Of an inguinal rupture, with a pin in the appendix coeci, incruised with stone; and some observations on wounds in the guts. *Philos Trans R Soc Lond* 1736;**39**:329–42.
4. Sharma H, Gupta A, Shekhawat NS, Memon B, Memon MA. Amyand's hernia: a report of 18 consecutive patients over a 15-year period. *Hernia* 2007;**11**:31–5.
5. Häuser U, Merkle P. Differential diagnosis of incarcerated inguinal hernia in an infant: appendicitis in the hernial sac. *Z Kinderchir* 1984;**39**:72–3.
6. Pellegrino JM, Feldman SD. Case report: acute appendicitis in an inguinal hernia. *N J Med J Med Soc N J* 1992;**89**:225–6.
7. Johnson CD. Appendicitis in external hernia. *Ann R Coll Surg Engl* 1982;**64**:283.
8. Losanoff JE, Basson MD. Amyand hernia: a classification to improve management. *Hernia* 2008;**12**:325–6.
9. Singal R, Mittal A, Gupta A, Gupta S, Sahu P, Sekhon MS. An incarcerated appendix: report of three cases and a review of the literature. *Hernia* 2012;**16**:91–7.
10. Mebis W, Hoste P, Jager T. Amyand's Hernia. *J Belg Soc Radiol* 2018;**102**:8.
11. Ivashchuk G, Cesmebasi A, Sorenson EP, Blaak C, Tubbs SR, Loukas M. Amyand's hernia: a review. *Med Sci Monit Int Med J Exp Clin Res* 2014;**20**:140.
12. Chatzimavroudis G, Papaziogas B, Koutelidakis I, Tsiaousis P, Kalogirou T, Atmatzidis S, et al. The role of prosthetic repair in the treatment of an incarcerated recurrent inguinal hernia with acute appendicitis (inflamed Amyand's hernia). *Hernia* 2009;**13**:335.
13. Vermillion JM, Abernathy SW, Snyder SK. Laparoscopic reduction of Amyand's hernia. *Hernia* 1999;**3**:159–60.
14. Rehman MR, Panteli C, Tsang T. Laparoscopic repair of Amyand's hernia in an 8-week-old infant. *Hernia* 2010;**14**:443–5.
15. Green J, Gutwein LG. Amyand's hernia: a rare inguinal hernia. *J Surg Case Rep* 2013;**2013**:rjt043.
16. Shamim M. Amyand's hernia as a sliding component of inguinal hernia. *J Surg Pak (Int)* 2010;**15**:60.