

Available online at www.sciencedirect.com

ScienceDirect

journal homepage: www.elsevier.com/locate/radcr

Case Report

Dynamic CT angiography of the head and neck in the diagnosis of Bow Hunter's Syndrome: A case report [☆]

Caiyun Shi, M.D.^a, Lingjie Wang, M.D., Ph.D.^a, Yana Dou, M.D., Ph.D.^b, Fan Yang, M.D.^a, Ying Qiao, M.D.^a, Hua Zhang, M.D.^{a,*}

^a Department of Radiology, First Hospital of Shanxi Medical University, Taiyuan, Shanxi Province 030001, People's Republic of China

^b Siemens Healthcare Ltd, Beijing 100102, People's Republic of China

ARTICLE INFO

Article history:

Received 27 July 2020

Revised 9 August 2020

Accepted 9 August 2020

Keywords:

Angiography of the head and neck

Bow Hunter's Syndrome

Computed tomography

ABSTRACT

Bow Hunter's syndrome is extremely rare, which is mainly caused by mechanical vertebral artery occlusion or stenosis during head and neck rotation or hyperextension. Herein, we describe the case of a 19-year-old man without a history of trauma who presented with dizziness, binocular blackness, and disturbance of consciousness after looking up when cleaning the classroom. Subsequent imaging findings revealed the blood flow of the C2 segment of the contralateral vertebral artery was interrupted when the patient turned his head to 1 side. Such patients with normal CT angiography of the head and neck scan will show that the head and neck blood vessels are normal, which will affect the prognosis of patients. This case highlights the importance and implications of dynamic CT angiography of the head and neck in the diagnosis of Bow Hunter's syndrome.

© 2020 The Authors. Published by Elsevier Inc. on behalf of University of Washington.

This is an open access article under the CC BY-NC-ND license

(<http://creativecommons.org/licenses/by-nc-nd/4.0/>)

Introduction

Bow Hunter's syndrome (BHS), also known as rotating vertebral artery occlusion syndrome, is a rare but treatable symptomatic vertebrobasilar artery insufficiency syndrome, which is characterized by dynamic rotation leading to vertebral artery occlusion. It was first proposed by Sorensen in 1978 when he described a hunter turning his head and shooting an arrow to cause Wallenberg syndrome [1,2]. If the diagnosis

is not timely, it will lead to cerebral posterior circulation ischemia and affect the prognosis and quality of life of patients. Therefore, the use of dynamic CT angiography of the head and neck plays a vital role in a timely and accurate diagnosis.

Case presentation

On March 20th, 2019, a 19-year-old male student, after cleaning the classroom experienced dizziness around half an hour

[☆] Written informed patient consent for publication has been obtained.

* Corresponding author.

E-mail address: 13623665879@163.com (H. Zhang).

<https://doi.org/10.1016/j.radcr.2020.08.022>

1930-0433/© 2020 The Authors. Published by Elsevier Inc. on behalf of University of Washington. This is an open access article under the CC BY-NC-ND license (<http://creativecommons.org/licenses/by-nc-nd/4.0/>)

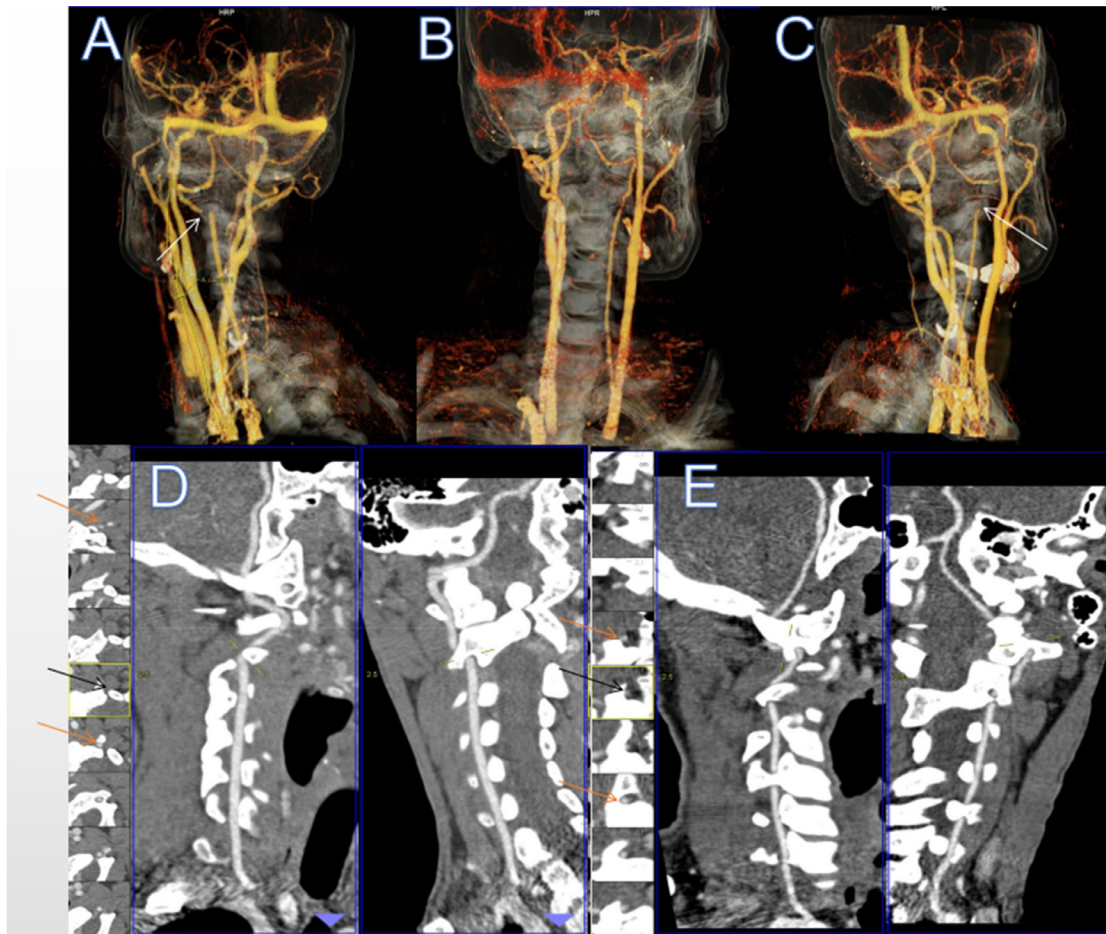


Fig. 1 – VR and MPR images of CT angiogram of the patient turning his head to one side showed contralateral C2 segment occlusion. (A) VR image of CT angiogram of the patient turning right 90° showed C2 segment occlusion of the left vertebral artery (white arrow). (B) VR image of CT angiogram of the patient in the neutral position showed good bilateral vertebral artery development. (C) VR image of CT angiogram of the patient turning left 90° showed C2 segment occlusion of the right vertebral artery (white arrow). (D) MPR image of CT angiogram of the patient turning right 90° showed C2 segment occlusion of the left vertebral artery (black arrow), but the other vascular segments were normal (yellow arrow). (E) MPR image of CT angiogram of patient turning left 90° showed C2 segment occlusion of the right vertebral artery (black arrow), but the other vascular segments were normal (yellow arrow). MPR, multiplanar reconstruction; VR, virtual reality. (Color version of the figure is available online.)

after looking up, accompanied by rotation of visual objects, binocular blackness, and disturbance of consciousness but with, no nausea, vomiting, or tinnitus. In the local hospital, no obvious abnormality was found in the MRI of the head, cervical spine, and lumbar spine. At this time, the patient felt dizzy when walking and normal when sitting or lying down. The patient confirmed no history of craniocerebral and cervical trauma. In our hospital, the patient underwent head and neck dynamic computed tomography angiography (CTA) examination using a Siemens SOMATOM Force dual-source CT scanner. Head and neck dynamic CTA showed (Fig. 1), when the patient was located in a neutral position, the bilateral vertebral artery developed well, and the right vertebral artery thinner than the left. The patient was told to turn 90° to the left, where the virtual reality (VR) and multiplanar reconstruction (MPR) of the

vertebral artery showed local interruption of the upper edge blood flow of the C2 level of the right vertebral artery, and the contralateral vertebral artery developed well. The patient was told to turn the head 90° to the right, after which the vertebral artery VR and curved surface reconstruction MPR showed local interruption of the left vertebral artery C2 level superior edge blood flow, and the contralateral vertebral artery developed well. The patients completed other laboratory tests and received symptomatic treatment such as improving circulation and brain protection.

After symptomatic treatment, the dizziness and other symptoms of the patients were significantly improved, and the patients were ordered to follow up regularly after discharge. Up to now, the patient's previous symptoms have not recurred.

Differential diagnosis

BHS should be differentiated from vertebral artery type cervical spondylosis and ischemic stroke. They have similar symptoms, such as dizziness, disturbance of consciousness, which are easily confused clinically.

Discussion

BHS is rare and is divided into primary and secondary BHS subtypes. Osteophyte and bone spur are the most common cause of primary BHS [3]. Secondary BHS arises due to complications in surgeries such as aortic arch replacement, aneurysm operation, head and neck trauma, and movement [4]. The adolescent BHS may be due to the occipital condyle, the abnormal bypass of the vertebral artery, or the abnormality of the cervical spine. The vertebral artery is well distributed in the V2 segment because passes through the transverse foramen of the cervical vertebra, but each segment of the vertebral artery can be developed [5]. Thus, when the BHS patient is rotated or overstretched at the head, a narrowing or even temporary occlusion of 1 or both of the vertebral arteries under a series of factors leads to the insufficiency of the vertebral artery, and the symptoms of dizziness, nystagmus, nausea and vomiting, and Horner syndrome [6]. The BHS symptoms are the same and maybe transient ischemic or severe post-circulatory ischemia. These symptoms can be immediately relieved when the head is returned to the neutral position. The threshold angle of the symptoms is 30°, 40°, 45°60°, 80°, and 90° [6–10]. Therefore, we use head rotation to assist in the analysis of the effect of blood flow dynamics to determine if ischemia is present. The current “gold standard” auxiliary examination is the cerebral artery digital subtraction angiography. While, digital subtraction angiography is accurate, rapid and allows blood flow change to be observed in real-time, it is also invasive, the patient's acceptance is poor and the observation of the surrounding structure is limited. With the rapid development of medical imaging technology, the CT has also realized a wide range of rapid scanning. The third-generation dual-source CT has a faster scanning speed and wider coverage, so the dynamic CTA examination can be completed in a shorter time. The reconstruction of the image can be completed on the workstation, and the problems of blood vessel shape, small size, stenosis, or vascular malformation can be displayed at multiple angles. Combined with carotid ultrasound findings and clinical features, the final diagnosis was BHS. The patient was asked to avoid excessive neck movement, protect the cervical vertebra, and wear a cervical collar if necessary. The follow-up lasted for 5 months after patient discharge, during which time the symptoms have not recurred.

In this case, using these functions of the CT, multiposition dynamic scanning of a blood vessel was performed under a single injection of contrast agent. The scanning was carried

out under the neutral position, and a 6-second scanning interval was used for rapidly changing the position of the patient under the guidance of the doctor. The scanning image was successfully obtained, and the diagnosis effect was good. As far as we know, this is the first time that BHS has been diagnosed on CT with a single injection of contrast agent, using a scanning method that allows patients to constantly change their position and a special scanning program for the patient. However, our design also has some limitations. That is, for 20 seconds after the start of the scan, the display of the artery is partially blocked due to the large-area enhancement of the peripheral vein of the vertebral body. The 3-dimensional imaging effect is affected, though, the artery can be clearly observed in the cross-section. This is a defect that we have not considered in the protocol design. It is also a reminder that the overall scan duration should be noted in the future design to avoid venous interference and make the arterial image clearer.

REFERENCES

- Grandhi R, Godse N, Williamson RW, Hanel RA. Bowhunter's syndrome. *BMJ Case Rep* 2015;2015:bcr2015210654. doi:10.1136/bcr-2015-210654.
- Duan G, Xu J, Shi J, Cao Y. Advances in the pathogenesis, diagnosis, and treatment of bow hunter's syndrome: a comprehensive review of the literature. *Interven Neurol* 2016;5(1-2):29–38. doi:10.1159/000444306.
- Jadeja N, Nalleballe K. Pearls & oysters: Bowhunter syndrome: a rare cause of posterior circulation stroke: do not look the other way. *Neurology* 2018;91(7):329–31 PMID: 30104228.
- Anene-Maidoh TI, Vega RA, Fautheree GL, Reavey-Cantwell JF. An unusual case of pediatric bow hunter's stroke. *Surg Neurol Int* 2013;4(1):148. doi:10.4103/2152-7806.121647.
- Lu T, Chinnadurai P, Anaya-Ayala JE, Diaz OM. DynaCT angiography for the diagnosis of bilateral bow hunter's syndrome. *Interven Neuroradiol* 2017;23(1):73–8. doi:10.1177/1591019916673221.
- Sakai K, Tsutsui T. Bow hunter's stroke associated with atlantooccipital assimilation—case report. *Neurol Med Chir* 1999;39(9):696–700 PMID: 10563123.
- Seki T, Hida K, Akino M, Iwasaki Y. Anterior decompression of the atlantoaxial vertebral artery to treat bow hunter's stroke: technical case report. *Neurosurgery* 2001;49(6):1474–6. doi:10.1097/00006123-200112000-00037.
- Ikeda DS, Vilelli N, Shaw A, Powers C. Bow hunter's syndrome unmasked after contralateral vertebral artery sacrifice for aneurysmal subarachnoid hemorrhage. *J Clin Neurosci* 2014;21(6):1044–6. doi:10.1016/j.jocn.2013.10.005.
- Chung CK, Cheng BC, Welch WC, Park CK. Bow hunter's stroke caused by a severe facet hypertrophy of C1-2. *J Korean Neurosurg Soc* 2010;47(2):134–6. doi:10.3340/jkns.2010.47.2.134.
- Yoshitaka Y, Nagasawa H, Yamakawa T, Kato T. Bow hunter's syndrome after contralateral vertebral artery dissection. *J Stroke Cerebrovasc Dis* 2012;21(8):916.e7–916.e9. doi:10.1016/j.jstrokecerebrovasdis.2012.04.003.