

## Oncology

# Mixed germ cell tumor of metastatic undescended testicle causing major GIS bleeding

Özlem Zeliha Sert<sup>a,\*</sup>, Hilmi Bozkurt<sup>a</sup>, Aziz Serkan Senger<sup>b</sup>, Özge Hande Güneş<sup>c</sup>

<sup>a</sup> Gastrointestinal Surgery Fellow at Kosuyolu Education and Research Hospital, Istanbul, Turkey

<sup>b</sup> Gastrointestinal Surgeon, Kosuyolu Education and Research Hospital, Istanbul, Turkey

<sup>c</sup> Pathology Department, Kartal, Dr. Lutfi Kırdar Education and Research Hospital, Istanbul, Turkey

## ARTICLE INFO

## Keywords:

Cryptorchidism  
Germ cell tumor  
Non-seminoma  
Testicular cancer  
Undescended testis

## Introduction

Most of the testicular tumors originate from the testis in normal localization, so they can often be diagnosed at an early stage, resulting in good prognosis. One out of every 500 men has undescended testes that may be associated with complications such as cancer, ischemia and infertility. Undescended testis is most commonly seen in the inguinal canal but only 10% is located in the abdominal cavity<sup>1</sup>.

## Case presentation

A 32-year-old young fertile male patient was admitted to the hospital emergency department due to syncope in December 2017. His vital signs included tachycardia and hypotension. His fever was and oxygen saturation was normal. In the laboratory hemoglobin (HB) was 4.5 g/dl and hematocrit was %20. 6 units of erythrocyte suspension were given. In the physical examination a large, palpable mass was in the right lower quadrant of the abdomen. There was melena in the rectal touch. Antral gastritis was found in the gastroscopy and the colonoscopy was normal. CT demonstrated a 92 × 71 × 99 mm thick-walled cystic lesion in the right side of the right lower quadrant (Fig. 1). Five metastases suspected nodular lesion were found in the liver, as well. Hence, positron emission tomography (PET) was done because of distant metastases. The lesions in the liver were interpreted as metastasis and there were also suspected lesions in the right lung. AFP was high (2930 ng/dl), carcinoembryonic antigen (CEA) and carbohydrate antigen (CA) 19-9 were normal. In addition lactate dehydrogenase

hydrogen (LDH) was 207 IU/L. Because of the 300-fold high AFP, testicular tumor was suspected in the differential diagnosis. Despite the left testis was palpated, in the right scrotum the testis could not be palpated. On scrotal ultrasonography (USG); right testis wasn't in its normal place and the left testis was normal. Initially, the we suspected non seminoma due to undescended testis. Surgery was planned because of HB level wasn't increased despite the transfusion, and occurring recurrent severe GIS bleeding. At subsequent laparotomy, there was a nearly 12 × 10 cm mass adjacent to small bowel segments. He underwent partial small bowel resection, side-to-side anastomosis and segment 5 liver wedge resection (Fig. 2). The patient was discharged postoperatively without complication. Pathologic evaluation of the mass showed testicular mixed germ cell tumor (mostly 70% teratoma, 20% yolk sac tumor, 10% choriocarcinoma). Tumor size was measured as 13 × 12 × 6 cm, vascular invasion and tunica albuginea invasion were present (Fig. 3). Liver metastasectomy was mixed germ cell carcinoma. The tumor stage was accepted as TxNxM1b according to the American Joint Committee on Cancer (AJCC) 8th edition. After discharge, the patient was referred to the Oncology unit for standard bleomycin, etoposide and cisplatin (BEP) treatment.

## Discussion

Undescended testicular cancer peaks at 3rd or 4th decade. Histopathology of undescended testis tumor in adults, depending on location, is when located in the abdomen 93% pure seminoma, if inguinal 63% and 28% if normotrophic.<sup>2</sup> In this case, testis was located in

\* Corresponding author. Kosuyolu Education and Research Hospital, Istanbul, Turkey. Tel.: +905077678007.

E-mail address: [drzozlemsert@gmail.com](mailto:drzozlemsert@gmail.com) (Ö.Z. Sert).

<https://doi.org/10.1016/j.eucr.2019.100868>

Received 17 December 2018; Accepted 14 March 2019

Available online 20 March 2019

2214-4420/© 2019 The Authors. Published by Elsevier Inc. This is an open access article under the CC BY-NC-ND license (<http://creativecommons.org/licenses/by-nc-nd/4.0/>).

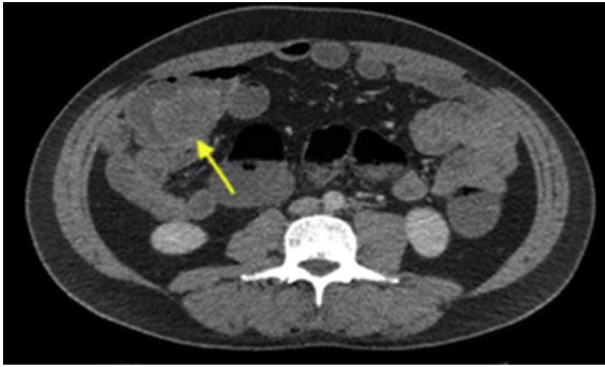


Fig. 1. Axial contrast-enhanced computed tomography (CT) scan demonstrated thick-walled cystic lesion in the right side of the right lower quadrant.

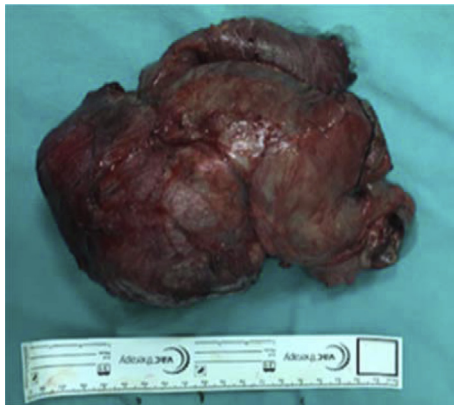

Fig. 2. Intraoperative photo of undescended testis tumor after partial small bowel resection.

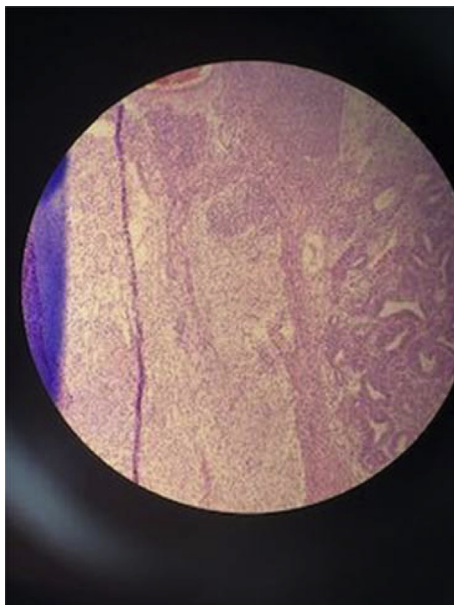


Fig. 3. Hematoxylin and Eosin (H&E) stain showing that tumor cells with vascular invasion and tunica albuginea invasion.

the abdomen, despite this histopathologic components of mixed germ cell tumor was mostly 70% teratoma, 20% yolk sac and 10% choriocarcinoma. 50% of the testicular non-seminoma germ cell tumors present a symptom with metastasis. Most of these metastases occur in the para-aortic lymph nodes or supraclavicular fossa or in the lung,

liver, bone or brain so in this presentation, multiple liver metastases and suspicious metastasis were present in the lung. In the detailed history of the patient, a physical examination performed by urology in childhood and the right testis was not palpated in scrotum.

The right testis was not detected in the scrotal USG. Subsequent abdomen USG did not show any intra-abdominal pathology. The right testicular agenesis was diagnosed. Afterwards, the patient did not go to urology follow-up and no infertility developed, nor did any symptoms occur until sudden syncope occurred. In developed countries, the presence of undescended testis in adults is rare, since this is a good practice of elective orchidopexy performed before age 2 to prevent cancer and infertility. Orchidopexy does not reduce the risk of cancer, but facilitates testicular exploration in early diagnosis.<sup>3</sup>

There are many studies in the literature on cryptorchidism and cancer.

However, there are no long series of intra-abdominal testicular tumors, and most of the cases are in the form of case reports.

In the literature, the case presented by Ahmed Abu-Zaid et al. in Saudi Arabia, presented a 25-year-old male with undescended testicle with a rapidly growing mass in the left groin. A 17 × 19 × 35 cm retroperitoneal mass without distant metastasis was detected in CT. Tru-cut biopsy resulted mixed germ cell tumor and the patient underwent orchiectomy. Four cycles of BEP treatment were given after discharge.<sup>4</sup> In this report, we planned surgery due to ongoing major GIS bleeding despite transfusion, as well. There are no advanced cases such as our case in the literature.

Nickalis et al. reported that a 30-year-old male patient with severe right lower quadrant pain presented to the emergency service. CT demonstrated that 9.9 × 9 × 13.1 cm heterogeneous mass which had torsion findings. At subsequent laparotomy they removed a 10 × 10 cm intra-abdominal left testicular tumor and the final pathology was seminoma with extensive necrosis.<sup>5</sup>

Since germ cell tumors of the intra-abdominal testis are rare in the etiology of GIS bleeding, they are not suspected at the time of diagnosis. A complete physical examination including a scrotal examination may provide initial clues about likelihood etiology and should not be ignored, because testicular cancers are especially highly curable. On the other hand, true classification of the patient and accurate diagnosis play a vital role in achieving successful results.

**Conclusion**

If a young male has an empty inguinal canal and abdominal mass, an intra-abdominal testicular mass should be taken into account. Public awareness should be increased in terms of signs and symptoms of testis tumors, and the importance of testicular self-examination.

**Conflict of interest**

The authors declare that there is no conflict of interest regarding the publication of this case report.

**References**

1. Miller FH, Whitney WS, Fitzgerald SW, Miller EI. Seminomas complicating undescended intraabdominal testes in patients with prior negative findings from surgical exploration. *AJR Am J Roentgenol.* 1999 Feb;172(2):425–428.
2. Carmona Campos E, Regueiro Lopez JC, Prieto Castro R, Leva Vallejo M, Moreno Arcas P, Requena Tapia MJ. Cryptorchidism and testicular cancer. *Actas Urol Esp.* 2000;24(1):49–51.
3. Rogers E, Teahan S, Gallagher H, et al. The role of orchiectomy in the management of postpubertal cryptorchidism. *J Urol.* 1998;159(3):851–854.
4. Abu-Zaid A, Azzam A, Amin T. Mixed germ cell tumor complicating an intra-abdominal cryptorchidism. *Hematol Oncol Stem Cell Ther.* 2013;6(3-4):122–123.
5. Nickalis OJ, Tan CL, Thian YL. A torred ruptured intra-abdominal testicular seminoma presenting as an acute abdomen. *J Radiol Case Rep.* 2015;9(12):21–28.