

Case Report

# Extracting a large live freely floating cysticercosis cyst from the anterior chamber of the eye using visco expression technique: A case report



Satya Prakash Singh<sup>a</sup>; Jagriti Rana<sup>a</sup>; Jagdish Dukre<sup>a,\*</sup>; Premala Anthony Singh<sup>b</sup>

## Abstract

Ocular involvement by cysticercosis is uncommon and rare in the anterior chamber. It can give rise to iridocyclitis which can be potentially blinding to the patient. The management is usually surgical. We report a case of 18-year-old girl with large cysticercosis cyst in the anterior chamber. The cyst was removed intact by viscoexpression technique from the anterior chamber of the eye and the patient achieved visual acuity of 6/9 post-operatively.

**Keywords:** Cysticercosis, Ocular cysticercosis, Anterior chamber cyst, Viscoexpression

© 2015 The Authors. Production and hosting by Elsevier B.V. on behalf of Saudi Ophthalmological Society, King Saud University. This is an open access article under the CC BY-NC-ND license (<http://creativecommons.org/licenses/by-nc-nd/4.0/>).  
<http://dx.doi.org/10.1016/j.sjopt.2015.08.003>

## Introduction

Cysticercosis is the infection of the human being by the larval form of bacon tapeworm, *Taenia Solium*. The human infection is acquired either by drinking contaminated water or eating improper cooked bacon or vegetables infested with eggs of the worm or rarely by autoinfection due to reverse peristalsis whereby the eggs reach the portal system in a retrograde manner from the intestines.<sup>1</sup> The tapeworm resides in the small intestine of man who is definitive host. Segments containing the ova are shed in the stool. The eggs are ingested by swines who act as intermediate host. Upon ingestion the capsule of the egg digested by gastric juices of the boar and the oncosphere comes out which is deposited in the muscles, brain, eye or skin. It passes into larval or cysticercus stage. The cyst can liberate toxin if ruptured

causing intense local tissue reaction. Later, it may calcify or form a small fibrous nodule.

## Case report

An 18-year-old girl reported to our outpatient department with the history of redness in the right eye one month back which was associated with pain, watering and redness. This was followed by decrease of visual acuity in her right eye for 15 days. She also noticed something white floating in the same eye for 3 days before presenting to our outpatient department. There was no history of fever, convulsions or headache. She was a vegetarian, who had no pets.

On examination vision was 6/36 in both eyes. No restriction of ocular movements was noted in any direction in either of the eyes.

Received 22 February 2015; received in revised form 20 May 2015; accepted 3 August 2015; available online 17 August 2015.

<sup>a</sup> Regional Institute of Ophthalmology at Govt. M. D. Eye Hospital, Moti Lal Nehru Medical College, Allahabad, Uttar Pradesh, India

<sup>b</sup> Department of Pathology, Moti Lal Nehru Medical College, Allahabad, Uttar Pradesh, India

\* Corresponding author at: Regional Institute of Ophthalmology at Govt. M. D. Eye Hospital, Dr. Katju Road, Allahabad, Uttar Pradesh 211003, India. Mobile: +91 8765626342.

e-mail addresses: [dr.spsingh999@rediffmail.com](mailto:dr.spsingh999@rediffmail.com) (S.P. Singh), [jagritirana@rediffmail.com](mailto:jagritirana@rediffmail.com) (J. Rana), [jagdishdukre@gmail.com](mailto:jagdishdukre@gmail.com) (J. Dukre), [premalaanthonysingh@hotmail.com](mailto:premalaanthonysingh@hotmail.com) (P.A. Singh).

Slit lamp biomicroscopy revealed two live cysts in the anterior chamber in the right eye while the left eye was unremarkable. The grayish white cysts were neither attached to the iris nor to the cornea or lens capsule and were freely floating in the anterior chamber (Fig. 1a). The cyst showed characteristic undulating, contracting and expanding movements along with protrusion and retraction of scolex head from the cyst (Fig. 1b). Mutton fat keratic precipitates (KP's) were present along with grade 3 flare (Fig. 1c). When the scolex was invaginated, its location within the cyst was indicated by a dense white spot called the receptaculum capitis while when evaginated it made pendulous movements (Fig. 1d). The iris pattern and the lens capsule were normal. Fundus examination of both eyes was unremarkable. The stool examination and the haemogram and ESR were within normal limits.

Ultrasonography of the orbits showed small cystic lesions of size  $2.9 \times 2.6$  mm in anterior chamber of right eye on lateral side with irregular thin echogenic membrane along anterior surface of the iris (Fig. 2a). The CT-scan of the brain revealed no lesions in brain parenchyma.

The patient was started on oral prednisolone 1 mg/kg/day and oral albendazole (15 mg/kg/day). Topical prednisolone acetate 1% eye drop was started four times a day in the right eye. The patient could not come for an early surgery due to some personal problems and came a day later. On the second day, one of the cysts was ruptured and ruptured cyst wall was seen in anterior chamber along with large floating cyst (Fig. 1d).

Peribulbar anaesthesia had been given after which limbal incision at 12 o'clock position with blade no. 11 was made. Crescent was used for making a clear corneal tunnel. A 3.2 mm keratome was used for anterior chamber entry.

Viscoelastic (methylcellulose) substance was injected in the anterior chamber through the wound. The cyst was gently guided to the wound and removed through the incision by depressing the posterior lip of the chamber and simultaneously injecting the viscoelastic. The cyst came out without getting ruptured in toto. The self sealing clear corneal wound was hydrated.

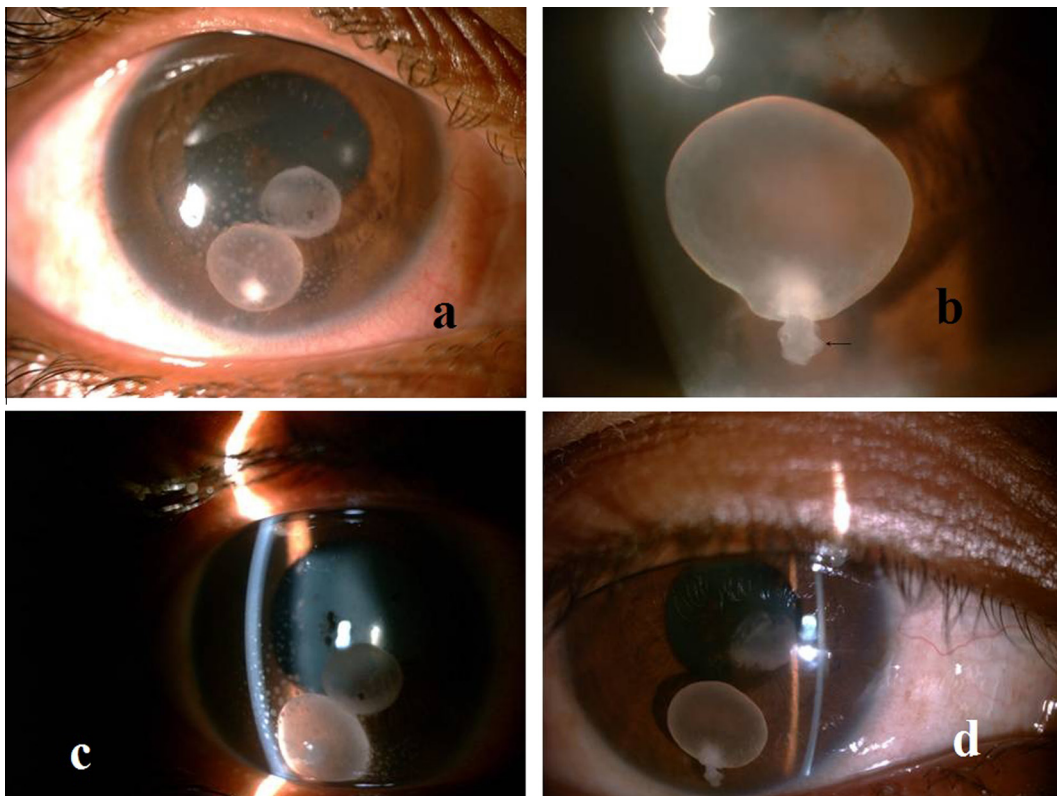
The specimen was sent for histopathological study. On gross examination, the cyst appeared to be translucent white in appearance and measured  $0.2 \text{ cm} \times 0.2 \text{ cm}$ . It was fixed in 10% formalin and stained with haematoxylin and eosin (Fig. 2b). Histopathologically, the specimen demonstrated a scolex and a membranous cyst wall, thus confirming it was a cyst of *cysticercus cellulosae* (Fig. 2c and d).

Post-operatively, topical steroids one hourly and atropine eye drops three times a day were prescribed. Oral prednisolone and albendazole were continued as prescribed pre-operatively.

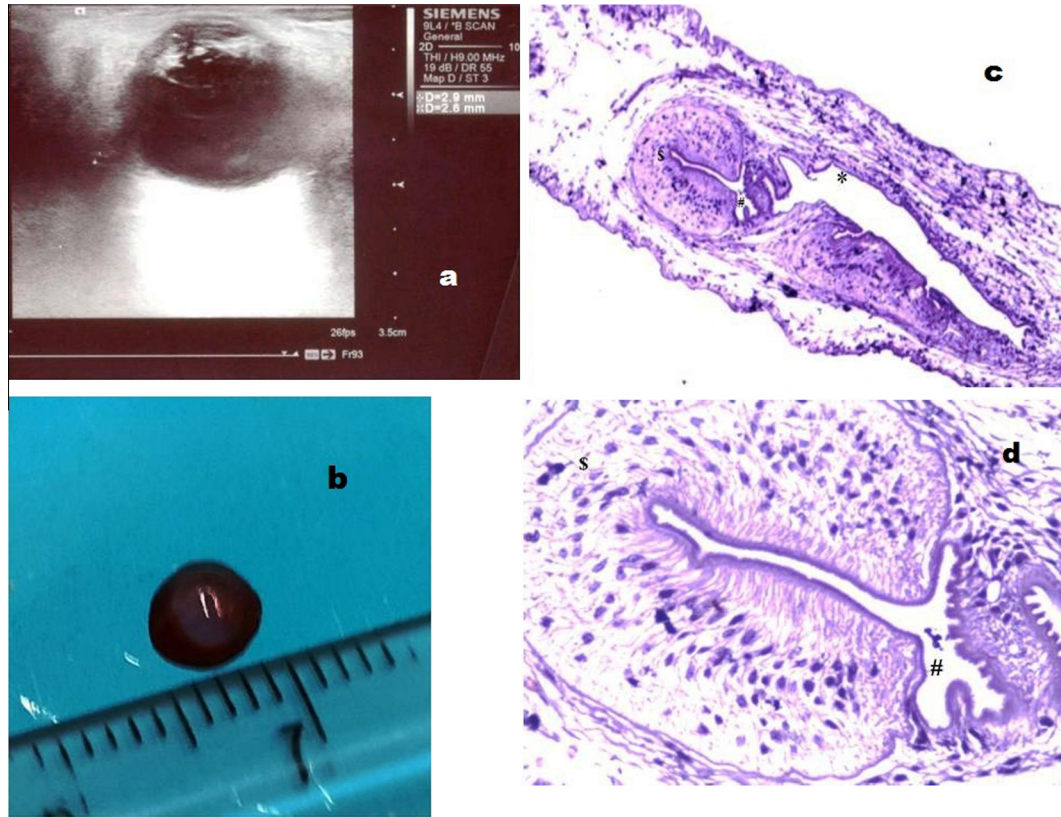
By the second post-operative day, the mutton fat keratic precipitates had completely cleared and the vision was 6/12 in the right eye, with no cells or flare in anterior chamber (Fig. 3a and b). The anterior segment and the posterior segment examinations were within normal limit. We regularly followed up the patient for 1 month and advised her glasses after surgery. Her corrected vision with glasses in the right eye is 6/9.

## Discussion

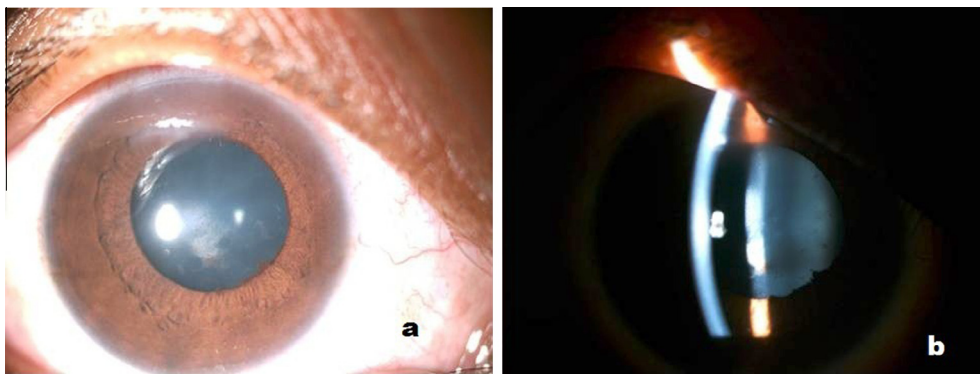
Ocular involvement occurs in 46% of the infected patients but anterior chamber cysticercosis is an extremely rare



**Figure 1.** (a) Slit lamp images showing live cysts. (b) The black arrow shows the sucker on scolex head. (c) Mutton fat keratic precipitates seen on slit lamp. (d) Ruptured cyst wall with large floating cyst.



**Figure 2.** (a) Cystic lesions with irregular thin echogenic membrane. (b) Gross photograph of cyst after H & E stain. (c) \$, # & \* denote head, sucker and body of scolex (20 $\times$ ). (d) \$ and # denote the head and sucker of scolex (200 $\times$ ).



**Figure 3.** (a) Keratic precipitates completely cleared on post-op. (b) No inflammation seen on second post-operative day.

condition.<sup>2</sup> The cyst enters the eye via the posterior ciliary arteries<sup>3</sup> while the route of entry to anterior chamber remains debatable. Few authors have suggested that it enters the anterior chamber through the ciliary vessels, or through the pupil in aphakes or through the angle of anterior chamber.<sup>4</sup>

On clinical examination on slit lamp biomicroscopy, the cyst shows a characteristic movement, contracting and expanding especially when the beam intensity is changed. In ocular cysticercosis, it is not necessary that eosinophilia be found as was the case in our study where the haemogram was within normal limits. The serological tests are also not of much value in ocular cysticercosis as they lack sensitivity.<sup>5</sup>

The surgeon must take precautions while removing the cyst from the anterior chamber. The cyst if ruptured causes

severe inflammatory reaction in the eye leading to plastic iridocyclitis.<sup>6</sup> Our patient at the time of presentation had two cysts, out of which one had ruptured before the surgery. She had mutton fat keratic precipitates in the eye suggesting that the cyst incites a granulomatous inflammatory response. These mutton fat keratic precipitates had disappeared, probably, because the patient was on oral prednisolone.

Surgical removal of the parasite is the treatment of choice,<sup>1</sup> as the cyst is known to increase in size,<sup>3</sup> thus resulting finally in profound inflammatory reaction.<sup>6</sup> Various surgical modalities described in the literature include paracentesis, extraction with capsule forceps, cryoextraction, evisceration and viscoexpression.<sup>1</sup> We chose viscoexpression for the removal of the cyst as it gives a good working space and minimises the tissue damage.

We could easily remove the cyst through a 3.2 mm supero-temporal incision using viscoexpression and found this facilitates easy removal of the cyst, and should be tried specially in cases where the cyst is large and the chances of rupture are high. An anterior chamber cyst mandates its removal at the earliest, as if delayed the visual results may suffer irreversibly.

### Conflict of interest

The authors declare that there is no conflict of interest.

### References

1. Shekhar CG, Lemke BN. Orbital cysticercosis. *Ophthalmology* 1997;**104**:1599–604.
2. Sachdeva RS, Manchanda SK, Abrol S, Wadhwa SC, Ramchandran KA. Freely mobile cysticercosis in the anterior chamber. *Indian J Ophthalmol* 1995;**43**:135–6.
3. Bartholomew RS. Subretinal cysticercosis. *Am J Ophthalmol* 1975;**79**:670–3.
4. Das JC, Chaudhari Z, Bansal LR. Viscoexpression of anterior chamber cysticercosis cellulosae. *Indian Ophthalmol* 2002;**50**:133–5.
5. Wadhwa V, Kharbanda P, Rai S. How reliable are serological test in diagnosis of cysticercosis. *Indian J Med Microbiol* 2006;**24**:78–9.
6. Mathur RN, Abraham L. Cysticercosis of the eye: a case of a plastic iridocyclitis due to cysticercus cyst in the anterior chamber. *Arch Ophthalmol* 1962;**67**:562–3.