

CASE REPORT

Ewing's sarcoma of maxilla: A rare case report

Deepak Kumar Jairamdas Nagpal, Prashant Ramesh Prabhu, Sangeeta Jayant Palaskar, Swati Patil

Department of Oral Pathology and Microbiology, Sinhgad Dental College and Hospital, Pune, Maharashtra, India

Address for correspondence:

Dr. Deepak Kumar
Jairamdas Nagpal,
Reader, Department of Oral and
Maxillofacial Pathology,
Sinhgad Dental College and Hospital,
Pune - 411 041, Maharashtra, India.
E-mail: deepaknagpal2013@rediffmail.com

Received: 02-11-2013

Accepted: 30-06-2014

ABSTRACT

Ewing's sarcoma is uncommon malignancy of childhood, frequently involving the mandible. The occurrence in maxilla is rare. It is histopathologically characterized by sheets of round cells positive for CD99. Although the prognosis is poor but early diagnosis and long term follow up can improve the survival. This article presents a rare case of Ewing's sarcoma of maxilla in a 15 year old male patient showing excessive fibro-osseous response which is not a frequent presentation. A retrospective analysis of cases of Ewing's sarcoma of maxilla published in the English literature is reviewed. In our case, diagnosis was confirmed by immunohistochemistry where sheets of round tumor cells were positive for CD 99. Ewing's sarcoma of maxilla is a rare and aggressive tumor. Hence early diagnosis, combined therapy and long term follow up is suggested in such cases.

Key words: CD99, Ewing's sarcoma, fibro-osseous, round cells

INTRODUCTION

Ewing's sarcoma (ES) is a primary neoplasm of the skeletal system, first described by James Ewing in 1921.^[1] ES is the second most common bone cancer, most often occurring in Caucasian children, adolescents and young adults. It is considered a high-grade malignancy. The neoplasm is thought to arise from immature reticulum cells or primitive bone marrow cells. The current reports have suggested the role of mesenchymal stem cells (MSC) in Ewing tumor proliferation.^[2] Its occurrence in head and neck region is less frequent and majority of them are found in mandible as compared to maxilla.^[3] This article describes a case of 15-year-old boy with ES of maxilla.

CASE REPORT

A 15-year-old male patient reported with a chief complaint of swelling on right side of face, gradually increasing in size. Episodes of epistaxis were also associated with the enlargement. Swelling was insidious in onset. There was no relevant medical or family history or a history of trauma. On physical appearance there was gross facial asymmetry with a well-circumscribed swelling measuring about 8 × 5 cm, on the right cheek. Movements of the eye were restricted exhibiting

decreased width of palpebral fissure. Acuity of vision was not altered.

Intraorally a well-circumscribed, non-ulcerated, pinkish-red swelling was noticed extending from upper right canine to maxillary tuberosity with obliteration of maxillary vestibule. On palpation the swelling was non tender, slightly lobulated and bony hard in consistency. It was non-pulsatile and noncompressible. The swelling was associated with grade II mobility of the teeth from canine to second molar of the right side.

Considering the patient's history and clinical observation following procedures were carried out.

- Radiographs and Computed Tomography (CT) scan
- Hematological and Biochemical investigations
- An incisional biopsy.

Radiographs

An OPG showed lytic lesion with focal areas of opacification in right maxilla and nasal cavity. In addition, septal deviation with lateral nasal wall erosion, opacification of right maxillary sinus and loss of lamina dura with displacement of roots of first and second premolars were also noted.

Computed tomography scan

It showed an expansile lytic lesion of maxilla and nasal cavity involving the alveolus and hard palate with erosive borders. Posterolateral and anterolateral walls of the right maxillary sinus showed cortical break and extension into the infratemporal, temporal, buccal and facial tissues. Cortical breach was

Access this article online

Quick Response Code:



Website:

www.jomfp.in

DOI:

10.4103/0973-029X.140769

observed in the superior and medial walls of the sinus. Overall the radiographic findings were suggestive of malignancy.

Hematology report

Hemoglobin: 14.2%, total count-8200 cell/mm³, ESR-18MM, Bleeding time (Dukes method)-1 minute 50 seconds, Clotting time (Lee and White method): 5 minutes 20 seconds, differential count: Neutrophils-88%, lymphocytes-10, eosinophils-01, monocytes-01%. HIV, HbsAg was found to be negative by ELISA (tridot and rapid kit respectively).

Biochemical investigation

Using semiautomatic analyzer (Star 21 Plus) Serum Glutamic Oxaloacetic Transaminase, Serum Glutamic-Pyruvic Transaminase, Potassium, Sodium, Calcium, Creatinine and serum alkaline phosphatase were analyzed and found to be within normal range.

Histopathology

Using a sub labial incision, biopsy was performed and sent to our department for examination. The hematoxylin and eosin stained section showed infiltration of proliferating lesional cells with varying amount of reactive fibro-osseous proliferation [Figures 1 and 2]. The tumor cells were in the form of aggregates of round darkly staining cells showing vacuolated cytoplasm and uniform nuclei with evenly dispersed chromatin.

Immunohistochemistry

The tumor cells showed membrane positivity for CD 99 [Figures 3 and 4] and were negative for Pan Cytokeratin [Figure 5], leukocyte common antigen, desmin [Figure 6] and synaptophysin [Figure 7]. These features were conclusive of Ewing's sarcoma.

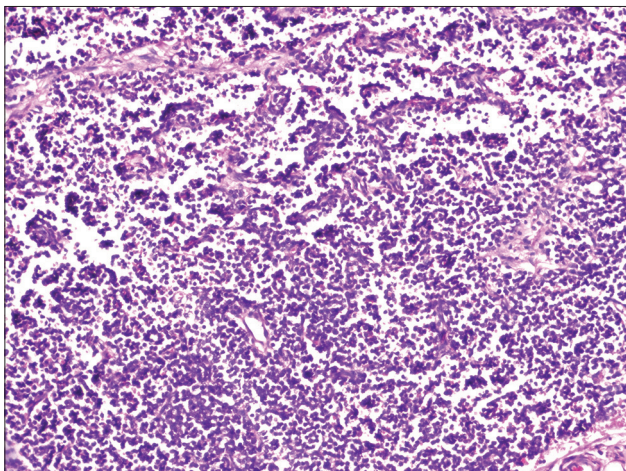


Figure 1: Photomicrograph showing sheets of proliferating round cells. (H&E stain, ×100)

Treatment

An extended maxillectomy [Figure 8] was performed including hard palate till midline. The resected specimen also showed similar histopathological finding with anterior, posterior, medial, lateral and superior margins positive for the lesional cells. Three weeks, postoperatively, the patient was referred for radiation and chemotherapy.

After a follow up period of one year the patient did not reveal any evidence of recurrence. But at three year follow up patient was noticed with multiple metastatic lesions primarily involving the lungs. Soon the patient died of the disease.

DISCUSSION

After osteosarcoma, ES/Peripheral Neuro-Ectodermal Tumor (PNET) is the second most frequent primary malignant tumor occurring in bone. However, it is rare for ES/PNET to be found in the head and neck region.^[1,4] PNET is a rare malignant tumor of ES family of tumors which include ES, PNET and Askins tumor.^[2] ES and PNET share a common karyotype translocation t(11;12) (q24;q12). PNET is thought to be arising from soft tissues and ES in bone. Both ES and PNET share a high level of expression of the CD99 antigen (MIC-2 gene product). Because of these findings many investigators now believe that ES and PNET belong to same spectrum of tumors with different morphological patterns.^[7-9] Approximately 4% of Ewing's sarcoma cases have arisen in the bones of head and neck with 1% occurring in the jaws. When the jaws are involved it frequently involves the mandible than maxilla.^[5, 6, 7, 8, 9] Out of 9 cases analyzed with Ewing's sarcoma of maxilla, 6 were seen in males and 3 in females with a male to female ratio of 2:1 [Figure 9]. The median age of the patient was 17 years. A painful swelling was the most common presentation. The majority of patients had a average tumor size of 6 × 4 cm.^[1,6,10-15] [Figure 10]. Out of these cases, one case presented with a history of trauma.^[15]

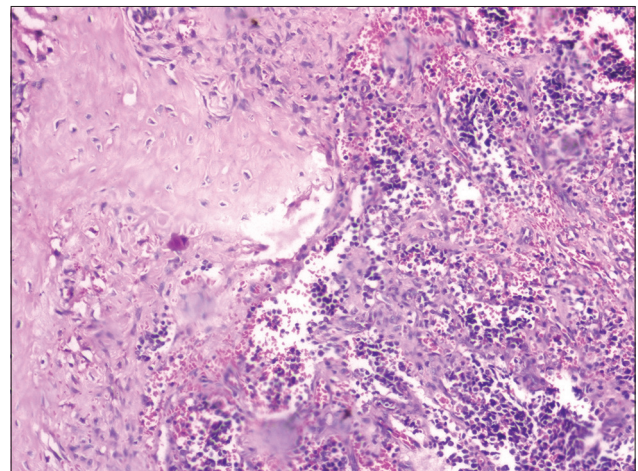


Figure 2: Photomicrograph showing peripheral reactive fibro-osseous proliferation. (H&E stain, ×400)

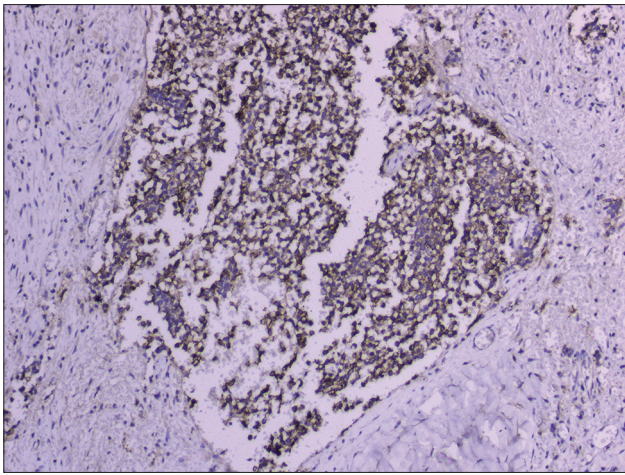


Figure 3: Lesional cells showing strong positivity for CD 99. (IHC stain, ×100)

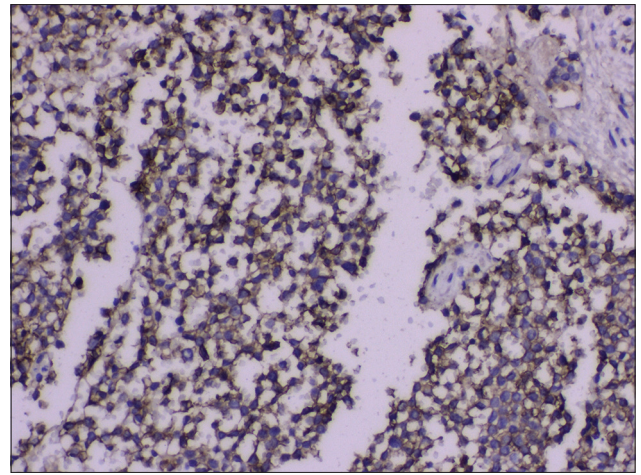


Figure 4: Lesional cells showing strong positivity for CD 99. (IHC stain, ×400)

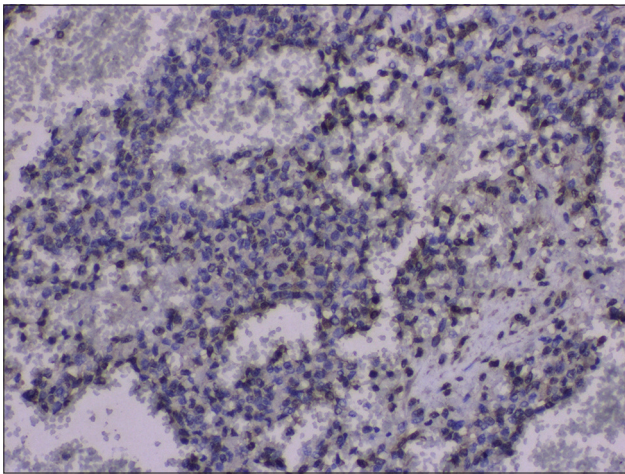


Figure 5: Lesional cells negative for pan cytokeratin>. (IHC stain, ×400)

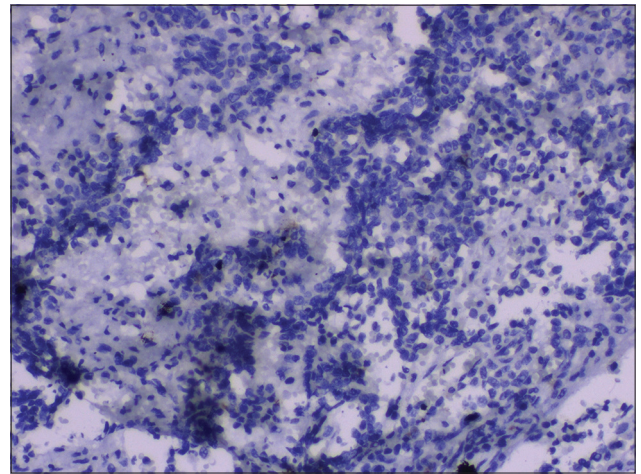


Figure 6: Lesional cells negative for desmin. (IHC stain, ×400)

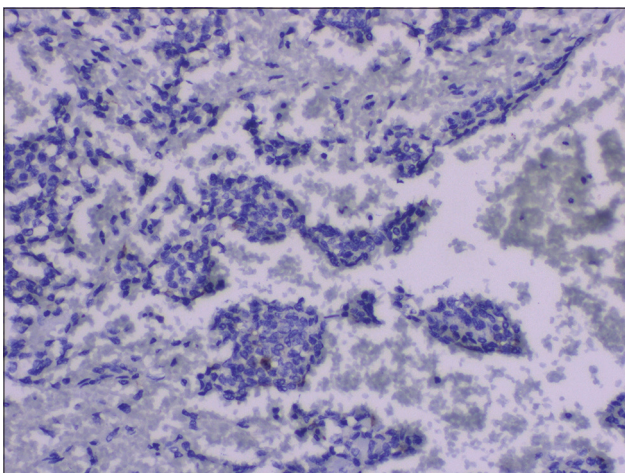


Figure 7: Lesional cells negative for synaptophysin. (IHC stain, ×400)

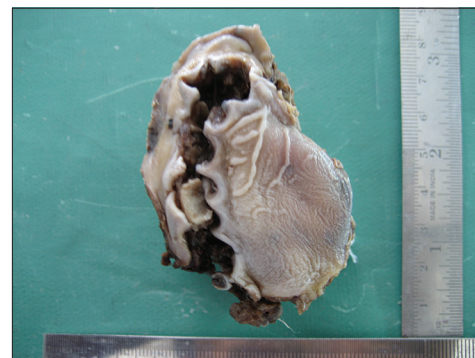


Figure 8: Gross specimen of extended maxillectomy

Its common presentation is localized growth which may be associated with pain and paresthesia. Lesions of maxilla are frequently associated with epistaxis as was seen in our case.^[5,14] The lesion is predominantly seen in children and young

adults. It has characteristic radiographic picture described by some authors as “onion skin appearance” especially in the long bones, but such pattern is less commonly seen in lesions of jaws.^[4,9] Similar findings were observed in our case wherein lytic lesion was observed and the characteristic onion skin appearance was not evident. With respect to teeth, some of the radiological features noted include periodontal space widening, loss of lamina dura, root resorption,

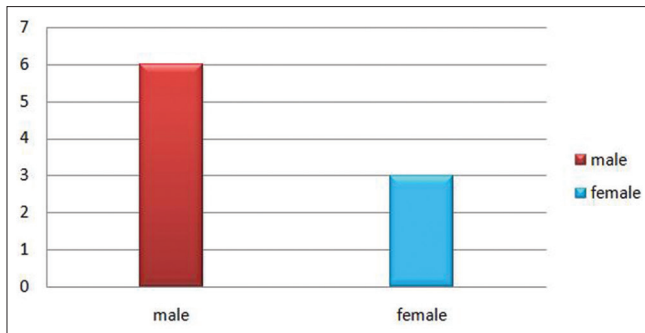


Figure 9: Graph showing sex distribution of Ewing's sarcoma

displacement or more commonly destruction of unerupted tooth follicles. MRI is considered to be an important tool to determine the extent of the lesion and for monitoring the effects of chemotherapy on the tumor.^[16,17] Ewing's sarcoma is composed of uniform small, round, undifferentiated tumour cells with round or oval nuclei exhibiting a fine chromatin pattern, small nucleoli and scanty cytoplasm usually crowded in sheets or segregated in lobules by fine fibrovascular septa.^[9] The intracytoplasmic glycogen may be demonstrated by PAS stain in 75% of the cases, but it is not pathognomonic and conclusive because other small round cells may show the presence of glycogen as well. Since Ewing's sarcomas are usually vascular; hemorrhagic areas and extensive necrosis are common.^[2,3,9] It is rare to see extensive reactive bone formation as was seen in our case, which may be in response to the neoplastic cells, making it difficult to differentiate from round cell osteosarcoma. Histopathologically the tumor must also be differentiated from other small round cell tumor such as mesenchymal chondrosarcoma, rhabdomyosarcoma, malignant lymphoma, eosinophilic granuloma, neuro-endocrine tumors and metastatic neuroblastoma.^[10,11] The use of immunohistochemistry has helped in the diagnosis of this tumor.^[13] In general, the tumor cells are positive for vimentin and CD99 and negative for neural, skeletal, vascular and lymphoid cell markers.^[17-19] Regarding Mic-2 antigen, recently published data have confirmed the high sensitivity of the Mic-2 gene product (CD99) for all ES family tumors with over 95% of the cases showing positivity for this marker.^[2]

Both ES/PNET are no longer considered a distinct entity because of histological and molecular similarities. More than 90% show a clear translocation $t(11; 22)(q24; q12)$ resulting from the fusion of EWS and FLI gene. The gene rearrangement causes a fusion product which functions as an oncogene aberrant transcription factor with structural variability and potential prognostic impact. The neuroepithelial differentiation is varied, Ewing's sarcoma shows a minimum degree of differentiation and PNET shows obvious degree of differentiation.^[2,16]

Ewing's sarcoma is a radiosensitive tumour.^[13] Multimodality therapy consisting of an initial biopsy, aggressive combination of surgery, chemotherapy and localized radiotherapy is the treatment of choice for Ewing's sarcoma of the head and

| Author/Year | Site | Age/sex | Size | Follow-up |
|---|---|---------|--------|-----------------------------|
| Alberto Roca/1968 ¹⁰ | Right side of maxilla | 19/M | 5x3 | INA |
| Alberto Roca/1968 ¹⁰ | Posterior part of hard palate | 16/M | 3x3 | INA |
| Amin MN/1990 ¹¹ | Right side of maxilla | 14/F | 8x6 | INA |
| Leonardo Wexler/2003 ¹² | Posterior part of hard palate | 9/F | 8x6 | No recurrence after 4 years |
| Pedro Infante Cassio/2005 ¹³ | Left side of anterior and posterior part of hard palate | 17/M | 5x3 | INA |
| Saurabh Varshney/2007 ⁶ | Left side of maxilla | 15/M | 4x3 | INA |
| Vikas Prasad B/2008 ¹⁴ | Left side of Anterior and posterior maxilla | 18/M | 12 x 8 | No recurrence after 1 year |
| Gupta A/2009 ¹ | Posterior part of hard palate | 30/M | 5x3 | INA |
| Rafiq Pamori/2011 ¹⁵ | Right side of maxilla | 16/F | 6x6 | INA |

Figure 10: Data of Ewing's sarcoma cases obtained from the English literature

neck region and may result in long-term survival.^[14] The prognosis of ES is poor because hematogenous spread and lung metastases occur within a few months after diagnosis, although the tumor burden is considered today as an important factor of prognosis.^[2,9,19,20] Systemic disease is the most important predictive factor towards disease-free survival followed by the clinical response to chemotherapy.^[21]

CONCLUSION

We have described a rare case of ES of maxilla showing excessive fibro-osseous response which is not a frequent presentation. Because of its high metastatic potential, the patient died after four years. Therefore ES demands early intervention. Evaluation of lesion using plain radiographs, CT, MRI, biopsy followed by histopathology and immunohistochemistry are necessary for early diagnosis.

REFERENCES

- Gupta S, Gupta OP, Mehrotra S, Mehrotra D. Ewing sarcoma of maxilla: A rare presentation. *Quintessence Int* 2009;40:135-40.
- Ross KA, Smyth NA, Murawski CD, Kennedy JG. The biology of ewing sarcoma. *ISRN Oncol* 2013;2013:759725. Doi: 10.1155/2013/759725. Epub 2013 Jan 10.
- Mukherjee A, Ray JG, Bhattacharya S, Deb T. Ewing's sarcoma of mandible: A case report and review of Indian literature. *Contemp Clin Dent* 2012;3:494-8.
- Kawabata M, Yoshifuku K, Sagara Y, Kuroki Y. Ewing's sarcoma/primitive neuroectodermal tumour occurring in the maxillary sinus. *Rhinology* 2008;46:75-8.
- Kaler AK, Sheriff S. Primary ewing's sarcoma of the paranasal sinuses and orbit. *Innov J Med Health Sci* 2013;3:1-3.
- Varshney S, Bist SS, Gupta N, Bhatia R. Primary extraskelatal Ewing's sarcoma of the maxilla with intraorbital extension. *Indian J Otolaryngol Head Neck Surg* 2007;59:273-6.
- Hafezi S, Seethala RR, Stelow EB, Mills SE, Leong IT, MacDuff E, et al. Ewing's family of tumors of the sinonasal tract and maxillary bone. *Head Neck Pathol* 2011;5:8-16.
- Allam A, El-Husseiny G, Khafaga Y, Kandil A, Gray A, Ezzat A, et al. Ewing's sarcoma of the head and neck: A retrospective analysis of 24 cases. *Sarcoma* 1999;3:11-5.

9. Regezi JA, Scubba JJ. Oral Pathology: Clinical Pathology Correlation. 3rd ed. Philadelphia: Saunders. p. 407- 9.
10. Roca AN, Smith JL, MacComb WS, Jing BS. Ewing's sarcoma of the maxilla and mandible. *Oral Surg* 1968;25:194-203.
11. Amin MN, Islam KM, Ahmed AN, Datta PG, Amin AS, Abdullah M. Ewing's sarcoma of maxilla: A case report. *Bangladesh Med Res Counc Bull* 1990;16:42-5.
12. Wexler LH, Kacker A, Piro JD, Haddad J Jr, Close LG. Combined modality treatment of Ewing's sarcoma of the maxilla. *Head Neck* 2003;25:168-72.
13. Infante-Cossio P, Guiterrez-Perez JL, Garcia-Perla A, Noguer-mediavilla M, Gavilan-arrasco F. Primary Ewing's sarcoma of the maxilla and zygoma: Report of a case. *J Oral Maxillofac Surg* 2005;63:1539-42.
14. Vikas Prasad B, Ahmed Mujib BR, Bastian TS, David Tauro P. Ewing's sarcoma of the maxilla. *Indian J Dent Res* 2008;19:66-9.
15. Pampori R, Shamas I, Malik A. Ewings sarcoma of maxilla: A case report. *JPMI* 2011;25:171-4.
16. Lopes SL, Almeida SM, Costa AL, Zanardi VA, Cendes F. Imaging findings of Ewing's sarcoma in the mandible. *J Oral Sci* 2007;49:167-71.
17. Coskun BU, Cinar U, Savk H, Basak T, Dadas B. Isolated maxillary sinus Ewing's sarcoma. *Rhinology* 2005;43:225-8.
18. Fiorillo A, Tranfa F, Canale G, Fariello I, D'Amore R, De Chiara C, et al. Primary Ewing's sarcoma of the maxilla, a rare and curable localization: Report of two new cases, successfully treated by radiotherapy and systemic chemotherapy. *Cancer Lett* 1996;103:177-82.
19. Davido N, Rigolet A, Kerner S, Gruffaz F, Boucher Y. Case of Ewing's sarcoma misdiagnosed as a periapical lesion of maxillary incisor. *J Endod* 2011;37:259-64.
20. Brazão-Silva MT, Fernandes AV, Faria PR, Cardoso SV, Loyola AM. Ewing's sarcoma of the mandible in a young child. *Braz Dent J* 2010;21:74-9.
21. Zheng P, Lu X, Zheng K. Ewing's sarcoma of the maxilla. *Chin Med J (Engl)* 1998;111:377-8.

How to cite this article: Jairamdas Nagpal DK, Prabhu PR, Palaskar SJ, Patil S. Ewing's sarcoma of maxilla: A rare case report. *J Oral Maxillofac Pathol* 2014;18:251-5.

Source of Support: Nil. **Conflict of Interest:** None declared.

Author Help: Reference checking facility

The manuscript system (www.journalonweb.com) allows the authors to check and verify the accuracy and style of references. The tool checks the references with PubMed as per a predefined style. Authors are encouraged to use this facility, before submitting articles to the journal.

- The style as well as bibliographic elements should be 100% accurate, to help get the references verified from the system. Even a single spelling error or addition of issue number/month of publication will lead to an error when verifying the reference.
- Example of a correct style
Sheahan P, O'leary G, Lee G, Fitzgibbon J. Cystic cervical metastases: Incidence and diagnosis using fine needle aspiration biopsy. *Otolaryngol Head Neck Surg* 2002;127:294-8.
- Only the references from journals indexed in PubMed will be checked.
- Enter each reference in new line, without a serial number.
- Add up to a maximum of 15 references at a time.
- If the reference is correct for its bibliographic elements and punctuations, it will be shown as CORRECT and a link to the correct article in PubMed will be given.
- If any of the bibliographic elements are missing, incorrect or extra (such as issue number), it will be shown as INCORRECT and link to possible articles in PubMed will be given.