

ORIGINAL ARTICLE

Biliary architecture of livers exhibiting right-sided ligamentum teres: an indication for preoperative cholangiography prior to major hepatectomy

Ryuta Nishitai¹, Junichi Shindoh^{2,3}, Toshihide Yamaoka⁴, Masaaki Akahane⁵, Norihiro Kokudo³ & Dai Manaka¹

¹Department of Surgery, Kyoto-Katsura Hospital, ²Hepatobiliary-Pancreatic Surgery Division, Department of Digestive Surgery, Toranomon Hospital, ³Hepatobiliary-Pancreatic Surgery Division, Department of Surgery, Graduate School of Medicine, University of Tokyo, ⁴Department of Diagnostic Imaging and Interventional Radiology, Kyoto-Katsura Hospital, and ⁵Department of Radiology, NTT Medical Center Tokyo, Japan

Abstract

Objective: To obtain information about the basic biliary anatomy of livers with right-sided ligamentum teres (RSLT).

Summary of background data: RSLT is a relatively rare anomaly with a reported incidence of 0.2–1.2%. Although the portal/hepatic venous and arterial anatomy of livers with RSLT has already been established, the biliary architecture of such livers remains unclear.

Methods: RSLT was detected in 48 patients during 12,071 consecutive image readings (0.4%). Of these patients, the cholangiograms of 46 patients were analyzed, and their intrahepatic biliary tree confluence patterns were classified.

Results: The following four unique biliary confluence patterns were identified in livers with RSLT: the symmetrical type (23/46), independent right lateral type (13/46), total left type (6/46), and total right type (1/46). Analyses of the portal and arterial branching patterns of these livers showed that there were no correlations between their biliary confluence patterns and their portal or arterial ramification patterns.

Conclusion: The basic biliary architecture of livers with RSLT was clarified. As the RSLT patients' anomalous biliary confluences differed from those seen in normal livers and were difficult to predict, preoperative cholangiography should be performed prior to complex hepatobiliary surgery involving livers with RSLT to ensure patient safety.

Received 8 June 2016; accepted 3 August 2016

Correspondence

Ryuta Nishitai, Department of Surgery, Kyoto-Katsura Hospital, 17 Yamada-Hirao, Nishikyo, Kyoto, 615-8256, Japan. Tel: +81 75 391 5811. Fax: +81 75 381 4224. E-mail: rnishi@katsura.com

Introduction

Right-sided ligamentum teres (RSLT) is a relatively rare congenital anomaly in which the fetal umbilical vein is connected to the right paramedian trunk of the portal vein; however, it can have clinically important implications for hepatobiliary surgery.^{1,2} RSLT is sometimes encountered during cholecystectomy

The concept of this study was presented at the 12th World Congress of the International Hepato-Pancreato-Biliary Association (abstract: A-754-0023-01332).

These authors contributed equally to this work.

or hepatobiliary surgery and has a reported prevalence of 0.2%–1.2% in the adult population.^{3,4} As this anomaly results in a right-sided dominant distribution of the portal veins, the segmental anatomy of adult livers with RSLT exhibits “extreme right-side dominance”, even though the external appearance of the liver is similar to that of a normal liver, except for the reversed positions and a small gap between the gallbladder and the ligamentum teres.¹ (Fig. 1a).

Shindoh *et al.* previously reported that the symmetrical configuration of the portal/hepatic venous systems and the segmental anatomy seen in the early stages of hepatic

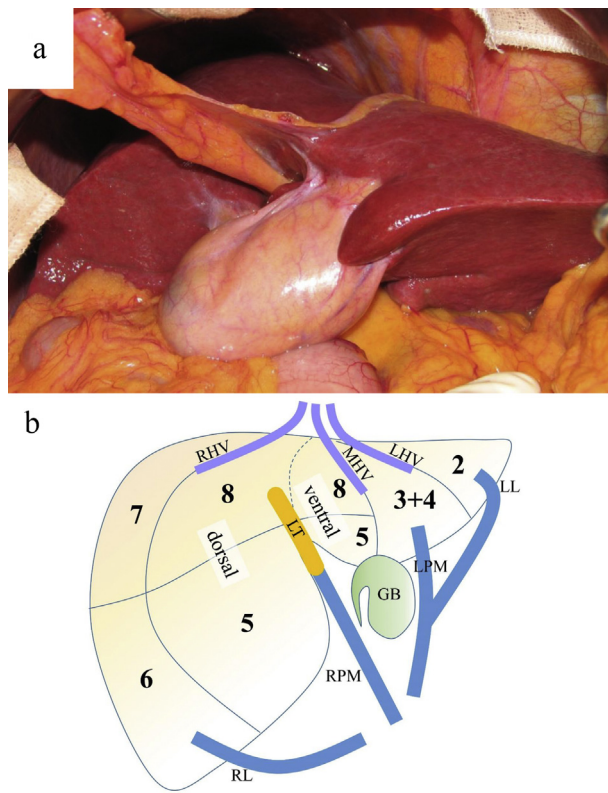


Figure 1 a) The appearance of a liver with right-sided ligamentum teres. Please note the reversed anatomy and the small gap between the ligamentum teres and gallbladder. b) A scheme of the relationships between hepatic segments and anatomical landmarks. RHV: right hepatic vein, MHV: middle hepatic vein, LHV: left hepatic vein, GB: gallbladder, LT: ligamentum teres, RL: right lateral portal vein, RPM: right para-median portal vein, LPM: left para-median portal vein, LL: left lateral portal vein

development are well preserved in adult livers with RSLT, as they are in normal livers.^{1,5} (Fig. 1b) Thus, in RSLT livers the basic vascular architecture of the portal vein, hepatic vein, and hepatic artery are established according to the developmental anatomy of the liver.¹ However, the anatomical characteristics of the biliary system in RSLT livers are not yet fully understood because of the difficulty of evaluating the confluence patterns of the biliary tree on computed tomography (CT) images. It is important to understand the anatomy of the intrahepatic biliary tree because several clinically critical variations in biliary anatomy have been reported in patients with RSLT, which could cause serious biliary injuries or complications during major hepatectomy.^{6–10} Given the increasing requirements for precise understanding of the anatomical variations of the liver in the era of aggressive surgical approaches, this study sought to clarify the biliary anatomy of livers with RSLT to improve the safety of complex hepatobiliary surgery.

Methods

Screening and study population

Radiological screening for RSLT was basically performed using axial CT images. RSLT was suspected when one of the following findings was encountered during the initial CT screening: a strong deviation of the umbilical portion towards the right, a lack of liver parenchyma between the gallbladder and the umbilical portion, or a deeply fissured groove for the ligamentum venosum near the level of the portal bifurcation.¹ Then, the three-dimensional (3D) portal-hepatic venous relationship was examined using CT, 3D-CT, and magnetic resonance imaging (MRI) to obtain a definitive diagnosis of RSLT, as described previously.^{1,11} First, the right lateral portal pedicle (Sg. 6 + 7) was identified. Then, the right hepatic vein (RHV) was identified by searching for a prominent vein that ran along the intersectoral plane of the right posterior sector. The right paramedian portal pedicle (Sg. 5 + 8), which is another significant branch, was then found next to the border of the drainage area of the RHV. The middle hepatic vein (MHV) was located on the left surface of the right anterior sector, and the midplane of the liver was finally identified. The ligamentum teres was then sought as a cord-like fatty structure with an occluded umbilical vein at its center that connected to the portal vein in a cleft of liver parenchyma. RLST was diagnosed when the connection of the ligamentum teres to the portal vein (the umbilical portion) was located on the right side of the midplane of the liver.

The study population was derived from two sets of clinical general radiology databases (rather than from hepatobiliary pancreatic directed radiology databases). Based on the 8050 consecutive image readings performed by M.A. at the University of Tokyo Hospital between May 2002 and January 2009, 35 patients were diagnosed with RSLT (0.4%), and their images were used for vascular analysis in a previous study.¹ Of these, the appropriate intrahepatic biliary tree radiological information was available for 33 patients. Based on the consecutive screenings performed by R.N. and T.Y. of 4021 patients who underwent magnetic resonance cholangiopancreatography (MRCP) at Kyoto Katsura Hospital between January 2006 and August 2015, 13 patients (0.3%) were diagnosed with RSLT. The diagnoses of the 46 patients were re-confirmed by R.N., J.S., T.Y. and M.A., and the biliary anatomy of the 46 patients was studied in detail using CT and MRCP.

Terminology and anatomical classification

Couinaud's conventional terms "sector" and "segment",¹² as defined in the addendum in *The Brisbane 2000 Terminology of Liver Anatomy and Resections*,¹³ were used to describe the basic structure of the liver. (http://www.ihpba.org/myHPBA/92_Liver-Resection-Guidelines.html). The segmental anatomy and portal/hepatic venous anatomy of the livers with RSLT were defined according to Shindoh's classification.¹

Portal ramification patterns were classified into three types: the independent right lateral type, bifurcation type, and trifurcation type, according to Shindoh's classification (Fig. 2). Arterial branching patterns were also classified according to Shindoh's classification (Fig. 3). Briefly, type 1 indicates an independent ramification of the left hepatic artery, type 2 refers to the formation of a common trunk for the left hepatic artery and the ventral branch of the right anterior sector (Sg. 5 + 8 ventral, Fig. 1b), and type 3 involves the replacement of the left hepatic artery by the left gastric artery. The biliary branches were named according to the segment they drained, as viewed on 3-D images. The correlations between the patterns of biliary confluence and portal/arterial ramification were analyzed in the evaluable patients.

Data analysis

Clinical data were recorded in an Excel 2013 (Microsoft) spreadsheet and analyzed using the statistical software JMP Pro 11.0 (SAS Institute Japan). All of the analyses conducted in the present study were performed in accordance with the ethical guidelines for clinical studies of each institution.

Results

Overview

The overall incidence of RSLT was 0.40% (48/12071). Of the RSLT-positive patients, the images of 46 patients were analyzed in this study. The incidence rates of the three portal ramification types were 27/46 for the independent right lateral type, 10/46 for the bifurcation type, and 9/46 for the trifurcation type. As for the hepatic veins, no anomalous confluences were observed.

Patterns of biliary confluence

Four distinct confluence patterns were identified during the biliary screening of the 46 patients' images (Figs 4,5).

The "symmetrical type" was observed in 26 patients. The right umbilical portion (rUP) always indicates the watershed of the biliary drainage territory for the right or left hepatic duct in this biliary confluence pattern. Based on the segmental anatomy of RSLT livers, the right hepatic duct drains the right posterior sector (Sg. 6 + 7) plus the dorsal part of the right anterior sector (Sg. 5 + 8 dorsal, Fig. 1b), and the left hepatic duct drains the

ventral part of the right anterior sector (Sg. 5 + 8 ventral, Fig. 1b) plus the left hemiliver (Figs 4a,5a).

The "independent right lateral type" was observed in 13 patients. The entire right anterior sector (Sg. 5 + 8) is drained by the left hepatic duct in this variation (Figs 4b,5b).

The "total left type" was observed in 6 patients. In this pattern, the entire right hemiliver is drained by a thick biliary branch, which is connected to the left biliary branch, passes across the umbilical fissure towards the left and backwards to the rUP (Figs 4c-1,5c). This pattern includes a minor variation in which a small independent branch from the right anterior sector (Sg. 5 dorsal, Fig. 1b) drains directly into the common hepatic duct (Fig. 4c-2).

The "total right type" was only observed in one patient. In this pattern, the entire left hemiliver is drained by a thick biliary branch that passes across the umbilical fissure towards the right (Figs 4d,5d).

The bile ducts of the caudal segment (Sg. 1) were usually thin and difficult to detect on MRCP images. The caudal bile ducts were not included in this classification because of the inconsistent results of the image readings.

Relationships with portal or arterial branching patterns

Fig. 6 shows the correlations between each biliary confluence type and the portal/arterial branching patterns. The independent right lateral portal ramification and the type 1 arterial branching pattern were dominant in all biliary confluence types. No correlations were detected between the biliary confluence patterns and the portal or arterial ramification patterns.

Discussion

Several studies have reported experiences of major hepatectomy procedures involving livers with RSLT and urged caution regarding intrahepatic vascular anomalies.^{4,6-10,14-18} Most of these papers focused on portal variations in RSLT livers, but some papers provided information on intrahepatic biliary anomalies, which could have caused critical biliary complications.^{6,7,9,10,15,19} However, there has been no large-scale review of biliary architecture, nor any attempt to classify biliary confluence patterns in livers with RSLT.

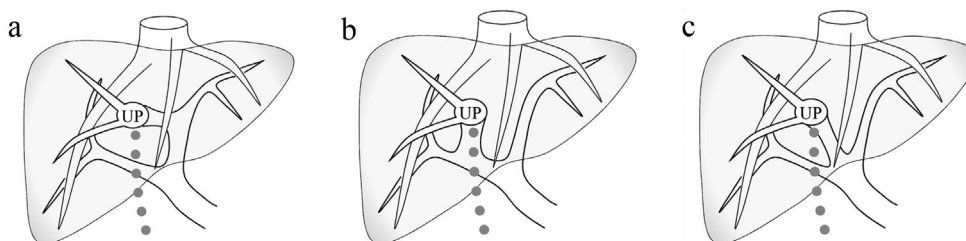


Figure 2 A classification of intrahepatic portal ramification patterns.¹ a) Shindoh's independent right lateral type, b) bifurcation type, c) trifurcation type

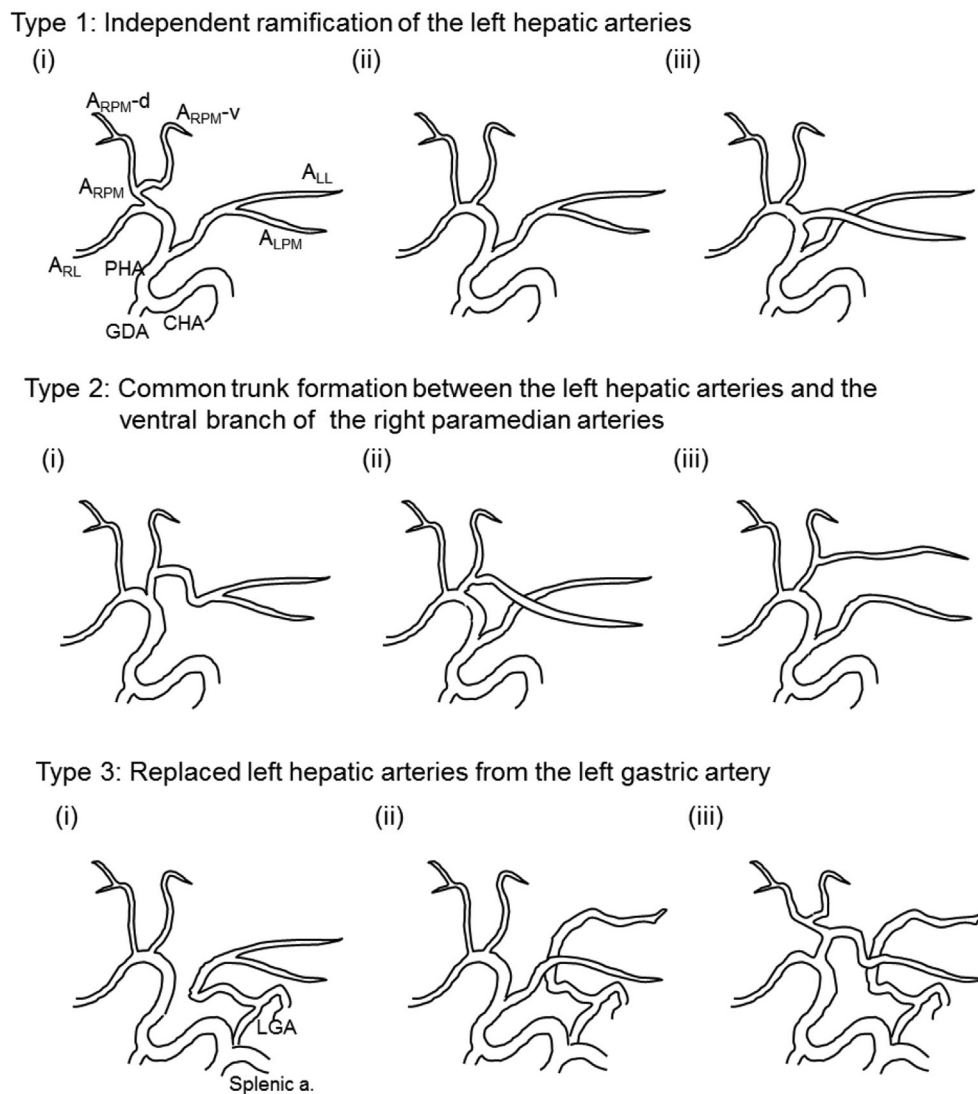


Figure 3 Shindoh's classification of intrahepatic arterial ramification patterns.¹ The major three types are classified based on the position of the left hepatic artery

In this study, four distinct biliary confluence patterns were identified based on the detailed screening of 46 livers with RSLT. A literature review extracted 12 relevant images of the intrahepatic biliary tree from nine papers, which confirmed that this basic biliary classification applies to most RSLT patients.^{3,6-9,15,19-21} Based on these images, information about the risk of biliary injuries has been provided for the following three types of formal hepatectomy.

1 Resection of the right hemiliver can be performed safely in most patients except for the rare total right biliary type, although right hemihepatectomy is rarely performed in RSLT patients because of the extremely small volume of the remnant left hemiliver.¹

2 Left hemihepatectomy may lead to biliary injuries of the right anterior bile ducts (Sg. 5 + 8) in patients involving the independent right lateral biliary type, whereas it can damage all of the branches of the remnant right hemiliver in patients involving the total left type.

3 Right anterior sectorectomy carries a risk of injuring the right posterior bile ducts (Sg. 6 + 7) in patients involving the total left type, whereas it can damage the left hepatic duct in patients involving the total right type.

As the independent right lateral and the total left biliary types are not rare, it is important to be aware of the patient's intrahepatic biliary confluence pattern in cases in which formal hepatectomies are planned for patients with RSLT.

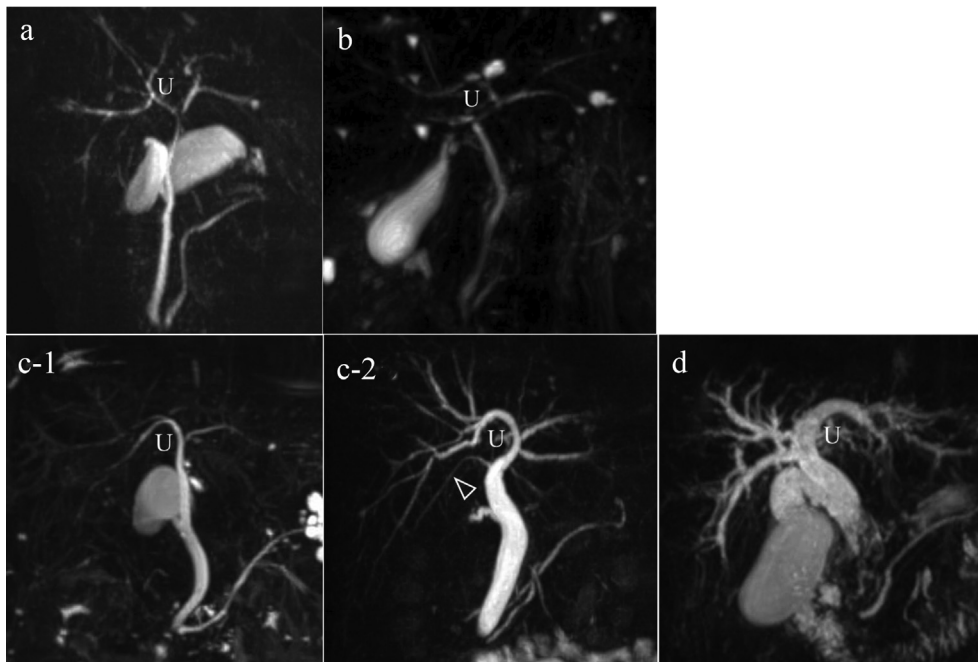


Figure 4 Typical MRCP images of the intrahepatic bile ducts of RSLT livers. a) Symmetrical type; b) independent right lateral type; c-1) total left type; c-2) a frequent variation of the total left type, in which an independent branch drained a minor area of the right anterior segment (Sg 5) (arrow); d) total right type

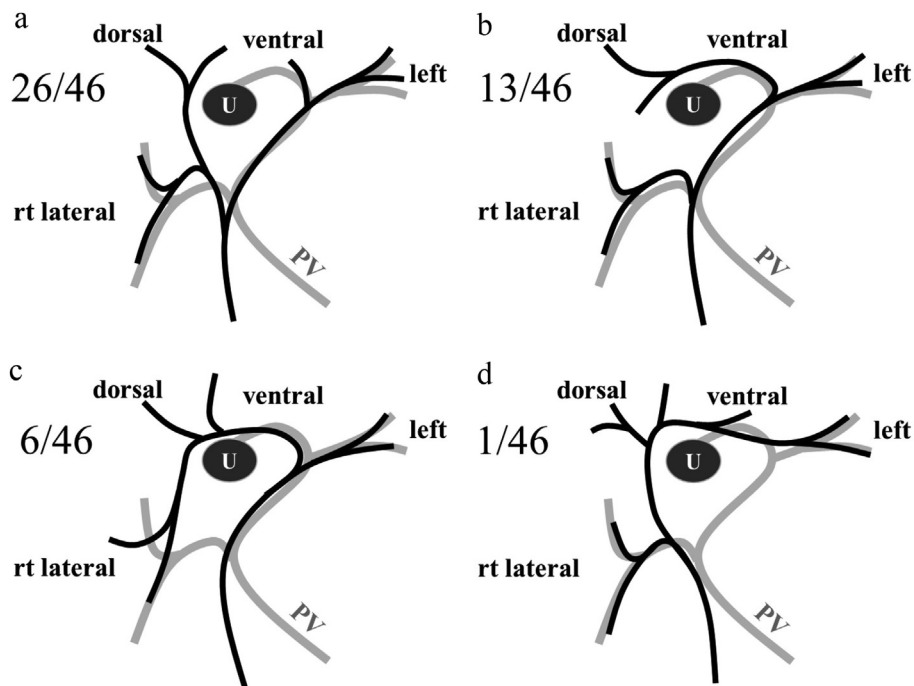


Figure 5 Scheme of the intrahepatic bile duct confluence patterns seen in RSLT livers. “U” indicates the right umbilical portion, and the gray line represents the intrahepatic portal vein. a) Symmetrical type, b) independent right lateral type, c) total left type, d) total right type

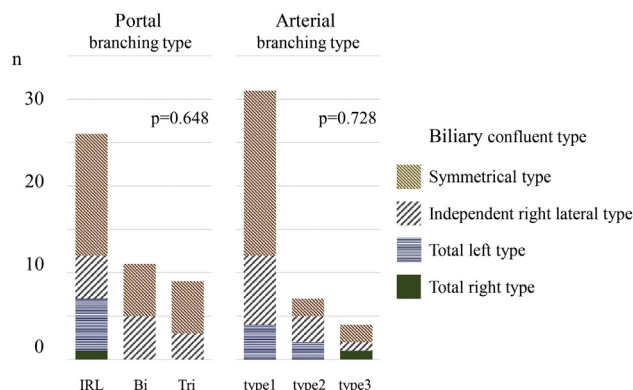


Figure 6 Correlations between each biliary confluence type and portal/arterial ramification patterns. No significant correlations between biliary type and portal/arterial type were detected. IRL: independent right lateral type, Bi: bifurcation type, Tri: trifurcation type. Arterial branching patterns were studied in 42 out of 46 patients (the evaluable patients)

In the present study, simultaneous analysis of portal/arterial branching patterns and biliary confluence patterns revealed that there were no specific relationships among the patterns of the biliary, portal, and arterial trees of RSLT livers. Although the total left and total right biliary types were solely identified in independent right lateral portal type livers in the current study, it was not possible to predict the biliary confluence pattern from the portal ramification pattern because the sample number was limited, and no significant correlations were detected between the portal and biliary types. One of the most noteworthy results of this study is that the biliary confluence patterns of livers with RSLT are difficult to predict based on basic knowledge about the normal anatomy of the liver, and no other anatomical clues to the biliary confluence patterns of livers with RSLT, including clues based on the branching patterns of other intrahepatic vascular structures, are known to exist. Although the external morphology of RSLT livers is similar to that of normal livers, the biliary branches cross the umbilical fissure in the opposite direction (i.e., from right to left versus from left to right) in approximately two-fifths of patients (those that exhibit the independent right lateral type and total left type patterns). Given that there are no anatomical clues that can be used to predict biliary confluence patterns, and that there are marked differences in the distributions of intrahepatic vascular structures between RSLT and normal livers, intraoperative examinations of the biliary tree that are conducted immediately before the incision of the hepatic hilar plate might be confusing and could increase the operative time and/or lead to biliary complications. Thus, preoperative evaluations of the intrahepatic biliary system are recommended in order to prevent biliary injuries.

The first step in the preoperative diagnosis of RSLT is to suspect the condition. Strong *et al.* pointed out that many RSLT patients who experienced postoperative morbidity had not been

diagnosed with RSLT until the operation.¹⁰ As was mentioned in the Methods section, livers with RSLT exhibit several characteristics on axial CT images. Radiologists and surgeons should keep this anomaly in mind so that they do not overlook such findings.

The next step is to evaluate the intrahepatic bile ducts. In most patients, CT alone is not sufficient for assessing biliary anatomy as it is depicted less clearly on CT than on cholangiography. Instead, MRCP is recommended as the first-line tool because it is more widely available and safer than retrograde cholangiography, and MRCP is able to detect upstream bile ducts even in cases involving biliary obstruction. It is worth noting that the use of cholangiography alone can sometimes lead to misunderstandings. MRCP images of the symmetrical and total left types can exhibit similar findings to those of the typical biliary trees of normal livers if one is not aware of the existence of RSLT. (Fig. 4a,c-1). Fusion images composed of MRCP and 3-D CT images are considered to be particularly effective for evaluating the 3-D relationships between the portal veins and bile ducts and fully understanding biliary anomalies.

This study had several limitations. First, it was based on the examination of a limited number of livers with RSLT; therefore, it is likely that the classification outlined in this study does not cover rare variations. Another limitation is that 42 of the 46 patients in this study did not undergo hepatectomy, and the study was based on image readings instead of solid liver specimens. Thus, caudal segments and some small branches of the portal vein or bile ducts that drain small segments might have been overlooked. In addition, the actual incidence of biliary injuries related to RSLT is not known. Despite all of these limitations, this study is still considered to provide a “basic platform” for future studies of the biliary anatomy of livers with RSLT.

While a prospective study of the intrahepatic vascular anatomy of RSLT livers would be difficult, the current study provides a good beginning and is based on the largest number of patients of RSLT detected among 12,071 image readings. The incidence of 0.40% (48/12,071) detected in the current study seems to be compatible with the reported incidence of RSLT during neonatal ultrasonography (0.08–0.46%)^{22–28} and the prevalence of the condition in the adult population.^{4,14,15,29} To compare and discuss various observations about the anatomy of the liver, clear definitions and knowledge about basic vascular anatomy are required. The current results will contribute to the establishment of a “basic” intrahepatic vascular architecture for livers with RSLT, and hence, offer important information for anatomical validation studies.

In conclusion, the basic biliary architecture of livers with RSLT was clarified through detailed analyses of 46 patients. As the anomalous biliary confluence patterns of RSLT livers are difficult to predict based on basic knowledge of the normal anatomy of the liver and other intrahepatic vascular structures, preoperative cholangiography is indispensable for ensuring patient safety during formal hepatectomies and complex hepatobiliary surgery involving livers with RSLT.

Funding sources

None.

Conflicts of interest

None to declare.

References

- Shindoh J, Akahane M, Satou S, Aoki T, Beck Y, Hasegawa K *et al.* (2012) Vascular architecture in anomalous right-sided ligamentum teres: three-dimensional analyses in 35 patients. *HPB* 14:32–41.
- Kawai K, Koizumi M, Honma S, Tokiyoshi A, Kodama K. (2008) Right ligamentum teres joining to the right branch of the portal vein. *Anat Sci Int* 83:49–54.
- Maetani Y, Itoh K, Kojima N, Tabuchi T, Shibata T, Asonuma K *et al.* (1998) Portal vein anomaly associated with deviation of the ligamentum teres to the right and malposition of the gallbladder. *Radiology* 207: 723–728.
- Nagai M, Kubota K, Kawasaki S, Takayama T, Bandai Y, Makuuchi M. (1997) Are left-sided gallbladders really located on the left side? *Ann Surg* 225:274–280.
- Shindoh J, Satou S, Aoki T, Beck Y, Hasegawa K, Sugawara Y *et al.* (2012) Hidden symmetry in asymmetric morphology: significance of Hjortsjo's anatomical model in liver surgery. *Hepatogastroenterology* 59:519–525.
- Abe T, Kajiyama K, Harimoto N, Gion T, Shirabe K, Nagaie T. (2012) Resection of metastatic liver cancer in a patient with a left-sided gallbladder and intrahepatic portal vein and bile duct anomalies: a case report. *Int J Surg Case Rep* 3:147–150.
- Almodhaiberi H, Hwang S, Cho YJ, Kwon Y, Jung BH, Kim MH. (2015) Customized left-sided hepatectomy and bile duct resection for perihilar cholangiocarcinoma in a patient with left-sided gallbladder and multiple combined anomalies. *Korean J Hepatobiliary Pancreat Surg* 19:30–34.
- Hiei K, Nimura Y, Nagino M, Kamiya J, Kondo S, Toyoda S *et al.* (1995) Resection of metastatic liver cancer in a patient with an anomalous intrahepatic portal system: a case report. *Hepatogastroenterology* 42: 1002–1007.
- Kaneoka Y, Yamaguchi A, Isogai M, Harada T. (2000) Hepatectomy for cholangiocarcinoma complicated with right umbilical portion: anomalous configuration of the intrahepatic biliary tree. *J Hepatobiliary Pancreat Surg* 7:321–326.
- Strong RW, Fawcett J, Hatzifotis M, Hodgkinson P, Lynch S, O'Rourke T *et al.* (2013) Surgical implications of a left-sided gallbladder. *Am J Surg* 206:59–63.
- Shindoh J, Satou S, Aoki T, Kawaguchi Y, Beck Y, Sugawara Y *et al.* (2012) Step-by-step vascular naming algorithms for a precise understanding of major anomalies in the liver. *Hepatogastroenterology* 59: 511–514.
- Couinaud C. (1989) *Surgical anatomy of the liver revisited*. Paris, France: Couinaud.
- Terminology Committee of the International Hepato-Pancreato-Biliary Association. (2000) The Brisbane 2000 terminology of liver anatomy and resections. *HPB* 2:333–339.
- Asonuma K, Shapiro AM, Inomata Y, Uryuhara K, Uemoto S, Tanaka K. (1999) Living related liver transplantation from donors with the left-sided gallbladder/portal vein anomaly. *Transplantation* 68:1610–1612.
- Hwang S, Lee SG, Park KM, Lee YJ, Ahn CS, Kim KH *et al.* (2004) Hepatectomy of living donors with a left-sided gallbladder and multiple combined anomalies for adult-to-adult living donor liver transplantation. *Liver Transpl* 10:141–146.
- Rocca JP, Rodriguez-Davalos MI, Burke-Davis M, Marvin MR, Sheiner PA, Facchiuto ME. (2006) Living-donor hepatectomy in right-sided round-ligament liver: importance of mapping the anatomy to the left medial segment. *J Hepatobiliary Pancreat Surg* 13:454–457.
- Shimizu T, Hayashi M, Inoue Y, Komeda K, Asakuma M, Hirokawa F *et al.* (2012) Living-donor liver transplantation from donor with a left-sided gallbladder with portal vein anomaly. *Transplantation* 94:e60–e61.
- Matsumoto T, Aoki T, Iso Y, Tago K, Shimoda M, Kubota K. (2016) Successful right hemihepatectomy for a patient with right-sided round ligament. *J Gastrointest Surg* 20:470–472.
- Regimbeau JM, Panis Y, Couinaud C, Kardache M, Pocard M, Brouland JP *et al.* (2003) Sinistroposition of the gallbladder and the common bile duct. *Hepatogastroenterology* 50:60–61.
- Matsumura N, Tokumura H, Yasumoto A, Sasaki H, Yamasaki M, Musya H *et al.* (2009) Laparoscopic cholecystectomy and common bile duct exploration for cholecystocholedocholithiasis with a left-sided gallbladder: report of a case. *Surg Today* 39:252–255.
- Namikawa T, Tamura K, Morita M, Tamura S, Maeda H, Kobayashi M *et al.* (2015) Laparoscopic cholecystectomy for a patient with left-sided gallbladder. *Surg Technol Int* 26:120–123.
- Blazer S, Zimmer EZ, Bronshtein M. (2000) Persistent intrahepatic right umbilical vein in the fetus: a benign anatomic variant. *Obstet Gynecol* 95:433–436.
- Hill LM, Mills A, Peterson C, Boyles D. (1994) Persistent right umbilical vein: sonographic detection and subsequent neonatal outcome. *Obstet Gynecol* 84:923–925.
- Martinez R, Gamez F, Bravo C, Sanchez P, Orizales C, Ortiz L *et al.* (2013) Perinatal outcome after ultrasound prenatal diagnosis of persistent right umbilical vein. *Eur J Obstet Gynecol Reprod Biol* 168: 36–39.
- Nakanishi S, Shiraki K, Yamamoto K, Koyama M, Nakano T. (2005) An anomaly in persistent right umbilical vein of portal vein diagnosed by ultrasonography. *World J Gastroenterol* 11:1179–1181.
- Weichert J, Hartge D, Germer U, Axt-Fliedner R, Gembruch U. (2011) Persistent right umbilical vein: a prenatal condition worth mentioning? *Ultrasound Obstet Gynecol* 37:543–548.
- Wolman I, Gull I, Fait G, Amster R, Kupfermanc MJ, Lessing JB *et al.* (2002) Persistent right umbilical vein: incidence and significance. *Ultrasound Obstet Gynecol* 19:562–564.
- Yang PY, Wu JL, Yeh GP, Chou PH, Hsu JC, Hsieh CT. (2007) Prenatal diagnosis of persistent right umbilical vein using three-dimensional sonography with power Doppler. *Taiwan J Obstet Gynecol* 46:43–46.
- Hsu SL, Chen TY, Huang TL, Sun CK, Concejero AM, Tsang LL *et al.* (2007) Left-sided gallbladder: its clinical significance and imaging presentations. *World J Gastroenterol* 13:6404–6409.