

# Analysis of Fibular Single Graft and Fibular Double-barrel Graft for Mandibular Reconstruction

Naohiro Ishii, MD\*  
Yusuke Shimizu, MD, PhD†  
Jyun Ihara, MD‡  
Kazuo Kishi, MD, PhD‡

**Background:** High-quality mandibular reconstruction using vascularized free fibular graft is necessary to provide an osseointegrated dental implant and fixed denture. An appropriate crown–implant ratio is needed, and a good match between bones is extremely important. There are no articles describing the analysis and evaluation of both the fibula and mandible in the same patients.

**Methods:** Computed tomography images of both mandible and fibula of 80 patients were selected in a random manner. We measured bone height of the fibula and mandible at specified points and evaluated the difference of bone height between the fibula and mandible using fibular single or double-barrel grafts.

**Results:** The percentage of patients who had a “good” result for a fibular single graft was only 13.8%. There was no significant difference in bone heights when analyzed by gender. Whether patients were dentulous or not had a large influence on the difference between fibular and mandibular bone heights. Most young patients, but only half of older patients, needed fibular double-barrel grafts. Overweight patients with a high body mass index more often needed fibular double-barrel grafts.

**Conclusions:** For mandibular reconstruction using a fibular graft, preoperative analysis of the patient’s profile and proper use of a fibular single or double-barrel graft contribute to minimizing the difference between the height of the grafted fibula and native mandible and are keys to an ideal reconstruction with good cosmetics and function. (*Plast Reconstr Surg Glob Open* 2016;4:e1018; doi: 10.1097/GOX.0000000000001018; Published online 17 August 2016.)

A vascularized free fibular flap is widely used as an excellent method to repair mandibular defects. Recently, higher quality mandibular reconstructions are necessary to place osseointegrated dental implants and provide an adequate superstructure for fixed implants. A vascularized free fibular graft of the appropriate size for the mandibular defect is required to provide an appropriate crown–implant ratio. The double-barrel technique can provide greater fibular height,<sup>1–3</sup> but excess volume is a problem particularly for alveolar bone reconstruction.<sup>4</sup>

Analyses of the morphology of the fibula and mandible have been reported by several authors. However, there are no articles describing the analysis and evaluation of both the fibula and mandible in the same patients as they relate to the proper use of fibular single or double-barrel grafts.

To perform an appropriate mandibular reconstruction using a fibular graft, measurement only of the fibula is not sufficient. Matching of both bones and quantitative evaluation of grafting is extremely important.

The purpose of our study is to measure and analyze the bone heights of both fibula and mandible in the same patients as a means to minimize the difference between the grafted fibula and native mandibular bone to provide an ideal reconstruction with good cosmetics and function.

## MATERIALS AND METHODS

### Materials

Computed tomography (CT) images of 80 patients who had received CT scanning of both mandible and fibula in the same day were selected randomly. Patients who

**Disclosure:** The authors have no financial interest to declare in relation to the content of this article. The Article Processing Charge was paid for by the authors.

From the \*Department of Plastic and Reconstructive Surgery, Tochigi Cancer Center, Tochigi, Japan; †Department of Plastic and Reconstructive Surgery, University of the Ryukyus Hospital, Okinawa, Japan; and ‡Department of Plastic and Reconstructive Surgery, Keio University, Tokyo, Japan.

Received for publication May 2, 2016; accepted July 8, 2016.

Copyright © 2016 The Authors. Published by Wolters Kluwer Health, Inc. on behalf of The American Society of Plastic Surgeons. All rights reserved. This is an open-access article distributed under the terms of the Creative Commons Attribution-Non Commercial-No Derivatives License 4.0 (CCBY-NC-ND), where it is permissible to download and share the work provided it is properly cited. The work cannot be changed in any way or used commercially.

DOI: 10.1097/GOX.0000000000001018

had sustained trauma to the mandible or fibula, or had a bone metabolic disease, were excluded. The patient population comprised 48 men (mean: 58.0 yr; range: 16–95 yr) and 32 women (mean: 56.4 yr; range: 17–89 yr). Fifteen of these patients were edentulous. Height (mean: 162.1; range 138–180), weight (mean: 59.2; range: 36–88), and body mass index (BMI) (mean: 22.4; range: 15.2–31.6) were collected. The patient population was divided by each demographic variable (gender, age, tooth, height, weight, and BMI) into 2 or 3 groups (Table 1).

**Measurement of Fibular and Mandibular Height**

First, fibular head and lateral malleolus were marked with reference to the coronal plane on the CT images. The length between the fibular head and the lateral malleolus was divided into 5 equal segments, and each of the dividing points from the lateral malleolus was denoted point A, B, C, or D. The lateral bone width in the axial plane was measured from CT images (Fig. 1A).

Then, the mental eminence on the median line of the mandible and the posterior aspect of the last molar near mandibular angle were marked with reference to the axial plane on the CT images. The length between the mental eminence (point a) and the posterior part of the last molar (point d) was divided into 3 equal segments, and each of the dividing points between segments was denoted as points b and c. The bone height along the anterior aspect of the mandible in the sagittal plane was measured from CT images (Fig. 1B).

According to recent research, the length between the fibular head and lateral malleolus is 25 cm on average, and the length between the mental eminence on the median line of the mandible and the posterior of the last molar near the mandibular angle is 7.5 cm on average.<sup>5</sup> Therefore, the length of 5 equal segments of the fibula is about 5 cm, and the length of 3 equal segments of the mandible is about 2.5 cm. For fibular single grafts, we decided that one segment of the fibula would be grafted for a defect of 2 segments of the mandible and measured the difference of height between the fibula and the mandible for these segments. For fibular double-barrel grafts, we decided that 2 segments of the fibula would be harvested and folded into a single segment and grafted into a defect of 2 segments of the mandible. Then, we measured the difference in height between the double-barrel fibular graft and the mandible.

As the pedicle is located on the medial aspect of the fibula, the reconstruction plate usually is fixed between the lateral aspect of the fibula and the anterior aspect of the mandible. Considering this, we decided that the lateral aspect of the fibula and the anterior aspect of the mandible would be points of measurement.

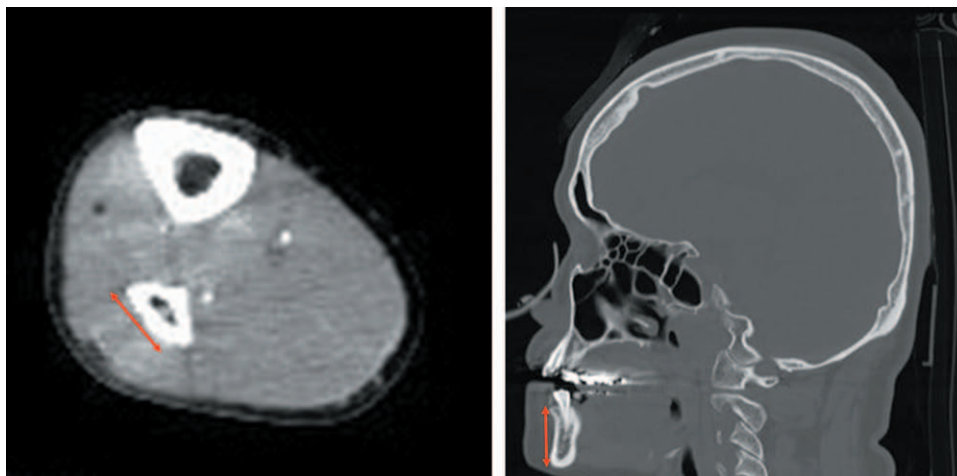
Measurement of the difference in bone height between the single fibula and mandible in a fibular single graft was performed in 4 ways (Fig. 2):

D1, 2, 3, 4: difference in bone height between the fibula and the mandible;

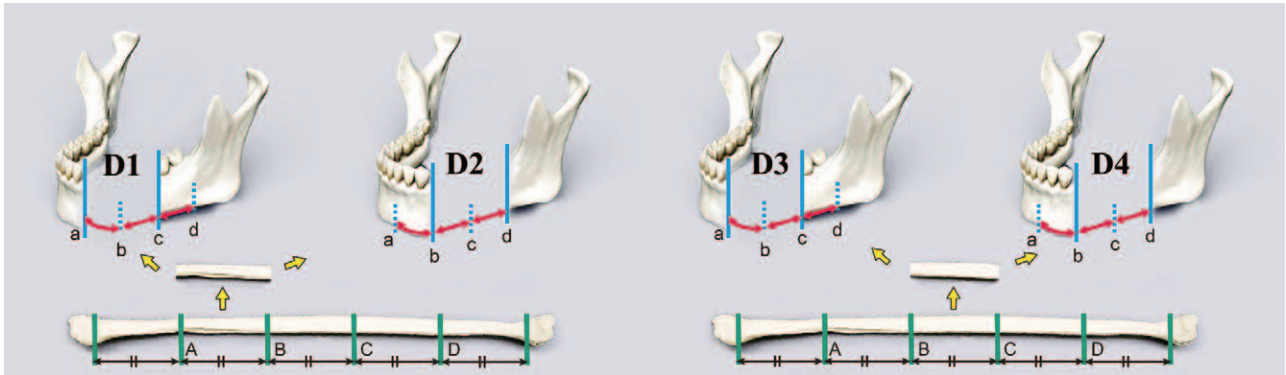
A, B, C, D, a, b, c, d: bone height at points A, B, C, D, a, b, c, d;

**Table 1. The Number of Patients in Each Category**

Category			
Gender	Male: 48	Female: 32	
Age (yr)	Young (16–39): 21	Middle (40–69): 31	Old (70–95): 28
Tooth	Dentulous: 65	Edentulous: 15	
Height (cm)	Short ( $\leq 155$ ): 22	Medium (156–169): 37	Tall ( $\geq 170$ ): 21
Weight (kg)	Light ( $\leq 50$ ): 25	Medium (51–65): 28	Heavy ( $\geq 66$ ): 27
BMI	Low ( $\leq 18.4$ ): 9	Medium (18.5–24.9): 58	High ( $\geq 25$ ): 13



**Fig. 1.** A, An arrow shows the lateral bone width in the axial plane as it was measured from CT images. B, An arrow shows the bone height along the anterior aspect of the mandible in the sagittal plane as it was measured from CT images.



**Fig. 2.** One segment of a single fibula replaced the defect of 2 segments of the mandible. The difference in bone height between the fibula and the mandible was measured in 4 different ways. Left, Grafting from the distal fibula (A–B) to the medial mandibular defect (a–c)/grafting from the distal fibula (A–B) to the lateral mandibular defect (b–d). Right, Grafting from the proximal fibula (B–C) to the medial mandibular defect (a–c)/grafting from the proximal fibula (B–C) to the lateral mandibular defect (points b–d). D1, 2, 3, 4, Measurement of the difference in bone height between the fibula and mandible.

- D1 = mean A, B – mean a, c;
- D2 = mean A, B – mean b, d;
- D3 = mean B, C – mean a, c;
- D4 = mean B, C – mean b, d.

**Evaluation of Fibular Single Graft**

We defined the difference in bone height appropriate for placing an osseointegrated dental implant that would provide suitable fixation for a fixed denture in a fibular single graft as  $D_a$  (–0.8 to 0.4cm). If  $D1-4 < D_a$ , it was considered “short”; if  $D1-4 = D_a$ , it was considered “good”; and if  $D1-4 > D_a$ , it was considered “over.” We did not evaluate the acceptable range of variation.

Data for D1–4 were compared by gender, age, height, weight, BMI, and whether the patient was dentulous or edentulous. Within the dentulous subsample, data were compared by age, gender, and BMI. Data for D1, D2 and D3, D4 were compared by donor site. Data for D1, D3 and D2, D4 were compared by recipient site.

The distribution of data for fibular single grafts was investigated by gender, age, BMI, and whether the patient

was dentulous or edentulous. Within the dentulous subsample, data were compared by age, gender, and BMI.

Measurement of the difference in bone height between the double-barrel fibula and mandible in a fibular double-barrel graft was performed in 4 ways (Fig. 3):

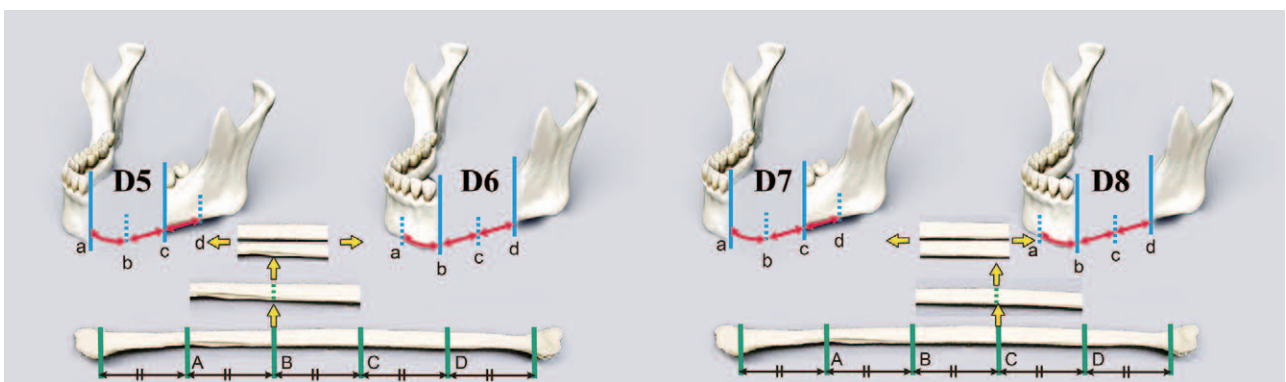
D5, 6, 7, 8: difference in bone height between the fibula and the mandible;

- D5 = mean A + C, B + B – mean a, c;
- D6 = mean A + C, B + B – mean b, d;
- D7 = mean B + D, C + C – mean a, c;
- D8 = mean B + D, C + C – mean b, d.

**Evaluation of Fibular Double-Barrel Graft**

We defined the difference in height appropriate for placing an osseointegrated dental implant that would provide suitable fixation for a fixed denture in a fibular double-barrel graft as  $D_b$  (–1.3 to 0.4cm). We categorized “short” as  $D5-8 < D_b$ , “good” as  $D5-8 = D_b$ , and “over” as  $D5-8 > D_b$ .

Data for D5–8 were compared by gender, age, height, weight, BMI, or whether the patient was dentulous or



**Fig. 3.** One segment of double-barrel fibula replaced a defect of 2 segments of the mandible. The difference in bone height between the double-barrel fibula and the mandible was measured in 4 different ways. Distal double-barrel fibular graft was double-folded at point B. Left, Grafting from the distal double-barrel fibula (A–C) to the medial mandibular defect (a–c). Right, Grafting from the distal double-barrel fibula (A–C) to the lateral mandibular defect (b–d). Proximal double-barrel fibular graft was double-folded at point C. Left, Grafting from the proximal double-barrel fibula (B–D) to the medial mandibular defect (a–c). Right, Grafting from the proximal double-barrel fibula (B–D) to the lateral mandibular defect (b–d). D5, 6, 7, 8, Measurement of the difference in bone height between the fibula and mandible.

edentulous. Within the subsample of dentulous patients, data were compared by age, gender, and BMI. Data from D5, D6 and from D7, D8 were compared by donor site. Data from D5, D7 and from D6, D8 were compared by recipient site.

The distribution of results for fibular double-barrel graft was investigated by gender, age, BMI, and whether the patient was dentulous or edentulous. Within the subsample of dentulous patients, data were compared by age, gender, and BMI.

**Statistics and Ethics**

Student’s *t* test and the Holm test were used to analyze differences in bone height between the fibula and the mandible in each category using SPSS (software for Windows, version 23). Chi-square tests and adjusted residual analysis were used to analyze the results of fibular graft in each category.

Our study was reviewed and accepted by the hospital ethics committee.

All study procedures were performed in accordance with the Declaration of Helsinki.

**RESULT**

The overall results are shown in Table 2. The percentage of patients who had a “good” result for a fibular single graft was only 13.8%. The percentage of patients who had a “good” result for a double-barrel graft was 70.9%.

Analysis of the difference in bone height of fibular single graft (D1–4) and fibular double-barrel graft (D5–8) by gender, age, height, weight, and BMI is shown in Figure 4. The difference in bone height for D1–4 and D5–8 was almost the same in each gender and was not significantly different for either fibular single graft or fibular double-barrel graft. The difference in height for D1–4 and D5–8 was larger in elderly patients than in younger patients. The difference in height for D1–4 was smaller in taller patients, and the difference in both D1–4 and D5–8 was smaller in heavier patients. The difference in height for D1–4 and D5–8 was smaller in patients with a higher BMI. The difference in bone height of fibular single graft and fibular double-barrel graft was significant for age, weight, and BMI. Only the difference in bone height of fibular single grafts varied significantly by an individual’s height.

Analysis of the difference in bone height of fibular single graft (D1–4) and fibular double-barrel graft (D5–8) by tooth and by gender, age, and BMI of dentulous patients is shown in Figure 5. The difference in height for D1–4 and D5–8 was much smaller in dentulous patients

and was almost the same in each gender of dentulous patients. The difference in bone height for D1–4 and D5–8 was larger in elderly patients who were dentulous and was smaller in patients with a higher BMI. Significant differences were found in bone height of fibular single grafts for tooth, age of dentulous patients, and BMI of dentulous patients. Significant differences were found in bone height of fibular double-barrel grafts for tooth and age of dentulous patients.

Analysis of the difference in bone height of fibular single graft (D1–4) and fibular double-barrel graft (D5–8) by donor site and recipient site is shown in Figure 6. The bone height of the fibular single graft harvested from the distal fibula was significantly smaller for D1–D4 than graft taken from other donor sites. The height for D5–8 was almost the same, regardless of donor site. The difference in height for D1–4 and D5–8 was almost the same regardless of recipient site and did not differ significantly.

Evaluation of fibular single graft and fibular double-barrel graft by gender, age, BMI, tooth, age of dentulous patients, and BMI of dentulous patients is shown in Figures 7 and 8. Fibular single grafts in males and females were statistically different, but fibular double-barrel grafts did not vary significantly by gender. Fibular single and fibular double-barrel grafts were significantly different in young and old patients. Fibular single grafts in low BMI subjects and fibular double-barrel grafts in both low and high BMI subjects were significantly different. Within both the dentulous and edentulous groups, both fibular single grafts and fibular double-barrel grafts were significantly different. Fibular single and fibular double-barrel grafts were significantly different in young and middle-aged dentulous patients. Fibular single grafts in dentulous patients with a medium BMI, and fibular double-barrel grafts in dentulous patients with a high BMI, were significantly different.

**DISCUSSION**

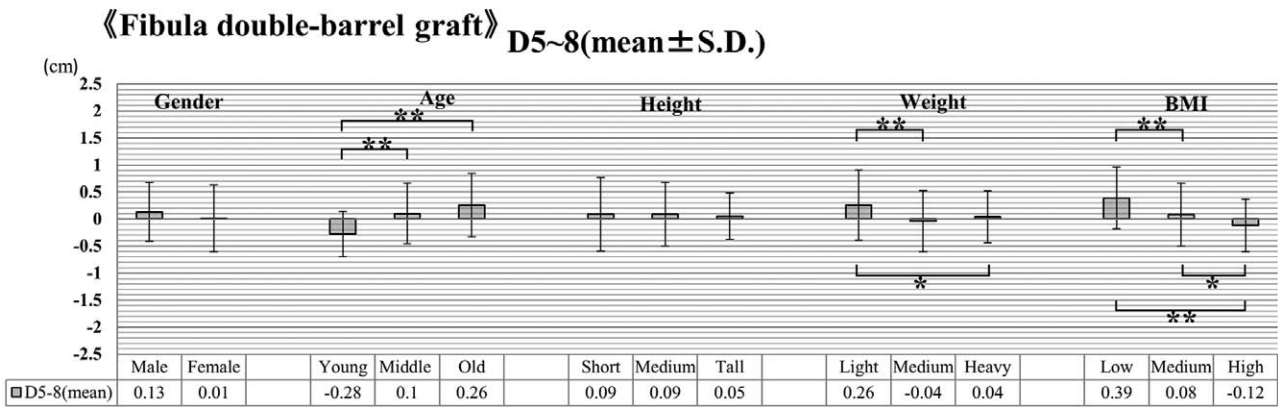
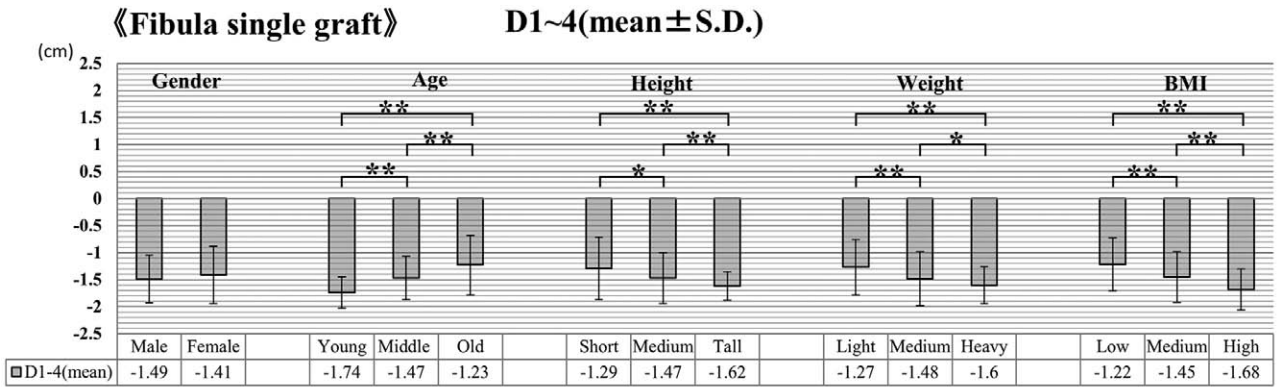
A vascularized free fibular flap was first transferred by Taylor et al in 1975.<sup>6</sup> Since it was first reported by Hidalgo as a method for mandibular reconstruction in 1989,<sup>7</sup> it has been used widely as an excellent method to repair mandibular defects. The bone appropriate for an osseointegrated dental implant was at a minimum 6mm in height, 10mm in height, and well vascularized.<sup>8–11</sup> The problem with a vascularized fibular flap for mandibular defects is limited bone height. The double-barrel technique preserves the vascular pedicle, and folding it doubles the height. However, the problem of fibular double-barrel graft is an excess volume, particularly for alveolar bone reconstruction.<sup>4</sup>

It is important to place a longer implant to achieve more contact with the grafted fibula when placing an osseointegrated dental implant after mandibular reconstruction. Twelve- or 14-mm implants provide good anchorage in the grafted fibula.<sup>12</sup> Removable or fixed dentures are available to support osseointegrated dental implants. Removable dentures distribute weight not only to the dental implant but also to the gingiva. Consideration

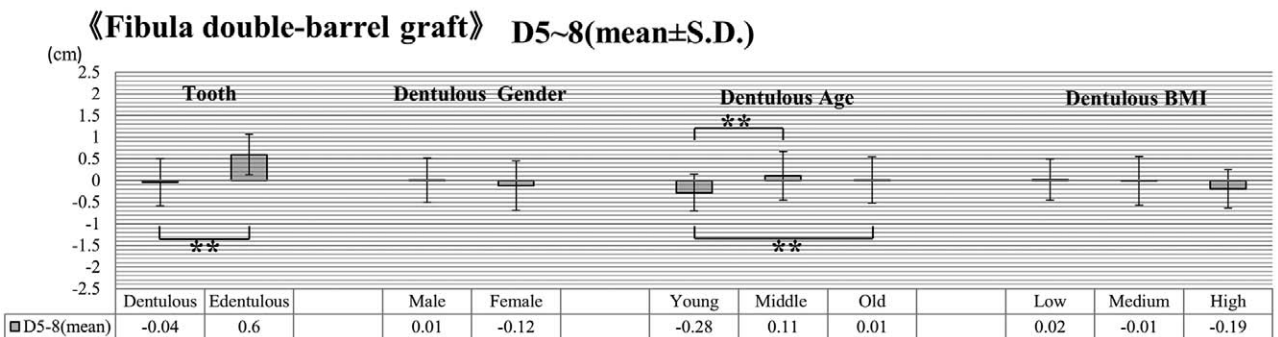
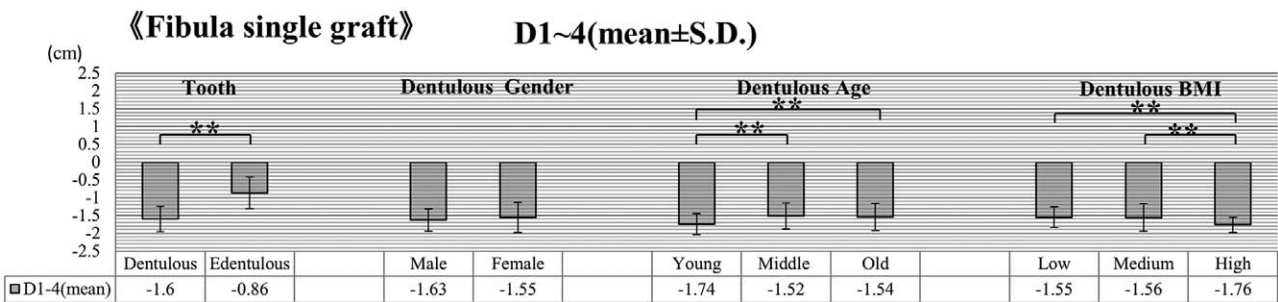
**Table 2. Overall Results of the Difference in Bone Height and Evaluation of the Result of the Fibular Graft**

Difference in bone height of FSG	-1.46 ± 0.48 cm (mean ± SD)
Difference in bone height of FDG	0.08 ± 0.58 cm (mean ± SD)
Evaluation of result of FSG	86.3%, “short”/13.8%, “good”/0%, “over”
Evaluation of result of FDG	0%, “short”/70.1%, “good”/29.1%, “over”

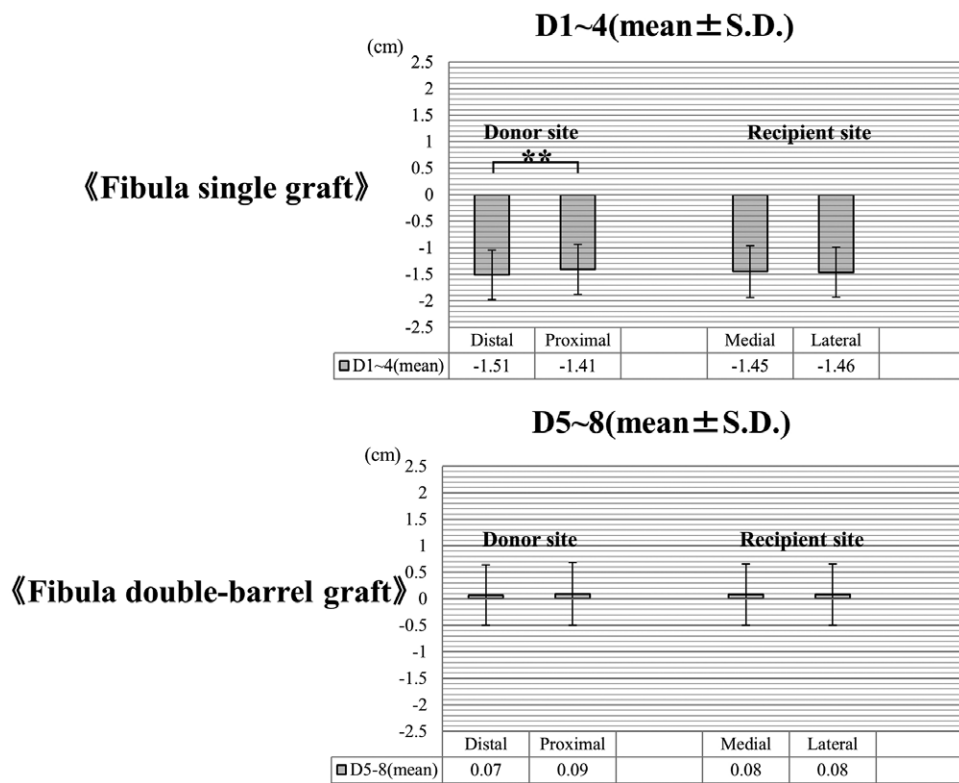
FDG indicates fibula double-barrel graft; FSG, fibula single graft.



**Fig. 4.** Analysis of the difference in bone height of fibular single graft (D1–4) and fibular double-barrel graft (D5–8) by gender, age, height, weight, or BMI. \*\* $P < 0.01$ , \* $P < 0.05$ .



**Fig. 5.** Analysis of the difference in bone height of fibular single graft (D1–4) and fibular double-barrel graft (D5–8) by tooth, or by gender, age, and BMI of dentulous patients. Dentulous Age indicates age of dentulous patients; Dentulous BMI, BMI of dentulous patients; Dentulous Gender, gender of dentulous patients. \*\* $P < 0.01$ .



**Fig. 6.** Analysis of the difference in bone height of fibular single graft (D1–4) and fibular double-barrel graft (D5–8) by donor and recipient sites.  $**P < 0.01$ .

of mechanical balance by occlusal force, and the crown–implant ratio, is extremely important for designing the implant–bone superstructure.<sup>13</sup> The crown–implant ratio should be less than 1:1. If it is greater than 1:1, the longevity of the superstructure is endangered,<sup>14</sup> and the dental implant cannot bear high occlusion forces for long periods of time because the bone around the dental implant is in danger of being absorbed and removed.<sup>15</sup> The best choice for a superstructure is to provide a fixed denture, but only 23% of patients with fibular single graft can use a fixed denture.<sup>16</sup> To provide a fixed denture, an appropriate crown–implant ratio is needed; hence, the difference between fibular and mandibular bone heights should be considered when performing fibular grafts.

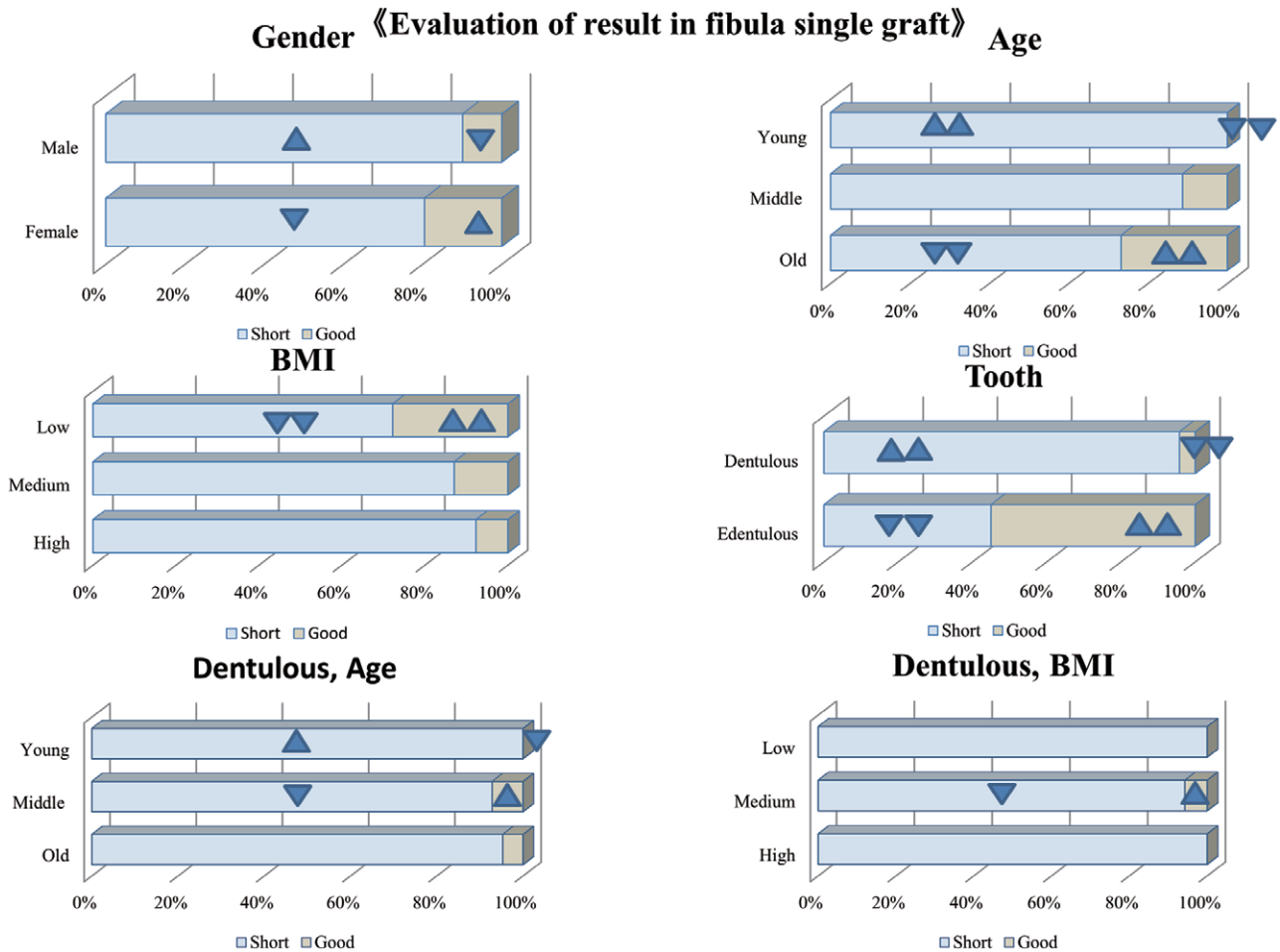
Although the vascularized free fibula should be grafted for the mandibular defect, with a good match between both bones, there are no reports evaluating both fibula and mandible in the same patients when using fibular single graft or fibular double-barrel graft. There are only a few articles that compare fibula and mandible in mandibular reconstruction. In some patients, the difference in height between the fibula and the atrophied mandible was slight.<sup>16</sup> In 12 cases of double-barrel fibular graft, the crown–implant ratio was measured (mean: 0.98; range: 0.86–1.17);<sup>17</sup> however, distribution and analysis of results in the various categories defined here have not been reported.

We defined the difference in height appropriate for placing osseointegrated dental implants to provide a fixed denture using fibular graft as Da (–0.8 to 0.4 cm) for fibular

single graft and as Db (–1.3 to 0.4 cm) for fibular double-barrel graft. Until now, the appropriate numerical difference between the height of the fibula and mandible has not been reported. If a 1.4-cm dental implant is placed after a fibular graft, the height of the superstructure should be less than 1.4 cm. Considering that the average height of a tooth is about 0.6 cm in our clinical experience, we decided that the minimum Da should be –0.8 cm. Considering our clinical experience and difficulties associated with shaving excess bone, we decided that the maximum Da, Db should be 0.4 cm. If the gap between the 2 fibular segments in a double-barrel graft is less than 0.5 cm, the gap will disappear after 6 months.<sup>18</sup> It is no problem if the difference between the grafted double-barrel fibula and native mandible is more than –1.3 cm (the minimum of Db).

The percentage of excess volume in fibular double-barrel grafts has not been reported. Our study showed that the percentage of patients who had a “good” result for a fibular single graft was only 13.8%, whereas the percentage who had a “good” result for a fibular double-barrel graft was 70.9%. The difference of bone height between grafted double-barrel fibula and native mandible was a minimum of –1.2 cm, and there were only 2 cases in which the difference was less than 1.0 cm. Shortage in bone height of a double-barrel fibular graft compared with the native mandible will not occur.

The height of the fibula is 0.94 to 1.74 cm in males and 0.77 to 1.56 cm in females. On average, the height and length of the fibula are greater in males than in females.<sup>11</sup> However, our study showed that the difference in bone



**Fig. 7.** Evaluation of the result of fibular single graft by gender, age, BMI, and tooth or by age and BMI of dentulous patients. Dentulous Age indicates age of dentulous patients; Dentulous BMI, BMI of dentulous patients; 2 upward triangles, significantly very large; 2 downward triangles, significantly very small,  $P < 0.01$ ; 1 upward triangle, significantly large; 1 downward triangle, significantly small,  $P < 0.05$ .

height between the fibula and the mandible was not statistically different between genders for either fibular single graft or fibular double-barrel graft.

The bone height of the edentulous mandible is significantly low because the alveolar base is absorbed by tooth loss and the alveolar crest is flat.<sup>19</sup> In our study, whether patients were dentulous or not had a large influence on the difference in bone height between the fibula and mandible and on clinical results, in fibular single graft and double-barrel graft. For mandibular reconstruction, dentulous patients mostly needed fibular double-barrel grafts, but the edentulous patients mostly needed fibular single grafts.

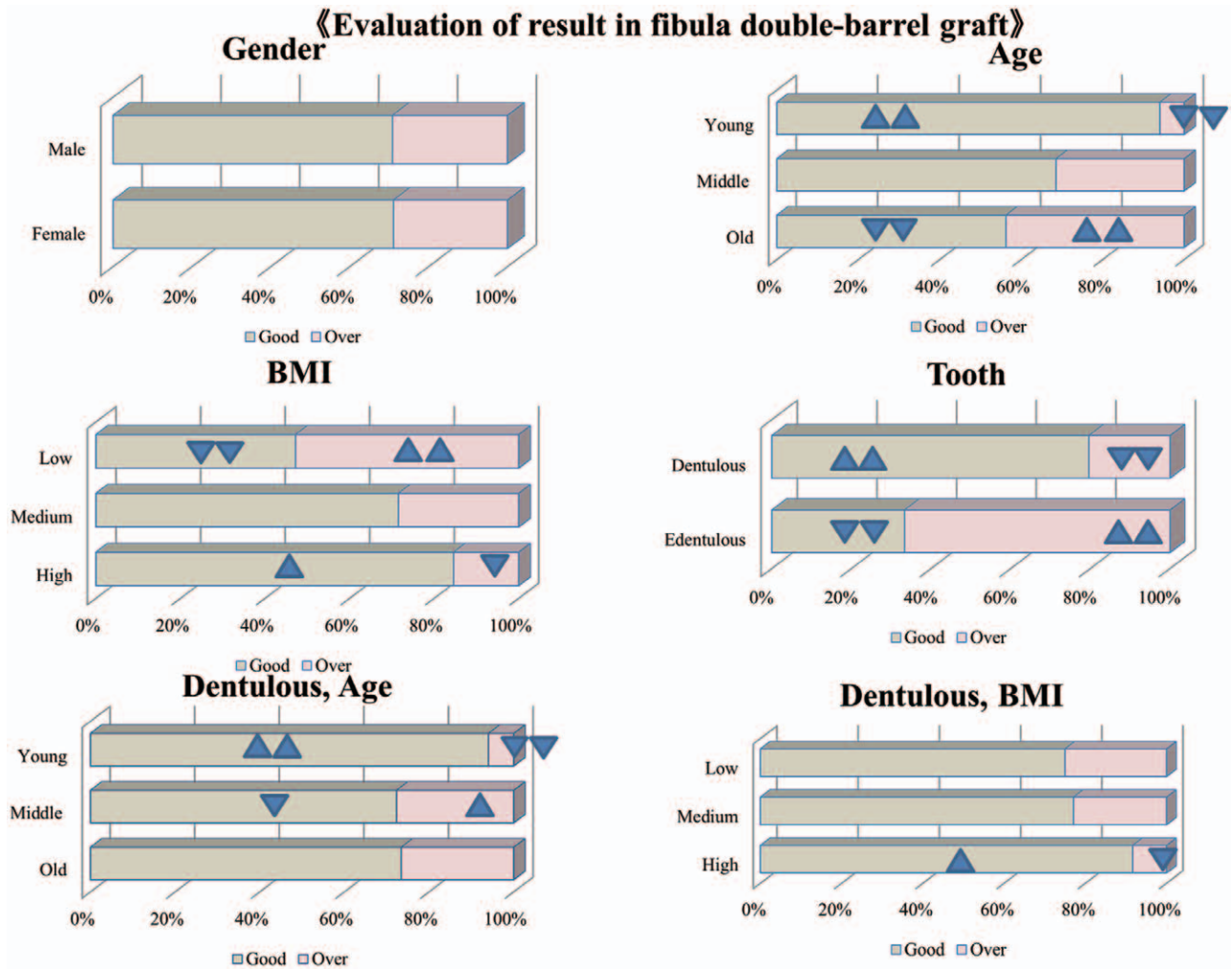
The effect of age on the difference in bone height between the fibula and mandible, and the evaluation of clinical results of fibular grafts, has not been reported. In our study, the older the patients were, the smaller the difference of bone height between single fibular grafts and the mandible. Within increasing age, a fibular single graft was more appropriate as a fibular double-barrel graft had too much volume. There is a possibility of atrophy of the mandible even in dentulous patients as they age. Therefore, young patients mostly needed a double-barrel graft, but

only half of the older patients needed a fibular double-barrel graft.

The effect of BMI on the difference in bone height between the fibula and mandible, and the evaluation of clinical results of fibular grafts, has not been reported. In our study, the higher the BMI, the greater the difference in bone height between the single fibula and the mandible. Patients with a high BMI more often needed a fibular double-barrel graft.

The height of the central section of the fibula was larger than other sections.<sup>20</sup> As shown in Figure 6, bone height of the proximal fibula was greater than that of the distal fibula, and the bone height of the medial mandible was almost equal to that of the lateral mandible. Therefore, a proximal fibular graft can achieve greater bone height than a distal fibular graft. The difference of bone height between the fibula and mandible was almost the same whether the recipient site was medial or lateral.

One limitation of our study is the possibility of post-operative change of bone height. Another limitation is the difference between height measurements made in 2 dimensions and those made in 3 dimensions. The cross-sectional shape of the fibula along its length varies be-



**Fig. 8.** Evaluation of the result of fibular double-barrel graft by gender, age, BMI, and tooth or by age and BMI of dentulous patients. Dentulous Age indicates age of dentulous patients; Dentulous BMI, BMI of dentulous patients; 2 upward triangles, significantly very large; 2 downward triangles, significantly very small,  $P < 0.01$ ; 1 upward triangle, significantly large; 1 downward triangle, significantly small,  $P < 0.05$ .

tween individuals.<sup>21-23</sup> If the cross-sectional shape of the fibular graft is approximately triangular, the graft may not have sufficient volume to be able to place a long implant. Finally, there can be an unavoidable gap between 2 fibular segments in a double-barrel graft.

### CONCLUSIONS

For mandibular reconstruction using a fibular graft, preoperative analysis of the patient's profile with reference to our study and proper use of a fibular single graft or double-barrel graft contribute to minimizing the difference between the height of the grafted fibula and native mandible. This is a key to an ideal reconstruction with good cosmetics and function.

**Naohiro Ishii, MD**

Department of Plastic and Reconstructive Surgery  
Tochigi Cancer Center  
4-9-13, Yohnnan  
Utsunomiya City  
Tochigi 320-0834, Japan  
E-mail: ishinao0916@gmail.com

### REFERENCES

1. Jones NE, Swartz WM, Mears DC, et al. The "double barrel" free vascularized fibular bone graft. *Plast Reconstr Surg.* 1988;81:378-385.
2. Horiuchi K, Hattori A, Inada I, et al. Mandibular reconstruction using the double barrel fibular graft. *Microsurgery* 1995;16:450-454.
3. O'Brien BM, Gumley GJ, Dooley BJ, et al. Folded free vascularized fibula transfer. *Plast Reconstr Surg.* 1988;82:311-318.
4. Ulkur E, Karagoz H, Kulahci Y, et al. One-and-a-half-barrel vascularized free fibular flap for the reconstruction of segmental mandibular defect. *J Craniofac Surg.* 2013;24:e167-e169.
5. Mataga I. Functional reconstruction of the maxillo-mandible by revascularized fibular osteoseptocutaneous flap and application of dental implant. *Hosp Dent.* 2003;15:3-21 (Japanese).
6. Taylor GI, Miller GD, Ham FJ. The free vascularized bone graft. A clinical extension of microvascular techniques. *Plast Reconstr Surg.* 1975;55:533-544.
7. Hidalgo DA. Fibula free flap: a new method of mandible reconstruction. *Plast Reconstr Surg.* 1989;84:71-79.
8. Frodel JL Jr, Funk GF, Capper DT, et al. Osseointegrated implants: a comparative study of bone thickness in four vascularized bone flaps. *Plast Reconstr Surg.* 1993;92:449-455.



9. Hayter JP, Cawood JI. Oral rehabilitation with endosteal implants and free flaps. *Int J Oral Maxillofac Surg*. 1996;25:248.
10. Brånemark PI. Osseointegration and its experimental background. *J Prosthet Dent*. 1983;50:399–410.
11. Carbiner R, Jerjes W, Shakib K, et al. Analysis of the compatibility of dental implant systems in fibula free flap reconstruction. *Head Neck Oncol*. 2012;4:37.
12. Wang F, Huang W, Zhang C, et al. Comparative analysis of dental implant treatment outcomes following mandibular reconstruction with double-barrel fibula bone grafting or vertical distraction osteogenesis fibula: a retrospective study. *Clin Oral Implants Res*. 2015;26:157–165.
13. Bidez MW, Misch CE. Force transfer in implant dentistry: basic concepts and principles. *J Oral Implantol*. 1992;18:264–274.
14. Bähr W, Stoll P, Wächter R. Use of the “double barrel” free vascularized fibula in mandibular reconstruction. *J Oral Maxillofac Surg*. 1998;56:38–44.
15. Saadoun AP, LeGall ML. Clinical results and guidelines on Steri-Oss endosseous implants. *Int J Periodontics Restorative Dent*. 1992;12:487–495.
16. Raoul G, Ruhin B, Briki S, et al. Microsurgical reconstruction of the jaw with fibular grafts and implants. *J Craniofac Surg*. 2009;20:2105–2117.
17. Chang YM, Wallace CG, Hsu YM, et al. Outcome of osseointegrated dental implants in double-barrel and vertically distracted fibula osteoseptocutaneous free flaps for segmental mandibular defect reconstruction. *Plast Reconstr Surg*. 2014;134:1033–1043.
18. González-García R, Naval-Gías L, Rodríguez-Campo FJ, et al. Gap ossification in the double-barrel technique for the reconstruction of mandibular defects by means of the vascularized free fibular flap. *Plast Reconstr Surg*. 2006;117:2519–2520.
19. Morita T, Takeuchi S, Yamashita H. [Morphological study on edentulous mandibula]. *Kaibogaku Zasshi*. 1993;68:316–327.
20. Ide Y, Matsunaga S, Harris J, et al. Anatomical examination of the fibula: digital imaging study for osseointegrated implant installation. *J Otolaryngol Head Neck Surg*. 2015;44:1.
21. Fujisawa M, Ishihara O, Mataga I. Anatomical study and clinical application of fibular osteocutaneous flap: for maxillo-mandibular reconstruction and dental implant installation. *Odontology* 1998;86:150–163.
22. Klesper B, Wahn J, Koebke J. Comparisons of bone volumes and densities relating to osseointegrated implants in microvascularly reconstructed mandibles: a study of cadaveric radius and fibula bones. *J Craniomaxillofac Surg*. 2000;28:110–115.
23. Choi SW, Kim HJ, Koh KS, et al. Topographical anatomy of the fibula and peroneal artery in Koreans. *Int J Oral Maxillofac Surg*. 2001;30:329–332.