



# Diffuse Alveolar Hemorrhage after Receiving Oral Levonorgestrel for Emergency Contraception: A Case Report

Clinical Medicine Insights: Case Reports  
Volume 14: 1–7  
© The Author(s) 2021  
Article reuse guidelines:  
sagepub.com/journals-permissions  
DOI: 10.1177/11795476211005821



Athina Georgopoulou<sup>1</sup>, Efthymia Papadopoulou<sup>1</sup>, Marianna Moyses<sup>1</sup>, Sofia-Chrysovalantou Zagaloti<sup>2</sup> , Christos Hatzis<sup>2</sup>, Dimitrios Karanasios<sup>2</sup> and Stavros Tryfon<sup>1</sup> 

<sup>1</sup>Pulmonary Department of NHS, General Hospital "George Papanikolaou," Thessaloniki, Greece.

<sup>2</sup>Primary Health Center, N. Madytos, Greece.

## ABSTRACT

**INTRODUCTION:** Drug-induced diffuse alveolar hemorrhage (DAH) has been associated with the administration of various medications, among which levonorgestrel (LN) has not been reported until now.

**CASE PRESENTATION:** This case study describes a 42-year-old woman who presented with hemoptysis, hypoxemia, and radiological depiction of ground glass opacities, 3 days after she had received emergency contraceptive medication containing levonorgestrel. Emergent bronchoscopy was performed, and BAL was diagnostic of diffuse alveolar hemorrhage (DAH). A thorough diagnostic approach was followed, in order to detect the underlying pathological condition that induced DAH. The absence of other identifiable pathological conditions in this patient raised suspicion of LN's potential causative role.

**CONCLUSION:** DAH has not been reported as an adverse effect of LN until now. However, LN has been found to exert immunomodulatory effects and to present potential for manifestations of vasculitis as well as severe hypersensitivity reactions. These mechanisms may have been implicated in the development of DAH in our patient, who presented no other pathological conditions.

**KEYWORDS:** Diffuse alveolar hemorrhage (DAH), levonorgestrel, progesterone derivative, emergency contraception, progestogen

**RECEIVED:** November 19, 2020. **ACCEPTED:** March 9, 2021.

**TYPE:** Case Report

**FUNDING:** The author(s) received no financial support for the research, authorship, and/or publication of this article.

**DECLARATION OF CONFLICTING INTERESTS:** The author(s) declared no potential conflicts of interest with respect to the research, authorship, and/or publication of this article.

**CORRESPONDING AUTHOR:** Stavros Tryfon, Pulmonary Department of NHS, General Hospital "George Papanikolaou," Thessaloniki, Greece. Email: stavrostryfon@yahoo.gr

## Introduction

This case study describes a 42-year-old woman who presented with hemoptysis, hypoxemia, and radiological depiction of ground glass opacities, 3 days after she had received emergency contraceptive medication containing levonorgestrel (LN). Emergent bronchoscopy was performed, and BAL was diagnostic of diffuse alveolar hemorrhage (DAH). The development of DAH has not been reported among LN's side effects until now. Nevertheless, the absence of other identifiable pathological conditions in this patient, along with LN's potential for severe adverse reactions, raised strong suspicion of a causative association.

## Case Presentation

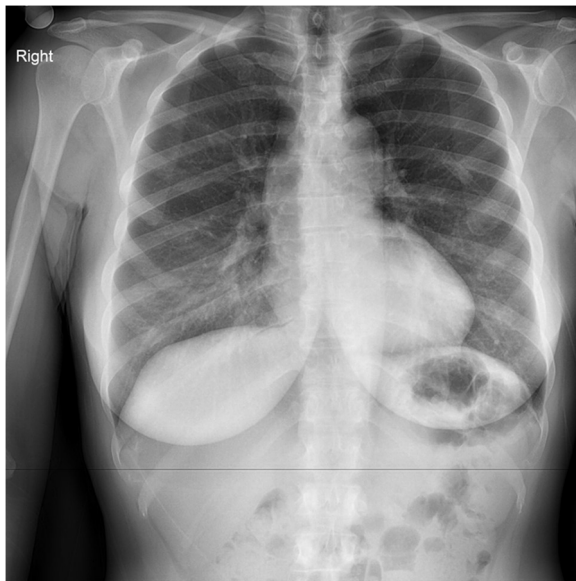
A 42-year-old female presented to the Emergency Department with episodes of hemoptysis amounting to approximately 50 ml of bright-red blood, which occurred along with coughing a few hours ago. The patient was an otherwise healthy woman with no previous episodes of hemoptysis, no history of smoking, and no remarkable family history. Upon further questioning, she disclosed having received, first time in her life, oral emergency contraceptive medication, containing levonorgestrel (1.5 mg), 3 days prior to the episodes of hemoptysis, with the intention of preventing unwanted pregnancy. The patient denied having

received contraceptive medication, levonorgestrel, or progestogens in the past. On physical examination she was found to be hemodynamically stable and afebrile. No apparent bleeding diathesis was detected. She had mild hypoxemia with SpO<sub>2</sub> at 93% on room air, but neither respiratory failure nor remarkable abnormal breath sounds were noted. Ear, nose and throat (ENT) examination excluded pathological lesions and active bleeding from the upper respiratory tract.

Chest X-ray (Figure 1) depicted no pathological findings, whereas laboratory tests (Table 1) revealed neutrophilic leukocytosis [WBC = 13.4 K/ $\mu$ L (normal range: 3.8–10.5 K/ $\mu$ L) – neutrophils = 79.6% (normal range 45%–75%)]. Erythrocytes, platelets, and coagulation study showed no deviation from normal values. Furthermore, mild anemia with decrease in Ht was documented. Urine analysis presented normal results with no detectable hemoglobinuria. Computed Tomography (CT) scan of the thorax (Figure 2) revealed multiple bilateral ground glass opacities compatible with alveolar hemorrhage. An incidental finding of an aneurysm, with a maximum diameter of 4cm, was also depicted in the ascending aorta, without clinical denotation.

The patient underwent emergent bronchoscopy, that showed extensive hemorrhagic areas in the submucosa throughout the bronchial tree and endobronchial serpentine of clots at the right middle as well as lower lobe. Bronchoalveolar lavage (BAL) was





**Figure 1.** Chest X-ray depicted no pathological findings—despite the patient's symptoms of cough and hemoptysis.

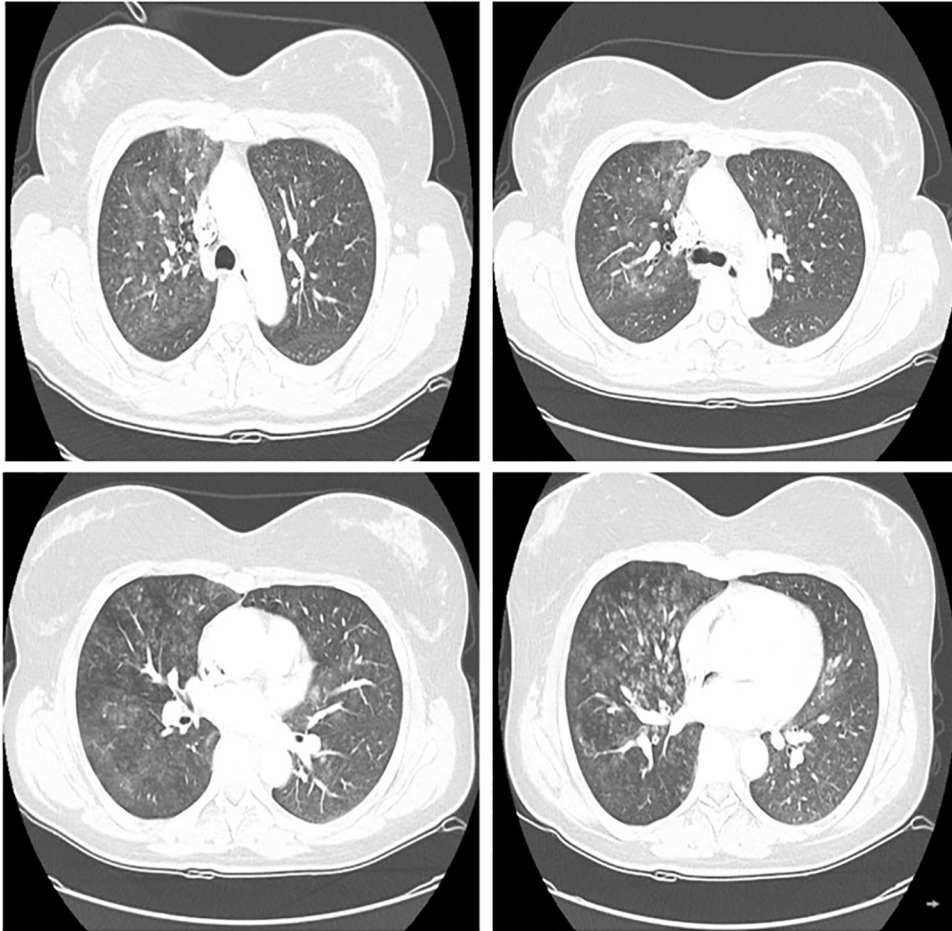
highly indicative of alveolar hemorrhage, as it presented the characteristic progressively more hemorrhagic fluid in sequential aliquots from B8 secondary lobar bronchus. Blood and BAL samples were collected for immunological, cytological as well as microbiological analysis. BAL culture presented no pathological findings, whereas cytological examination (Table 2) revealed numerous red blood cells, many alveolar hemosiderin-laden

macrophages, several inflammatory cells, and few bronchial epithelial cells, without elements of malignancy. The BAL findings confirmed diffuse alveolar hemorrhage (DAH) in our patient. Possible differential diagnosis of DAH included antineutrophilic cytoplasmic antibody associated vasculitis, systemic lupus erythematosus, Goodpasture syndrome, collagen vascular diseases, inhaled toxic gasses, celiac disease, and cytotoxic drug therapy. Serologic biochemical and immunological findings were normal (Table 3), thus excluding all the above-mentioned disorders. As the principal “risk therapy” for alveolar hemorrhage, pulses of methylprednisolone 500mg per day were administered for 3 days. The patient was also put under antibiotic therapy with ampicillin-sulbactam. During hospitalization period, she received tranexamic acid as a means to ensure the abatement of hemoptysis. Her clinical condition remained stable and no further episodes of hemoptysis occurred. On the 4th hospitalization day, corticosteroid therapy was tapered to 32mg of oral methylprednisolone and 7 days later the patient was discharged from the hospital as shown in timeline (Figure 3). At follow-up, one month later, while methylprednisolone had been tapered to 8mg per second day, the patient was in good physical condition with normal oxygen saturation. Her chest X-ray revealed no pathological entities and both blood laboratory findings and pulmonary function tests were within normal values. High resolution chest tomography (HRCT) was performed (Figure 4), which revealed resolution of the ground glass opacities that had been depicted 1 month ago. The dimensions of the ascending aorta

**Table 1.** Blood laboratory findings revealed leukocytosis and mild anemia.

	ON ADMISSION	ON DISCHARGE, 7 D LATER	NORMAL VALUES
WBC (/ $\mu$ L)	13,400	11,520	3800-10,500/ $\mu$ L
Neutrophils (/ $\mu$ L)	79.6% 10,700	87% 10,000	45-75% 1600-6500/ $\mu$ L
Lymphocytes (/ $\mu$ L)	18.9% 2500	7.2% 830	20-51% 1500-3600/ $\mu$ L
RBC (M/ $\mu$ L)	4.37	3.78	3.80-5.30M/ $\mu$ L
Hb (g/dL)	12.7	11.8	12-16 g/dL
Ht	35.9%	35%	37-47%
MCV (fL)	92.6	89.9	80-99fL
MCH (pg)	31.2	31.4	27-32pg
MCHC (g/dL)	33.7	34.9	32-35 g/dL
Fe-serum ( $\mu$ g/dL)		33	13-150 $\mu$ g/dL
Ferritin (ng/mL)		83	37-145 ng/mL
PLT (/ $\mu$ L)	259,000	248,000	150,000-450,000/ $\mu$ L
PT (s)	12.6	11.1	10-14 s
PTT (s)	20	26	25-35 s
INR (s)	1.08	1.03	0.8-1.1 s

Abbreviations: Hb: hemoglobin; Hct: hematocrit; INR: international normalized ratio; MCH: mean corpuscular hemoglobin; MCHC: mean corpuscular hemoglobin concentration; MCV: mean corpuscular volume; PLT: platelets; PT: prothrombin time; PTT: partial thromboplastin time; RBC: red blood cells; WBC: white blood cells.



**Figure 2.** CT scan of the thorax revealed multiple confluent ground glass and botryoid nodules throughout the right lung, but also to a lesser extent in the left lung. There is a thickening of the wall of the central bronchi of the right lower lobe as well. Based on the reported history, the imaging findings are primarily in favor of diffuse alveolar haemorrhage. An incidental finding of an aneurysm, maximum diameter 4 cm, was also depicted in the ascending aorta, without clinical denotation.

**Table 2.** BAL cytological analysis revealed a neutrophilic predominance.

BAL CELL TYPE		NORMAL VALUES
Hemosiderin-laden macrophages	32%	0
Lymphocytes	12%	5-15%
Neutrophils	56%	1-4%
Other/eosinophils		<1%

Abbreviations: BAL: bronchoalveolar lavage; DAH: diffuse alveolar hemorrhage. Hemosiderin-laden macrophages were pathognomonic of DAH.

were measured the same. Urine analysis at follow-up was normal, without signs of hemoglobinuria, or proteinuria.

## Discussion

We present a case of mild hemoptysis, hypoxemia, and radiological depiction of bilateral ground glass opacities in a female patient who had received oral emergency contraceptive medication containing levonorgestrel 3 days prior to the episode of hemoptysis. Emergent bronchoalveolar lavage (BAL) was

diagnostic of diffuse alveolar hemorrhage (DAH) and intravenous corticosteroid therapy was administered, followed by improvement in the patient's clinical condition and radiological findings. Interestingly, our patient presented no other causative factors for hemoptysis, but had received levonorgestrel (LN), thereby raising suspicion of a potential adverse reaction leading to the development of DAH.

DAH, which was first described by Osler in 1904,<sup>1</sup> constitutes a life-threatening medical emergency resulting from the disruption of the pulmonary microcirculation which leads to blood accumulation within the alveoli.<sup>2</sup> In patients presenting with dyspnea, hemoptysis, cough, and anemia, along with radiological depiction of diffuse alveolar infiltrates, DAH should be taken into consideration and prompt diagnostic as well as therapeutic approach should be followed, in order to ensure a favorable outcome.<sup>3</sup> Bronchoscopy with BAL confirms the diagnosis, as BAL becomes progressively more hemorrhagic in sequential aliquots, a finding indicative of the alveolar origin of blood. BAL cytology examination with numerous red blood cells, as well as hemosiderin-laden macrophages, amounting to

**Table 3.** Serum immunological findings were normal, both on admission and at follow-up 1 mo later.

	ON ADMISSION	AT FOLLOW-UP (1 MO LATER)	NORMAL VALUES
ANA	Negative	Negative	Negative
Anti-ds DNA	Negative	Negative	Negative
Anti-SS-A(Ro)	4.29 U/mL	Negative	<12 U/mL
Anti-SS-B(La)	1.14 U/mL	Negative	<12 U/mL
Anti-Sm	1.79 U/mL	N/A	<12 U/mL
Anti-RNP	0.98 U/mL	N/A	<12 U/mL
Anti-Jo-1	1.05 U/mL	N/A	<12 U/mL
Anti-Scl 70	6.81 U/mL	N/A	<12 U/mL
AMA	Negative	N/A	Negative
ASMA	Negative	N/A	Negative
P-ANCA (MPO) IgG	4.19 AU/mL	Negative	<20 AU/mL
C-ANCA (PR-3) IgG	0.90 AU/mL	Negative	<20 AU/mL
Anti-GBM		2.2 U/mL	<20 U/mL
RF	<20.0 IU/mL	10.8	<20 IU/mL
CRP	0.16 mg/dL	<0.3	<0.8 mg/dL
C3-complex	83 mg/dL	N/A	79-152 mg/dL
C4-complex	17 mg/dL	N/A	16-38 mg/dL

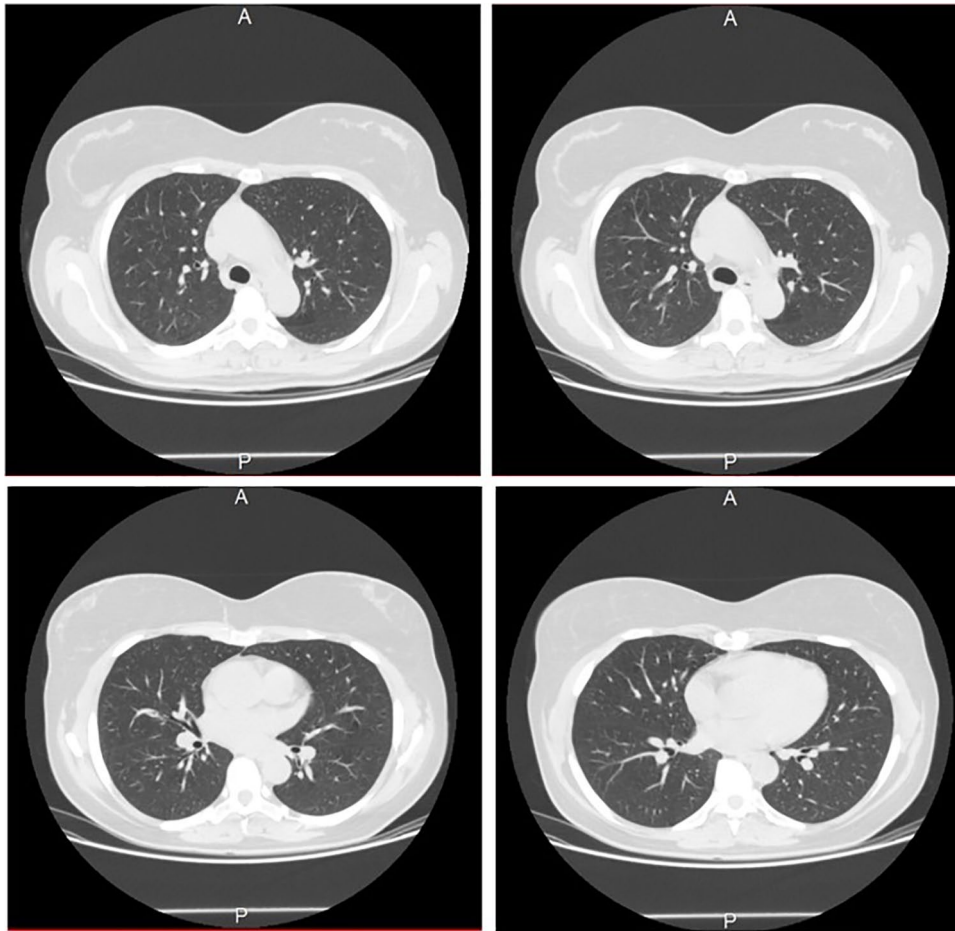
ANA: antinuclear antibodies; Anti-ds DNA: anti-double stranded DNA antibodies; Anti-GBM: anti-glomerular basement membrane antibodies; Anti-SS-A(Ro): anti-Sjögren's syndrome type A autoantibodies; Anti-SS-B(La): Anti-Sjögren's syndrome type B (Lupus La protein) antibodies; Anti-Sm: Anti-Smith antibodies; Anti-RNP: anti-ribonucleoprotein antibodies; Anti-Jo-1: anti-nuclear antibody Anti-Jo1; Anti-Scl 70: anti-scleroderma 70 kD fragment antibodies; AMA: anti-mitochondrial antibodies; ASMA: anti-smooth muscle antibodies; C-ANCA (PR-3): cytoplasmic anti-neutrophil cytoplasmic antibodies (proteinase 3); CRP: C-reactive protein; C3: complement component 3; C4: complement component 4; N/A: non applicable; P-ANCA (MPO): perinuclear anti-neutrophil cytoplasmic antibodies (myeloperoxidase); RF: rheumatoid factor.

>20% of all cells, is pathognomonic of DAH.<sup>4</sup> However, this type of cells is usually detectable 48 hours after hemorrhage.<sup>5</sup> Among the underlying pathological conditions for the development of DAH, numerous medications have been incriminated. Drug-induced DAH involves various pathophysiologic processes leading to vasculitis, hypersensitivity reactions, direct toxicity with subsequent epithelial injury and damage to the alveolar capillary basement membrane.<sup>6</sup>

Levonorgestrel (LN), also known as *17 $\alpha$ -ethynyl-18-methyl-19-nortestosterone* or as *17 $\alpha$ -ethynyl-18-methylestr-4-en-17 $\beta$ -ol-3-one*, is an active progesterone derivative, which was first utilized as a combined oral contraceptive with ethinylestradiol in 1970,<sup>7</sup> and then assessed as a form of emergency contraception in 1973.<sup>8</sup> Since then, its medical utilization has expanded in the field of hormone replacement therapy as a combined oral tablet with estradiol valerate and as a combined transdermal patch with estradiol.<sup>9</sup> LN-releasing intrauterine devices, as well as subcutaneous implants, have also been introduced as contraceptive methods.<sup>10</sup> LN activates progesterone and androgen receptors, impeding the secretion of gonadotropin-releasing hormone from the hypothalamus,

and thus inhibiting the luteinizing hormone surge that normally occurs at the pre-ovulation stage.<sup>11</sup> Regarding its distribution, 98% of the circulating molecules is bound to serum proteins, namely to albumin (33%) and to sex hormone binding globulin (SHBG-65%), whereas the remaining 1.5% exerts its effects in the form of free steroid.<sup>12</sup> LN is characterized by a mean half-life of approximately 26 hours.<sup>12</sup> After hydroxylation by liver enzymes, mainly by CYP3A4, and glucuronidation by liver glucuronidase enzymes, LN's metabolites are excreted with urine and faeces.

Commonly reported side effects of LN include fatigue, headache, dizziness, nausea, irritability, decrease in libido, fluid accumulation, acne, menstrual disorders, abnormal uterine bleeding, hirsutism, hair loss, as well as breast tenderness.<sup>13,14</sup> Bleeding as an adverse reaction of LN has been reported only for the gynecological system until now at a percentage of 31%.<sup>15</sup> Even more severe adverse effects, as well as susceptibility to the development of serious diseases, have also been documented, albeit rarely. According to Conz et al.,<sup>16</sup> a higher risk of breast cancer has been associated with utilization of levonorgestrel as a contraceptive intrauterine



**Figure 3.** CT scan of the thorax 1 month later revealed resolution of the ground glass opacities that had been depicted 1 month ago. The dimensions of the ascending aorta were measured the same.

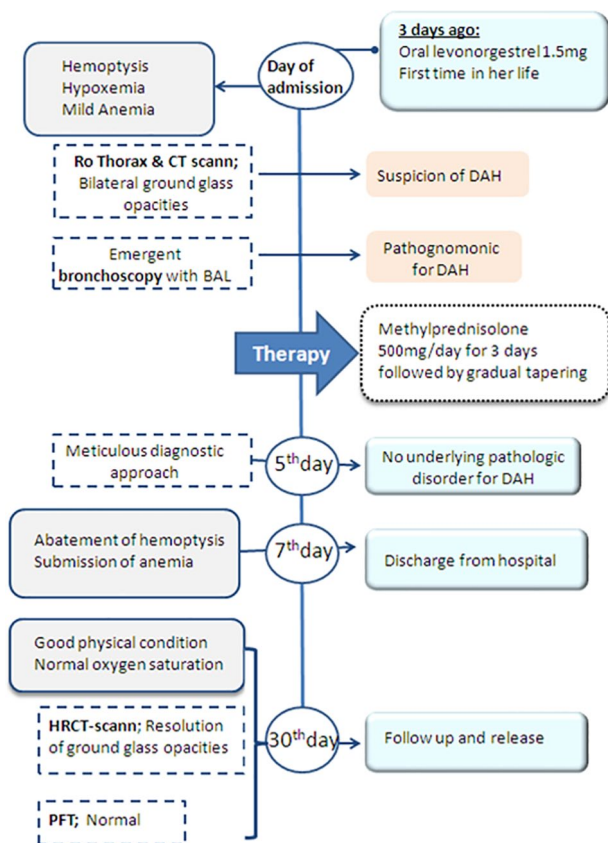
device. The pivot of the acute adverse reactions has been associated with LN's initially highly elevated plasma concentration, which may amount to significantly higher levels than the therapeutic range of the drug (4–6 ng/mL), thereby presenting potential for even fatal complications.<sup>12</sup> To date, based on the reports of the international databases (PubMed, Vigibase, Pneumotox, EudraVigilance), no cases of DAH associated with LN have been observed. Nevertheless, according to the Adverse Drug Reaction Probability Scale, this case highlights a probable causal association between LN and DAH, with a total score amounting to 6.<sup>17</sup> LN's potentiality to induce immunomodulatory effects, vasculitis, susceptibility to infections, as well as hypersensitivity reactions, has been amply documented and may reflect possible pathophysiologic explanations for the development of DAH in our patient, who presented no other etiologic factors.

#### *LN's immunomodulatory effects*

Through the extensive distribution of their receptors, sex steroids exert various potent effects on the body, among which modulation of the immune system has been thoroughly studied.<sup>18,19</sup> Progestins' immunomodulatory impact has been proven to directly affect T cells and T cell subsets.<sup>20</sup>

Furthermore, contraceptives' effects on the immune system are also exerted through the suppression of pituitary gonadotropins, that have been implicated in additional immunomodulatory effects.<sup>21</sup> In particular, the gonadotropin releasing hormone (GnRH) and its receptor are found in immune cell subsets and GnRH has been implicated in programming the immune system.<sup>22</sup> Thus, administration of either combined estrogen-progestin contraceptives or progestin-only contraceptives presents immunomodulatory effects and may influence susceptibility to autoimmune diseases.<sup>20</sup>

Indeed, an elevated risk for manifestations of rheumatism, arthropathies, rheumatoid arthritis, eczema, contact dermatitis, urticaria, and pruritis has been found to be associated with utilization of progesterone-only contraceptives.<sup>23</sup> Accordingly, the prescribing information for LN implants has included, albeit indirectly, potentiality for autoimmune diseases such as scleroderma, lupus erythematosus disseminatus, and rheumatoid arthritis.<sup>24</sup> Another T-cell autoimmune entity, namely lichenoid drug eruption, in which inflammatory cells attack a protein of keratinocytes, has been shown to relate not only to oral contraceptives,<sup>25,26</sup> but also to LN-releasing intrauterine devices.<sup>27</sup> Moreover, progesterone-only contraceptives may trigger or aggravate the emergence of autoimmune progesterone dermatitis. Even the risk of developing multiple sclerosis



**Figure 4.** Symptoms and signs, diagnostic approach, therapeutic intervention, and follow-up shown in timeline schedule.

has been postulated to increase with utilization of combined hormonal contraceptives.<sup>28</sup> Our patient presented neither clinical symptoms nor serum immunological markers indicative of an autoimmune reaction or disorder.

### LN-induced hypersensitivity reactions

Severe hypersensitivity reactions to LN have been abundantly reported. Cases<sup>29,30</sup> of a rare syndrome called “progesterone hypersensitivity,” which may be induced either by endogenous progesterone during the luteal phase of the menstrual cycle and during pregnancy, or by exogenous progestogens, have been found to be associated with LN administration. Symptoms are heterogeneous and include manifestations of cyclic dermatitis, urticaria, angioedema, asthma, multiple organ involvement, and anaphylaxis.<sup>31-35</sup> The underlying pathophysiologic mechanism pivots on type I or type IV hypersensitivity reaction mediated by lymphocytes Th2.<sup>36</sup> Positive results in a skin prick and intradermal skin testing to progesterone may be found in such cases.<sup>31</sup> Immediate treatment with administration of corticosteroids and antihistaminics is initiated in such cases.<sup>37</sup>

Atypical neutrophilic reactions resembling Sweet’s syndrome in patients who are otherwise well and receive the oral contraceptive, have also been reported.<sup>38</sup>

Again, our patient was devoid of clinical symptoms as well as immunological markers suggestive of an underlying allergic or hypersensitivity reaction.

### LN-induced vasculitis

Allergic vasculitis with manifestations of severe renal complications, fixed pigmented erythema, urticaria, and lichenoid eruptions, has been observed in several cases.<sup>24</sup> Associations between markers of allergy (eosinophils, IgE, atopy) and hormonal-dependent conditions in women (premenstrual asthma, menopause, and oral contraceptive use) have been noted.<sup>39</sup> Combined steroid contraceptives have been found to impede antibody formation, to cause a decrease in complement levels, and to exert an immunosuppressive effect on lymphocyte activation by nonspecific mitogens “in vitro.” In vivo, the immunosuppressive effect on lymphocytes has also been observed.<sup>40</sup> We noted no evidence of a specific type of vasculitis in our patient.

**Hypersensitivity reactions with allergic angitis** as an ultimate manifestation, as well as forms of vasculitis resembling Wegener’s granulomatosis, polyarteritis nodosa, or Churg-Strauss syndrome have been reported. A reaction of cell-mediated immunity has been proposed as the underlying mechanism.<sup>38</sup> Patients may develop only cutaneous involvement or life-threatening systemic involvement, with severe and even fatal deterioration. Oral contraceptives have been postulated to induce principally mild vasculitis; however, a rare case of vasculitis manifesting with cutaneous necrosis in a woman who received oral contraceptive containing levonorgestrel 0.15 µg and ethinylestradiol 0.03 mg has been observed.<sup>41</sup> As this entity presents a variable clinical picture and a multitarget pathological involvement, it seems as the most apposite pathophysiologic mechanism explaining the development of DAH syndrome in our patient.

### Conclusion

A substantial risk for the development of autoimmune disorders, as well as severe hypersensitivity reactions, has been associated with the utilization of levonorgestrel (LN). Taking into consideration the fact that LN is a commonly used progestin worldwide given its use in oral, implantable, and intrauterine contraceptives without previous reports of diffuse alveolar hemorrhage as a complication, this would be the first report documenting the rarity of this occurrence with a probable cause-effect relationship.

### ORCID iDs

Sofia-Chrysovalantou Zagalioti  <https://orcid.org/0000-0002-6371-1251>

Stavros Tryfon  <https://orcid.org/0000-0001-5102-0480>

### REFERENCES

- Zamora MR, Warner ML, Tuder R, Schwarz MI. Diffuse alveolar hemorrhage, and systemic lupus erythematosus. Clinical presentation, histology, survival, and outcome. *Medicine (Baltimore)*. 1997;76:192-202.
- Lara AR, Schwarz MI. Diffuse alveolar hemorrhage. *Chest*. 2010;137:1164-1171.
- Specks U. Diffuse alveolar hemorrhage syndromes. *Curr Opin Rheumatol*. 2001;13:12-17.
- Alexandre AT, Vale A, Gomes T. Diffuse alveolar hemorrhage: how relevant is etiology? *Sarcoidosis Vasc Diffuse Lung Dis*. 2019;36:47-52.

5. Pérez-Arellano JL, Losa García JE, García Macías MC, Gómez Gómez F, Jiménez López A, de Castro S. Hemosiderin-laden macrophages in bronchoalveolar lavage fluid. *Acta Cytol.* 1992;36:26-30.
6. Schwarz MI, Fontenot AP. Drug-induced diffuse alveolar hemorrhage syndromes and vasculitis. *Clin Chest Med.* 2004;25:133-140.
7. Roth K. *Chemische Leckerbissen.* Weinheim Wiley-VCH; 2014:77.
8. Kesserü E, Larrañaga A, Parada J. Postcoital contraception with D-norgestrel. *Contraception.* 1973;7:367-379.
9. Kubíková D. Menopausal symptoms and hormone replacement therapy. *Praktické Lékařství.* 2014;10:68-73.
10. Friend DR. Development of controlled release systems over the past 50 years in the area of contraception. *J Control Release.* 2016;240:235-241.
11. Kahlenborn C, Peck R, Severs WB. Mechanism of action of levonorgestrel emergency contraception. *Linacre Q.* 2015;82:18-33.
12. Shahiwala A, Misra A. Pulmonary absorption of liposomal levonorgestrel. *AAPS Pharm Sci Tech.* 2004;5:E13.
13. Jatlaoui TC, Riley H, Curtis KM. Safety data for levonorgestrel, ulipristal acetate and Yuzpe regimens for emergency contraception. *Contraception.* 2016;93:93-112.
14. Brache V, Faundes A, Alvarez F, Cochon L. No menstrual adverse events during use of implantable contraceptives for women: data from clinical trials. *Contraception.* 2002;65:63-74.
15. Leelakanok N, Methaneethorn J. A systematic review and meta-analysis of the adverse effects of levonorgestrel emergency oral contraceptive. *Clin Drug Investig.* 2020;40:395-420.
16. Conz L, Mota BS, Bahamondes L, et al. Levonorgestrel-releasing intrauterine system and breast cancer risk: a systematic review and meta-analysis. *Acta Obstet Gynecol Scand.* 2020;99:970-982.
17. Naranjo CA, Busto U, Sellers EM, Sandor P, et al. A method for estimating the probability of adverse drug reactions. *Clin Pharmacol Ther.* 1981;30:239-245.
18. Schuurs AH, Verheul HA. Effects of gender and sex steroids on immune response. *J Steroid Biochem Mol Biol.* 1990;35:157-172.
19. Mann D, Ansari AA, Akinbami MA, Wallen K, Gould KG, McClure HM. Neonatal treatment with lutenizing hormone-releasing hormone analogs alters peripheral lymphocyte subsets and cellular and humoral mediated immune responses in juvenile and adult male monkeys. *J Clin Endocrinol Metab.* 1994; 78: 292-298.
20. Tan IJ, Peeva E, Zandman-Goddard G. Hormonal modulation of the immune system—a spotlight on the role of progestogens. *Autoimmun Rev.* 2015;14:536-542.
21. Athreya BH, Rettig P, Williams WV. Hypophyseal-pituitary-adrenal axis in autoimmune and rheumatic diseases. *Immunol Res.* 1998;18:93-102.
22. Tanriverdi F, Silveira LF, MacColl GS, Bouloux PM. The hypothalamic-pituitary-gonadal axis: immune function and autoimmunity. *J Endocrinol.* 2003;176:293-304.
23. Farley TMM, Sivin I; International Collaborative Post-Marketing Surveillance of Norplant. Post-marketing surveillance of norplant contraceptive implants: II. Non-reproductive health. *Contraception.* 2001;63:187-120.
24. Cutolo M, Straub RH. Sex steroids and autoimmune rheumatic diseases: state of the art. *Nat Rev Rheumatol.* 2020;16:628-644.
25. Coskey RJ. Eruptions due to oral contraceptives. *Arch Dermatol.* 1977;113:333-334.
26. Thomas P, Dalle E, Revillon B, Delecour M, Devarenne-nicolle, Pagniez I. Cutaneous effects in hormonal contraception [in French]. *NPN Med.* 1985;5:19-24.
27. Jones JA, Shuler MJ, Zlotoff BJ. Levonorgestrel-releasing intrauterine system causes a lichenoid drug eruption. *Cutis.* 2015;96:E13-E15.
28. Williams WV. Hormonal contraception and the development of autoimmunity: a review of the literature. *Linacre Q.* 2017;84:275-295.
29. Chen X, Wu X, Zhu H. Acute urticaria as a side effect of the Mirena® (levonorgestrel-releasing intrauterine system): a case report. *BMC Res Notes.* 2014;7:209.
30. Pereira A, Coker A. Hypersensitivity to Mirena—a rare complication. *J Obstet Gynaecol.* 2003;23:81.
31. Foer D, Buchkeit KM, Gargiulo AR, et al. Progesterone hypersensitivity in 24 cases: diagnosis, management and proposed renaming and classification. *J Allergy Clin Immunol Pract.* 2016;4:723-729.
32. Li RC, Buchheit KM, Bernstein JA. Progesterone hypersensitivity. *Curr Allergy Asthma Rep.* 2018;18:1.
33. Hart R. Autoimmune progesterone dermatitis. *Arch Dermatol.* 1977;113:426-30.
34. Maguire T. Autoimmune progesterone dermatitis. *Dermatol Nurs.* 2009;21:190-192.
35. George R, Badawy SZ. Autoimmune progesterone dermatitis: a case report. *Case Rep Obstet Gynecol.* 2012;2012:757854.
36. Cristaudo A, Bordignon V, Palamara F, De Rocco M, Pietravallo M, Picardo M. Progesterone sensitive interferon-gamma producing cells detected by ELISpot assay in autoimmune progesterone dermatitis. *Clin Exp Dermatol.* 2007;32: 439-441.
37. Nguyen T, Razzague A. Autoimmune progesterone dermatitis: update and insights. *Autoimmun Rev.* 2016;15:191-197.
38. Tefany FJ, Georgouras K. A neutrophilic reaction of Sweet's syndrome type associated with the oral contraceptive. *Australas J Dermatol.* 1991;32:55-59.
39. Siroux V, Oryszczyn MP, Varraso R, et al. Environmental factors for asthma severity and allergy results from the EGEA study. *Rev Mal Respir.* 2007;24:599-608.
40. Sabatini R, Cagiano R, Rabe T. Adverse effects of hormonal contraception. *J Reproduktionsmed Endokrinol.* 2011;8:130-156.
41. Mosovich B, Biton A, Avinoach I. Vasculitis with cutaneous necrosis induced by oral contraceptive. *Harefuab.* 1991;120:451-453.