

# Functional MRI evaluation of the effect of carotid artery stenting: a case study demonstrating cognitive improvement

Acta Radiologica Open  
10(2) 1–10  
© The Foundation Acta  
Radiologica 2021  
Article reuse guidelines:  
sagepub.com/journals-permissions  
DOI: 10.1177/2058460120988822  
journals.sagepub.com/home/arr



Betty Chinda<sup>1,2</sup> , Simon Liang<sup>3</sup> , William Siu<sup>4</sup>,  
George Medvedev<sup>5</sup> and Xiaowei Song<sup>1,2</sup>

## Abstract

**Background:** The narrowing of the carotid arteries with plaque formation represents a major risk factor for ischemic stroke and cognitive impairments. Carotid angioplasty and stenting is a standard clinical treatment to reduce stroke risk. The cognitive effect of carotid angioplasty and stenting remains largely unknown.

**Purpose:** This study aims to provide direct evidence of possible effects of carotid angioplasty and stenting on cognition, using task-phase functional magnetic resonance imaging.

**Material and Methods:** This study received harmonized institutional ethics board approval (Grant number REB ID =H18-02495/FHREB 2018-058). Two patients had MRI scans pre-carotid angioplasty and stenting and two-month post-carotid angioplasty and stenting. Case 1 had severe (>95%) flow-limiting stenosis in the right carotid artery. Case 2 had 70% non-flow limiting stenosis in the left carotid artery. At each scan, patients completed two functional magnetic resonance imaging sessions while performing a working memory task. Accuracy, reaction time, and brain activation were analyzed for each patient for possible pre-post carotid angioplasty and stenting changes.

**Results:** Case 1 showed increased activation in the right (treated-side) frontal and temporal lobes post-carotid angioplasty and stenting; associated with improvements in accuracy (from 58% to 74%) and task completion rate (from 17% to 72%). Case 2 completed the tasks pre- and post-carotid angioplasty and stenting with >90% accuracy, while decreased functional magnetic resonance imaging activation in the contralateral (untreated) hemisphere and mildly increased activation in the left (treated -side) anterior circulation territory were observed post-carotid angioplasty and stenting.

**Conclusion:** These cases provided the first task-phase functional magnetic resonance imaging data demonstrating that carotid angioplasty and stenting improved cognitive function in the re-perfused vascular territory. The finding supports the role of carotid angioplasty and stenting in improving cognitive performance beyond reducing stroke risk.

## Keywords

Carotid stenosis, carotid angioplasty and stenting, task-phase functional magnetic resonance imaging, stroke, cognitive function, prospective case study

Received 27 June 2020; accepted 30 December 2020

## Introduction

The narrowing of the carotid arteries with plaque formation is a major risk factor for ischemic stroke.<sup>1</sup> One standard option for treating significant carotid stenosis is the carotid angioplasty and stenting (CAS) procedure, which has been shown to be beneficial for stroke risk reduction.<sup>2</sup> When the stenosis is severe ( $\geq 70\%$  stenosis), blood flow via the carotid arteries is impacted, leading to decreased cerebral perfusion.<sup>3</sup> This potentially can result in clinically significant cognitive impairments in several domains, and notably in executive functioning and working memory.<sup>4</sup> However, the effects of CAS

<sup>1</sup>Health Sciences and Innovation, Surrey Memorial Hospital, Fraser Health Authority, British Columbia, Canada

<sup>2</sup>Department of Biomedical Physiology & Kinesiology, Simon Fraser University, British Columbia, Canada

<sup>3</sup>Department of Medicine, University of British Columbia, British Columbia, Canada

<sup>4</sup>Division of Radiology, Royal Columbian Hospital, British Columbia, Canada

<sup>5</sup>Division of Neurology, Royal Columbian Hospital, British Columbia, Canada

### Corresponding author:

William Siu, Royal Columbian Hospital, 330 E Columbia St, New Westminster, BC V3L 3W7, Canada.  
Email: William.Siu@fraserhealth.ca



on cognition are not well understood. Current clinical standard evaluates primarily the successful completion of the procedure by assessing correct stent placement and perioperative complications, notably the 30-day stroke rate, myocardial infarction rates and death.<sup>5</sup> Previous research has mostly relied on paper-based cognitive tests to study the cognitive impact of CAS in patients with carotid stenosis without direct measure of brain activity, and revealed conflicting results<sup>6-9</sup> that suggested either positive<sup>7,8</sup> or negative<sup>6,9</sup> impact of CAS on cognition. Studies that utilized functional magnetic resonance imaging (fMRI) have been conducted at resting-phase and showed functional connectivity changes with CAS.<sup>10-12</sup> Even so, the resting-state fMRI data lacked the ability to detect the brain functional changes in solving cognitive problems that require the application of task-phase fMRI. Task-phase fMRI as utilized here has provided an objective method of evaluating brain activation as measured by the blood-oxygen level dependent (BOLD) response when paired to specific fMRI tasks such that cerebral recruitment can be spatially and temporally isolated.<sup>13</sup>

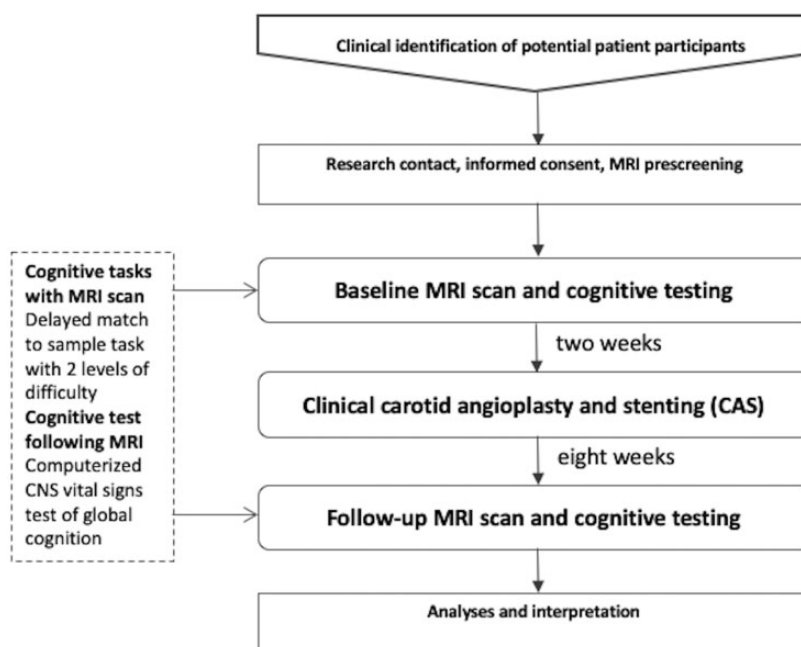
Here, we used task-phase BOLD fMRI in viewing the brain at work when dealing with a working memory task, aiming to provide more direct evidence in understanding the effects of CAS on cognition. The main goal of this

research is to initiate the evaluation of the fMRI changes for patients with severe carotid stenosis, comparing pre- and post-carotid artery revascularization by carotid angioplasty and stenting. To achieve this goal, we investigated the brain functional activation in response to cognitive task pre- and post-CAS, evaluated the correlation between brain functional activation and behavioral performances in conducting the fMRI task (response speed, accuracy, and completion rate), and examined the brain functional activation in relation to global cognition.

## Methods

This study was built on top of standard clinical care for patients with carotid stenosis and has received harmonized institutional human research ethics board approval from Fraser Health Authority, Simon Fraser University and the University of British Columbia (H18-02495/FHREB 2018-058). Upon identification of a suitable patient for CAS with potential research participation by the treating physician, the research team recruited and consented the patient participants, and scheduled the initial research MRI scans (Fig. 1). Prospective patients were 19–90 years of age with a diagnosis of severe cervical carotid artery stenosis who needed the carotid stenting procedure, and could provide informed written consent, pass the MRI safety

### Study design and clinical-research interaction flowchart



**Fig. 1.** Study design and clinical-research interaction flowchart. This is the flowchart demonstrating the study design and the flow of participants. Upon identification of a suitable patient for CAS with potential research participation by the treating physician, the research team recruited and consented the patient participants, and scheduled the initial research MRI scans. The study involved a baseline MRI, followed by CAS within two weeks, and another MRI two months' post CAS.

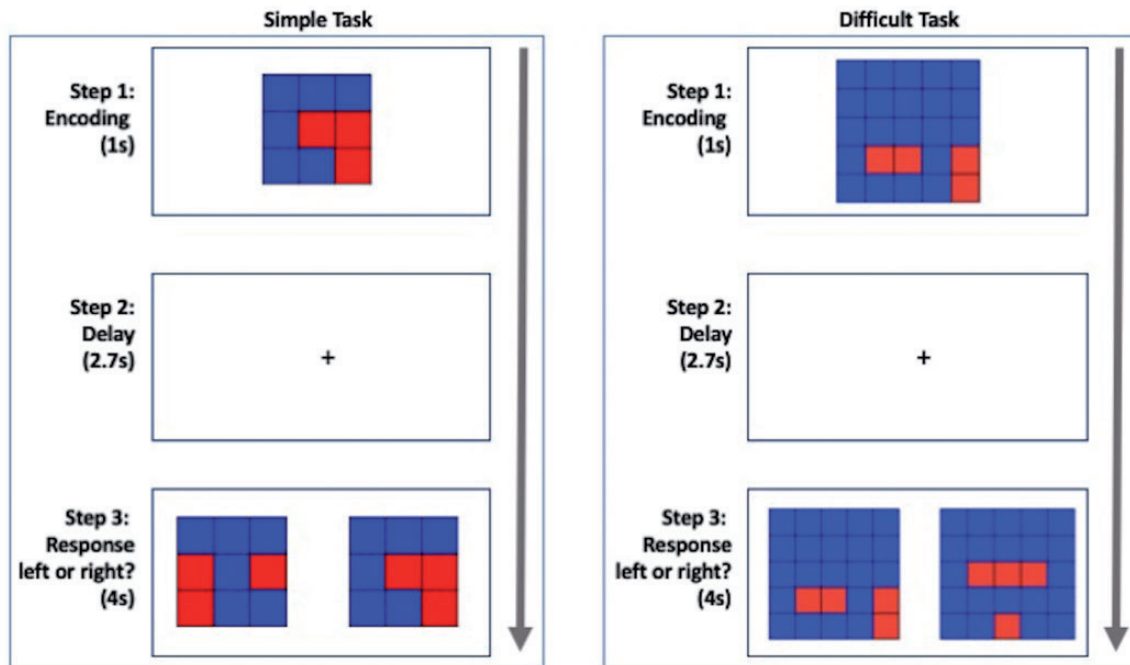
screening, were fluent in English, and with normal or corrected vision and hearing abilities.

The study involved a baseline MRI, followed by CAS within two weeks (performed by (W.S), a radiologist with over 20 years of experience), and another MRI two months' post CAS (Fig. 1). At each research appointment, the patients performed a battery of neurocognitive tests (i.e. CNS vital signs or CNSVS, a validated computerized assessment tool adapted from paper-based conventional cognitive tests<sup>14</sup> that evaluates a range of cognitive domains including complex attention, working memory, and executive function with automated scoring) on a computer, following the MRI scan (Fig. 1).

MRI scans were conducted using a whole-body Philips Ingenia 3.0T CX Quasar Dual MRI system equipped with 32-channel dStream head coil and operated by Release 5.3 (Philips Medical Systems Nederland B.V.). At each MRI scan, patients completed two task-phase fMRI sessions that lasted for approximately 5 min each. The fMRI utilized an echo planar imaging (GRE-EPI) sequence (TR/TE = 2000/30 ms, flip angle = 90°,  $3 \times 3 \times 3 \text{ mm}^3$  voxels covering the whole-brain). High-resolution anatomical T1 images (for co-registration) were acquired.

The delayed match to sample working memory task<sup>15,16</sup> was applied, adapted with modification for the study with two levels of task difficulties (Fig. 2). The task began with presentation of a stimulus (for encoding), followed by a 2.7s delay, and then a response, for which participants were instructed to indicate the stimulus shown before, when it was presented together with a distractor image (Fig. 2). Two levels of task difficulties were implemented using simple ( $3 \times 3$  grid) and difficult ( $5 \times 5$  grid) stimuli. The delayed match to sample task was chosen as it has been well-validated for testing working memory and executive functioning,<sup>15,16</sup> i.e. cognitive domains important for coordination of goal-driven, complex and guided behavior,<sup>17</sup> representing impacted areas often observed in carotid stenosis patients.<sup>18</sup> The task was also easy to understand/perform by the patients.

fMRI data processing was carried out using FEAT (FMRI Expert Analysis Tool) Version 6.00, part of FSL (FMRIB's Software Library, [www.fmrib.ox.ac.uk/fsl](http://www.fmrib.ox.ac.uk/fsl)) following the standard processing procedures.<sup>19–21</sup> These included non-brain tissue (e.g. skull) removal, motion correction, spatial smoothing (5 mm), grand-mean intensity normalization of the entire 4D dataset, and highpass temporal filtering (50 s). Functional data were co-registered to high resolution



**Fig. 2.** fMRI task design. This is the fMRI task presented to the patients in the study. It is the delayed match to sample task which begins with presenting the study stimulus (encoding), followed by a delay, and then a response time in which participants must correctly select the study stimulus when it is presented together with a distractor image. There are two levels of task complexity; a simple ( $3 \times 3$  grid) and a difficult ( $5 \times 5$  grid) task. Each participant had two BOLD-fMRI scans to perform both levels of the task. The task is presented in a block design with five blocks and six rest phases. Each block contains 6 stimuli such that a total of 30 responses are collected in each fMRI scan session.

structural (T1-weighted) and standard space (MNI152 1 mm) images. Time-series statistical analysis was carried out using FILM with local autocorrelation correction, fitting to the GLM ( $Z > 2.0$  at  $p < 0.05$  cluster-corrected). Higher level analysis was carried out using a fixed effects model in FLAME, applying contrasts to compare between tasks (i.e. simple vs. difficult) and time points (i.e. pre vs. post CAS). For each fMRI scan/task, region of interest (ROI) analyses were also performed to evaluate brain regions known to be important for working memory and attention, comparing pre-post CAS on the filtered time series and percentage of activated voxels within the ROI using Featquery.

Performance accuracy and reaction time (RT) in response to fMRI tasks were examined using pairwise  $t$ -test ( $p < 0.05$ ). Changes in brain fMRI activation and behavioral performance were compared for each patient pre/post CAS.

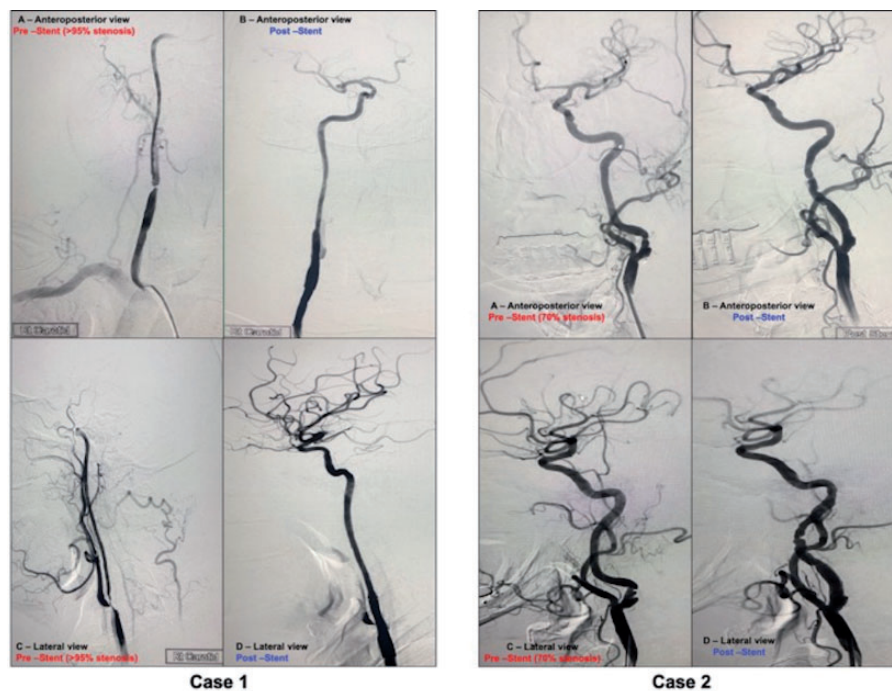
## Case studies

### Case 1

**Initial clinical presentation and MRI.** A 65-year-old man of South Asian origin was referred for treatment of an asymptomatic pre-occlusive carotid stenosis found on

a CT angiogram scan performed for dizziness following coronary bypass surgery. He had a history of myocardial infarction treated by coronary bypass surgery. He has type 2 diabetes, hypertension, and hypercholesterolemia and is a previous smoker. Further evaluation via a CT angiogram scan showed a pre-occlusive stenosis ( $>95\%$ , determined using NASCET criteria) at the origin of the right internal carotid artery (Fig. 3). The circle of Willis anatomy showed a patent anterior communicating artery and a small right posterior communicating artery. He received the CAS procedure (a Medtronic Protégé tapered 8/6 mm $\times$ 30 mm nitinol stent with distal protection using an EV3 Spider filter device) to restore flow in the affected right carotid artery (Fig. 3) 13 days after his baseline MRI scan. There were no complications and post-CAS stenosis rate was  $<20\%$ . He undertook the second MRI scan 86 days post-CAS.

**Results.** Poor cognitive performance was observed pre-CAS, which significantly improved post-CAS (Table 1). Pre-CAS, the patient encountered difficulties in task completion (80% missing in simple task; 86% missing in difficult task) and performed poorly in terms of accuracy (67% simple, 50% difficult). Post-CAS, there was improvements in both task completion rate (43%

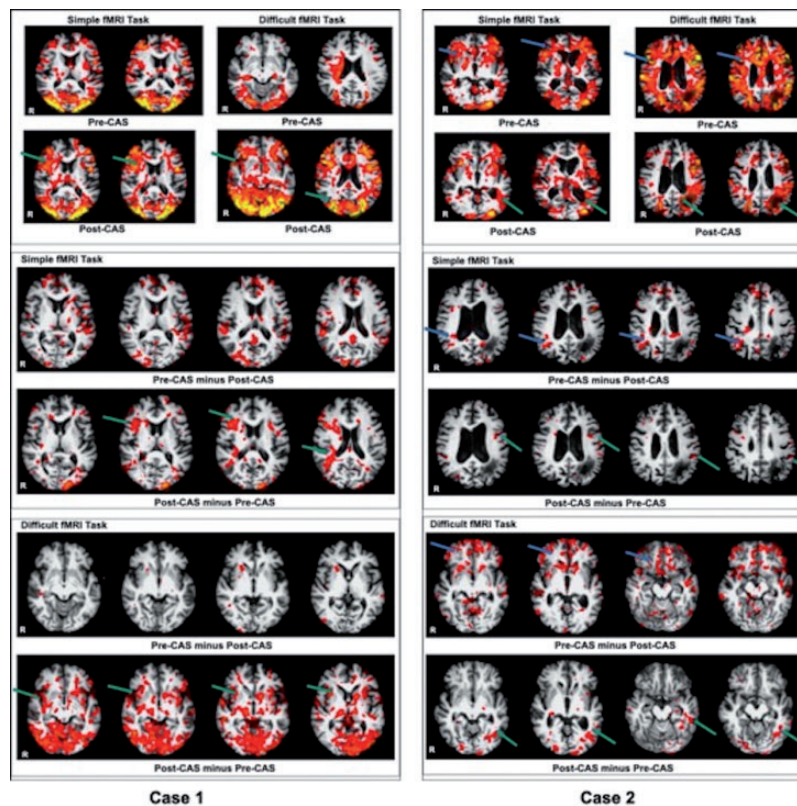


**Fig. 3.** Carotid angiogram pre-and post-stenting in anteroposterior and lateral projections. The left figure shows the carotid angiogram for Case 1 with right carotid artery flow-limiting stenosis ( $>95\%$ , determined using NASCET criteria), while the right figure shows Case 2 with left carotid artery non-flow-limiting stenosis (70%, determined using NASCET criteria). The top and bottom panels show the anteroposterior and lateral projections respectively. In each panel, the left image shows the pre-CAS artery with the stenosis, while the right image shows the post-CAS artery with the stent implanted.



**Table 1.** fMRI task performance pre-and post CAS.

Task type	Pre-CAS			Post CAS		
	Reaction time (ms)	Accuracy (%)	Missed (%)	Reaction time (ms)	Accuracy (%)	Missed (%)
Case 1						
Simple	1974.9 ± 869.6	66.7	80.0	2295.1 ± 857.1	70.5	43.3
Difficult	1712.2 ± 1336.0	50.0	86.7	2042.2 ± 706.9	77.0	13.3
Case 2						
Simple	1277.0 ± 267.7	96.7	0.0	1280.1 ± 361.0	93.3	0
Difficult	1546.2 ± 474.8	100.0	3.3	1321.4 ± 405.0	90.0	0

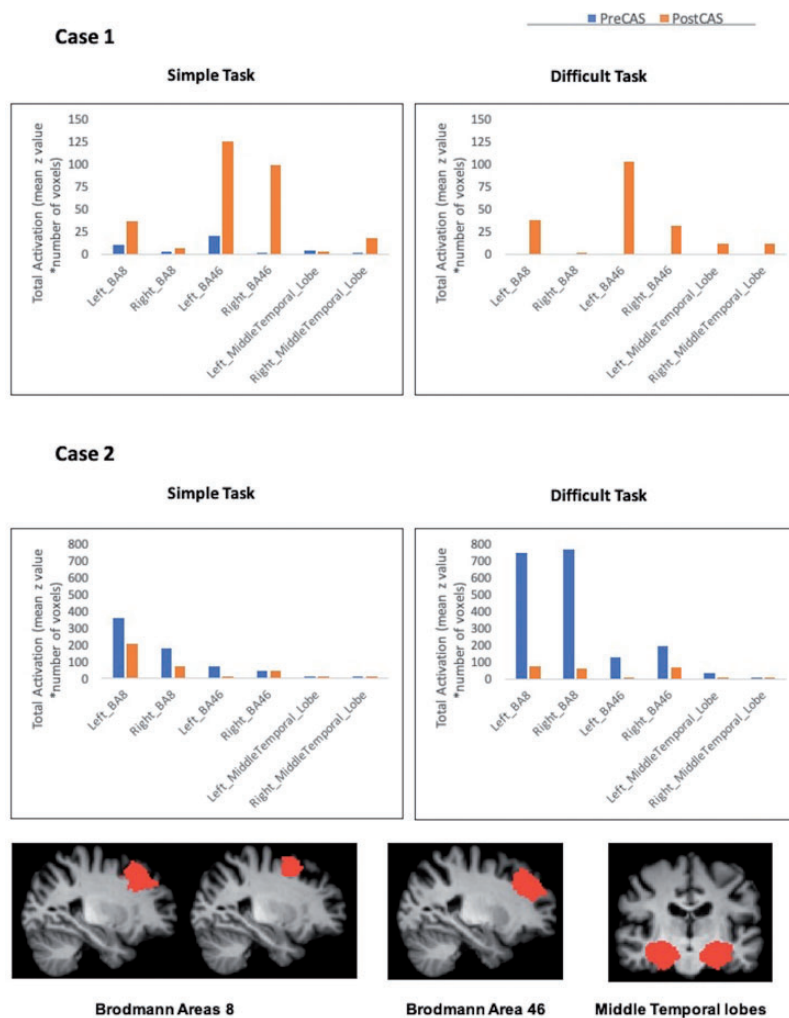


**Fig. 4.** fMRI activation maps. These figures show the fMRI activation maps for the cases. Z statistic images were thresholded non-parametrically using clusters determined by  $Z > 2$  and a (corrected) cluster significance threshold of  $p = 0.05$ . The marking “R” indicates the right side of the brain. The top panel shows comparison of brain activation for both the simple and difficult tasks for the two time-points (pre-and post-CAS); the middle and bottom panels show subtraction images of the two time-points for the simple and difficult tasks respectively. The left figure represents Case 1. In general, more activations were found in the treated right hemisphere post-CAS (as indicated by green arrows). The right figure represents Case 2. In general, post-CAS, fMRI activations are more prominent in the treated left hemisphere (as indicated by green arrows) and reduced in the contralateral hemisphere (as indicated by blue arrows).

missing in simple task; 13% missing in difficult task) and accuracy (71% simple, 77% difficult). However, reaction times increased slightly post-CAS compared to pre-CAS (simple  $t = -0.78$ ,  $p = 0.459$  two-tailed; difficult  $t = -0.77$ ,  $p = 0.448$ )

The fMRI brain activation maps for Case 1 showed increased activations in the treated right anterior

circulation territory, especially in the frontal and temporal lobes with simple and difficult tasks post-CAS compared to pre-CAS (Fig. 4). Query into activations in specific brain regions showed a corresponding increased activations post-CAS (Fig. 5) in the medial temporal lobes and the dorsal frontal cortical network (Brodmann Areas 8 and 46). The CNSVS scores for



**Fig. 5.** Strength of brain activation in regions associated with cognition. This figure shows a query into the dorsal frontal cortical network (BA 8 and 46) as well as the medial temporal lobes for both cases on the simple and difficult tasks pre (blue) and post (red) CAS. The bars represent the strength of fMRI activation generated by multiplying the mean value and number of the z-thresholded voxel clusters. In Case 1 (top panel), there is increased activations post CAS for all brain regions, especially in Brodmann Area 46 and is seen most for the difficult task which had zero activations pre-CAS. There is also a dramatic increase in activation post CAS in the right hemisphere (side of stenting) – this is illustrated in the simple fMRI task. In Case 2 (bottom panel), there is decreased activations post CAS for all brain regions, especially in Brodmann Area 8 and is seen most for the difficult task. This is consistent with the behavioral results for Case 2 who had excellent performance at baseline for which CAS did not have much effect.

Case 1 showed an improvement in the cognitive domains of processing speed and reaction time Post-CAS (Table 2). Table 2 shows the raw test scores and the standard scores corrected for age for each patient. The standard scores (mean = 100, SD = 15) for each cognitive domain are calculated based on a normative database of healthy Americans.<sup>14</sup>

### Case 2

**Initial clinical presentation and MRI.** An 81-year-old man of Caucasian origin was referred for CAS for a symptomatic carotid stenosis. He had episodes of transient ischemic attacks, consisting of episodes of aphasia and

amaurosis fugax. He had a history of coronary stenting, and is awaiting further coronary artery revascularization treatment for unstable angina. He underwent imaging workup of his carotid artery with Doppler ultrasound and CT angiogram scan that showed a significant (70%, determined using NASCET criteria) left carotid stenosis (Fig. 3). The circle of Willis anatomy showed a hypoplastic A1 segment of the left anterior cerebral artery and bilateral hypoplastic posterior communicating arteries. He received the CAS procedure (a Medtronic Protégé tapered 8/6 mm × 30 mm nitinol stent with distal protection using an EV3 Spider filter device) to restore the caliber of the affected left carotid artery (Fig. 3) two days after his baseline MRI scan.

**Table 2.** Computerized cognitive performance pre-and post CAS.

	Pre-CAS		Post-CAS	
	Raw score	Standard score	Raw score	Standard score
Case 1				
Neurocognition index		64		54
Composite memory	88	88	80	74
Verbal memory	47	90	41	72
Visual memory	41	90	39	84
Psychomotor speed	101	67	40	28
Reaction time	1198	44	1058	60
Complex attention	29	65	32	60
Cognitive flexibility	-15	54	-20	50
<b>Processing speed</b>	<b>11</b>	<b>57</b>	<b>21</b>	<b>70</b>
Executive function	-11	56	-81	49
Simple attention	40	108	40	108
Motor speed	88	82	19	19
Case 2				
Neurocognition index		96		93
Composite memory	90	104	76	80
Verbal memory	47	101	44	93
Visual memory	43	107	32	74
<b>Psychomotor speed</b>	<b>124</b>	<b>104</b>	<b>132</b>	<b>109</b>
Reaction time	812	106	862	100
Complex attention	26	82	24	85
<b>Cognitive flexibility</b>	<b>-1</b>	<b>84</b>	<b>4</b>	<b>88</b>
<b>Processing speed</b>	<b>22</b>	<b>92</b>	<b>31</b>	<b>106</b>
<b>Executive function</b>	<b>4</b>	<b>88</b>	<b>8</b>	<b>91</b>
Simple attention	40	110	39	102
<b>Motor speed</b>	<b>99</b>	<b>108</b>	<b>101</b>	<b>109</b>

The bold characters signifies cognitive domains in which patients showed improvements Post-CAS.

The raw scores are the actual patient scores on each cognitive domain. Patient standard scores for each domain are calculated based on the distribution (mean = 100, standard deviation = 15) of the cognitive data for healthy controls of same age. A standard score of 90 and above shows normal cognitive function in that domain.

There were no complications and post-CAS stenosis rate was <20%. He undertook the second MRI scan 81 days post-CAS.

**Results.** Excellent baseline cognitive performance (>90% accuracy, mean missing = 0.8%) was observed pre-CAS across both the simple and difficult tasks, which was not improved further by the CAS procedure (Table 1). There was a slight increase in reaction time post CAS for the difficult task (simple  $t = -0.04$ ,  $p = 0.970$  two-tailed; difficult  $t = 1.96$ ,  $p = 0.028$ ).

The fMRI brain activations maps showed decreased activations in the contralateral right hemisphere to the treated side and mild increased activation in the left anterior circulation territory, namely in the left temporal lobe post-CAS (Fig. 4). Query into activations in specific brain regions did not show improvements with CAS (Fig. 5). The CNSVS scores for Case 2 showed an improvement in several cognitive domains including psychomotor speed, cognitive flexibility, motor speed,

processing speed, and executive function post-CAS (Table 2).

## Discussion

These clinical case studies showed that improved cerebral perfusion to areas supplied by carotid arteries following CAS is correlated with improved cognitive function in working memory performance along with increased fMRI activations in the re-perfused vascular territory. Pre-CAS, fMRI activations are generally more prominent in the contralateral frontal and temporal lobes, areas that have been shown to be important in working memory and decision-making.<sup>22</sup> Post-CAS, fMRI activations are more prominent in the treated frontal and temporal lobes and reduced in the contralateral hemisphere. In Case 1, the reaction time increased post-CAS for both tasks, and was associated with higher-level task performance and may infer that the patient had paid more attention to the task post-

CAS. Case 1 had increased activations in the queried brain regions covering the medial temporal lobes and Brodmann Areas 8 and 46 (part of the dorsal frontal cortical network). These networks have been shown to be areas involved in working memory performance,<sup>22</sup> suggesting cognitive improvement resulting from the clinical procedure with reestablished cerebral circulation and perfusion. While post-CAS improvements in the CNSVS performance were consistently observed in processing speed in both cases, variability existed in several domains, presumably reflecting the complexity and lesser sensitivity of the subjective test, compared to directly “viewing” the functional brain activation on MRI, especially given the relatively short follow-up time.

There was considerable individual variability between the two cases that had impacted the cognitive changes observed post-CAS. One of these variations is the severity and degree of flow limitation of the stenosis, which impacts the degree of cognitive impairment by affecting the rate of hypo-perfusion and silent embolization in the affected area.<sup>23</sup> This could explain why Case 1 (with >95% flow-limiting stenosis pre-CAS) had more cognitive improvements post-CAS compared to Case 2 (with only 70%). Another source of variation is the Circle of Willis anatomy and collateral flow to the affected circulation territory pre- and post CAS. Typically, patients with very severe ICA stenosis can present with normal levels of cognition if the collateral blood supply system is not compromised.<sup>24</sup> For case 1, the Circle of Willis consists of a small right posterior communicating artery (PCOMM) and a small anterior communicating artery (ACOMM). Prior to the right carotid stenting, the right middle cerebral artery territory was likely receiving collateral flow via the right PCOMM and ACOMM, which prevented infarction but we theorized the flow was insufficient to allow full function of the neurons in the MCA territory due to compromised blood flow secondary to the severe flow-limiting carotid stenosis. Hence, we predicted the fMRI will show dampened activity in the right MCA territory prior to stenting and increased fMRI activity after stenting after restoring blood flow to the territory. For case 2, the Circle of Willis consists of a hypoplastic left PCOMM and a slightly hypoplastic A1 segment of the left anterior cerebral artery. As the moderately severe left carotid stenosis was not flow limiting, the left middle cerebral artery was theorized to receive adequate blood flow prior to stenting and the fMRI will not show any obvious dampened activity. After stenting, with improved blood flow to the left MCA territory, the fMRI activity in the MCA territory may only increase marginally, if at all. For case 1, after restoring flow to the right MCA territory by treating a flow-limiting carotid stenosis in an individual with an

inadequate Circle of Willis anatomy, there was clinical neurological improvement, which was demonstrated by fMRI testing with anatomical mapping. For case 2, as the carotid stenosis was not flow limiting, there was no dramatic clinical and fMRI improvement demonstrated after stenting. The subjects' base line cognitive function and reserve pre-CAS can also impact the effects of the stenting procedure. Cases with lower cognitive reserve at baseline (Pre-CAS) showed the most cognitive improvements with the stenting procedure (e.g. Case 1) compared to cases with great cognitive reserve from baseline (e.g. Case 2).

This study to the best of our knowledge is the first to address the gap of a direct and objective measure of the cognitive impact of CAS for the treatment of severe carotid stenosis. The BOLD response in task-phase fMRI is paired to the specific fMRI task such that cerebral recruitment is spatially and temporally isolated.<sup>13</sup> In this way, we can connect the relationship between the treatment and specific brain activations. This is an improvement upon current clinical standard which just evaluates the success as the completion of the procedure without perioperative complications.<sup>5</sup> Previous research studies relying on only paper-based/adapted routine neurocognitive tests have been largely conflicting in their results.<sup>6-9</sup> While some studies have utilized resting-state fMRI<sup>10-12</sup> to show functional connectivity changes with CAS, our study has the advantage of using task-phase fMRI to map out specific brain areas associated with memory improvement in patients undergoing CAS.

One caveat to consider while interpreting the results of this study is that the finding was based on only two cases, which showed a considerable individual variability. Hence, the generalizability of the results warrants further investigations. Even so, the follow-up nature of the study allowed each patient to have duplicate scans for pre-post comparison and provides individual patient oriented evidence of the impact of CAS on cognition. Enlightened by these cases, we hope to further test the cognitive outcomes of artery stenting using task-phase fMRI as described here with increased sample size and more follow-up sessions, involving matched healthy control participants.

In conclusion, we have demonstrated using task-phase fMRI that CAS holds some promise in improving cognition for patients with flow-limiting carotid stenosis. The clinical significance of this study is paramount. The results from this study have the potential to map out brain areas associated with memory improvement in patients undergoing CAS. This could translate into improving evidence-based clinical decision making by demonstrating CAS' role in improving patient memory. In doing so, the study has potential to inform clinical care by highlighting the necessity for



CAS intervention for patients who have asymptomatic stenosis with regards to displaying TIA or other stroke symptoms, but are rather “symptomatic” with regards to cognitive decline.

### Authorship and contributions

BC conducted the literature review and prepared the research documents, performed the MRI experiment and cognitive testing, analyzed functional MRI data, prepared result presentation, helped with patient recruitment and consent, and drafted the first manuscript. SL performed patient recruitment and enrolment, helped with research documents preparation, neurocognitive tests preparation, data analysis, and results preparation, and reviewed the manuscript. WS conceptualized the clinical need, identified and enabled the initial contact to the potential patient participants, organized the research funding application, verified imaging quality, supervised research documents preparation and results presentation, and drafted the clinical sections of the manuscript. GM conceptualized the neurocognitive testing, helped in functional MRI experimental design, supervised cognitive testing and research documents preparation, and reviewed the manuscript. XS enabled the research funding and trainee supports, provided trainings in MRI research and project coordination, supervised research documents preparation, experimental design, implementation, and optimization, data acquisition, analysis and result preparation, and helped draft the first manuscript. All authors participated in result interpretation and manuscript revision, and agree upon publication of the paper.

### Acknowledgements

The authors would like to thank Bob Strain and Kim Crooks-William, patient partners of the research project for their valuable and constructive contributions. We thank the patient participants for volunteering in the study. We thank the SFU ImageTech Lab for approval for the research team to conduct the MRI experiment with 3 h of pilot scans at reduced MRI scanner fee charge. The authors acknowledge the Departments of Medical Imaging, Interventional Radiology and Neurology at Royal Columbian Hospital, Department of Evaluation and Research Services, and Surrey Memorial Hospital of Fraser Health for technical and administrative supports.

### Declaration of Conflicting Interests

The author(s) declared no potential conflicts of interest with respect to the research, authorship, and/or publication of this article.

### Funding

The author(s) disclosed receipt of the following financial support for the research, authorship, and/or publication of this article: This work was supported by a research grant from the Royal Columbian Hospital Foundation (G2019-21000). Additional research and scholarship supports were from the Surrey Hospital Foundation (G2017-001), Canadian Institute of Health Research Graduate Scholarship Program and the BC SUPPORT Unit Fraser Centre SPOR initiative.

### ORCID iDs

Betty Chinda  <https://orcid.org/0000-0002-2180-1849>

Simon Liang  <https://orcid.org/0000-0001-8001-7328>

### References

1. Flaherty ML, Kissela B, Khoury JC, et al. Carotid artery stenosis as a cause of stroke. *Neuroepidemiology* 2013;40:36–41.
2. Morris DR, Ayabe K, Inoue T, et al. Evidence-based carotid interventions for stroke prevention: state-of-the-art review. *J Atheroscler Thromb* 2017;24:373–387.
3. Moneta GL, Edwards JM, Chitwood RW, et al. Correlation of North American Symptomatic Carotid Endarterectomy Trial (NASCET) angiographic definition of 70% to 99% internal carotid artery stenosis with duplex scanning. *J Vasc Surg* 1993;17:152–159.
4. Zheng S, Zhang M, Wang X, et al. Functional MRI study of working memory impairment in patients with symptomatic carotid artery disease. *Biomed Res Int* 2014;2014:327270.
5. Higashida RT, Meyers PM, Phatouros CC, et al. Reporting standards for carotid artery angioplasty and stent placement. *J Vasc Interv Radiol* 2004;15:421–422.
6. Plessers M, Van Herzele I, Vermassen F, et al. Neurocognitive functioning after carotid revascularization: a systematic review. *Cerebrovasc Dis Extra* 2014;4:132–148.
7. Yoon BA, Sohn SW, Cheon SM, et al. Effect of carotid artery stenting on cognitive function in patients with carotid artery stenosis: a prospective, 3-month-follow-up study. *J Clin Neurol* 2015;11:149–156.
8. Whooley JL, David BC, Woo HH, et al. Carotid revascularization and its effect on cognitive function: a prospective nonrandomized multicenter clinical study. *J Stroke Cerebrovasc Dis* 2020;29:104702.
9. Gaudet JG, Meyers PM, McKinsey JF, et al. Incidence of moderate to severe cognitive dysfunction in patients treated with carotid artery stenting. *Neurosurgery* 2009;65:325–330.
10. Tani N, Yaegaki T, Nishino A, et al. Functional connectivity analysis and prediction of cognitive change after carotid artery stenting. *J Neurosurg* 2018;131:1709–1715.
11. Schaaf M, Mommertz G, Ludolph A, et al. Functional MR imaging in patients with carotid artery stenosis before and after revascularization. *Am J Neuroradiol* 2010;31:1791–1798.
12. Wang T, Sun D, Liu Y, et al. The impact of carotid artery stenting on cerebral perfusion, functional connectivity,

- and cognition in severe asymptomatic carotid stenosis patients. *Front Neurol* 2017;8:403.
13. Ogawa S, Lee TM, Kay AR, et al. Brain magnetic resonance imaging with contrast dependent on blood oxygenation. *Proc Natl Acad Sci U S A* 1990;87:9868–9872.
  14. Gualtieri CT, Johnson LG. Reliability and validity of a computerized neurocognitive test battery, CNS vital signs. *Arch Clin Neuropsychol* 2006;21:623–643.
  15. Daniel TA, Katz JS, Robinson JL. Delayed match-to-sample in working memory: a BrainMap meta-analysis. *Biol Psychol* 2016;120:10–20.
  16. McDonald AP, D'Arcy RCN, Song X. Functional MRI on executive functioning in aging and dementia: a scoping review of cognitive tasks. *Aging Med* 2018;1:209–219.
  17. D'Esposito M, Postle BR. The cognitive neuroscience of working memory. *Annu Rev Psychol* 2015;66:115–142.
  18. Sztrihá LK, Nemeth D, Sefcsik T, et al. Carotid stenosis and the cognitive function. *J Neurol Sci* 2009;283:36–40.
  19. Jenkinson M, Bannister P, Brady M, et al. Improved optimization for the robust and accurate linear registration and motion correction of brain images. *Neuroimage* 2002;17:825–841.
  20. Woolrich MW, Ripley BD, Brady M, et al. Temporal autocorrelation in univariate linear modeling of FMRI data. *Neuroimage* 2001;14:1370–1386.
  21. Worsley KJ. Statistical analysis of activation images. In: P Jezzard, PM Matthews, SM Smith (eds) *Functional MRI. An introduction to methods*. Oxford: Oxford University Press, 2001, pp.251–270.
  22. Sallet J, Mars RB, Noonan MP, et al. The organization of dorsal frontal cortex in humans and macaques. *J Neurosci* 2013;33:12255–12274.
  23. Zuccalà G, Onder G, Pedone C, et al. Hypotension and cognitive impairment: selective association in patients with heart failure. *Neurology* 2001;57:1986–1992.
  24. Wei W, Yi X, Ruan J, et al. Influence of collateral circulation on cerebral blood flow and frontal lobe cognitive function in patients with severe internal carotid artery stenosis. *BMC Neurol* 2019;19:151.