




Since January 2020 Elsevier has created a COVID-19 resource centre with free information in English and Mandarin on the novel coronavirus COVID-19. The COVID-19 resource centre is hosted on Elsevier Connect, the company's public news and information website.

Elsevier hereby grants permission to make all its COVID-19-related research that is available on the COVID-19 resource centre - including this research content - immediately available in PubMed Central and other publicly funded repositories, such as the WHO COVID database with rights for unrestricted research re-use and analyses in any form or by any means with acknowledgement of the original source. These permissions are granted for free by Elsevier for as long as the COVID-19 resource centre remains active.



Does infection of 2019 novel coronavirus cause acute and/or chronic sialadenitis?



Chenxing Wang^{a,b}, Heming Wu^{a,b}, Xu Ding^{a,b}, Huan Ji^{a,b}, Pengfei Jiao^{a,b}, Haiyang Song^{a,b}, Sheng Li^{a,b}, Hongming Du^{a,b,*}

^a Department of Oral and Maxillofacial Surgery, Affiliated Stomatological Hospital of Nanjing Medical University, Nanjing, Jiangsu Province 210029, PR China

^b Jiangsu Key Laboratory of Oral Disease, Nanjing Medical University, Nanjing, Jiangsu Province 210029, PR China

ARTICLE INFO

Keywords:

2019-nCoV
Angiotensin-converting enzyme 2
Saliva
Sialadenitis
Clinical character

ABSTRACT

2019 novel coronavirus (2019-nCoV) is widespread in China and other countries. The target of 2019-nCoV and severe acute respiratory syndrome coronavirus (SARS-CoV) is angiotensin-converting enzyme 2 (ACE2) positive cells. ACE2 is present in the salivary gland duct epithelium, and thus it could be the target of 2019-nCoV and SARS-CoV. SARS-CoV-related animal model experiments show that it can infect the epithelial cells on the salivary gland duct in Chinese rhesus macaques by targeting ACE2. Clinical studies confirmed that 2019-nCoV and SARS-CoV could be detected in saliva of human patients. We hypothesize that the infection of 2019-nCoV and SARS-CoV will lead to inflammatory pathological lesions in patients' target organs, and possibly inflammatory lesions in salivary glands. 2019-nCoV may cause acute sialoadenitis in the acute phase of infection. After the acute phase, chronic sialoadenitis may be caused by fibrosis repairment. Although there was no direct evidence to prove this, the available indirect evidence indicates a high probability of our hypothesis.

Background

According to serological and genomic characteristics, coronaviruses are classified into four types, α , β , γ , and δ [1]. Current research shows that most coronaviruses infect animals, and only a few infect humans. The seven coronaviruses that are currently known to infect humans belong to types α and β . Both HCoV-229E and HCoV-NL63 belong to type α . HCoV-OC43, CoV-HKU1, Middle East respiratory syndrome coronavirus (MERS-CoV), severe acute respiratory syndrome coronavirus (SARS-CoV), and 2019 novel coronavirus (2019-nCoV), belong to type β . CoV-HKU1, SARS-CoV, MERS-CoV, and 2019-nCoV can cause human pneumonia [2].

At the end of 2019, 2019-nCoV pneumonia first occurred in Wuhan, China, and spread rapidly outward, leading to a mass epidemic, which has become a significant global public health incident [3,4]. Because of strong virulence, 2019-nCoV can cause severe acute respiratory infections (SARIs) [5,6]. With the accumulation of clinical cases and the progress of research, except for SARIs, 2019-CoV may also cause diarrhea, liver damage, and impaired organ function, e.g., in the kidneys and testes [7–10]. The above content shows some clinical characteristics of coronavirus disease 2019 (COVID-19) caused by 2019-nCoV

infection, but the clinical features still need to be further studied.

Current research results show that the spike protein receptor-binding domain (RBD) of 2019-nCoV can bind to ACE2 receptor on the host cells, thereby completing the adsorption [11]. This adsorption mechanism is the same as that of SARS-CoV [12,13]. 2019-nCoV can cause damage in respiratory and other organs and could be related to the distribution of ACE2 in human organs [5–10]. Therefore, cells with ACE2 receptor distribution may become host cells for 2019-nCoV and further cause inflammatory reactions in related organs.

Based on available publicity datasets in GTExportal (<https://gtexportal.org>), mRNA and ACE2 protein are detected in salivary glands [8]. Liu *et al.* reported ACE2 receptors in the epithelium of salivary gland ducts in Chinese rhesus macaques by immunohistochemistry [14]. Therefore, salivary glands are very likely to become targets of 2019-nCoV.

ACE2 is 2019-nCoV target

Since the discovery of SARS-CoV in 2002, many studies have proved that the RBD sequence of spike protein, which is located on the envelope of SARS-CoV, can specifically bind to the host receptor ACE2

* Corresponding author at: Department of Oral and Maxillofacial Surgery, Affiliated Stomatological Hospital of Nanjing Medical University, Hanzhong Road No.136, Nanjing, Jiangsu Province 210029, PR China.

E-mail address: dhm_010@sina.com (H. Du).

<https://doi.org/10.1016/j.mehy.2020.109789>

Received 2 March 2020; Received in revised form 23 March 2020; Accepted 23 April 2020

0306-9877/ © 2020 Elsevier Ltd. All rights reserved.

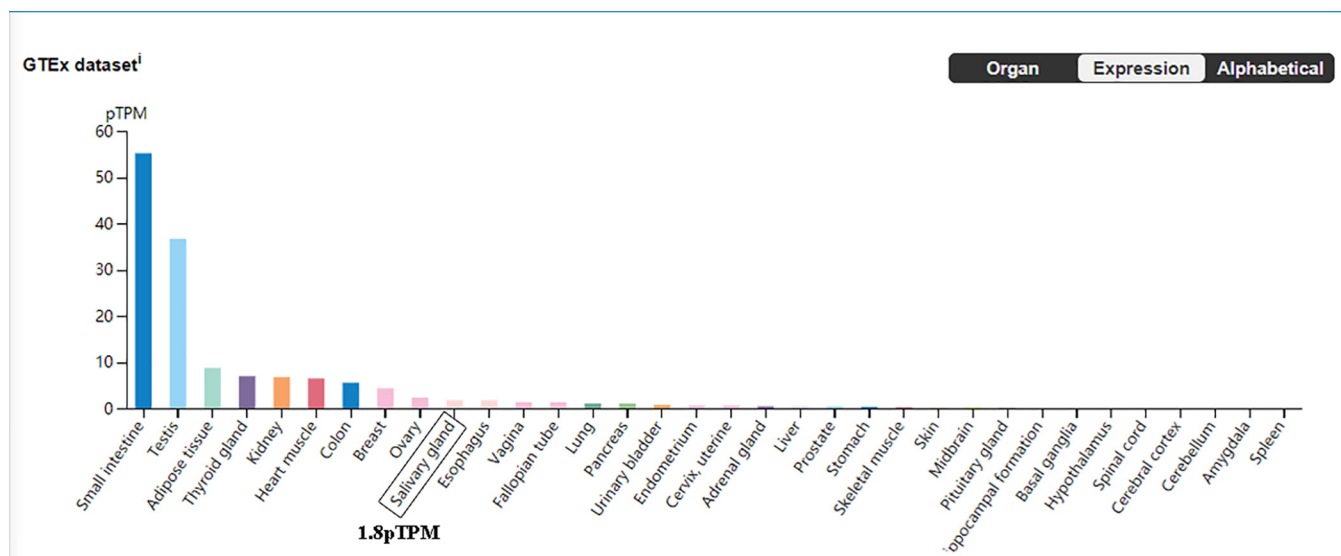


Fig. 1. ACE2 protein expression level in different human organs.

and then be adsorbed into host cells [12,13]. The connection between RBD and ACE2 also participates in the fusion of the virus and host cells and then stimulates the organism to produce neutralizing antibodies and to mediate cellular immune response [15,16]. Xiao *et al.* found that the above process does not require the participation of other proteins, and ACE2 becomes a key target for SARS-CoV fusion with host cells [17]. Scholars have found that the RBD sequences of the spike proteins of SARS-CoV and 2019-nCoV are highly similar [5–10]. This result suggests that the invasion mechanism of 2019-nCoV and SARS-CoV may be highly similar.

Distribution of ACE2 in salivary glands

ACE2 is an important member of the renin-angiotensin system. It is widely distributed in the vasculature and participates in the regulation of blood pressure [18]. According to data in the GTEx dataset (<https://gtexportal.org>), except for the vasculature, ACE2 protein can also be found in other organs, such as the small intestine, testes, adipose tissue, thyroid gland, kidneys, heart muscle, colon, and ovaries (Fig. 1). According to the above results, the ACE2 protein can be detected in salivary glands, and the mean expression level is 1.8 pTPM (protein-coding transcripts per million), which ranks 10th in total organs, even higher than that in the lung (Fig. 1). Liu *et al.* reported that ACE2 receptors are located on epithelial cells of salivary ducts; the epithelial cells are early targets of SARS-CoV infection [14]. The above evidence indicates that salivary glands could be the invasive target of 2019-nCoV.

2019-nCoV in saliva

Since ACE2 receptors are expressed in salivary glands, they could become a target for 2019-nCoV infection. In theory, 2019-nCoV will fuse into the epithelial cells on the salivary gland duct, replicate in them, and be released into saliva at a specific time. Therefore, 2019-nCoV should be detectable in saliva. Related studies have shown that nucleic acid of 2019-nCoV could be detected in saliva samples from 91.7% (11/12) of patients by polymerase chain reaction; the live virus is confirmed by viral culture, which is isolated from saliva [19]. A study related to SARS-CoV has also shown that SARS-CoV can be detected in saliva obtained from the early phase of infected patients [20].

Immunoreaction after coronavirus infection

Peiris *et al.* proposed the clinical progression of SARS-CoV with a tri-phasic pattern [21]. In the first phase, viral replication and cytolysis cause fever, myalgia, and symptoms in other systems [21], and lymphocytes are attacked by SARS-CoV, causing the decrease of lymphocyte counts in peripheral blood [22]. These aspects are similar to the clinical character of COVID-19 [9]. The second phase is tissue damage associated with excessive immunoreaction. A large number of mononuclear macrophages were observed in pathological lesions of SARS-CoV target organs, and some of them activated; they play the role of phagocytosis and antigen presentation in immunoreaction [23]. In the second phase, in the immunopathological progression, secreted inflammatory cytokines, such as IL-8, IL-6, IL-16, and TNF- α , promote the inflammatory response to induce relatively severe tissue damage [23].

Based on the above evidence and the similarity between SARS-CoV and 2019-nCoV, we speculate that 2019-nCoV replicates in salivary gland cells, which are then lysed in the first phase of infection. The salivary glands and ducts may be further damaged by the immunopathological process.

2019-nCoV may cause acute sialadenitis

Based on the above evidence, we infer that 2019-nCoV may cause acute sialadenitis according to the following process. 2019-nCoV binds to ACE2 receptors on the epithelium of salivary glands, fuses with them, replicates, and lyses cells to induce obvious symptoms and signs, such as discomfort, swelling, and pain in major salivary glands (parotid and submandibular glands). The virus can be detected in saliva [19]. After acinar cells are lysed by the cytolytic effect of 2019-nCoV, salivary amylase is released into the peripheral blood. Therefore, we infer that amylase increases in peripheral blood in the early phase of infection. As the immunopathological progression proceeds, secreted inflammatory cytokines promote the inflammatory response that damages salivary gland tissue. With decreasing immunoreaction, inflammatory damage will be repaired by granulation and fibrogenesis.

2019-nCoV may cause chronic sialadenitis

Based on the conventional repair mechanism of acute inflammatory damage [24–26], we speculate that the inflammatory destruction of salivary glands will be repaired by fibroblast proliferation and fibrous connective tissue formation. The hyposecretion of salivary glands

would be caused by fibrous repair of acinar cell damage. Stenosis and dilatation in the ducts of salivary glands may be caused by hyperplastic fibrous scars.

Hyposecretion reduces salivary flow, which is bound to affect the flushing function of saliva for the ductal system, thereby increasing the probability of retrograde infection through ductal orifices [27]. Second, hyposecretion increases the possibility of deposition of inorganic salts on the ductal wall, causing sialolithiasis [28]. Ductal stenosis that may be caused by hyperplasia of fibrous connective tissue around ducts can also reduce the salivary flow, increasing the incidence of the above diseases [29]. Moreover, ductal dilatation also reduces salivary flow, which promotes the formation of mucous plugs that block the excretion of saliva to further aggravate obstruction [30].

The repairing changes mentioned above may be caused by inflammation, which are causes of chronic obstructive sialadenitis. Therefore, chronic obstructive sialadenitis may be caused by 2019-nCoV infection.

Discussion

2019-nCoV erupted in Wuhan, China, in December 2019, causing widespread epidemics due to large-scale population movements during holidays [2]. At present, the number of confirmed cases in China has exceeded 70,000, and the scale of this infection exceeded that of SARS-CoV in 2003 (https://www.who.int/docs/default-source/coronaviruse/situation-reports/20200225-sitrep-36-covid-19.pdf?sfvrsn=2791b4e0_2). At present, the clinical management of COVID-19 is mainly applied by relevant specialists in infectious diseases, respiratory diseases, and intensive care. Research on the clinical characteristics of patients has been published in various professional journals, but the focus is mainly on the related damage of the respiratory, digestive, and urinary systems [9,10]. Of course, due to the outbreak of COVID-19 and the isolation of patients, medical professionals in other related professions are still unable to participate in the comprehensive evaluation of patients, so some clinical characteristics of COVID-19 may be missed. Therefore, specialists involved in clinical management are advised to pay attention to some subtle changes in many other organs of COVID-19 cases and to accumulate evidence with which to understand the characteristics of COVID-19 further.

SARS-CoV-related animal model experiments show that the first point of invasion is the salivary ducts [14]. Patient-based clinical studies also show that SARS-CoV can be detected early in saliva [19]. Therefore, possible early symptoms of COVID-19 may include discomfort, swelling, pain, or secretory dysfunction of the salivary glands. We speculate that with the further development of infection, amylase may enter peripheral blood after acinar cell destruction. Therefore, clinicians should pay more attention to the above symptoms and signs.

For acute sialadenitis occurring in the parotid and submandibular glands, ultrasound and amylase examination in peripheral blood could be used in diagnosis. The result of amylase examination in peripheral blood must be discriminated from that of acute pancreatitis. For acute sialadenitis that may occur in the sublingual gland, it is necessary to consider the difficulty of ventilation caused by swelling of the mouth-floor. If acute sialadenitis occurs in major salivary glands, the amount of saliva secretion may decrease significantly, causing xerostomia, which could be relieved by the use of artificial saliva.

Patients infected with SARS-CoV or 2019-nCoV may suffer from acute and chronic sialadenitis. Clinicians should pay more attention to the status of salivary glands during follow-up after cure, especially if the patient's health is complicated by chronic obstructive sialadenitis and salivary secretion dysfunction. For possible chronic obstructive sialadenitis, ultrasound, sialography, magnetic resonance, or salivary gland endoscopy can be used to understand the shape of the salivary gland and its catheter and to determine whether the stenosis of ducts has occurred. For possible hyposecretion, the measurement of saliva flow or radionuclide imaging could be used to determine the secretion

function of salivary glands.

Conclusions

Based on available evidence, we hypothesize that 2019-nCoV may cause acute sialadenitis and related symptoms, such as discomfort, pain, swelling, and secretory dysfunction in salivary glands; after the acute phase, the structure of salivary glands may be abnormal due to 2019-nCoV infection, which may cause chronic sialadenitis. Although not proven by direct evidence, clinicians should pay sufficient attention to such symptoms.

Acknowledgments

This work was supported by the National Natural Science Foundation of China (Grant No. 81600908) and the Technology Development Fund of Nanjing Medical University (Grant No. 2017NJMU103). We thank LetPub (www.letpub.com) for its linguistic assistance during the preparation of this manuscript.

Declaration of Competing Interest

The authors declare that they have no known competing financial interests or personal relationships that could have appeared to influence the work reported in this paper.

References

- [1] Cui J, Li F, Shi ZL. Origin and evolution of pathogenic coronaviruses. *Nat Rev Microbiol* 2019;17:181–92.
- [2] Hui DS, Azhar E, Madani TA, et al. The continuing 2019-nCoV epidemic threat of novel coronaviruses to global health—the latest 2019 novel coronavirus outbreak in Wuhan, China. *Int J Infect Dis* 2020;91:264–6.
- [3] Li Q, Guan X, Wu P, et al. Early transmission dynamics in Wuhan, China, of Novel Coronavirus-Infected Pneumonia. *N Engl J Med* 2020.
- [4] Chan JF, Yuan S, Kok KH, et al. A familial cluster of pneumonia associated with the 2019 novel coronavirus indicating person-to-person transmission: a study of a family cluster. *Lancet* 2020;395:514–23.
- [5] Liu W, Morse JS, Lalonde T, et al. Learning from the past: possible urgent prevention and treatment options for severe acute respiratory infections caused by 2019-nCoV. *ChemBioChem* 2020.
- [6] Patel A, Jernigan DB; 2019-nCoV CDC Response Team. Initial Public Health Response and Interim Clinical Guidance for the 2019 Novel Coronavirus Outbreak - United States, December 31, 2019–February 4, 2020. *MMWR Morb Mortal Wkly Rep* 2020;69:140–146.
- [7] Chai XQ, Hu LF, Zhang Y, et al. Specific ACE2 Expression in Cholangiocytes May Cause Liver Damage After 2019-nCoV Infection. *bioRxiv*, 2020: p. 2020.02.03. 931766.
- [8] Fan CB, Li K, Ding YH, et al. ACE2 expression in kidney and testis may cause kidney and testis damage after 2019-nCoV infection. *MedRxiv*, 2020: 2020.02.12. 20022418.
- [9] Chen N, Zhou M, Dong X, et al. Epidemiological and clinical characteristics of 99 cases of 2019 novel coronavirus pneumonia in Wuhan, China: a descriptive study. *Lancet* 2020;395:507–13.
- [10] Huang C, et al. Clinical features of patients infected with 2019 novel coronavirus in Wuhan, China. *Lancet* 2020;395:497–506.
- [11] Wan Y, Shang J, Graham R, et al. Receptor recognition by novel coronavirus from Wuhan: An analysis based on decade-long structural studies of SARS. *J Virol* 2020;pii: JVI.00127-20.
- [12] Kuba K, Imai Y, Rao S, et al. A crucial role of angiotensin converting enzyme 2 (ACE2) in SARS coronavirus-induced lung injury. *Nat Med* 2005;11:875–9.
- [13] Li W, Moore MJ, Vasilieva N, et al. Angiotensin-converting enzyme 2 is a functional receptor for the SARS coronavirus. *Nature* 2003;426:450–4.
- [14] Liu L, Wei Q, Alvarez X, et al. Epithelial cells lining salivary gland ducts are early target cells of severe acute respiratory syndrome coronavirus infection in the upper respiratory tracts of rhesus macaques. *J Virol* 2011;85:4025–30.
- [15] Ho TY, Wu SL, Cheng SE, et al. Antigenicity and receptor-binding ability of recombinant SARS coronavirus spike protein. *Biochem Biophys Res Commun* 2004;313:938–47.
- [16] Gallagher TM, Buchmeier MJ. Coronavirus spike proteins in viral entry and pathogenesis. *Virology* 2001;279:371–4.
- [17] Xiao X, Chakraborti S, Dimitrov AS, et al. The SARS-CoV S glycoprotein: expression and functional characterization. *Biochem Biophys Res Commun* 2003;312:1159–64.
- [18] Arendse LB, Danser AHJ, Poglitsch M, et al. Novel therapeutic approaches targeting the renin-angiotensin system and associated peptides in hypertension and heart failure. *Pharmacol Rev* 2019;71:539–70.
- [19] To KK, Tsang OT, Chik-Yan Yip C, et al. Consistent detection of 2019 novel

- coronavirus in saliva. *Clin Infect Dis* 2020; pii:ciaa149.
- [20] Wang WK, Chen SY, Liu JJ, et al. Detection of SARS-associated coronavirus in throat wash and saliva in early diagnosis. *Emerg Infect Dis* 2004;10:1213–9.
- [21] Peiris JS, Chu CM, Cheng VC, et al. Clinical progression and viral load in a community outbreak of coronavirus-associated SARS pneumonia: a prospective study. *Lancet* 2003;361:1767–72.
- [22] Booth CM, Matukas LM, Tomlinson GA, et al. Clinical features and short-term outcomes of 144 patients with SARS in the greater Toronto area. *JAMA* 2003;289:2801–9.
- [23] Channappanavar R, Perlman S. Pathogenic human coronavirus infections: causes and consequences of cytokine storm and immunopathology. *Semin Immunopathol* 2017;39:529–39.
- [24] Hwang SM, Chung G, Kim YH, Park CK. The role of maresins in inflammatory pain: function of macrophages in wound regeneration. *Int J Mol Sci* 2019;20:5849.
- [25] Afonina IS, Zhong Z, Karin M, Beyaert R. Limiting inflammation—the negative regulation of NF- κ B and the NLRP3 inflammasome. *Nat Immunol* 2017;18:861–9.
- [26] Bednash JS, Mallampalli RK. Regulation of inflammasomes by ubiquitination. *Cell Mol Immunol* 2016;13:722–8.
- [27] Antoniadis D, Harrison JD, Epivatianos A, Papanayotou P. Treatment of chronic sialadenitis by intraductal penicillin or saline. *J Oral Maxillofac Surg* 2004;62:431–4.
- [28] Harrison JD, Epivatianos A. Production of microliths and sialadenitis in rats by a short combined course of isoprenaline and calcium gluconate. *Oral Surg Oral Med Oral Pathol* 1992;73:585–90.
- [29] Ngu RK, Brown JE, Whaites EJ, Drage NA, Ng SY, Makhadmeh J. Salivary duct strictures: nature and incidence in benign salivary obstruction. *Dentomaxillofac Radiol* 2007;36:63–7.
- [30] Koch M, Iro H, Zenk J. Role of sialoscopy in the treatment of Stensen's duct strictures. *Ann Otol Rhinol Laryngol* 2008;117:271–8.