



Case report

Surgical management of a hepatic hydatid cyst fistulized into the duodenum: A case report

Ahmed Saidani^{*}, Sarra Saad, Anis Belhadj, Hichem Rakkeh, Mahmoud Kammoun, Faouzi Chebbi

General Surgery Department, Mahmoud Elmati Hospital, Tunisia

ARTICLE INFO

Keywords:

Echinococcosis
Liver
Hydatid cyst
Duodenum
Fistula
Antrectomy

ABSTRACT

Introduction and importance: Hydatid cyst of liver is a disease usually seen in endemic regions. Fistulization into duodenum is one of the most exceptional complications of the hydatid cyst commonly discovered during surgery. This paper aims to present and discuss a rare case of cyst ruptured into the duodenum. This case report has been reported in line with the SCARE criteria 2020.

Case presentation: A 44-year-old female patient, previously diagnosed with hydatid cyst of liver with deferred care due to the period of COVID 19 containment, presented with the complaints of abdominal pain and fever. Abdominal CT scan showed up a 2 cm multiseptal hydatid cyst in the segment III of the liver with an exovesiculation of 20 cm, communicating with the first duodenum. The patient underwent antrectomy involving the first duodenum and removing the cystoduodenal fistula with a Roux-en-Y anastomosis. She was discharged with full recovery on the postoperative 5th day.

Clinical discussion: Clinical features of hydatid cyst fistulized into the duodenum are non-specific. There are two pathognomonic symptoms, hydatidemia and hydatidenteria. Typically, cysto-duodenal fistula is intra-operatively discovered. The CT scan is the most used morphological examination. The presence of air in the cyst should alert for the gastrointestinal fistula formation. Surgical strategies to perform should be tailored to every patient and to intra operative findings. The post-operative morbidity and mortality are underestimated in the literature.

Conclusion: The fistulization of Hydatid cyst into the duodenum should be evoked in front of any acute abdominal pain whether or not associated with hydatidemia or hydatidenteria.

1. Introduction

Hydatid disease is an anthrozoosis caused by the larval stage of the *Echinococcus granulosus*. It is associated with a wide spectrum of complications in about 30% of patients.

The most common complications of liver hydatid cysts are infection, and perforation into the biliary tree. [3,4]

The perforation of the cyst into the gastrointestinal tract is very rare.

Barely, between 0.29% and 0.5% of the hepatic hydatidosis operated surgically reveals perforation of the cyst into the gastrointestinal tract and only 0.15% of them are fistulized in the duodenum [3,5]. The cysto-duodenal fistula is hardly diagnosed in imaging and constitutes a challenge in the choice of the surgical management [2].

In this article we describe a case of duodenal fistulization of hepatic

hydatid cyst. This paper has been reported in line with the SCARE criteria 2020 [7].

2. Case presentation

A 44-year-old female patient, with no medical or surgical history, previously diagnosed with hydatid cyst of liver (Fig. 1) about six months ago with deferred care due to the period of COVID 19 containment, presented with the complaints of abdominal pain and fever. Physical examination revealed fever of 39°C and a large tender mass in the right hypochondrium.

Laboratory data showed a white blood cell count of 21200/μl with elevated level of C-Reactive protein at 331mg/l. Abdominal CT showed up a 2 cm multiseptal hydatid cyst in the segment III of the liver (Fig. 2).

^{*} Corresponding author.

E-mail addresses: a.saidani22@yahoo.fr (A. Saidani), sarrasaad.dr@gmail.com (S. Saad), Anis.belhadj1@laposte.net (A. Belhadj), Hichem-rakkeh@hotmail.com (H. Rakkeh), Dr.kammoun.mahmoud@gmail.com (M. Kammoun), Chebbi.fauzi2@gmail.com (F. Chebbi).

<https://doi.org/10.1016/j.ijscr.2021.106518>

Received 1 September 2021; Received in revised form 10 October 2021; Accepted 13 October 2021

Available online 21 October 2021

2210-2612/© 2021 Published by Elsevier Ltd on behalf of IJS Publishing Group Ltd. This is an open access article under the CC BY-NC-ND license

(<http://creativecommons.org/licenses/by-nc-nd/4.0/>).

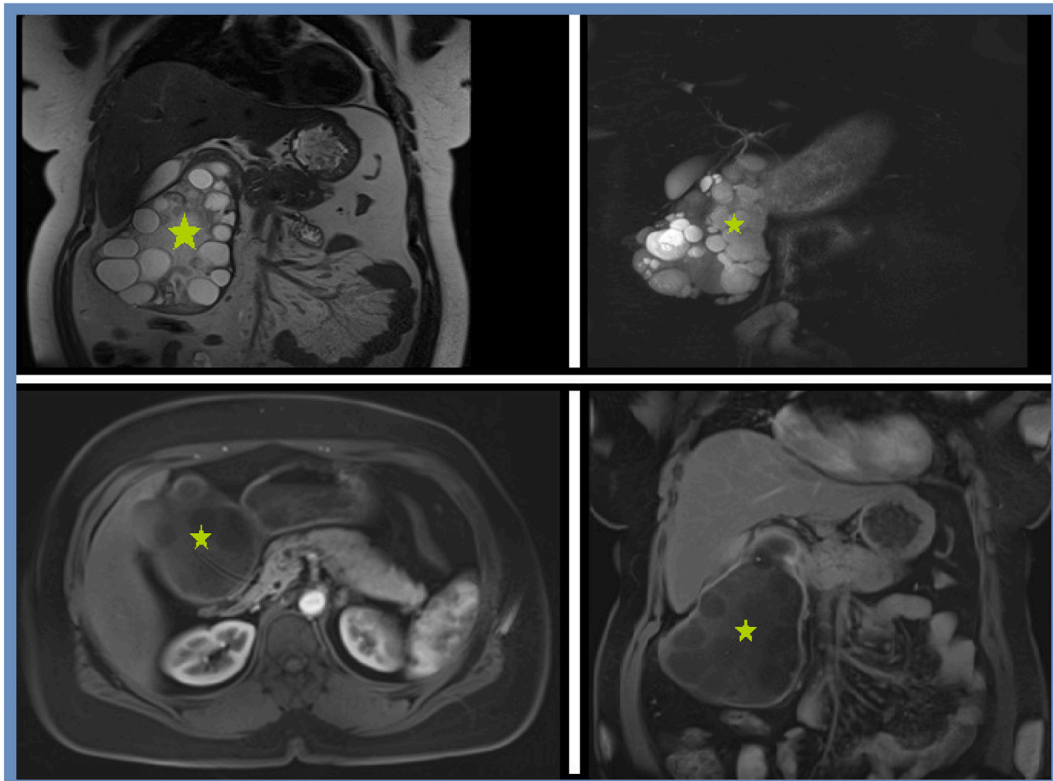


Fig. 1. Different MRI views showing a multiseptal hydatid cyst without fistulization.

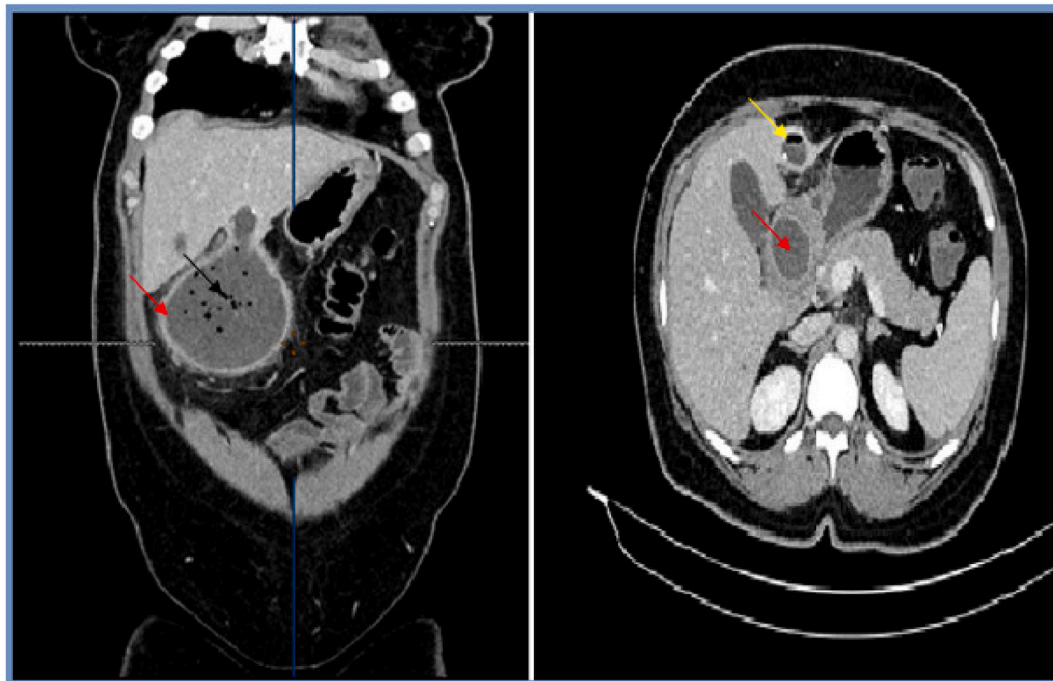


Fig. 2. Different views of the CT scan of the patient's abdomen, showing a 2 cm multiseptal hydatid cyst in the segment III of the liver (yellow arrow) with an enormous exovesiculation (red arrow) communicating with the cyst and an air bubble sign (black arrow). (For interpretation of the references to colour in this figure legend, the reader is referred to the web version of this article.)

The cyst had a partially calcified wall and an exovesiculation of 20 cm in the lower pole. A fistulous communication between the duodenal bulb and the hydatid vesiculation has been identified (Fig. 3). Emergency laparotomy was carried out under the diagnosis of infected hydatid cyst

fistulized in the first duodenum. The surgical approach was a right subcostal laparotomy, a single hydatid cyst of the segment III of the liver was identified measuring 2 cm with extra parenchymal development. There was an enormous exovesiculation of 20 cm, communicating with

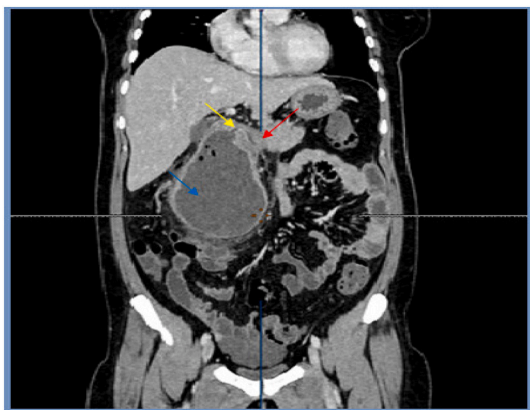


Fig. 3. CT scan view showing a hydatid cyst with an exovesiculation of 20 cm in the lower pole. A fistulous communication (yellow arrow) between the duodenal bulb (red arrow) and the hydatid vesiculation (blue arrow). (For interpretation of the references to colour in this figure legend, the reader is referred to the web version of this article.)

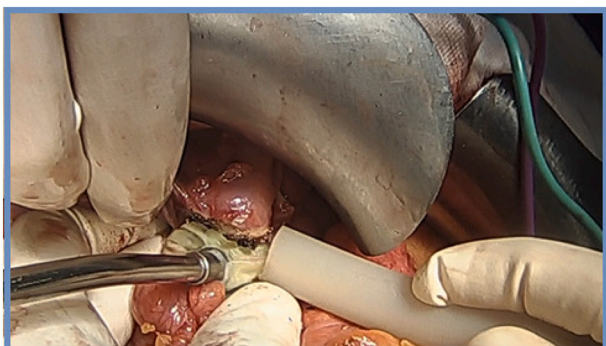


Fig. 4. Per-operative image showing laminated membrane removed from the hydatid cyst of the liver.

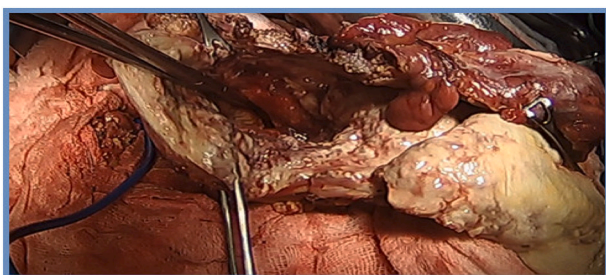


Fig. 5. Per-operative image showing the detection of the communication between the cyst and the duodenum.

the cyst, in close contact with the duodenum, the gastric antrum and the transverse mesocolon blocking the access to the omental bursa. After protecting the surrounding organs with swabs with protoscolicidal agent (Hypertonic saline 20%), the puncture of the cyst revealed purulent fluid and multiple daughter cysts. Careful dissection was done freeing the exovesiculation from its attachments with the transverse mesocolon (Fig. 4). It remains attached to the anterior wall of the duodenal bulb and to the gastric antrum (Fig. 5). The opening of the exovesiculation revealed a wide communication of 2cm with the first duodenum. Hence, we decided to perform an antrectomy removing the cystoduodenal fistula. The descending duodenum was mobilized by Kocher's maneuver and through the opening of the pars flaccida. The pylorus and the distal

part of the stomach were dissected, ligating the vasculature on the greater and lower curvature. The duodenum was divided with the stapler device below the cystoduodenal fistula. The stapled lines were buried with a layer of mattress sutures (Fig. 6).

The proximal resection line was placed in the distal third of the stomach. Antrum was stapled and reinforced with sutures. The gastrointestinal transit reconstruction was performed with a Roux-en-Y anastomosis. Curettage for cyst cavity was performed. After closure of mesenteric defects, two thin drainage tubes were placed close to the duodenal stump. The patient had an uneventful recovery. Drainage tube has been removed and patient was discharged on the 6th postoperative day. Histopathology confirmed the clinical diagnosis. No problem had occurred during the over the 3-month follow-up.

3. Discussion

Hydatidosis is a zoonosis caused by *Echinococcus granulosus*. It is most commonly located in the liver (5075%) [8]. The main complications of the liver hydatid cyst are infection and rupture, especially into the biliary tract, the peritoneum and thorax [9]. Rupture is associated with a high death rate. Indeed spontaneous rupture into the gastro-intestinal tract is rare (0.29%) and stomach is the most common site of perforation [10]. Duodenum is affected in only 0.15% of cases [11,12].

The pathogenesis of cysto-duodenal fistula is not well elaborated in the literature [13]. Some conditions can make a cyst susceptible to fistulization; often originates from the left liver with extra-hepatic development. A long and large -standing cyst, with thick and calcified enable mechanical duodenal frictions that continuously erode it duodenal wall through mechanical frictions. Prolonged inflammatory process participates also in fistula genesis. Duodenal wall can be already weakened by other factors such as peptic ulcer [10].

Clinical features of fistulized into the duodenum are non-specific. The most frequently reported symptoms are abdominal pain, nausea and vomiting [13]. Two pathognomonic symptoms were reported in the literature hydatidemesis and hydatidenteria [14]. Hydatidenteria is the passage of hydatid membranes in the stools, hydatidemesis is vomiting of a salty liquid with membranes. Patients with cysto-duodenal fistula may also be asymptomatic.

Typically, cysto-duodenal fistula is intra-operatively discovered. The most used morphological examination is Computed Tomography. The detection of air in the cyst should alert for the gastrointestinal fistula formation [11,15]. CT with an orally administered contrast material can objectify fistula between the cyst and the gastro-intestinal tract [16].

Few cases in the literature reported the use of upper gastrointestinal endoscopy to diagnose cysto-duodenal fistula [17,18].

Our patient underwent an intravenous contrast enhanced CT scan without oral contrast demonstrating communication between HC and the duodenum.

Hydatid cyst fistulized into the duodenum is often infected necessitating urgent surgical management via laparotomy. There is no consensus on surgical strategies to perform. They should be tailored to every patient and to intra operative findings [13].

Surgical treatment should have three aims: sterilization and removal of the parasite, logout of cysto-digestive fistula and repair of duodenal wall [1].

The conservative techniques are used in 75% of cases [9]. It seems adapted to an infected cyst in an emergency context as it is rapid and does not require a particular experience in liver surgery [8]. Radical surgery may be carried out if surgeon consider it technically feasible, secure and with no added risk [10].

The surgical management of cysto-digestive fistula is controversial. A variety of procedures was used in the literature from simple suture, duodenal exclusion to duodenectomies.

Three key factors determine the suitable technique; the importance of duodenal wall defect, the duodenal segment affected and the anatomical position relative to Vater's ampulla [13].

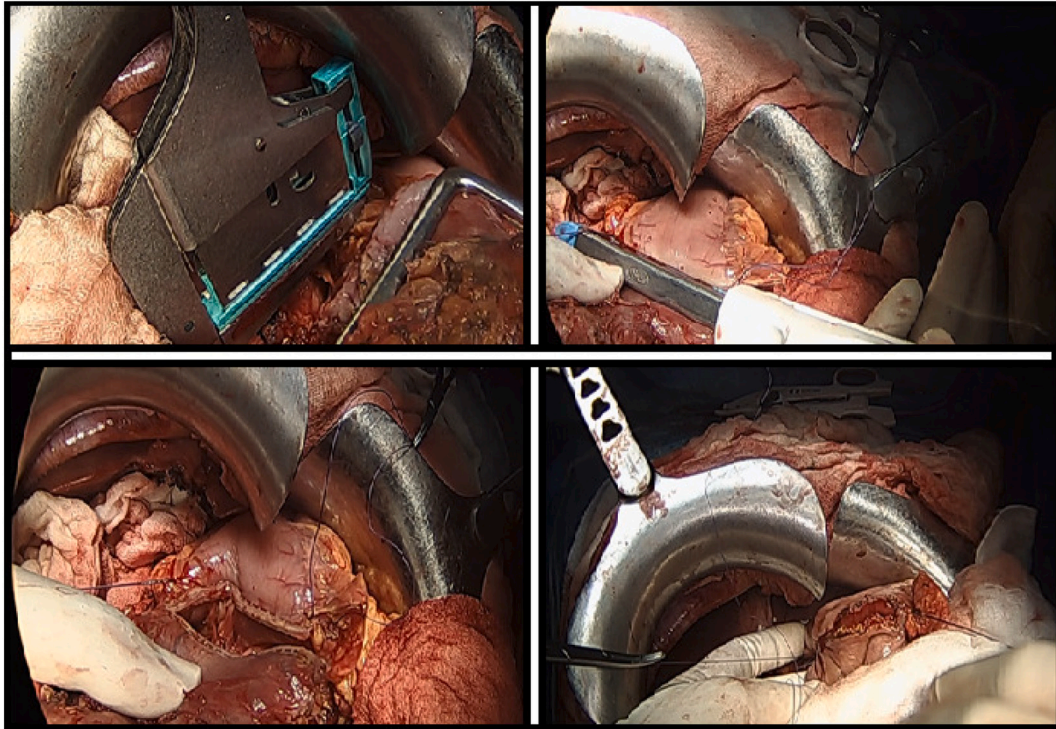


Fig. 6. Antrectomy removing the cystoduodenal fistula and gastrointestinal transit reconstruction with a Roux-en-Y anastomosis.

If the cysto-duodenal fistula is small, it can be sutured. Or else, if the defect is important, more complex procedures should be performed such as duodenal resection, duodenal diverticulization and duodenostomy.

About our patient, we opted for Lagrot's procedure as a rapid technique adapted to endemic zone of hydatid cyst. The surgical management of the duodenal fistula was dictated by the importance of wall defect and the young age of the patient. Hence, we opted for an antrectomy with Roux-en-Y anastomosis.

4. Conclusion

The fistulization of Hydatid cyst into the duodenum should be evoked in front of any acute abdominal pain whether or not associated with hydatidemia or hydatidenteria. This condition requires urgent surgical management which should be tailored to every patient and to intra operative findings.

Patient consent

Written informed consent was obtained from the patient for publication of this case report and accompanying images. A copy of the written consent is available for review by the Editor-in-Chief of this journal on request.

Author contribution

Dr. Ahmed SAIDANI: data collection and writing
 Dr. Sarra SAAD: data collection
 Dr. Anis BELHADJ: interpretation
 Dr. Hichem rakkeh: Design
 Dr. Mahmoud Kammoun data collection
 Dr. Faouzi Chebbi: contributor

Registration of research studies

1. Name of the registry: international journal of surgery case reports

2. Unique identifying number or registration ID: a.saidani
 3. Hyperlink to your specific registration (must be publicly accessible and will be checked): <https://www.editorialmanager.com/ijscaserports/default.aspx>

Guarantor

Dr. Ahmed SAIDANI

Provenance and peer review

Not commissioned, externally peer-reviewed.

Declaration of competing Interest

The authors whose names are listed immediately below certify that they have NO affiliations with or involvement in any organization or entity with any financial interest (such as honoraria; educational grants; participation in speakers, bureaus; membership, employment, consultancies, stock ownership, or other equity interest; and expert testimony or patent-licensing arrangements), or non-financial interest (such as personal or professional relationships, affiliations, knowledge or beliefs) in the subject matter or materials discussed in this manuscript.

References

- [1] C. Gomez i Gavara, R. López-Andújar, T. Belda Ibáñez, J.M. Ramia Ángel, Á. Moya Herraiz, F. Orbis Castellanos, Review of the treatment of liver hydatid cysts, *World J Gastroenterol*: WJG 21 (1) (2015) 124–131, 7 janv.
- [2] S. Greco, R. Cannella, D. Giambelluca, G. Pecoraro, E. Battaglia, M. Midiri, Complications of hepatic echinococcosis: multimodality imaging approach, *Insights Imaging* 10 (2019) 113, 2 déc.
- [3] A. Ezer, T.Z. Nursal, G. Moray, S. Yildirim, F. Karakayali, T. Noyan, Surgical treatment of liver hydatid cysts, *HPB* 8 (1) (2006) 38–42, 1 févr.
- [4] K. Alexiou, S. Mitsos, A. Fotopoulos, I. Karanikas, K. Tavernaraki, F. Konstantinidis, Complications of hydatid cysts of the liver: spiral computed tomography findings, *Gastroenterol. Res.* 5 (4) (2012) 139–143, août.
- [5] B. Kourias, Apropos de 2000 cas de kystes hydatiques operas: brdves considérations d'ordre statistique et chirurgical, *Presse Med.* 69 (1961) 165–168.

- [7] R.A. Agha, T. Franchi, C. Sohrabi, G. Mathew, A. Kerwan, A. Thoma, The SCARE 2020 guideline: updating consensus Surgical CAse REport (SCARE) guidelines, *Int. J. Surg.* 84 (2020) 226–230, déc.
- [8] Y. Wu, J. Gong, W. Xiong, X. Yu, X. Lu, Primary pancreatic hydatid cyst: a case report and literature review, *BMC Gastroenterol.* 21 (1) (2021) 164, 13 avr.
- [9] J.R. Hankins, Management of complicated hepatic hydatid cysts, *Ann. Surg.* 158 (6) (1963) 1020–1034, déc.
- [10] L. Diez Valladares, A. Sanchez-Pernaute, O. Gonzalez, E. Perez-Aguirre, P. Talavera, A. Gutierrez del Olmo, Hydatid liver cyst perforation into the digestive tract, *Hepatogastroenterology* 45 (24) (déc 1998) 2110–2114.
- [11] M. Noguera, A. Alvarez-Castells, E. Castella, L. Gifre, J. Andreu, S. Quiroga, Spontaneous duodenal fistula due to hepatic hydatid cyst, *Abdom. Radiol.* 18 (3) (1993) 234–236, juin.
- [12] A. Zaouche, La chirurgie des kystes hydatiques du foie, in: *Étude multicentrique tunisienne à propos de 2013 cas*, 1994.
- [13] V.de la Fuente-Aguilar, P. Beneitez-Mascaraque, S. Bergua-Arroyo, M. Fernández-Riesgo, I. Camón-García, I. Cruza-Aguilera, Hydatidosis and the duodenum: a systematic review of the literature, *World J. Meta-Anal.* 8 (3) (2020) 265–274, 28 juin.
- [14] S. Thomas, M.C. Mishra, A.K. Kriplani, B.M.L. Upur, Hydatidemesis: a bizarre presentation of abdominal hydatidose, *ANZ J. Surg.* 63 (6) (1993) 496–498, juin.
- [15] T. Patankar, S. Prasad, O.S. Rohondia, J.D. Mohite, P. James, R. Radhakrishnan, Fistulization of hepatic hydatid cyst into duodenum, *Indian J. Gastroenterol.* 17 (4) (1998) 152, déc.
- [16] I. Pedrosa, A. Saíz, J. Arrazola, J. Ferreirós, C.S. Pedrosa, Hydatid disease: radiologic and pathologic features and complications: (CME available in print version and on RSNA Link), *RadioGraphics* 20 (3) (2000) 795–817, mai.
- [17] S. Daldoul, A. Moussi, A. Zaouche, in: *Spontaneous Fistulization of Hepatic Hydatid Cyst Into the Duodenum: An Exceptional Complication* 23, 2013, p. 3.
- [18] S. Akbulut, M. Yilmaz, S. Alan, M. Kolu, N. Karadag, Coexistence of duodenum derived aggressive fibromatosis and paraduodenal hydatid cyst: a case report and review of literature, *World J. Gastrointest. Surg.* 10 (8) (2018) 90–94, 27 nov.