

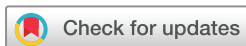# The Efficacy of Sodium-Glucose Cotransporter 2 (SGLT2) inhibitors for the treatment of chronic diabetic macular oedema in vitrectomised eyes: a retrospective study

Hiroki Mieno,<sup>1</sup> Kazuhito Yoneda,<sup>1</sup> Masahiro Yamazaki,<sup>2</sup> Ryosuke Sakai,<sup>2</sup> Chie Sotozono,<sup>1</sup> Michiaki Fukui<sup>2</sup>

**To cite:** Mieno H, Yoneda K, Yamazaki M, *et al.* The Efficacy of Sodium-Glucose Cotransporter 2 (SGLT2) inhibitors for the treatment of chronic diabetic macular oedema in vitrectomised eyes: a retrospective study. *BMJ Open Ophthalmology* 2018;**3**:e000130. doi:10.1136/bmjophth-2017-000130

► Additional material is published online only. To view please visit the journal online (<http://dx.doi.org/10.1136/bmjophth-2017-000130>).

Received 7 November 2017  
Revised 9 June 2018  
Accepted 18 June 2018



© Author(s) (or their employer(s)) 2018. Re-use permitted under CC BY-NC. No commercial re-use. See rights and permissions. Published by BMJ.

<sup>1</sup>Department of Ophthalmology, Kyoto Prefectural University of Medicine, Kyoto, Japan  
<sup>2</sup>Department of Endocrinology and Metabolism, Kyoto Prefectural University of Medicine, Kyoto, Japan

## Correspondence to

Dr Kazuhito Yoneda; [kazuyone@koto.kpu-m.ac.jp](mailto:kazuyone@koto.kpu-m.ac.jp)

## ABSTRACT

**Objective** To investigate the change of chronic diabetic macular oedema (DMO) in vitrectomised eyes when the administration of sodium–glucose cotransporter 2 (SGLT2) inhibitors is initiated as a systemic medical treatment.

**Methods and analysis** This study involved 10 eyes of five patients with chronic DMO lasting more than 6 months who had previously undergone vitrectomy and whose systemic medical treatments were newly changed to SGLT2 inhibitors. In this study, chronic DMO was defined as persistent diffuse macular oedema despite ophthalmic treatment in patients with diabetes. Patients who received antivasular endothelial growth factor therapy or steroids administration, or change of eye-drop medication from at 3 months before and after the initiation of SGLT2 inhibitors, were excluded. In this study, visual acuity (VA) and central retinal thickness (CRT,  $\mu\text{m}$ ) prior to and at 3, 6 and 12 months after the initiation of SGLT2 inhibitors were retrospectively compared. The Wilcoxon signed-rank test was used for statistical analysis.

**Results** In the 10 treated eyes, from at baseline to at 3, 6 and 12 months after the initiation of SGLT2 inhibitor, median VA (logMAR) improved from 0.35 to 0.15 ( $p=0.038$ ), 0.2 ( $p=0.157$ ) and 0.2 ( $p=0.096$ ), respectively, and median CRT significantly reduced from 500.5  $\mu\text{m}$  to 410  $\mu\text{m}$  ( $p<0.01$ ), 378  $\mu\text{m}$  ( $p<0.01$ ) and 339  $\mu\text{m}$  ( $p<0.01$ ), respectively.

**Conclusion** Although this study involved only five patients, our findings indicate that SGLT2 inhibitors might have structural efficacy for chronic DMO in vitrectomised eyes.

## INTRODUCTION

Diabetic macular oedema (DMO) is a well-known and devastating complication of diabetes mellitus (DM) and is characterised by thickening of the macula due to accumulation of intraretinal and/or subretinal fluid and exudates. DMO can seriously threaten a patient's vision, and it has been reported that in developed countries, DMO is the primary cause of blindness in the adult population.<sup>1</sup> Since nearly all DMO cases involve patients

## Key messages

### What is already known about this subject?

► To date, and to the best of our knowledge, there have been no published reports focused on the relationship between diabetic macular oedema (DMO) and sodium–glucose cotransporter 2 (SGLT2) inhibitors.

### What are the new findings?

► We theorised that the administration of SGLT2 inhibitors has an effect as a systemic medical treatment and also has an influence on DMO, and our findings indicate that SGLT2 inhibitors might affect DMO.

### How might these results change the focus of research or clinical practice?

► A larger prospective study is needed to more clearly elucidate the effect of the SGLT2 inhibitors on DMO.

who undergo systemic medical treatment for DM, it is considered highly preferable in terms of patient burden and medical economy if the DM treatment can secondarily result in being a successful treatment for DMO.

Sodium–glucose cotransporter 2 (SGLT2) inhibitors have recently attracted attention as a novel treatment for diabetes. Previous studies reported the presence of SGLT in cultured bovine retinal pericytes,<sup>2–4</sup> and in one of those studies, the SGLT was thought to be SGLT2,<sup>2</sup> while in the other study, the results of a laboratory experiment showed that phlorizin, an SGLT inhibitor, attenuated high glucose-induced morphological and functional changes in cultured bovine retinal pericytes.<sup>3</sup> It should be noted that SGLT2 inhibitors also have a diuretic effect, and previous studies have reported that diuretics can be used to improve DMO.<sup>5–6</sup> These findings suggest that the administration of drugs with a diuretic action can lead to an alleviation of DMO. Thus, we theorised

that the administration of SGLT2 inhibitors has an effect as a systemic medical treatment and also has an influence on DMO by changing retinal pericytes and/or diuretic action.

Currently, antivasular endothelial growth factor (VEGF) therapy is regarded as the 'cutting-edge' treatment for DMO. Since VEGF contributes to macular thickening and the visual impairment associated with DMO,<sup>7</sup> it has been reported that anti-VEGF therapy is effective for treating DMO.<sup>8,9</sup> However, frequent intravitreal injections are needed, and both economic and invasive problems related to the treatment remain. For DMO cases with vitreous haemorrhage and/or vitreous traction, vitrectomy is known to be a surgical option. However, if there is a recurrence of DMO after vitrectomy, it is difficult to treat. Although additional anti-VEGF therapy remains an option in such cases, the clearance may be faster in vitrectomised eyes than in non-vitrectomised eyes,<sup>10</sup> and more frequent injections are sometimes required in vitrectomised eyes. Hence, patients sometimes request medical follow-up without anti-VEGF therapy.

To date, and to the best of our knowledge, there have been no published reports focused on the relationship between DMO and SGLT2 inhibitors. In this present study, we report cases of chronic DMO that improved merely by changing the systemic medical treatment to SGLT2 inhibitors, as well as the associated treatment effects.

## PATIENTS AND METHODS

This study involved 10 eyes of five patients with type 2 DM with chronic DMO lasting more than 6 months who had previously undergone vitrectomy and whose systemic medical treatments were newly changed to SGLT2 inhibitors at Kyoto Prefectural University of Medicine Hospital, Kyoto, Japan, between April 2015 and October 2016. In this study, chronic DMO was defined as persistent diffuse macular oedema despite ophthalmic treatment in patients with diabetes. Patients who received anti-VEGF therapy or steroids administration, or a change of eye-drop medication, from at 3 months before and after the initiation of SGLT2 inhibitors, were excluded from the study. Patients who were undergoing dialysis were also excluded. All patients had a history of bilateral vitrectomy and panretinal photocoagulation, and more than 1 year

had passed since the last vitrectomy was performed. We selected the patients who requested medical follow-up without anti-VEGF therapy. In this study, visual acuity (VA) and central retinal thickness (CRT,  $\mu\text{m}$ ) measured by Topcon 3D OCT viewer (3D OCT-2000 or DCI OCT Triton; Topcon, Tokyo, Japan) at baseline and at 3, 6 and 12 months after the initiation of SGLT2 inhibitors were retrospectively analysed. In addition, VA and CRT at baseline and at 3 and 6 months before the initiation of SGLT2 inhibitors were evaluated.

In this study, the systemic medical treatment of the patients with SGLT2 inhibitors was performed by diabetes specialists. Moreover, blood-test findings obtained during the study period were retrospectively analysed.

IBM SPSS Statistics V.24 software and the Wilcoxon signed-rank test were used for statistical analyses. A *p* value of <0.05 was considered statistically significant. Descriptive analysis of data was carried out using medians, 25% quantile (Q1) and 75% quantile (Q3), as appropriate.

## RESULTS

Patient backgrounds and blood-test findings at baseline of the five patients (*n*=10 eyes) with chronic bilateral DMO are summarised in table 1. Most cases had undergone vitrectomy before anti-VEGF treatment for DMO was approved in Japan. Although only one eye received one anti-VEGF treatment before vitrectomy, no effect was observed and the patient opted to discontinue the anti-VEGF treatment.

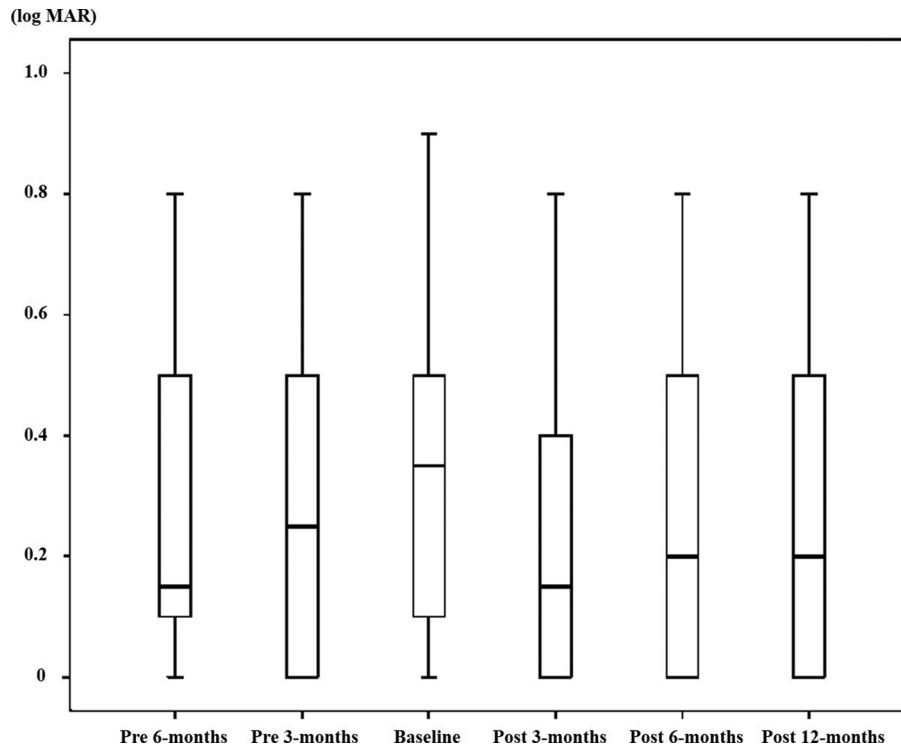
As a systemic medical treatment, the administration of dapagliflozin was newly initiated in four cases and luseogliflozin was newly initiated in one case. The doses used were 5 mg for dapagliflozin and 2.5 mg for luseogliflozin.

In 9 of the 10 eyes (90%), the difference of VA between that at baseline and at 12 months after the initiation of SGLT2 inhibitor was within 0.1 logMAR. In 1 of the 10 eyes (10%), VA improved by 0.3 logMAR during the follow-up period. From at baseline to at 3, 6 and 12 months after the initiation of SGLT2 inhibitor, median VA (logMAR) improved from 0.35 (Q1: 0.1, Q3: 0.5) to 0.15 (Q1: 0, Q3: 0.4, *p*=0.038), 0.2 (Q1: 0, Q3: 0.5, *p*=0.157) and 0.2 (Q1: 0, Q3: 0.5, *p*=0.096), respectively. In 9 of the 10 eyes (90%), CRT reduced more than 10%, yet in 1 of the 10 eyes (10%), the change was within 10%. From at baseline to at 3, 6 and 12 months after the initiation

**Table 1** Patient backgrounds and blood-test findings at baseline

Case	Age (years)	Sex	Diabetes duration (years)	Body Mass Index	Insulin use	Systemic hypertension	Dyslipidaemia	HbA1c (%)	eGFR (mL/min/1.73m <sup>2</sup> )
1	60	M	16	28.0	+	+	-	6.8	65.9
2	44	M	30	29.1	+	-	-	9.8	54
3	65	M	8	21.4	-	-	-	6.6	89.3
4	67	M	10-15	25.5	+	+	+	8.1	51.3
5	69	F	5	25.2	-	-	+	6.4	90.8

eGFR, estimated glomerular filtration rate; F, female; HbA1c, glycated haemoglobin; M, male.



**Figure 1** Changes of visual acuity (VA) at baseline, at 3 and 6 months before, and at 3, 6 and 12 months after the initiation of the administration of sodium–glucose cotransporter 2 inhibitor. The vertical-column boxes indicate values between the 25th and 75th percentiles (central line, median). Median VA (logMAR) significantly improved from 0.35 at baseline to 0.15 at 3 months after the initiation of the treatment ( $p=0.038$ ), and median VA improved from that at baseline to 0.2 at 6 months and 0.2 at 12 months after the initiation of the treatment ( $p=0.157$  and  $p=0.096$ , respectively) (Wilcoxon signed-rank test).

of SGLT2 inhibitor, median CRT significantly reduced from  $500.5\mu\text{m}$  (Q1: 390, Q3: 542) to  $410\mu\text{m}$  (Q1: 368, Q3: 431,  $p<0.01$ ),  $378\mu\text{m}$  (Q1: 350, Q3: 416,  $p<0.01$ ) and  $339\mu\text{m}$  (Q1: 293, Q3: 356,  $p<0.01$ ), respectively.

Compared with at baseline, at 6 and 3 months before the initiation of SGLT2 inhibitor, the median VA was 0.15 (Q1: 0.1, Q3: 0.5,  $p=0.439$ ) and 0.25 (Q1: 0, Q3: 0.5,  $p=0.438$ ), respectively, and no significant changes were observed, and the median CRT was  $457.5\mu\text{m}$  (Q1: 362, Q3: 479,  $p=0.308$ ) and  $443.5\mu\text{m}$  (Q1: 386, Q3: 542,  $p=0.959$ ), respectively, and no significant changes were observed. Prior to the initiation of SGLT2 inhibitor, there were no natural improvement tendencies of VA and CRT. The specific changes of VA and CRT are respectively shown in figures 1 and 2.

We also analysed median CRT of the right eyes and left eyes at baseline and 12 months after the initiation of SGLT2 inhibitor in order to ascertain whether similar results could be obtained by the analysis of each unilateral eye, and the results are shown in online supplementary table 1.

The representative cases are shown in figure 3. Chronic DMO had already attenuated at 3 months after the initiation of treatment and continued to improve throughout the 12-month follow-up period. The treatment was found to be effective, and there was no recurrence of DMO.

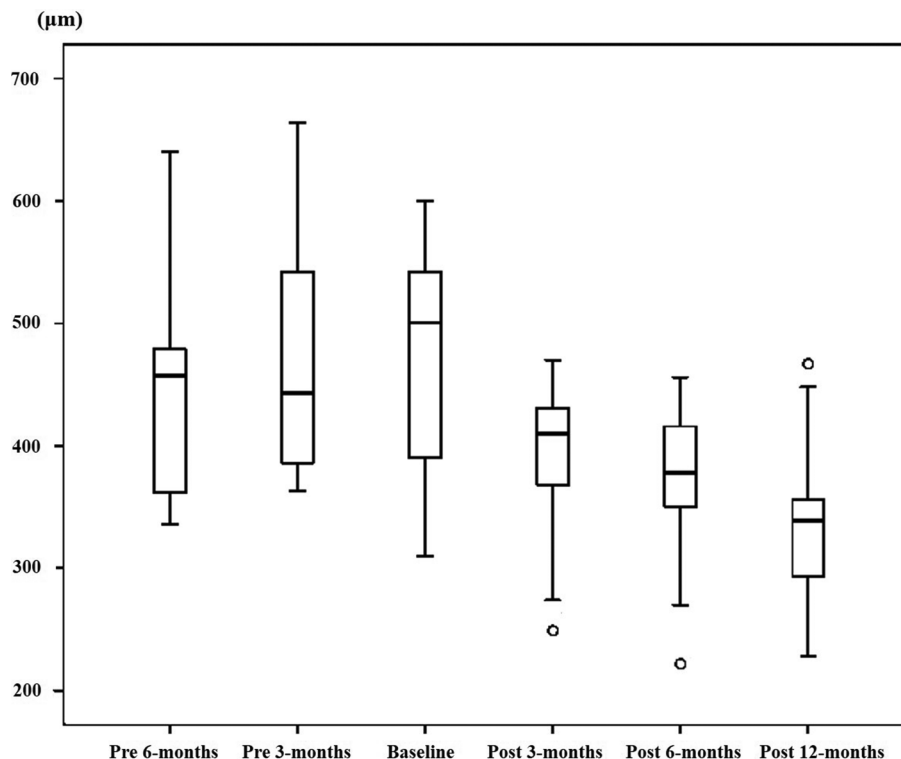
At the initiation of the SGLT2-inhibitor treatment, the blood glucose level in each patient was adjusted via insulin or sulfonylurea-agent reduction by diabetes specialists.

No complications were observed, and there was no discontinuation of treatment in all cases throughout the treatment course. The specific changes of glycated haemoglobin and estimated glomerular filtration rate in the blood test are shown in figure 4. Although some patients had hypertension and dyslipidaemia in addition to DM, they had already received treatment and those disorders were well controlled at baseline, and there were no changes or addition of systemic treatment for hypertension and dyslipidaemia throughout the follow-up period.

## DISCUSSION

To the best of our knowledge, this present study is the first to report cases in which chronic DMO improved after the initiation of the administration of SGLT2 inhibitors. Our findings confirmed that CRT continued to significantly reduce during the post-treatment follow-up periods; however, no significant change of VA was observed.

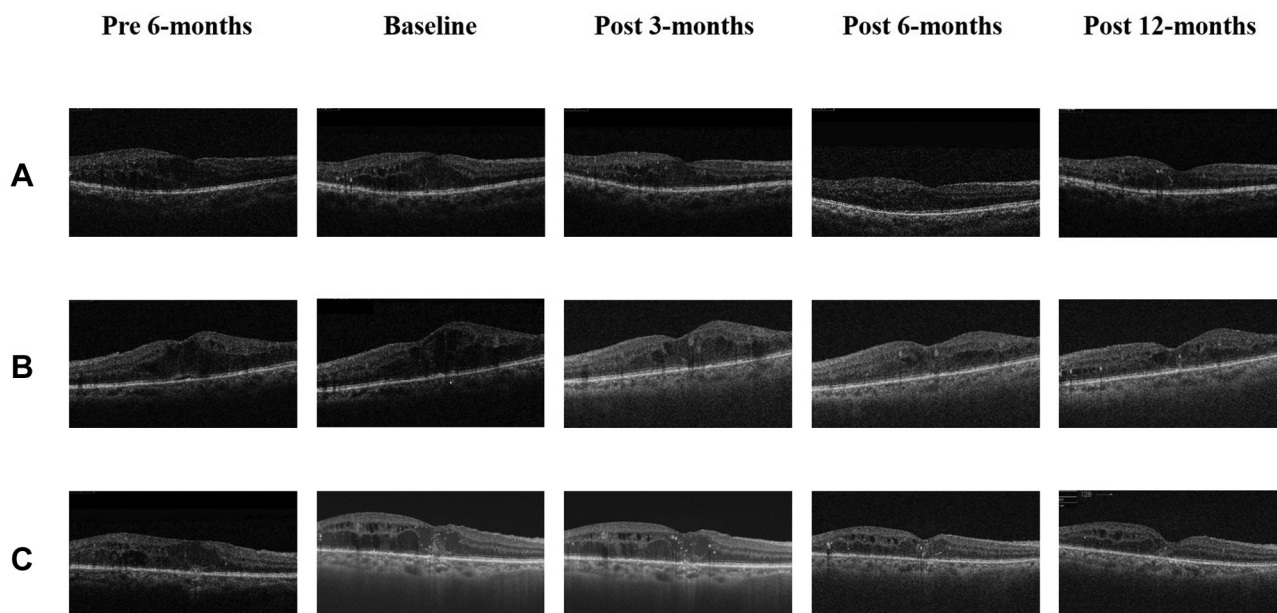
The findings in a previous study by Mitchell *et al*, which investigated ranibizumab monotherapy or combined with laser versus laser monotherapy for the treatment of patients with visual impairment due to DMO, showed the mean CRT change from baseline to 12 months after treatment decreased by  $61.3\mu\text{m}$  in the laser monotherapy group.<sup>11</sup> Korobelnik *et al*, who investigated intravitreal aflibercept monotherapy versus laser for the treatment of DMO, reported that the mean CRT change from baseline to 12 months in the laser-treated group decreased by



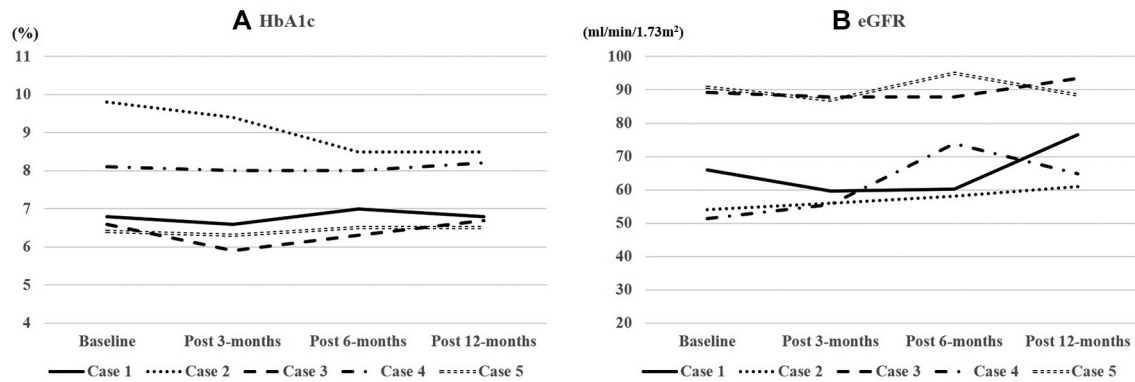
**Figure 2** Changes of central retinal thickness (CRT,  $\mu\text{m}$ ) at baseline, at 3 and 6 months before, and at 3, 6 and 12 months after the initiation of the administration of sodium–glucose cotransporter 2 inhibitor. The vertical-column boxes indicate values between the 25th and 75th percentiles (central line, median). The circles denote outliers. Median CRT significantly reduced from 500.5  $\mu\text{m}$  at baseline to 410  $\mu\text{m}$  at 3 months, 378  $\mu\text{m}$  at 6 months and 339  $\mu\text{m}$  at 12 months after the initiation of the treatment ( $p < 0.01$ , respectively) (Wilcoxon signed-rank test).

73.3  $\mu\text{m}$  (VISTA study) and 66.2  $\mu\text{m}$  (VIVID study).<sup>9</sup> In this study, the median CRT decreased by 161.5  $\mu\text{m}$ ; from 500.5  $\mu\text{m}$  at baseline to 339  $\mu\text{m}$  at 12 months after the initiation of SGLT2 inhibitor. Although a simple comparison

between our findings and those of the previous studies could not be made, it is possible that the CRT in our cases reduced due to the initiation of SGLT2 inhibitor. Moreover, although significant reduction of CRT was observed,



**Figure 3** Optical coherence tomography images showing the chronological change of representative cases from at 6 months before to 12 months after the initiation of the administration of sodium–glucose cotransporter 2 inhibitor. (A) The right eye of case 1, (B) the left eye of case 4 and (C) the right eye of case 5.



**Figure 4** Changes of (A) glycosylated haemoglobin (HbA1c) and (B) estimated glomerular filtration rate (eGFR) in the blood test at baseline and at 3, 6 and 12 months after the initiation of the administration of sodium–glucose cotransporter 2 inhibitor as a systemic medical treatment.

there was no significant change of VA. It should be noted that the optic cells were possibly already damaged due to the fact that the DMO in our cases was chronic. We theorise that the reason for the decrease in CRT was possibly due to the inherent effect of SGLT2 inhibitor and/or a diuretic effect. Previous studies have reported that SGLT2 exists in cultured bovine retinal pericytes and that the cellular tone of bovine retinal pericytes was regulated by extracellular glucose concentration, and that this regulation depended on  $\text{Na}^+$  ion entry through SGLT2.<sup>2–4</sup> To date, no studies have reported evidence showing that SGLT2 naturally exists in the human retina. However, we theorised that SGLT2 is possibly present in human, as well as in bovine, retinal pericytes, and that the administration of SGLT2 inhibitor may change the retinal microvascular circulation, thus having an effect on DMO. With that said, it is important to consider that diuretic action may have had a positive effect. In this study, since all treated eyes had previously undergone vitrectomy, there was no traction to fovea and diuretic action might work better.

Zinman *et al* reported that empagliflozin, one of the SGLT2 inhibitors, reduced the risk of major adverse cardiovascular events in patients with type 2 diabetes at high risk for cardiovascular events,<sup>12</sup> and in a report by Kimura, it was theorised that this cardioprotective action is related to diuretic action.<sup>13</sup> In addition, Wanner *et al* reported that empagliflozin is associated with slower progression of kidney disease and lower rates of clinically relevant renal events than the placebo when added to standard medical care.<sup>14</sup> Similar to the heart and kidney findings in that study, the suppression of diabetic retinopathy might also occur when SGLT2 inhibitors are added to the standard medical care.

In this present study, the systemic effects of SGLT2 inhibitors were assessed by blood tests. Some changes were observed during the follow-up period; however, all cases underwent a long-term treatment course and it was doubtful if such an insignificant change affected the chronic DMO. It is thought that SGLT2 inhibitor may

have some effect on DMO, beyond its effect on glycaemic control or renal function.

It should be noted that this current study did have some limitations, that is, the small number of cases, and the fact that it was not a control study. Since all cases in this study were non-vitreous and after panretinal photocoagulation, it remains unknown as to whether or not our findings apply to all DMO cases. As shown in online supplementary file, even in the analysis of one eye, we obtained similar results; however, the potential effect of the inter-eye correlation could not be eliminated. Thus, a future prospective study involving a larger number of cases is needed to more clearly elucidate the effect of the SGLT2 inhibitors on DMO.

In conclusion, the findings in this study show that in cases of chronic DMO, continuous treatment is necessary, and that SGLT2 inhibitors might have an effect on DMO.

**Acknowledgements** The authors wish to thank John Bush for reviewing and editing the manuscript, and thank to Kengo Yoshii for providing excellent statistical advice.

**Contributors** HM contributed to study design, researched ophthalmological data and wrote the manuscript. KY contributed to study design, performed ophthalmological examinations and wrote the manuscript. MY contributed to study design, performed physical examinations and reviewed the manuscript. RS researched physical data and reviewed the manuscript. CS and MF acted as the study coordinators and reviewed the manuscript. All authors contributed to the review of the data and discussion of the results, and gave approval of the final version of the manuscript submitted for publication.

**Funding** The authors have not declared a specific grant for this research from any funding agency in the public, commercial or not-for-profit sectors.

**Competing interests** None declared.

**Patient consent** Not required.

**Ethics approval** Kyoto Prefectural University of Medicine ERB-C-816-1.

**Provenance and peer review** Not commissioned; externally peer reviewed.

**Open access** This is an open access article distributed in accordance with the Creative Commons Attribution Non Commercial (CC BY-NC 4.0) license, which permits others to distribute, remix, adapt, build upon this work non-commercially, and license their derivative works on different terms, provided the original work is properly cited, appropriate credit is given, any changes made indicated, and the use is non-commercial. See: <http://creativecommons.org/licenses/by-nc/4.0/>.

## REFERENCES

1. Ciulla TA, Amador AG, Zinman B. Diabetic retinopathy and diabetic macular edema: pathophysiology, screening, and novel therapies. *Diabetes Care* 2003;26:2653–64.
2. Wakisaka M, Yoshinari M, Yamamoto M, *et al.* Na<sup>+</sup>-dependent glucose uptake and collagen synthesis by cultured bovine retinal pericytes. *Biochim Biophys Acta* 1997;1362:87–96.
3. Wakisaka M, Yoshinari M, Asano T, *et al.* Normalization of glucose entry under the high glucose condition by phlorizin attenuates the high glucose-induced morphological and functional changes of cultured bovine retinal pericytes. *Biochim Biophys Acta* 1999;1453:83–91.
4. Wakisaka M, Kitazono T, Kato M, *et al.* Sodium-coupled glucose transporter as a functional glucose sensor of retinal microvascular circulation. *Circ Res* 2001;88:1183–8.
5. Giusti C, Forte R, Vingolo EM, *et al.* Is acetazolamide effective in the treatment of diabetic macular edema? A pilot study. *Int Ophthalmol* 2001;24:79–88.
6. Ciardella AP. Partial resolution of diabetic macular oedema after systemic treatment with furosemide. *Br J Ophthalmol* 2004;88:1224–5.
7. Miller JW, Le Couter J, Strauss EC, *et al.* Vascular endothelial growth factor a in intraocular vascular disease. *Ophthalmology* 2013;120:106–14.
8. Brown DM, Nguyen QD, Marcus DM, *et al.* Long-term outcomes of ranibizumab therapy for diabetic macular edema: the 36-month results from two phase III trials: RISE and RIDE. *Ophthalmology* 2013;120:2013–22.
9. Korobelnik JF, Do DV, Schmidt-Erfurth U, *et al.* Intravitreal aflibercept for diabetic macular edema. *Ophthalmology* 2014;121:2247–54.
10. Niwa Y, Kakinoki M, Sawada T, *et al.* Ranibizumab and aflibercept: intraocular pharmacokinetics and their effects on aqueous VEGF level in vitrectomized and nonvitrectomized macaque eyes. *Invest Ophthalmol Vis Sci* 2015;56:6501–5.
11. Mitchell P, Bandello F, Schmidt-Erfurth U, *et al.* The RESTORE study: ranibizumab monotherapy or combined with laser versus laser monotherapy for diabetic macular edema. *Ophthalmology* 2011;118:615–25.
12. Zinman B, Wanner C, Lachin JM, *et al.* Empagliflozin, cardiovascular outcomes, and mortality in type 2 diabetes. *N Engl J Med Overseas Ed* 2015;373:2117–28.
13. Kimura G. Diuretic action of sodium-glucose cotransporter 2 inhibitors and its importance in the management of heart failure. *Circulation Journal* 2016;80:2277–81.
14. Wanner C, Inzucchi SE, Lachin JM, *et al.* Empagliflozin and progression of kidney disease in type 2 diabetes. *N Engl J Med Overseas Ed* 2016;375:323–34.