
Anesthesia for triggered electromyography-guided cord detethering in a three-month-old infant

Tethered cord syndrome is a congenital anomaly that is characterized by stretch-induced functional disorder. The surgical outcome depends on meticulous dissection of fibrous strands and preservation of the neural structure before detethering. Intraoperative neurophysiological monitoring is commonly implemented during spinal cord detethering.^[1,2] Triggered electromyography (EMG) is an essential tool to prevent postoperative neurological deficits. We present successful management of tethered cord syndrome in a 3-month-old infant utilizing the triggered EMG.

A 3-month-old infant presented with asymptomatic dermal sinus, and the preoperative magnetic resonance imaging of the spinal cord revealed tethered cord at the level of lower lumbar and sacral segments. Neurological examination was unremarkable without a neurological deficit. The infant was posted for cord detethering under general anesthesia along with triggered EMG monitoring of lumbosacral roots. Following the standard pediatric anesthetic induction, needle electrodes for recording the compound muscle action potential were placed in the tibialis anterior (L4–L5), abductor hallucis longus (L5–S1), and anal sphincter (S3–S4) bilaterally [Figure 1a and b]. Following prone positioning,

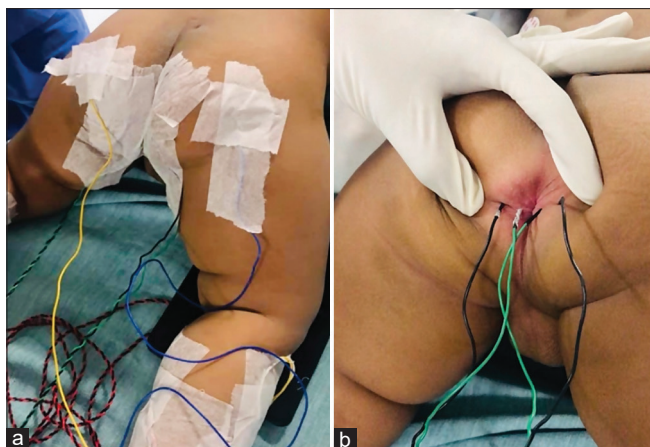


Figure 1: (a) The placement of lower limb muscle needle electrodes for triggered EMG monitoring. (b) The placement of anal sphincter needle electrodes for triggered EMG monitoring

intraoperative anesthesia was maintained with sevoflurane with a minimal inhibitory concentration of 0.8 and 0.1 mg/kg of intravenous morphine without the administration of muscle relaxant. During surgical dissection, the surgeon performed the mapping of nerve roots by intermittent monopolar stimulation (1-5 mA) thereby eliciting the corresponding compound muscle action potential. Detethering of the cord was performed successfully, and the integrity of nerve roots was ensured once again before the surgical closure. The trachea was extubated, and the infant was neurologically intact without any deficit.

Triggered EMG was first described as a tool to assess the correct placement of the pedicle screws during spine surgeries.^[3] Tethered cord syndrome can present in any age group, and an early intervention poses a better outcome. The utility of triggered EMG is quite challenging in an infant due to lack of myelination hence difficulty in evoking a response. But this can be overcome by the application of a stimulation current of higher intensity. Optimal anesthesia with avoidance of muscle relaxation technique is crucial for eliciting a triggered EMG response. Even though total intravenous anesthesia (TIVA) is the best choice, triggered EMG responses are much resistant to inhalational agents. TIVA can have its sets of complications like delayed awakening in infants, and inhalational agents with no muscle relaxant can provide elicitable responses in the setting of triggered EMG monitoring. From a surgical perspective, triggered EMG can facilitate the surgeon in differentiating a neural and non-neural structure before detethering the fibrous strands. Even though neurophysiologists are commonly involved in intraoperative neurophysiological monitoring, neuro anesthesiologists are taking over this part in the current era.

To conclude, triggered EMG is a point of care intraoperative neuromonitoring tool, and the anesthesiologists must

be familiar with the technique to facilitate intraoperative monitoring.

Declaration of patient consent

A full and detailed consent from the patient's parent/guardian has been taken for publication. Patient identity is not disclosed.

Financial support and sponsorship

Nil.

Conflicts of interest

There are no conflicts of interest.

BALAJI VAITHIALINGAM

Department of Neuroanaesthesia and Neurocritical Care, National Institute of Mental Health and Neurosciences (NIMHANS), Bengaluru, Karnataka, India

Address for correspondence: Dr. Balaji Vaithialingam, Department of Neuroanaesthesia and Neurocritical Care, National Institute of Mental Health and Neurosciences (NIMHANS), Bengaluru - 560 029, Karnataka, India.
E-mail: balamedicine04@gmail.com


Submitted: 19-Jan-2022, **Accepted:** 19-Jan-2022,

Published: 17-Mar-2022

References

1. Shinomiya K, Fuchioka M, Matsuoka T, Okamoto A, Yoshida H, Mutoh N, *et al.* Intraoperative monitoring for tethered spinal cord syndrome. *Spine* 1991;16:1290-4.
2. Lueders H, Hahn J, Gurd A, Gurd A, Tsuji S, Lesser R, *et al.* Surgical monitoring of spinal cord function: Cauda equina stimulation technique. *Neurosurgery* 1982;11:482-5.
3. Calancie B, Lebowitz N, Madsen P, Klose KJ. Intraoperative evoked EMG monitoring in an animal model. A new technique for evaluating pedicle screw placement. *Spine* 1992;17:1229-35.

This is an open access journal, and articles are distributed under the terms of the Creative Commons Attribution-NonCommercial-ShareAlike 4.0 License, which allows others to remix, tweak, and build upon the work non-commercially, as long as appropriate credit is given and the new creations are licensed under the identical terms.

Access this article online	
Website: www.saudija.org	Quick Response Code 
DOI: 10.4103/sja.sja_49_22	

How to cite this article: Vaithialingam B. Anaesthesia for triggered electromyography guided cord detethering in a three-month-old infant. *Saudi J Anaesth* 2022;16:270-1.

© 2022 Saudi Journal of Anesthesia | Published by Wolters Kluwer - Medknow