

Functional Recovery following Repair of Long Nerve Gaps in Senior Patient 2.6 Years Posttrauma

Christian A. Foy, MD*
 William F. Micheo, MD†
 Damien P. Kuffler, PhD‡

Summary: Sensory nerve grafts are the clinical “gold standard” for repairing peripheral nerve gaps. However, reliable good-to-excellent recovery develops only for gaps less than 3–5 cm, repairs performed less than 3–5 months posttrauma, and patients aged less than 20–25 years. As the value of any variable increases, the extent of recovery decreases precipitously, and if the values of any two or all increase, there is little to no recovery. One 9-cm-long and two 11-cm-long nerve gaps in a 56-year-old patient were repaired 2.6 years posttrauma. They were bridged with two sensory nerve grafts within an autologous platelet-rich plasma-filled collagen tube. Both were connected to the proximal ulnar nerve stump, with one graft end to the distal motor and the other to the sensory nerve branches. Although presurgery the patient suffered chronic level 10 excruciating neuropathic pain, it was reduced to 6 within 2 months, and did not increase for more than 2 years. Motor axons regenerated across the 9-cm gap and innervated the appropriate two measured muscles, with limited muscle fiber recruitment. Sensory axons regenerated across both 11-cm gaps and restored normal topographically correct sensitivity to stimuli of all sensory modalities, including static two-point discrimination of 5 mm, and pressure of 2.83 g to all regions innervated by both sensory nerves. This novel technique induced a significant long-term reduction in chronic excruciating neuropathic pain while promoting muscle reinnervation and complete sensory recovery, despite the values of all three variables that reduce or prevent axon regeneration and recovery being simultaneously large. (*Plast Reconstr Surg Glob Open* 2021;9:e3831; doi: [10.1097/GOX.0000000000003831](https://doi.org/10.1097/GOX.0000000000003831); Published online 22 September 2021.)

INTRODUCTION

The capacity of sensory nerve grafts, the clinical “gold standard” technique, to restore function to peripheral nerves with a gap^{1,2} is significantly limited by increasing gap length, time between trauma and repair, and patient age. Thus, reliable good-to-excellent recovery develops only across gaps less than 3–5 cm,^{2–7} repairs performed less than 3–5 months posttrauma,^{4,5} and patients aged less than 20–25 years.^{3–5} As the value of any variable increases, the extent of recovery decreases.^{3–19} As any two variables increase, there is a precipitous decrease in recovery.²⁰ If all three increase simultaneously, there is very limited to no recovery.^{4,9,20,21}

From the *Section of Orthopedic Surgery, Medical Sciences Campus, University of Puerto Rico, San Juan, Puerto Rico; †Department of Physical Medicine & Rehabilitation, Medical Sciences Campus, University of Puerto Rico, San Juan, Puerto Rico; and ‡Institute of Neurobiology, Medical Sciences Campus, University of Puerto Rico, San Juan, Puerto Rico.

Received for publication June 4, 2021; accepted July 28, 2021.

Copyright © 2021 The Authors. Published by Wolters Kluwer Health, Inc. on behalf of The American Society of Plastic Surgeons. This is an open access article distributed under the [Creative Commons Attribution License 4.0 \(CCBY\)](https://creativecommons.org/licenses/by/4.0/), which permits unrestricted use, distribution, and reproduction in any medium, provided the original work is properly cited.

DOI: [10.1097/GOX.0000000000003831](https://doi.org/10.1097/GOX.0000000000003831)

MATERIALS AND METHODS

Patient

Here, we report on a 56-year-old man who presented 2.6 years after a zone 4–5 ulnar nerve laceration resulting in severe intrinsic muscle atrophy and loss of sensation to ring and small finger digital ulnar nerve distribution.

Surgery

The nerve trauma region was exposed from the wrist to the trifurcation of its first motor and two sensory branches (Fig. 1A). The nerve stumps were trimmed to remove visible damaged tissue.

A 22-cm length of sural nerve was removed and cut into two lengths. The ends of both grafts were loosely secured to the proximal ulnar nerve stump, while the other end of one was loosely secured to the distal motor nerve branch and the other to the two distal sensory nerve branches (Fig. 1B).

The nerve grafts were surrounded with a tube of two 5-cm and one 3-cm lengths of NeuroMend collagen tubes (Collagen Matrix Inc., Oakland, N.J.) (Fig. 1C). The tubes have a longitudinal slit and are self-closing with a 25% overlap, which allows opening the tubes and slipping the nerve grafts inside.

Disclosure: The authors have no financial interest in relation to the content of this article.

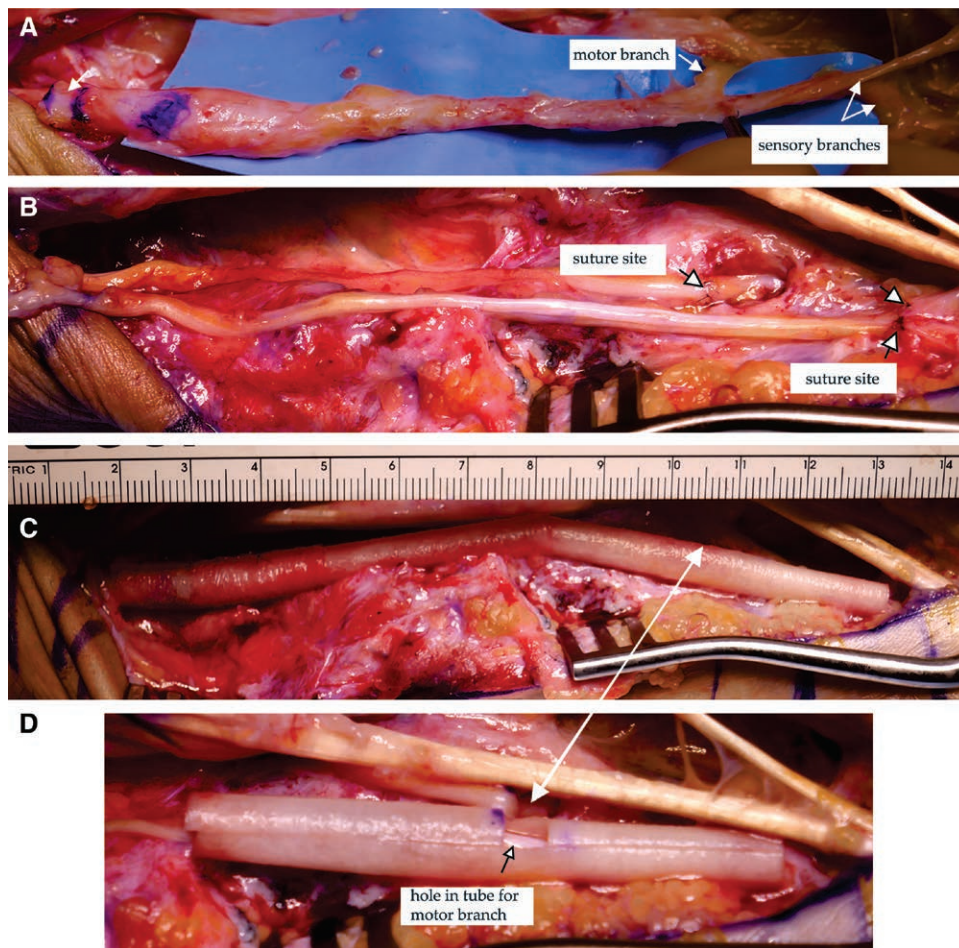


Fig. 1. Technique for repairing three long nerve gaps. Repair of one 9-cm-long and two 11-cm-long ulnar nerve gaps. A, Exposed ulnar nerve in the wrist/palm showing the severely damaged nerve. The arrow near the blue lines marks where the nerve will be cut. The other arrows indicate where the motor and two sensory branches will be cut. B, Two sural nerve grafts with their distal ends secured to the motor and two sensory nerve branches (marked by arrows). The proximal ends of the grafts are not yet secured to the proximal ulnar nerve stump. C, Completed nerve gap repair after injecting the PRP inside the collagen tube. D, Blow-up of the distal collagen tube with a hole cut into one side, marked by a black arrow, through which the motor branch entered into the collagen tube. The white arrow between panels C and D indicates the location of the hole in the completed collagen tube.

Because the distal motor nerve branch was proximal to the distal end of the tube, a hole was cut in its side into which the motor branch was slipped (Fig. 1C, D). The collagen tubes were adjusted to ensure overlapping ends and that the anastomosis sites were 2 mm or more inside the collagen tube.

Platelet-rich Fibrin

An estimated 6cc of platelet-rich plasma (PRP) was prepared and injected as previously described.²²

RESULTS

After removing the damaged nerve tissue, the motor branch had a 9-cm gap, and the two sensory nerve branches had 11-cm gaps. Electrodiagnostic and physical examinations performed 1.75 years postrepair established the presence of ulnar motor axon electrical continuity across the 9-cm gap to the abductor digit minima and

adductor pollicis muscles. Evoked motor axon action potentials to the adductor digiti minimi of the little finger had a prolonged latency of 4.13 versus 2.90 ms for the opposite hand and a decreased amplitude of 0.023 versus 10.1 mV, whereas those to the first dorsal interosseous had an adequate latency of 3.49 versus 3.90 ms, and a decreased amplitude of 1.07 versus 9.24 mV.

Electromyography studies established motor axon reinnervation of adductor digiti minimi and first dorsal interosseous muscle fibers. Evoked contractions were minimal due to poor muscle fiber recruitment.

Nerve conduction studies established electrical continuity across both 11-cm sensory nerve gaps, with a prolonged action potential latency of 4.50 versus 3.45 ms for the opposite hand and a decreased amplitude of 3.1 versus 9.5 mV. The dorsal ulnar sensory nerve branch had normal latency parameters of 2.95 versus 2.50 ms and 12.6 versus 7.90 mV amplitudes.

Sensory tests showed recovery of normal levels of topographically correct sensitivity to stimuli of all sensory modalities to all appropriate areas of the skin of both the small and ring fingers. This included sensitivity to light stroking, pinprick, deep pressure, hot and cold, and vibration, and correct proprioception to MCP, PIP, and DIP movements. The little finger developed static two-point discrimination of 5 mm, and the ring finger of 6–8 mm. Both fingers had a pressure sensitivity of 2.83 g. The sensory recovery by both sensory nerve branches was S4.

Although presurgery the subject suffered level 10 chronic excruciating neuropathic pain, it was reduced to 6 within 2 months. Subsequently, the level did not change for more than 2 years.

DISCUSSION

Although sensory nerve grafts are the clinical “gold standard” technique for repairing nerve gaps,^{1,2} recovery is often disappointing.^{17,23,24} This is attributed to the negative influence of the increasing values of gap length, time between trauma and repair, and patient age.¹² Thus, reliable good-to-excellent recovery is only across gaps less than 3–5 cm,^{2–7} repairs performed less than 3–5 months posttrauma,^{4,5} and patients aged less than 20–25 years.^{3–5,19,25,26} As any value increases, recovery decreases precipitously.¹⁸ When all three values increase simultaneously, there is very limited to no recovery.^{4,9,20,21}

Three long nerve gaps of a 56-year-old patient were repaired 2.6 years posttrauma using sensory nerve grafts within a PRP-filled collagen tube. Despite a 9-cm motor nerve gap, muscle fibers of the appropriate muscles were reinnervated. Limited contractions are attributed to poor muscle fiber recruitment due to massive muscle fiber atrophy.

Sensory axons regenerated entirely across both 11-cm gaps and established normal levels of topographically correct sensitivity to stimuli of all sensory modalities by all finger regions normally innervated by the two nerves. This included a static two-point discrimination of 5 mm and 6–8 mm, and a pressure sensitivity of 2.83 gm, comparable to the contralateral hand.

Although the patient suffered excruciating level 10 chronic neuropathic pain before surgery, it was reduced to 6 within 2 months. Subsequently, the pain did not change for more than 2 years.

When the values of all three variables that negatively influence axon regeneration are simultaneously large, sensory nerve grafts do not induce the observed axon regeneration, reinnervation, and recovery. This suggests that platelet-released factors promoted the recovery. This hypothesis is consistent with animal^{27–40} and clinical^{22,41,42} studies showing that PRP enhances axon regeneration.

In conclusion, despite simultaneous long nerve gaps, long repair delay, and older age, bridging nerve gaps with a sensory nerve graft within a PRP-filled collagen tube significantly reduces chronic neuropathic pain while inducing axon regeneration and recovery under conditions where sensory nerve grafts alone are not effective. The use of PRP in this study is off-label.

Damien P. Kuffler, PhD

Institute of Neurobiology

201 Blvd. del Valle

San Juan 00901

Puerto Rico

E-mail: dkuffler@hotmail.com

ACKNOWLEDGMENT

This study was performed under a local IRB-approved clinical study protocol and conformed to the Declaration of Helsinki.

REFERENCES

- Kornfeld T, Vogt PM, Radtke C. Nerve grafting for peripheral nerve injuries with extended defect sizes. *Wien Med Wochenschr.* 2019;169:240–251.
- Pan D, Mackinnon SE, Wood MD. Advances in the repair of segmental nerve injuries and trends in reconstruction. *Muscle Nerve.* 2020;61:726–739.
- Karabeg R, Jakirlic M, Dujso V. Sensory recovery after forearm median and ulnar nerve grafting. *Med Arh.* 2009;63:97–99.
- Terzis JK, Kokkalis ZT. Outcomes of secondary reconstruction of ulnar nerve lesions: Our experience. *Plast Reconstr Surg.* 2008;122:1100–1110.
- Matejčík V, Péntesová G. [Rare compression syndromes of the peripheral nerves of the forearm and distal leg]. *Rozhl Chir.* 2006;85:143–147.
- Hoben GM, Ee X, Schellhardt L, et al. Increasing nerve autograft length increases senescence and reduces regeneration. *Plast Reconstr Surg.* 2018;142:952–961.
- Terzis JK, Konofaos P. Radial nerve injuries and outcomes: Our experience. *Plast Reconstr Surg.* 2011;127:739–751.
- Aszmann OC, Korak KJ, Luegmair M, et al. Bridging critical nerve defects through an acellular homograft seeded with autologous Schwann cells obtained from a regeneration neuroma of the proximal stump. *J Reconstr Microsurg.* 2008;24:151–158.
- Shergill G, Bonney G, Munshi P, et al. The radial and posterior interosseous nerves. Results of 260 repairs. *J Bone Joint Surg Br.* 2001;83:646–649.
- Lee YH, Chung MS, Gong HS, et al. Sural nerve autografts for high radial nerve injury with nine centimeter or greater defects. *J Hand Surg Am.* 2008;33:83–86.
- Forde J, Xu QG, Khu KJ, et al. A long peripheral nerve autograft model in the sheep forelimb. *Neurosurgery.* 2011;68:1354–62; discussion 1362.
- Singh R, Mechelse K, Hop WC, et al. Long-term results of transplantations to repair median, ulnar, and radial nerve lesions by a microsurgical interfascicular autogenous cable graft technique. *Surg Neurol.* 1992;37:425–431.
- Roganovic Z, Petkovic S. Missile severances of the radial nerve. Results of 131 repairs. *Acta Neurochir (Wien).* 2004;146:1185–1192.
- Alnot J, Osman N, Masmajejan E, et al. [Lesions of the radial nerve in fractures of the humeral diaphysis. Apropos of 62 cases]. *Rev Chir Orthop Reparatrice Appar Mot.* 2000;86:143–150.
- Jonsson S, Wiberg R, McGrath AM, et al. Effect of delayed peripheral nerve repair on nerve regeneration, Schwann cell function and target muscle recovery. *PLoS One.* 2013;8:e56484.
- Pan CH, Chuang DC, Rodríguez-Lorenzo A. Outcomes of nerve reconstruction for radial nerve injuries based on the level of injury in 244 operative cases. *J Hand Surg Eur Vol.* 2010;35:385–391.
- Sarhane KA, Slavin BR, Hricz N, et al. Defining the relative impact of muscle versus Schwann cell denervation on functional recovery after delayed nerve repair. *Exp Neurol.* 2021;339:113650.

18. Scheib J, Höke A. Advances in peripheral nerve regeneration. *Nat Rev Neurol*. 2013;9:668–676.
19. Kallio PK, Vastamäki M, Solonen KA. The results of secondary microsurgical repair of radial nerve in 33 patients. *J Hand Surg Br*. 1993;18:320–322.
20. Ruijs AC, Jaquet JB, Kalmijn S, et al. Median and ulnar nerve injuries: A meta-analysis of predictors of motor and sensory recovery after modern microsurgical nerve repair. *Plast Reconstr Surg*. 2005;116:484–94; discussion 495.
21. Grinsell D, Keating CP. Peripheral nerve reconstruction after injury: A review of clinical and experimental therapies. *Biomed Res Int*. 2014;2014:698256.
22. Kuffler DP, Reyes O, Sosa IJ, et al. Neurological recovery across a 12-cm-long ulnar nerve gap repaired 3.25 years post trauma: Case report. *Neurosurgery*. 2011;69:E1321–E1326.
23. Sunderland S. Founder’s Lecture—American Society for Surgery of the Hand. *J Hand Surg Am*. 1979;4:201–211.
24. Terzis JK, Smith KJ. Repair of severed peripheral nerves: Comparison of the “de Medinaceli” and standard microsuture methods. *Exp Neurol*. 1987;96:672–680.
25. Costales JR, Socolovsky M, Sánchez Lázaro JA, et al. Peripheral nerve injuries in the pediatric population: A review of the literature. Part I: Traumatic nerve injuries. *Childs Nerv Syst*. 2019;35:29–35.
26. Kallio PK, Vastamäki M. An analysis of the results of late reconstruction of 132 median nerves. *J Hand Surg Br*. 1993;18:97–105.
27. Torul D, Bereket MC, Onger ME, et al. Comparison of the regenerative effects of platelet-rich Fibrin and plasma rich in growth factors on injured peripheral nerve: An experimental study. *J Oral Maxillofac Surg*. 2018;76:1823.e1–1823.e12.
28. Sánchez M, Anitua E, Delgado D, et al. Ultrasound-guided plasma rich in growth factors injections and scaffolds hasten motor nerve functional recovery in an ovine model of nerve crush injury. *J Tissue Eng Regen Med*. 2017;11:1619–1629.
29. Kūçük L, Günay H, Erbaş O, et al. Effects of platelet-rich plasma on nerve regeneration in a rat model. *Acta Orthop Traumatol Turc*. 2014;48:449–454.
30. Cho HH, Jang S, Lee SC, et al. Effect of neural-induced mesenchymal stem cells and platelet-rich plasma on facial nerve regeneration in an acute nerve injury model. *Laryngoscope*. 2010;120:907–913.
31. Teymur H, Tiftikcioglu YO, Cavusoglu T, et al. Effect of platelet-rich plasma on reconstruction with nerve autografts. *Kaohsiung J Med Sci*. 2017;33:69–77.
32. Ikumi A, Hara Y, Yoshioka T, et al. Effect of local administration of platelet-rich plasma (PRP) on peripheral nerve regeneration: An experimental study in the rabbit model. *Microsurgery*. 2018;38:300–309.
33. Zheng C, Zhu Q, Liu X, et al. Improved peripheral nerve regeneration using acellular nerve allografts loaded with platelet-rich plasma. *Tissue Eng Part A*. 2014;20:3228–3240.
34. Chuang MH, Ho LH, Kuo TF, et al. Regenerative potential of platelet-rich fibrin releasate combined with adipose tissue-derived stem cells in a rat sciatic nerve injury model. *Cell Transplant*. 2020;29:963689720919438.
35. Abbasipour-Dalivand S, Mohammadi R, Mohammadi V. Effects of local administration of platelet rich plasma on functional recovery after bridging sciatic nerve defect using silicone rubber chamber; an experimental study. *Bull Emerg Trauma*. 2015;3:1–7.
36. Roque JS, Pomini KT, Buchaim RL, et al. Inside-out and standard vein grafts associated with platelet-rich plasma (PRP) in sciatic nerve repair. A histomorphometric study. *Acta Cir Bras*. 2017;32:617–625.
37. Kornfeld T, Nessler J, Helmer C, et al. Spider silk nerve graft promotes axonal regeneration on long distance nerve defect in a sheep model. *Biomaterials*. 2021;271:120692.
38. Burks SS, Diaz, A, Haggerty, AE, et al. Schwann cell delivery via a novel 3D collagen matrix conduit improves outcomes in critical length nerve gap repairs. *J Neurosurg*. 2021;27:1–11.
39. Choi BH, Han SG, Kim SH, et al. Autologous fibrin glue in peripheral nerve regeneration in vivo. *Microsurgery*. 2005;25:495–499.
40. Kim JY, Jeon WJ, Kim DH, et al. An inside-out vein graft filled with platelet-rich plasma for repair of a short sciatic nerve defect in rats. *Neural Regen Res*. 2014;9:1351–1357.
41. Sánchez M, Yoshioka T, Ortega M, et al. Ultrasound-guided platelet-rich plasma injections for the treatment of common peroneal nerve palsy associated with multiple ligament injuries of the knee. *Knee Surg Sports Traumatol Arthrosc*. 2014;22:1084–1089.
42. Garcia de Cortazar U, Padilla S, Lobato E, et al. Intra-neural platelet-rich plasma injections for the treatment of radial nerve section: A case report. *J Clin Med*. 2018;7:13.