



# Intraleural Migration of Ventriculoperitoneal Shunt due to Negative Intrathoracic Pressure

Siddharth Srinivasan<sup>1</sup> Yasaswi Kanneganti<sup>1</sup> Rajesh Nair<sup>1</sup> Ajay Hegde<sup>2</sup> Sarah Johnson<sup>3</sup>  
Girish Menon<sup>1</sup>

<sup>1</sup>Department of Neurosurgery, Kasturba Medical College and Hospital, Udupi, Karnataka, India

<sup>2</sup>Department of Neurosurgery, Manipal Hospitals, Bangalore, Karnataka, India

<sup>3</sup>Post Doctoral Research Fellow, Department of Neurologic Surgery, Mayo Clinic, Rochester, Minnesota

Address for correspondence Siddharth Srinivasan, MCh, Department of Neurosurgery, Kasturba Medical College and Hospital, Manipal, Udupi, Karnataka 576104, India  
(e-mail: dr.siddharth.s.93@gmail.com).

Asian J Neurosurg 2024;19:408–411.

## Abstract

**Background** Ventriculoperitoneal (VP) shunt is still a mainstay of treatment in centers for infants with aqueductal stenosis which is the most common cause of congenital obstructive hydrocephalus. Shunt migration remains a common complication. Delayed distal shunt tip migration into the thoracic cavity due to negative intrathoracic pressure is a rare occurrence.

**Case Presentation** Authors report a 1-year-old infant presenting with drowsy sensorium, increasing head circumference, and bulging anterior fontanelle. Magnetic resonance imaging of the brain revealed significant obstructive hydrocephalus with periventricular seepage. A large expansile diverticulum of the suprapineal recess extending infratentorially compressing the dorsal midbrain and cerebellum inferiorly. The child underwent an emergency right-side VP shunt (medium pressure) in view of clinical symptoms of raised intracranial pressure. A right iliac fossa infraumbilical transverse incision was taken for placing the abdominal end. Visual confirmation of bowel was done after opening the peritoneum by two operating surgeons prior to inserting the distal catheter. Postoperative course was uneventful. The child presented 3 months later with acute dyspnea and diminished breath sounds on the right hemithorax. Neurologically, the child was active, feeding well, and anterior fontanelle was lax. A chest roentgenogram and computed tomogram (CT) of the thorax revealed complete shunt migration into the pleural space with significant pleural effusion on the right side. The distal shunt system on CT appeared to enter the pleural space below the 8th rib, probably indicating that there was subcostal tunneling of the shunt below the 8th rib space during the first surgery which was inconspicuous and subsequently over a span of 3 months due to sucking effect of negative intrathoracic pressure the shunt gradually migrated into the pleural cavity which led to the effusion. An emergency VP shunt revision was performed. The distal end below the chamber was retunneled subcutaneously into a new incision in the left paraumbilical region. Postoperative chest

## Keywords

- ▶ CSF flow problem
- ▶ hydrocephalus
- ▶ neurology
- ▶ neurosciences
- ▶ neurosurgery
- ▶ pediatrics

article published online  
June 7, 2024

DOI <https://doi.org/10.1055/s-0044-1787675>.  
ISSN 2248-9614.

© 2024. Asian Congress of Neurological Surgeons. All rights reserved.

This is an open access article published by Thieme under the terms of the Creative Commons Attribution-NonDerivative-NonCommercial-License, permitting copying and reproduction so long as the original work is given appropriate credit. Contents may not be used for commercial purposes, or adapted, remixed, transformed or built upon. (<https://creativecommons.org/licenses/by-nc-nd/4.0/>)

Thieme Medical and Scientific Publishers Pvt. Ltd., A-12, 2nd Floor, Sector 2, Noida-201301 UP, India

and abdomen roentgenograms showed resolving effusion and accurate shunt placement. The child required elective ventilation temporarily to tide over the underlying lung collapse and an intercostal tube drainage for the cerebrospinal fluid (CSF) hydrothorax for 2 days to aid in quicker weaning. The child was discharged on the 5th postoperative day.

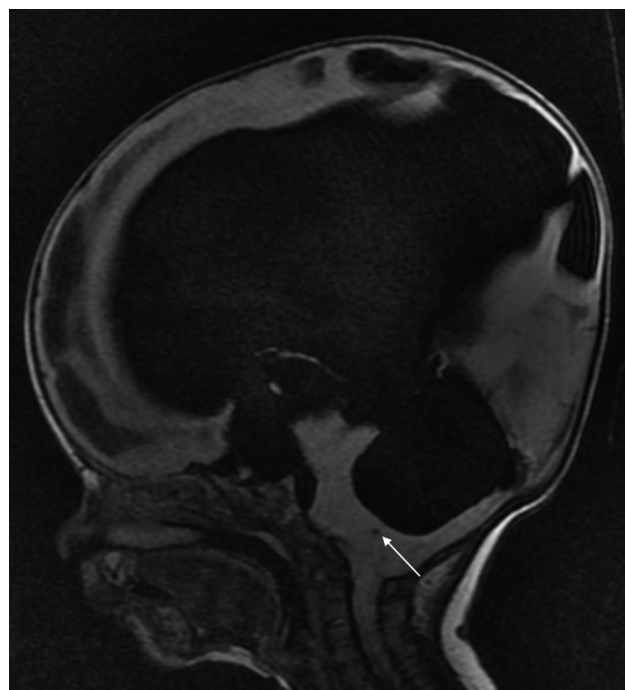
**Discussion** Intraleural migration of VP shunts has been contemplated to be due to trauma during surgery, migration across foramen of Bochdalek or Morgagni, and negative intrathoracic pressure. Taub and Lavyne have classified thoracic complications of VP shunt as thoracic trauma during shunt tunneling, supradiaphragmatic migration of shunt or transdiaphragmatic migration of shunt, and pleural effusion complicated by CSF ascites. Transdiaphragmatic migration is commonly seen in pediatric population and supradiaphragmatic migration can be seen in any age group. We believe our case to be a type of supradiaphragmatic migration of the shunt which has occurred slowly over a span of time due to the negative intrathoracic pressure. The idea behind this clinical case image is to edify neurosurgeons, pediatricians, and intensivists to remain wary of such a complication.

## Introduction

Pediatric hydrocephalus manifests in approximately 1 in every 1,000 live births and is speculated to potentially exhibit a higher prevalence in developing countries.<sup>1</sup> Ventriculoperitoneal (VP) shunt is still a mainstay of treatment in many centers, for infants with aqueductal stenosis which is the most common cause of congenital obstructive hydrocephalus.<sup>2</sup> Shunt migration remains a common complication.<sup>3</sup> However, distal tip migration into the thoracic cavity due to negative intrathoracic pressure is a rare occurrence.<sup>4</sup>

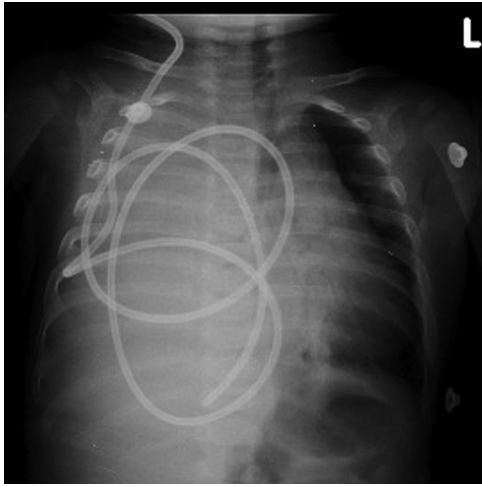
## Case Presentation

We report a 1-year-old infant presenting with drowsy sensorium, increasing head circumference, and bulging anterior fontanelle. The above clinical signs were suggestive of raised intracranial pressure probably due to hydrocephalus which is a common problem in this age group. Magnetic resonance imaging of the brain (→ Fig. 1) revealed gross obstructive hydrocephalus with periventricular seepage due to aqueductal stenosis. Additionally, a large expansile diverticulum of the suprapineal recess extending infratentorially over the dorsal midbrain and cerebellum inferiorly with a compressed 4th ventricle was noted (arrow mark). The child underwent an emergency right-side VP shunt (medium pressure). The cranial end was inserted via a keen point burr hole into the lateral ventricle, with a trajectory toward the frontal horn. On tapping the ventricle, the catheter was connected to a pressure transducer monitor which measured the cerebrospinal fluid (CSF) pressure to be at 9 cm H<sub>2</sub>O, thus justifying the need for a medium pressure shunt. A blunt-tip stainless steel shunt tunneler was used to create a subcutaneous passage from the cranial site into a transverse infraumbilical incision in the right iliac fossa. There were



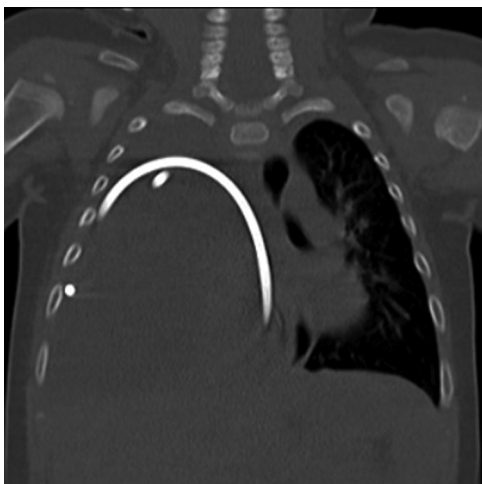**Fig. 1** T2 fluid-attenuated inversion recovery (FLAIR) mid-sagittal section showing significant hydrocephalus, periventricular seepage, and suprapineal recess diverticular extending below the tentorium causing significant compression over the cerebellum and brainstem. Anterior diverticulum from the lamina terminalis and infundibular recess extending to the suprasellar recess. Compressed 4th ventricle (arrow) and aqueductal stenosis.

no intrathoracic pressure changes during the procedure. Visual confirmation of the bowel was done after opening the peritoneum by two operating surgeons prior to inserting the distal catheter. The child's sensorium improved, was feeding well, and was discharged on postoperative day 3. The child presented 3 months later with acute dyspnea and diminished breath sounds on the right hemithorax.

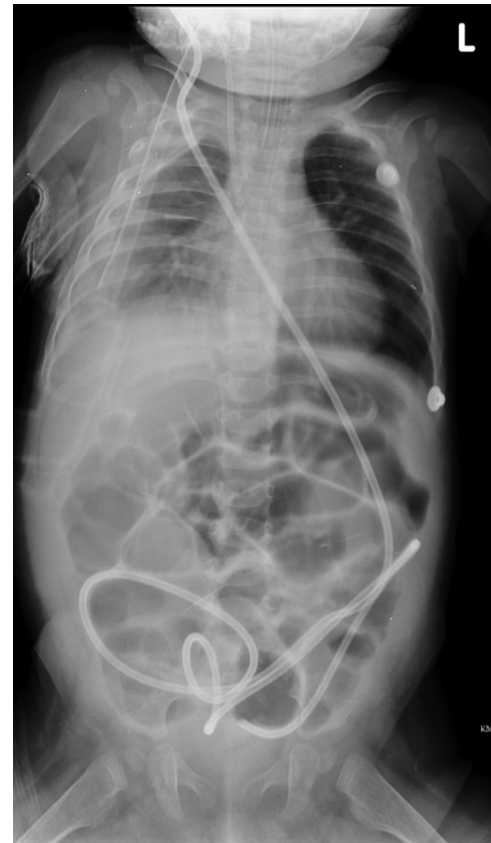

**Fig. 2** Chest roentgenogram showing shunt migration into the pleural space and pleural effusion.

Neurologically, the child was active and anterior fontanelle was lax. A chest roentgenogram (► **Fig. 2**) and computed tomogram (CT) (► **Fig. 3**) of the thorax revealed complete shunt migration into the pleural space with significant pleural effusion on the right side. The distal shunt system on CT appeared to enter the pleural space below the 8th rib, probably indicating that there was subcostal tunneling of the shunt below the 8th rib space during the first surgery which was inconspicuous and subsequently over a span of 3 months due to sucking effect of negative intrathoracic pressure the shunt gradually migrated into the pleural cavity which led to the effusion. An emergency VP shunt revision was performed. The distal end below the chamber was retunneled subcutaneously into a new incision in the left paraumbilical region. Postoperative chest and abdomen roentgenograms showed resolving effusion and accurate shunt placement (► **Fig. 4**). The child required elective ventilation to tide over the underlying collapse of the lung and an intercostal tube drainage for the CSF hydrothorax to aid in weaning. The child was discharged on the 5th postoperative day.



**Fig. 3** Computed tomogram (CT) thorax depicting shunt migration and cerebrospinal fluid (CSF) hydrothorax.



**Fig. 4** Postoperative chest and abdomen roentgenogram after revision of the shunt showing resolving effusion and appropriate shunt repositioning.

## Discussion

CSF hydrothorax after VP shunt surgery can be associated, either with shunt system migration or without shunt system migration.<sup>5-7</sup> Intrapleural migration of VP shunts has been contemplated to be due to trauma during surgery, migration across foramen of Bochdalek or Morgagni, and negative intrathoracic pressure.<sup>8</sup> Thoracic migration of VP shunt can lead to effusion, bronchial perforation, pneumothorax, and pneumonia.<sup>9</sup> Taub and Lavyne have classified thoracic complications of VP shunt as thoracic trauma during shunt tunneling, supradiaphragmatic migration of shunt or transdiaphragmatic migration of shunt, and pleural effusion complicated by CSF ascites.<sup>4</sup> Transdiaphragmatic migration is commonly seen in pediatric population and supradiaphragmatic migration can be seen in any age group.<sup>10</sup> We believe our case to be a type of supradiaphragmatic migration of the shunt, which has occurred slowly over a span of time due to the sucking effect from negative intrathoracic pressure. Pleural effusion as a sequela to intrathoracic migration of VP shunt is due to CSF production-absorption mismatch.<sup>11</sup> What adds to the problem, is the smaller surface area of pleural cavity especially in pediatric patients. Similar cases of shunt migration with delayed presentation, even after many years of surgery, have been reported.<sup>7</sup> Before shunt revision it is prudent to rule out meningitis. If infection is present, a temporary shunt exteriorization may be required until the distal end can be revised. To

prevent inadvertent subcostal tunneling of the shunt, it would be wise to continuously palpate the tip of the tunneler instrument during the procedure. The overarching aim of this clinical case illustration is to edify neurosurgeons, pediatricians, and intensivists to remain wary of such a complication.

## Conclusion

- (1) CSF hydrothorax can be a possibility after a VP shunt in children with delayed postoperative respiratory symptoms.
- (2) It is unlikely to be anatomical defects in the diaphragm through which the shunt has migrated if the complete shunt system and the tip are in the pleural space.
- (3) Inadvertent subcostal shunt tube tunneling may not have immediate manifestations. Clinical symptoms can occur once the shunt migrates into the pleural space due to negative intrathoracic pressure.

**Conflict of Interest**  
None declared.

## References

- 1 Kahle KT, Kulkarni AV, Limbrick DD Jr, Warf BC. Hydrocephalus in children. *Lancet* 2016;387(10020):788–799
- 2 Cinalli G, Spennato P, Nastro A, et al. Hydrocephalus in aqueductal stenosis. *Childs Nerv Syst* 2011;27(10):1621–1642
- 3 Hegde A, Nair RP, Ganapathy S, Kongwad LI. Shunt malfunction in patients with hydrocephalus: complications revisited. *BMJ Case Rep* 2016;2016:bcr2015213619
- 4 Taub E, Lavyne MH. Thoracic complications of ventriculoperitoneal shunts: case report and review of the literature. *Neurosurgery* 1994;34(01):181–183, discussion 183–184
- 5 Adeolu AA, Komolafe EO, Abiodun AA, Adetiloye VA. Symptomatic pleural effusion without intrathoracic migration of ventriculoperitoneal shunt catheter. *Childs Nerv Syst* 2006;22(02):186–188
- 6 Ergün R, Okten AI, Gezercan Y. Hydrothorax: transdiaphragmatic migration of a ventriculoperitoneal shunt catheter. *Pediatr Neurosurg* 2008;44(01):62–64
- 7 Glatstein MM, Roth J, Scolnik D, et al. Late presentation of massive pleural effusion from intrathoracic migration of a ventriculoperitoneal shunt catheter: case report and review of the literature. *Pediatr Emerg Care* 2012;28(02):180–182
- 8 Porcaro F, Procaccini E, Paglietti MG, Schiavino A, Petreschi F, Cutrera R. Pleural effusion from intrathoracic migration of a ventriculo-peritoneal shunt catheter: pediatric case report and review of the literature. *Ital J Pediatr* 2018;44(01):42
- 9 Sahin S, Shaaban AF, Iskandar BJ. Recurrent pneumonia caused by transdiaphragmatic erosion of a ventriculoperitoneal shunt into the lung. Case report. *J Neurosurg* 2007;107(2, suppl):156–158
- 10 Muramatsu H, Koike K. Pleural effusions appearing in the rehabilitation ward after ventriculoperitoneal shunts: a report of two adult cases and a review of the literature. *Brain Inj* 2004;18(08):835–844
- 11 Kiran NAS, Kasliwal MK, Suri A, Mahapatra AK. Intrathoracic migration of ventriculoperitoneal shunt. *Indian J Pediatr* 2010;77(03):335