



## Case Report

# Lacosamide-induced excessive laughing in a patient with Lennox–Gastaut syndrome

Hussein Algahtani <sup>a,\*</sup>, Bader Shirah <sup>b</sup>, Raghad Algahtani <sup>c</sup>

<sup>a</sup> King Abdulaziz Medical City/King Saud bin Abdulaziz University for Health Sciences, Jeddah, Saudi Arabia

<sup>b</sup> King Abdullah International Medical Research Center/King Saud bin Abdulaziz University for Health Sciences, Jeddah, Saudi Arabia

<sup>c</sup> King Saud bin Abdulaziz University for Health Sciences, Jeddah, Saudi Arabia

## ARTICLE INFO

## Article history:

Received 6 December 2017

Received in revised form 18 January 2018

Accepted 27 January 2018

Available online 6 February 2018

## Keywords:

Lacosamide

Excessive laughing

Adverse effect

Drug-induced

## ABSTRACT

Lacosamide is one of the third-generation antiseizure drugs that block voltage-gated sodium channels by enhancing slow inactivation. The most common adverse effects of lacosamide include dizziness, headache, nausea, vomiting, diplopia, fatigue, and sedation. Less common side effects include memory impairment, weight gain, rash, and atrioventricular block. In this article, we describe a patient with Lennox–Gastaut syndrome who developed excessive laughing as a rare side effect of lacosamide with complete resolution after discontinuation of the medication. The present case illustrates that excessive laughing may occur as an adverse effect of lacosamide.

© 2018 The Authors. Published by Elsevier Inc. This is an open access article under the CC BY-NC-ND license (<http://creativecommons.org/licenses/by-nc-nd/4.0/>).

## 1. Introduction

Lacosamide is one of the third-generation antiseizure drugs that block voltage-gated sodium channels by enhancing slow inactivation [1]. It was approved in 2008 and is considered a narrow-spectrum anti-seizure drug against focal seizures [2]. The most common adverse effects of lacosamide include dizziness, headache, nausea, vomiting, diplopia, fatigue, and sedation. Less common side effects include memory impairment, weight gain, rash, and atrioventricular block [3]. In this article, we describe a patient with Lennox–Gastaut syndrome who developed excessive laughing as a rare side effect of lacosamide with complete resolution after discontinuation of the medication. We also review the topic and hypothesize the mechanism behind this rare side effect. In addition, we will review the psychiatric manifestations of this drug and the use of lacosamide in Lennox–Gastaut syndrome.

## 2. Case report

A 22-year-old female had a history of Lennox–Gastaut syndrome since she was four years old. Her seizures were of different types including generalized tonic, clonic, and tonic–clonic seizures. She had frequent falls with multiple traumas to the head and long bones. Her seizures were resistant to treatment despite being on multiple antiseizure drugs including carbamazepine, valproic acid, and topiramate. Seizure

frequency was in the range of 1–2 seizures weekly. She was a product of normal spontaneous vaginal delivery with normal birth weight and absence of birth asphyxia. She had no later brain insult, and her developmental milestones were normal until the age of 5 years when the family noticed a gradual decline in her mental and cognitive abilities. She had a history of admission to the intensive care unit due to status epilepticus two years ago. In an attempt to control her seizures, she was started on lacosamide in gradually increasing doses reaching a total of 200 mg twice daily. Although her seizure-control started to improve, the family noticed excessive laughing, which is usually unprovoked and without mirth. These episodes of laughter had no relationship to seizures (non-ictal phenomenon). The family was embarrassed by such disinhibited behavior and started to limit social interaction and outdoor activities. They asked to stop lacosamide and find an alternative medication or just optimize her previous antiseizure drugs. Lacosamide was gradually tapered off, and other antiseizure drugs doses were adjusted. She returned back to her baseline status two weeks after stopping lacosamide. Her seizure frequency increased, and during a follow-up visit, her family insisted on restarting lacosamide since it controlled her seizures better than other antiseizure drugs. Lacosamide was restarted gradually reaching a total of 200 mg twice daily, and her excessive laughing came back. Psychiatry was consulted who started her on a selective serotonin reuptake inhibitor and atypical antipsychotic with significant improvement. While gelastic seizures may occur in Lennox–Gastaut syndrome, it was not thought that her laughter was a type of ictal phenomenon (not gelastic seizures). Basic hematological workup including complete blood count, liver function test, erythrocyte sedimentation rate, C-reactive protein, syphilis serology, HIV test,

\* Corresponding author at: King Abdulaziz Medical City/King Saud bin Abdulaziz University for Health Sciences, P.O. Box: 12723, Jeddah 21483, Saudi Arabia.

E-mail address: [gahtanih@ngha.med.sa](mailto:gahtanih@ngha.med.sa) (H. Algahtani).

connective tissue screen, and serum quantitative plasma amino acid analysis was unremarkable. Several interictal electroencephalography (EEG) records were abnormal with frequent generalized polyspike wave activities indicating active generalized epilepsy (Fig. 1). Computed tomography scan and magnetic resonance imaging (MRI) of the brain were unremarkable. Her seizure control has improved significantly with reduction of her seizure frequency to be one seizure every 1–2 months. Her laughter persisted, and the family was reassured.

### 3. Discussion

Lennox–Gastaut syndrome is a severe pediatric epileptic encephalopathy characterized by multiple seizure types, specific EEG pattern, and intellectual disability. It usually develops during the first decade of life and is more common in males with a prevalence estimated at 1–2% of all patients with epilepsy. It accounts for up to 10% of all cases of pediatric epilepsy [4]. The etiology could be identified in 65–75% of patients, which includes developmental cortical malformation, neurocutaneous syndrome, post-hypoxic ischemic insult, metabolic encephalopathy, or post-central nervous system infection. In 25% of patients, the syndrome is cryptogenic, and a positive family history of epilepsy was noted in as many as 30% of patients [5]. Typical EEG pattern of Lennox–Gastaut syndrome includes slow background rhythm and a burst of slow spike–wave complexes (less than 3-Hz), which may not be present at seizure onset. These epileptiform discharges are generalized, bilaterally synchronous, and occur intermittently in bursts of varying durations. Focal and multifocal epileptiform discharges are also common. The initial typical EEG changes may eventually disappear with time, particularly with better seizure control [6].

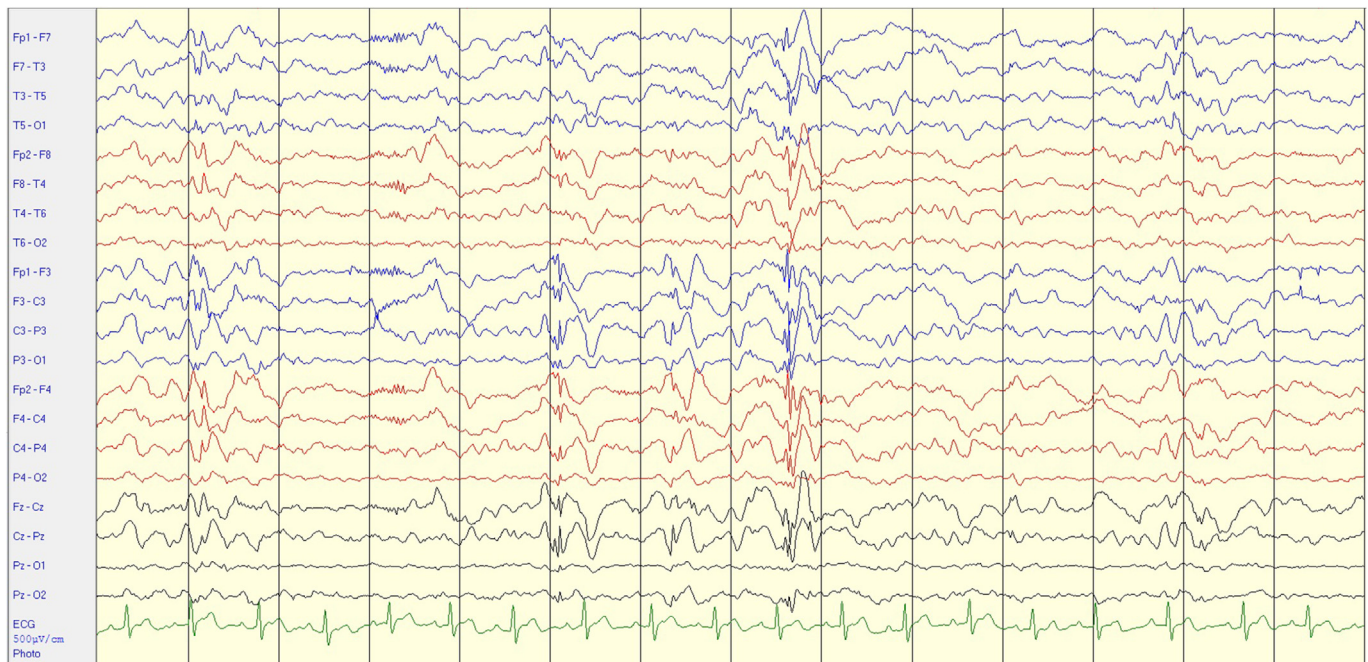
Lacosamide is a modified amino acid that stabilizes the neuronal membrane by slowly inactivating the sodium channels and inhibiting repetitive neuronal firing [7]. Lacosamide half-life is 13 h for young adults and does not have known pharmacokinetic interactions with other antiseizure drugs making it suitable for polytherapy. It has been approved as monotherapy or adjunctive treatment of adults and children with focal (partial-onset) seizures [8]. Lacosamide is a well-tolerated and relatively safe drug with generally mild-to-moderate adverse effects. Adverse effects in adults are dose-related and can be

reversed upon dose reduction or drug discontinuation. Lacosamide has been previously reported in the treatment of patients with Lennox–Gastaut syndrome. Thirty-three percent of treated children achieved a 50% reduction in seizure frequency, 44% experienced no change in seizure frequency, and 17% reported a more than 25% increase in seizure frequency. The increase was noticed in tonic seizures and drop attacks [9]. Therefore, the current evidence is not strong enough to support the use of lacosamide in Lennox–Gastaut syndrome, and further research is needed.

Mental retardation represents 1–3% of the general population with a male to female ratio of 1.5:1. There are more than 250 biological causes of mental retardation with significant direct and indirect economic cost. Psychiatric disorders occur in 40–70% individuals with mental retardation. The psychiatrist who does not specialize in mental retardation and developmental disabilities may lack the basic tools needed for assessment and treatment planning at the interface of mental retardation and psychiatric disorders. This is mainly due to little or no exposure in medical school or residency training of the special diagnostic and therapeutic issues posed by this group of patients. In addition, mental retardation may obscure the standard diagnostic indicators and overshadow symptoms attributable to psychiatric disorder. Patients with mental retardation may not articulate abstract or global concepts such as a depressed mood [10]. As a result, the assessment of mood changes and the diagnosis of mood disorder in patients with Lennox–Gastaut syndrome who have intellectual and cognitive impairment are difficult tasks for the treating physician.

Antiseizure drugs are well-known for their ability to affect the mood and cause psychiatric disturbances. In the pivotal clinical trials for lacosamide, two patients were reported to experience a psychotic disorder. Subsequently, three case reports of lacosamide-induced psychosis have been recently published. In addition, unpublished postmarketing data reported several psychiatric adverse effects including psychosis, agitation, aggression, and hallucinations. It was thought that a combination of antiseizure drugs regimen or abrupt change in the regimen might be responsible for developing psychosis rather than a particular drug [11].

Laughing is a human characteristic and considered an important part of the daily life with a positive effect on well-being. Laughing involves a



**Fig. 1.** Abnormal interictal EEG showing frequent generalized spike wave activity with slow posterior background rhythm maximal in the bifrontocentral areas occurring in trains without any clinical accompaniment.

complex sequence of muscle contractions in the face, pharynx, and diaphragm. Multiple areas of the brain are involved in laughing including the temporal lobe, frontal cortex, periculate premotor areas, cingulate and basal temporal cortex, and the left superior frontal gyrus [12]. Normal laughing is a behavioral response of humans to pleasant feelings and emotions while pathological laughing is not related to the emotional context. Pathological laughing has been reported in a variety of clinical conditions including gelastic seizures and pseudobulbar palsy [13]. In most of these cases, laughing was not related to feelings of joy. A thorough literature review did not yield sufficient reports of drug-induced pathological laughing. Although we cannot prove that the excessive laughing was due to lacosamide, there was a temporal relationship with the start of lacosamide and onset of excessive laughing, which suggests a close association (challenge–rechallenge provocation). We hypothesize that lacosamide may cause excessive laughing due to its anxiolytic effect, which has been proven in animal studies. This hypothesis needs to be further studied in animal models [14].

Gelastical seizures are commonly described in patients who have hypothalamic hamartoma causing precocious puberty. MRI of the brain with a special focus on the hypothalamus, infundibulum, and mammillary bodies usually shows a hamartoma as the cause of gelastic seizures. Focal brain lesions that are associated with gelastic seizures are typically located in the frontal or temporal region. Ictal EEG shows a flattening of cerebral activity, especially if associated with hypothalamic hamartoma [15]. Our patient had a normal MRI of the brain, thus excluding hypothalamic hamartoma. In addition, she did not have features of a gelastic seizure in her EEG during her laughing episodes, thus excluding a gelastic seizure.

#### 4. Conclusion

The present case illustrates that excessive laughing may occur as an adverse effect of lacosamide. Although we cannot prove that the excessive laughing was due to lacosamide, there was a temporal relationship with the start of lacosamide and onset of excessive laughing, which suggests a close association. The prescribing physicians should inform the patients about all potential side effects of lacosamide including excessive laughing. Similar to many undiagnosed conditions, increased awareness of their existence is the key to diagnosis. Early recognition and timely cessation of therapy are important to reverse this effect.

Further studies should be conducted to explore the pathophysiology of this rare side effect.

#### Conflict of interest

The authors declare that they have no conflicts of interest.

This study was approved by the institutional review board (IRB) of King Abdullah International Medical Research Center (KAIMRC).

#### References

- [1] Baulac M, Rosenow F, Toledo M, Terada K, Li T, De Backer M, et al. Efficacy, safety, and tolerability of lacosamide monotherapy versus controlled-release carbamazepine in patients with newly diagnosed epilepsy: a phase 3, randomised, double-blind, non-inferiority trial. *Lancet Neurol* 2017;16(1):43–54.
- [2] Halász P, Kälviäinen R, Mazurkiewicz-Beldzińska M, Rosenow F, Doty P, Hebert D, et al. Adjunctive lacosamide for partial-onset seizures: efficacy and safety results from a randomized controlled trial. *Epilepsia* 2009;50(3):443–53.
- [3] Weston J, Shukralla A, Mckay AJ, Marson AG. Lacosamide add-on therapy for partial epilepsy. *Cochrane Database Syst Rev* 2015(6):CD008841.
- [4] Cross JH, Auvin S, Falip M, Striano P, Arzimanoglou A. Expert opinion on the management of Lennox–Gastaut syndrome: treatment algorithms and practical considerations. *Front Neurol* 2017;8:505.
- [5] Al-banji MH, Zahr DK, Jan MM. Lennox–Gastaut syndrome. Management update. *Neurosciences (Riyadh)* 2015;20(3):207–12.
- [6] Bourgeois BF, Douglass LM, Sankar R. Lennox–Gastaut syndrome: a consensus approach to differential diagnosis. *Epilepsia* 2014(55 Suppl):4:4–9.
- [7] Giráldez BG, Toledano R, García-Morales I, Gil-Nagel A, López-González FJ, Tortosa D, et al. Long-term efficacy and safety of lacosamide monotherapy in the treatment of partial-onset seizures: a multicenter evaluation. *Seizure* 2015;29:119–22.
- [8] Mcginty RN, Costello DJ. Long-term lacosamide retention-Real-world experience at a tertiary epilepsy center in Ireland. *Epilepsy Behav* 2017;68:141–5.
- [9] Grosso S, Balestri P. Efficacy and tolerability of add-on lacosamide in children with Lennox–Gastaut syndrome. *Acta Neurol Scand* 2014;130(2):e39–0.
- [10] Ryan R, Sunada K. Medical evaluation of persons with mental retardation referred for psychiatric assessment. *Gen Hosp Psychiatry* 1997;19(4):274–80.
- [11] Pinkhasov A, Lam T, Hayes D, Friedman M, Singh D, Cohen H. Lacosamide induced psychosis: case report, review of differential diagnosis and relevant pharmacokinetics. *Clin Neuropharmacol* 2015;38(5):198–200.
- [12] Mainali NR, Jalota L, Aryal MR, Schmidt TR, Badal M, Alweis R. Laugh-induced seizure: a case report. *J Med Case Reports* 2013;7:123.
- [13] Arroyo S, Lesser RP, Gordon B, Uematsu S, Hart J, Schwerdt P, et al. Mirth, laughter and gelastic seizures. *Brain* 1993;116(Pt 4):757–80.
- [14] Higgins GA, Breyse N, Undzys E, Kuo C, Joharchi N, Derksen DR, et al. The anti-epileptic drug lacosamide (Vimpat) has anxiolytic property in rodents. *Eur J Pharmacol* 2009;624(1–3):1–9.
- [15] Striano S, Santulli L, Iannicello M, Ferretti M, Romanelli P, Striano P. The gelastic seizures–hypothalamic hamartoma syndrome: facts, hypotheses, and perspectives. *Epilepsy Behav* 2012;24(1):7–13.