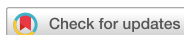

Review Article
Neuroscience



Magnetic Resonance-Guided Focused Ultrasound in Neurosurgery: Taking Lessons from the Past to Inform the Future

Na Young Jung and Jin Woo Chang

Department of Neurosurgery, Brain Research Institute, Yonsei University College of Medicine, Seoul, Korea



Received: Jul 1, 2018
Accepted: Sep 13, 2018

Address for Correspondence:

Jin Woo Chang, MD, PhD

Department of Neurosurgery, Brain Research Institute, Yonsei University College of Medicine, 50 Yonsei-ro, Seodaemun-gu, Seoul 03722, Korea.
E-mail: JCHANG@yuhs.ac

© 2018 The Korean Academy of Medical Sciences.

This is an Open Access article distributed under the terms of the Creative Commons Attribution Non-Commercial License (<https://creativecommons.org/licenses/by-nc/4.0/>) which permits unrestricted non-commercial use, distribution, and reproduction in any medium, provided the original work is properly cited.

ORCID iDs

Na Young Jung
<https://orcid.org/0000-0001-9996-1378>
Jin Woo Chang
<https://orcid.org/0000-0002-2717-0101>

Funding

This work was supported by funding from the Michael J. Fox Foundation (New York, NY, USA) in 2013 and the Focused Ultrasound Foundation (Charlottesville, VA, USA) in 2011.

Disclosure

The authors have no potential conflicts of interest to disclose.

ABSTRACT

Magnetic resonance-guided focused ultrasound (MRgFUS) is a new emerging neurosurgical procedure applied in a wide range of clinical fields. It can generate high-intensity energy at the focal zone in deep body areas without requiring incision of soft tissues. Although the effectiveness of the focused ultrasound technique had not been recognized because of the skull being a main barrier in the transmission of acoustic energy, the development of hemispheric distribution of ultrasound transducer phased arrays has solved this issue and enabled the performance of true transcranial procedures. Advanced imaging technologies such as magnetic resonance thermometry could enhance the safety of MRgFUS. The current clinical applications of MRgFUS in neurosurgery involve stereotactic ablative treatments for patients with essential tremor, Parkinson's disease, obsessive-compulsive disorder, major depressive disorder, or neuropathic pain. Other potential treatment candidates being examined in ongoing clinical trials include brain tumors, Alzheimer's disease, and epilepsy, based on MRgFUS abilities of thermal ablation and opening the blood-brain barrier. With the development of ultrasound technology to overcome the limitations, MRgFUS is gradually expanding the therapeutic field for intractable neurological disorders and serving as a trail for a promising future in noninvasive and safe neurosurgical care.

Keywords: High-Intensity Focused Ultrasound Ablation; Magnetic Resonance Imaging; Ablation; Neurological Disorder; Neurosurgical Procedure

INTRODUCTION

Ultrasound is widely known as a diagnostic or monitoring modality in the medical fields. In recent years, however, many investigators have concentrated on the potential role of acoustic energy in viable tissues and have been conducting research to investigate its therapeutic use. Ultrasound can generate high-intensity energy when focused at focal areas. This focused ultrasound (FUS) can produce discrete lesions in deep tissues of the body, even in the brain, with minimal effects on tissues near the target point. Since it was first realized that ultrasound could be focused when placed on a concave surface of generator in 1935, studies on clinical applications of ultrasound have been making a great progress.¹ In the 1940s, John Lynn and his colleagues were able to create ablative lesions in the bovine liver using intensely-

Author Contributions

Conceptualization: Chang JW. Formal analysis: Chang JW, Jung NY. Methodology: Jung NY. Investigation: Jung NY. Writing - original draft: Jung NY. Writing - review & editing: Chang JW.

focused ultrasound, and they later succeeded in applying similar techniques in animal brain tissues.^{2,3} Fry et al.^{4,5} first developed a FUS device to produce accurate lesions without damaging surrounding tissues. FUS has become more sophisticated with the stereotactic surgical technique, and has begun to be applied to clinical practices including psychiatric disorders or intractable pain.^{6,7}

Unfortunately, techniques were lacking to overcome the skull issues as a main obstacle of ultrasound energy delivery before the 1980s; consequently, opening the cranium was inevitable. In the 1990s, however, the accuracy and transmission efficiency of FUS markedly improved with the development of imaging techniques and ultrasonic technologies. In particular, multiple phased-array techniques of ultrasound transduction enabled the realization of non-invasive neurosurgery by transcranial sonication of deep brain tissue.^{8,9} Magnetic resonance (MR) thermometry is another key factor enabling the verification of the target location and real-time monitoring during the whole treatment procedure using FUS.¹⁰ These advancements have led FUS to become a promising technique in ablative procedures in terms of non-invasiveness and safety. Clinically, FUS has been applied to the thermal ablation of body masses, such as uterine fibroids, leiomyomas, other malignancies including breast cancers, prostate cancer, and bone metastasis.¹¹⁻¹³ Recently, transcranial MR-guided FUS (MRgFUS) has been used as a new surgical method applied to various neurological disorders, and useful outcomes are increasingly being reported. Thalamotomy with MRgFUS for intractable essential tremor (ET) was first approved by the United States Food and Drug Administration (FDA) in 2016. Treatments with MRgFUS for Parkinson's disease (PD), obsessive-compulsive disorder (OCD), major depressive disorder (MDD), and neuropathic pain have obtained international approval in several countries. The experimental and clinical applications of FUS are still being investigated. The object of this review is to confirm the current status of MRgFUS in neurosurgical field and to search for future direction.

PHYSICS OF FOCUSED ULTRASOUND

Ultrasound is a mechanical wave that occurs through a medium and propagates at frequencies higher than the range of human hearing of 20 Hz.¹⁴ Basically, when ultrasound passes through a specific area, reflection and refraction occur at the boundary between two media with different acoustic impedances.^{15,16} Specular reflection, which occurs when the acoustic rays contact a relatively smooth surface, usually contributes to delineate the interface between two soft tissues; therefore, displaying organ boundaries that could be used as diagnostic images.^{15,17} Another characteristic of ultrasound is attenuation by absorption and scattering of acoustic energy. The absorption of acoustic energy into a specific area can generate heat energy, leading to protein denaturation and coagulation and cell necrosis, and thus resulting in tissue ablation.¹⁸⁻²⁰ Moreover, ultrasound mechanical forces can cause formation and oscillation of microbubbles, known as cavitation, and create direct mechanical damage to tissue due to its high pressure and shear forces.^{6,21}

Since Gruetzmacher¹ first designed a curved quartz plate, which could concentrate ultrasound beams at a specific point in 1935, FUS technology has developed markedly. In particular, development of phased array transducers with hundreds of piezoelectric transducers has led to FUS becoming more efficient in passing through difficult obstacles with tissue heterogeneities, such as bone tissue, and effective in focusing multiple points to

Table 1. Clinical indications and their current state for ablation using MRgFUS

Current state	Indications (target)
Approved (by specific countries)	ET Thalamotomy (Vim) PD Thalamotomy (Vim) Obsessive compulsive disorder Capsulotomy (ALIC) Neuropathic pain Thalamotomy (CL)
Ongoing clinical trials	PD Pallidotomy (GP): NCT02003248, NCT02347254, NCT02263885 Subthalamotomy (STN): NCT02912871, NCT02246374 MDD Capsulotomy (ALIC): NCT03421574, NCT02348411 Brain tumor Ablation: NCT01473485, NCT00147056, NCT01698437, NCT03028246 BBB opening: NCT02343991 AD BBB opening: NCT02986932 Epilepsy Ablation of epileptic foci: NCT02804230 Thalamotomy (AN): NCT03417297 Neuromodulation: NCT02151175 Amyotrophic lateral sclerosis BBB opening: NCT03321487

MRgFUS = magnetic resonance-guided focused ultrasound, ET = essential tremor, Vim = ventro-intermediate nucleus of thalamus, PD = Parkinson's disease, ALIC = anterior limb of internal capsule, CL = centro-lateral nucleus of thalamus, GP = globus pallidus, STN = subthalamic nucleus, MDD = major depressive disorder, BBB = blood-brain barrier, AD = Alzheimer's disease, AN = anterior nucleus of thalamus.

increase therapeutic volume.^{9,21,22} Clinicians can modulate the parameters of sonication in recent systems, including the intensity of acoustic energy and frequency and sonication time depending on the purpose of treatment and characteristics of the subject.

As mentioned above, the thermal and mechanical effects of ultrasound could provide the basis for the therapeutic use of ultrasound in clinical fields (Table 1). Stereotactic ablative surgery is presently a main clinical application of the MRgFUS procedure, which complements the conventional, invasive thermal therapy using radiofrequency (RF) ablation. In addition, cavitation effects under specific sonication parameters can open the blood-brain barrier (BBB) in a selective and reversible manner. Ultrasound-mediated BBB opening is actively explored in the fields of drug delivery into the brain and neuromodulation.²³⁻²⁵

PROCEDURE

Conventionally, clinical MRgFUS lesioning is performed in 3-T MR imaging (MRI) scanners using devices such as the Exablate 4000 device (InSightec, Tirat Carmel, Israel) (Fig. 1A). This system consists of multiple-phased array transducers with 1,024 ultrasonic elements. The entire scalp is completely shaved to prevent scalp burning by absorbed high energy from the ultrasound. A stereotactic frame (Cosman-Roberts-Wells stereotactic frame, Radionics, Burlington, MA, USA) is then fixed on the patient's head under local anesthesia. A flexible silicone membrane with a central hole is applied to the patient's head to seal the space between the head and the transducer. This space contains cool, degassed water (15°C–20°C) to reduce heating of the scalp. The patient's head on frame are attached to

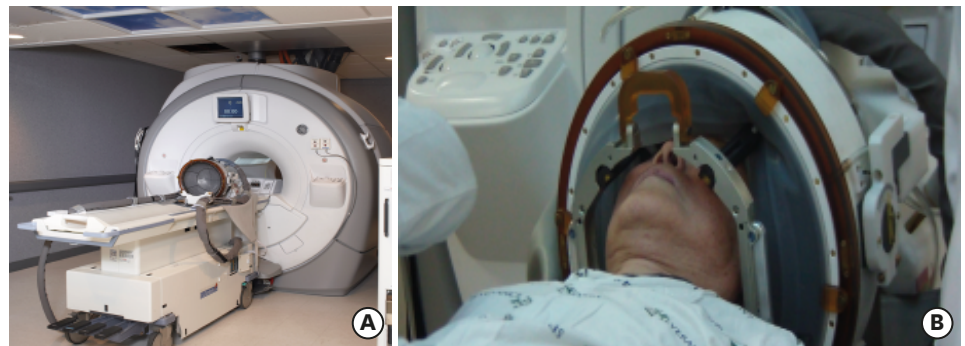


Fig. 1. MRgFUS system for brain surgery. The main device is the Exablate 4000 device (InSightec, Tirat Carmel, Israel) in combination with 3-T MRI scanner (A). The head of the patient is fixed to a stereotactic frame and assembled with a MRI machine (B). MRgFUS = magnetic resonance-guided focused ultrasound, MRI = MR imaging.

the spherical transducer, which again connects with the MRI machine (Fig. 1B). Prior to sonication, a series of standard diagnostic MRI scans are obtained to set the target point and its stereotactic coordinates. After planning the target, subthreshold, low-power sonication is applied several times for 10–20 seconds to reach a peak temperature between 40°C and 42°C. This process is necessary to confirm the accurate location of the target. It also allows practitioners to determine suitable sonication parameters to produce permanent lesions. High-power sonication is then delivered to the target area under the guidance of MRI and MR thermometry. Acoustic power and energy are steadily increased until target temperatures reaching over 54°C. The patient is neurologically evaluated to assess the therapeutic effect and side effects during the cooling time right after each sonication. The whole procedure is performed without general anesthesia and the patient remains awake and responsive. The process of whole procedure is briefly depicted Fig. 2.

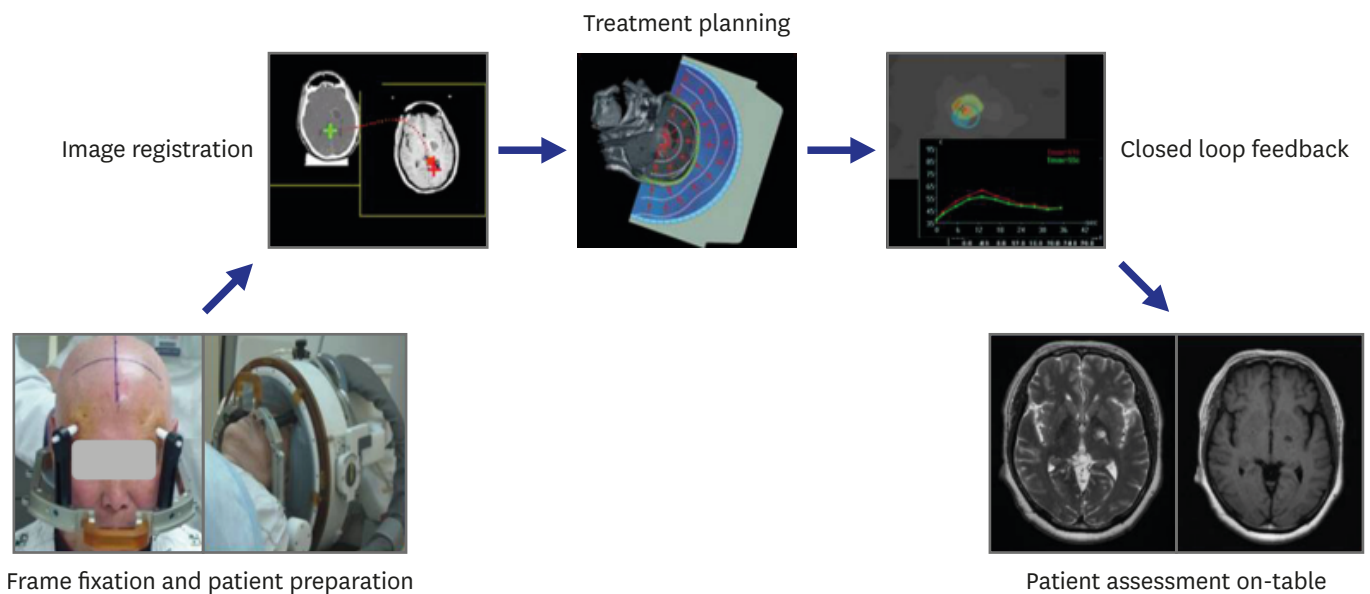


Fig. 2. Flow chart of procedure using MRgFUS ablation. MRgFUS = magnetic resonance-guided focused ultrasound.

CLINICAL APPLICATIONS

ET

ET is one of the most common movement disorders, involving involuntary, rhythmic shaking affecting mostly the hands, and sometimes the head or other part of the body. Its prevalence is approximately 4% and half of patients with ET require surgical treatment due to medically-refractory state.²⁶ Surgical treatment options involve RF ablation or deep brain stimulation (DBS), mainly targeting to the ventral intermediate (Vim) nucleus of the thalamus or posterior subthalamic area (Fig. 3A). These areas reportedly belong to the motor circuitry, which connects the cerebellum and cortex, and is historically associated with tremors.^{27,28} Since several pilot studies have shown the potential efficacy and safety of this new surgical approach for ET, the clinical outcomes of MRgFUS thalamotomy have been accumulating. Patients treated in this manner commonly present with favorable reduction in tremor scores after treatment in the early phase and much improved functions of daily living or quality of life.²⁹⁻³¹ Reported side effects included dizziness, nausea or vomiting, ataxia, and paresthesia, but no fatalities have been reported.²⁹⁻³¹ In 2016, a randomized, multicenter trial showed that hand tremor scores improved from 18.1 points at baseline to 9.6 at 3 months in a MRgFUS thalamotomy group compared with a sham group.³² They also found that the treatment effect was maintained at 12 months with an acceptable rate of side effects. These achievements validated the effectiveness and safety of MRgFUS thalamotomy and led to the procedure obtaining official approval, and to date, ET is the only FDA-approved neurological indication for transcranial MRgFUS ablation. Recently, a meta-analysis reported favorable outcome after MRgFUS lesioning for ET. The percentage improvements in the Clinical Rating Scale for Tremor (CRST) were 62.2%, 62.4%, and 69.1% for CRST total, part A, and part C, respectively.³³ The Quality of Life in Essential Tremor score was also improved by 46.5%.³³ In addition, long-term effectiveness was evaluated in a prospective study, which showed that the tremor and disability scores were sustained at the 2-year follow up.³⁴ This treatment combines more advanced imaging technology, such as tractography, and confirms the possibility of continuous development toward better accuracy and safety.^{35,36}

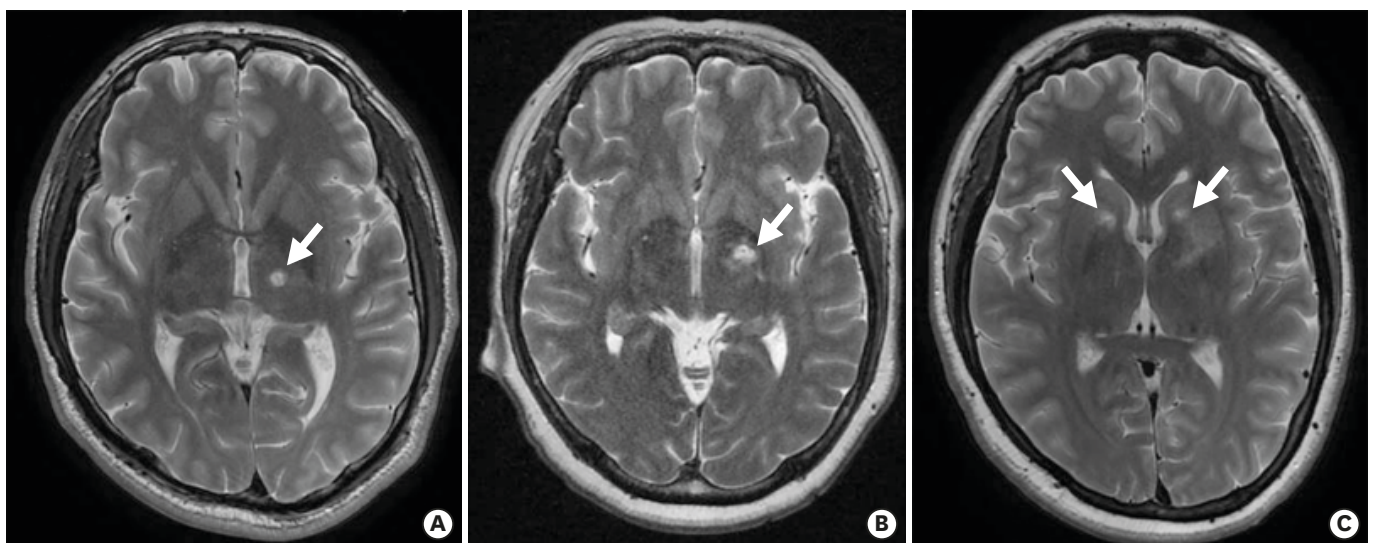


Fig. 3. Brain magnetic resonance images after the ablation procedure using MRgFUS. Well-defined small lesions are identified (white arrows) on T2 weighted imaging after unilateral thalamotomy for ET (A), unilateral pallidotomy for PD (B), bilateral capsulotomy for psychological disease (C). MRgFUS = magnetic resonance-guided focused ultrasound, ET = essential tremor, PD = Parkinson's disease.

PD

PD is a complex movement disorder, involving the clinical triad of akinesia/bradykinesia, resting tremors, and muscular rigidity. PD is deeply related to the disruption of the motor circuitry because the symptoms of PD result from progressive loss of innervation of dopaminergic neurons in the motor area of the basal ganglia. Conventional surgical treatments of PD have targeted specific areas of the motor circuit associated with the patient's main symptoms. Common targets for both DBS and lesioning procedures include the subthalamic nucleus, globus pallidus interna (GPI), and Vim among others.³⁷⁻³⁹ These areas are also being explored as potential targets for MRgFUS procedures for PD.

Magara et al.⁴⁰ demonstrated the feasibility and safety of the MRgFUS pallidothalamic tractotomy (PTT) for patients with medically-resistant PD. They applied repetitive sonication to 9 of 13 included patients, achieving final temperatures for appropriate lesions. These nine patients experienced a mean reduction of 60.9% in the Unified Parkinson's Disease Rating Scale (UPDRS) score and 56.7% improvement in global symptom relief at the 3 months follow-up after MRgFUS PTT.⁴⁰ Tremor-dominant PD is a good indication of MRgFUS thalamotomy, which has been validated in several clinical trials.⁴¹ Bond et al.⁴¹ showed differences in clinical outcome between patients with PD who underwent unilateral MRgFUS thalamotomy and a sham procedure. They found that the median tremor scores of 20 patients improved by 62% from baseline and the median UPDRS motor scores of the on-medication state also improved by 8 points from baseline after MRgFUS thalamotomy, which was much better than the outcome of the sham procedure.⁴¹ Recently, the preliminary efficacy of unilateral subthalamotomy using MRgFUS was reported by an open-label pilot study, which found that the mean UPDRS part III scores in the treated hemibody improved by 53% from baseline to 6 months in the off-medication state and by 47% in the on-medication state.⁴² The GPI is another important functional target for surgical treatment in patients with PD, mainly targeting dyskinesia (**Fig. 3B**). Clinical studies exploring the feasibility and safety of unilateral MRgFUS pallidotomy for Parkinsonian dyskinesia are ongoing. The 1-year follow-up results of a study conducted by our group (NCT02003248) have been recently accepted and will shortly be published.

Although it is at the experimental stage, the possibility of drug or gene delivery using BBB opening by FUS is also being continuously studied.⁴³⁻⁴⁵ This potential of MRgFUS raises expectations for future treatments for intractable neurodegenerative disorders.

Neuropsychological disorders

OCD, Tourette syndrome, and MDD are traditional neurosurgical indications that have been previously treated via lesioning procedures or DBS. These disorders reportedly result from abnormal neural circuits involving limbic areas. There are various targets for ablation, including the anterior limb of the internal capsule (**Fig. 3C**), anterior cingulate cortex, subgenual cingulate cortex, and ventral striatum.⁴⁶⁻⁴⁸ Firstly, Jung et al.⁴⁹ attempted to perform bilateral capsulotomy via MRgFUS in patients with medically-refractory OCD and they reported a marked improvement over the 6 months follow-up in the Yale-Brown Obsessive-Compulsive Scale (YBOCS) of 33%. They also identified immediate and sustained improvements in the Hamilton Depression Rating Scale (HAM-D) with a mean reduction of 61.1% and the Hamilton Anxiety Rating Scale (HAM-A) with a mean reduction of 69.4%. The treatment-related adverse events were minimal.⁴⁹ The long-term outcome over 2 years in the same group reaffirmed the efficacy of MRgFUS capsulotomy to manage obsessive, compulsive, depressive, and anxiety symptoms in patients with OCD.⁵⁰ The scores of the

YBOCS, HAM-D, and HAM-A decreased significantly across the 2-year follow-up period and the functioning scores improved without neuropsychological changes.⁵⁰ Bilateral capsulotomy using MRgFUS has been applied to MDD based on the improvement of depression scores in previous OCD results. Kim et al.⁵¹ first reported a case of a 56-year-old woman with MDD who underwent MRgFUS capsulotomy, resulting in considerably decreased scores in the HAM-D, and Beck's Depression Inventory Scores from baseline to the 1-year follow-up. A clinical trial on bilateral anterior capsulotomy for MDD has recently been completed and the results are pending announcement. Regarding neuromodulation, FUS-induced BBB opening may increase brain-derived neurotrophic factor levels, drug delivery, and hippocampal neurogenesis that can result in new modes of anti-depressive treatment.⁵²

Chronic pain

Chronic neuropathic pain poses a challenge for modern medicine. It is difficult to manage with simple approaches because of numerous different symptomatic presentations, various affecting areas, and heterogenous mechanisms. Although the medical treatments including sodium-channel blockers and anticonvulsants are the mainstay for alleviating chronic pain, interventional nerve blocks and physical therapy could be useful to reduce severe pain.^{53,54} Further, surgical treatments can be applied and specific options are selected based on the body area and cause of pain, including the cortex, cingulum, thalamus, spinal cord, and spinal nerves. In particular, the medial thalamus has been targeted by a variety of surgical modalities as the main relay station of the somatosensory pathway. Medial thalamotomy via RF ablation or radiosurgery and thalamic DBS have proven their effectiveness of pain control in patients with intractable pain.⁵⁵⁻⁵⁷ Jeanmonod et al.⁵⁸ demonstrated that patients with chronic neuropathic pain experienced a mean pain relief of 49% at the 3-months follow up and 57% at the 1-year follow up after central lateral thalamotomy via non-invasive treatment using MRgFUS. They have tried MRgFUS ablation in heterogenous pain patterns and causes from brain lesions to spinal cord injury or peripheral nerve problems.⁵⁸ Some countries have been officially approved MRgFUS ablation for chronic pain, and the United States is currently recruiting participants with uncontrolled chronic pain who are willing to undergo MRgFUS ablation in a phase I clinical trial (NCT03111277). Large-scaled clinical outcomes of MRgFUS thalamotomy for pain will be available in the near future.

Brain tumors and drug delivery

The therapeutic abilities of MRgFUS confined to focal regions have led to a breakthrough in the treatment of brain tumors because MRgFUS can limit treatment-related toxicity to normal brain tissue. Brain tumor management using MRgFUS techniques is classified into two different ways. One is the thermal ablation effect on tumor tissue using focused ultrasonic energy and the other is the ability to open the tight junctions of the BBB and to deliver the therapeutic agent more effectively to the target brain region.

MRgFUS enables the eradication of target cells noninvasively and safely with minimal injury to the adjacent normal area. Although resection is the main treatment for brain tumors for the purposes of histopathologic confirmation and cytoreduction, some cases are ineligible for open surgery. Currently, the standard option for surgically inaccessible lesions is radiosurgery or radiotherapy. These therapies have risks of complications, such as radiation necrosis or leukoencephalopathy due to radiation toxicity to viable tissue.^{59,60} Laser interstitial thermotherapy (LiTT) is one of the emerging options for tumor ablation and its effects have been shown in patients with recurrent glioblastoma and metastatic brain tumors, but its complication rate is still relatively high and it is an unsuitable option in cases with

nearby great vessels or hemorrhage.^{61,62} To date, several studies have reported successful cases of applying MRgFUS to achieve tumor ablation in a small number of patients with glioblastoma.^{20,63} A clinical trial using MRgFUS to target brain tumors (NCT01473485) has recently been completed and the results will be available soon. As is already clinically used as an available treatments, either primary or palliative, for body cancers, MRgFUS should be accompanied by studies that will determine the survival benefit and ways of improving the technical efficiency of using ultrasonic energy.

Historically, the goal of chemotherapy for brain tumors was to deliver the most effective agents to tumor cells passing through the BBB. Many attempts have made to enhance the efficiency of drug delivery, including receptor modifying nanoparticles, intranasal injections, and chemo-agent wafers (Bis-chloroethylnitrosourea wafers).⁶⁴⁻⁶⁶ However, all these methods carry risks of iatrogenic damage and significant toxicity by the drugs to normal brain tissues. BBB opening using MRgFUS has advantages over the existing methods. MRgFUS can disrupt the tight junctions of the BBB transiently for up to 24 hours by oscillation of microbubbles, known as stable cavitation, then it can restore the BBB to its previous state.⁶⁷⁻⁷⁰ When the range of sonication is defined under MRI guidance, MRgFUS can accurately increase the drug concentration within a specific volume of brain tumor while preserving normal brain tissues or other systemic organs.^{70,71} In animal experiments, the intravenous methotrexate concentration in the brain of healthy rabbits was 13 times higher with MRgFUS than without MRgFUS.⁷² In glioma rabbit models, the doxorubicin concentration was 14 times higher after 24 hours when MRgFUS-induced BBB opening was added.⁷³ Improved drug delivery using MRgFUS also has benefits for increasing median survival time over no treatment.⁶⁴ Regardless of these promising results from preclinical studies, clinical trials on human brain tumors remained to be conducted. The only relevant study in humans is a phase I clinical trial, which used MRgFUS to open the BBB in the frontal cortex in patients with Alzheimer's disease (AD) (NCT02986932). The results are yet to be reported. Another clinical trial on BBB opening in human glioblastoma is in the process of preparation and will be recruit patients with glioblastoma this year.

Other emerging indications

In addition to the previously mentioned diseases, there are many applicable disease entities and they are being tried in real clinical practice based on the satisfactory results of basic experiments.

Stroke is one of the most significant causes of long-term morbidity and mortality worldwide.^{74,75} Large-vessel occlusion is the main cause of acute ischemic stroke and is typically treated with endovascular mechanical thrombectomy or thrombolytic agents⁷⁶⁻⁷⁸; some patients are eligible for more invasive open surgeries, such as craniotomy or decompressive craniectomy.^{79,80} The concept of sonothrombolysis using MRgFUS has been applied as an alternative or neoadjuvant therapy for patients with stroke who cannot benefit from conventional therapies. This therapy is performed based on the piezoelectric effect, which generates acoustic waves to induce inertial cavitation, consequently leading to clot disintegration.⁸¹⁻⁸⁵ Several in vitro models have attempted to determine the optimal sonication parameters for effective thrombolysis and minimal injury to adjacent structures and they achieved a 58%–95% of recanalization rate using animal clots and a 10%–42% of thrombolysis rate using human clots under conditions of pulsed sonication.⁸⁶⁻⁸⁸ In addition, Harnof et al.⁸⁹ and Monteith et al.⁹⁰ reported clot liquefaction achieved with/without temperature increase in surrounding tissues in in-vivo experiments.

Epilepsy is another potential field of MRgFUS surgery application. Approximately 20%–40% of patients with epilepsy do not respond to antiepileptic drugs and they need surgical interventions. Except for neuromodulation, the most frequently employed surgical options for epilepsy are lobectomy or focal lesionectomy, which require invasive procedures. Numerous studies have explored minimal invasive approaches, such as stereotactic radiosurgery or LiTT. However, stereotactic radiosurgery has hazards related to ionizing radiation and the long latency of the therapeutic effect, and LiTT cannot be performed without scalp incision or trephination.⁹¹⁻⁹⁴ MRgFUS ablation can provide more noninvasive tissue destruction using high ultrasonic energy through the intact skull. Now, a phase I clinical trial (NCT02804230) is underway to determine the feasibility and safety of MRgFUS ablation for epilepsy related to subcortical, visible pathologies including hypothalamic hamartomas and tuberous sclerosis. Apart from its ablation effects, MRgFUS can be utilized to decrease cortical excitability and suppress epileptogenic discharges because the mechanical effects of acoustic waves can change the cellular membrane properties. A trial aiming to investigate the neuromodulatory effect of low-frequency FUS is ongoing (NCT02151175).

DISCUSSION

MRgFUS is undoubtedly an effective treatment modality; however, there are still limitations to overcome. First, the need to penetrate the skull is a main barrier to the energy transfer efficiency of MRgFUS. Ultrasound has its own characteristics of reflection and refraction that occur at the boundary between two media with different acoustic impedances.^{17,95} The human skull is a complex medium composed of heterogenous and viscoelastic structures. In the process of ultrasound transmission through the skull, there is unwanted energy loss and attenuation. Actually, several studies have shown that some of the included cases failed to achieve lesioning via MRgFUS because sufficient temperature rise was not obtained. Elias et al.³² found that 5 of 76 patients did not achieve sufficient energy delivery during MRgFUS thalamotomy for their ET. Chang et al.³⁰ also reported three of 11 patients where lesioning failed due to insufficient temperature into the thalamic target for ET management. Jeanmonod et al.⁵⁸ reported that they succeeded in delivering ultrasonic energy through the skull only 9 of 11 patients with medication-intractable neuropathic pain. The skull density ratio (SDR), i.e., the ratio of the Hounsfield unit value on brain computed tomography between the marrow layer and cortical layer is a known important factor because higher SDR (> 0.45) could be associated with lower energy requirement for generating temperature rise at the target tissue.⁹⁶ Yet, there is no formal cut off value of SDR for the MRgFUS procedure; further studies are needed to explore the valid reference value to select suitable patients. In addition, each sonication transducer in the spherical helmet has an incident angle when ultrasound beams heat the skull, and then part of them is refracted due to non-spherical skull calvaria. This possibly obstructs penetration of ultrasonic energy especially in cases of superficial targets or more lateral targets.⁹⁷⁻⁹⁹

Another clinical obstacle is that MRgFUS is usually performed with only empirical parameters of sonication. In terms of frequency of sonication, high-frequency, over 650 kHz, has the advantages of accurate focusing and consequent safety, but is more rapidly attenuated by the skull than low-frequency ultrasound.^{86,100} On the contrary, low-frequency ultrasound has less energy attenuation, but also less focusing ability, resulting in potential risk of damaging surrounding tissues.^{86,100-102} Although the MRgFUS technique is still

evolving, more efforts are required to understand the basic principles of ultrasound and to increase the efficiency of the current technology, as well as to expand the clinical indications of application of this novel treatment.

MRgFUS is an important first step for the ideal neurosurgery for neurological disorders due to its noninvasive nature and safety. Moreover, this new approach has potential beyond ablation and could be applied to a wide range of clinical fields, including brain tumor, AD, epilepsy, stroke, etc. Although there are still technical limitations, MRgFUS is expected to become a new future in neurosurgical treatment because numerous clinical and preclinical studies have shown the feasibility of MRgFUS and several studies are still ongoing. In the near future, if larger scaled data including from phase II and III trials are confirmatory of its efficacy, MRgFUS can open a new chapter in breakthrough treatments for intractable neurological diseases.

ACKNOWLEDGMENTS

The authors would like to thank Ms. Eun Jeong Kweon, RN, and Sang Keum Pak, RN, for providing clinical assistance.

NOTE

This article is an invited review for Prof. Jin Woo Chang as the laureate of the 14th Bayer Prize in Clinical Medicine, 2018.

REFERENCES

1. Gruetzmacher J. Piezoelektrischer kristall mit ultraschallkonvergenz. *Z Phys* 1935;96(5-6):342-9.
[CROSSREF](#)
2. Lynn JG, Putnam TJ. Histology of cerebral lesions produced by focused ultrasound. *Am J Pathol* 1944;20(3):637-49.
[PUBMED](#)
3. Lynn JG, Zwemer RL, Chick AJ, Miller AE. A new method for the generation and use of focused ultrasound in experimental Biology. *J Gen Physiol* 1942;26(2):179-93.
[PUBMED](#) | [CROSSREF](#)
4. Fry WJ, Barnard JW, Fry EJ, Krumins RF, Brennan JF. Ultrasonic lesions in the mammalian central nervous system. *Science* 1955;122(3168):517-8.
[PUBMED](#) | [CROSSREF](#)
5. Fry WJ, Mosberg WH Jr, Barnard JW, Fry FJ. Production of focal destructive lesions in the central nervous system with ultrasound. *J Neurosurg* 1954;11(5):471-8.
[PUBMED](#) | [CROSSREF](#)
6. Jagannathan J, Sanghvi NT, Crum LA, Yen CP, Medel R, Dumont AS, et al. High-intensity focused ultrasound surgery of the brain: part 1--A historical perspective with modern applications. *Neurosurgery* 2009;64(2):201-10.
[PUBMED](#) | [CROSSREF](#)
7. Lindstrom PA. Prefrontal ultrasonic irradiation-a substitute for lobotomy. *AMA Arch Neurol Psychiatry* 1954;72(4):399-425.
[PUBMED](#) | [CROSSREF](#)
8. Guthkelch AN, Carter LP, Cassady JR, Hynynen KH, Iacono RP, Johnson PC, et al. Treatment of malignant brain tumors with focused ultrasound hyperthermia and radiation: results of a phase I trial. *J Neurooncol* 1991;10(3):271-84.
[PUBMED](#) | [CROSSREF](#)

9. Hynynen K, Jolesz FA. Demonstration of potential noninvasive ultrasound brain therapy through an intact skull. *Ultrasound Med Biol* 1998;24(2):275-83.
[PUBMED](#) | [CROSSREF](#)
10. Cline HE, Hynynen K, Hardy CJ, Watkins RD, Schenck JF, Jolesz FA. MR temperature mapping of focused ultrasound surgery. *Magn Reson Med* 1994;31(6):628-36.
[PUBMED](#) | [CROSSREF](#)
11. LeBlang SD, Hctor K, Steinberg FL. Leiomyoma shrinkage after MRI-guided focused ultrasound treatment: report of 80 patients. *AJR Am J Roentgenol* 2010;194(1):274-80.
[PUBMED](#) | [CROSSREF](#)
12. Huisman M, van den Bosch MA. MR-guided high-intensity focused ultrasound for noninvasive cancer treatment. *Cancer Imaging* 2011;11:S161-6.
[PUBMED](#) | [CROSSREF](#)
13. Apfelbeck M, Clevert DA, Ricke J, Stief C, Schlenker B. Contrast enhanced ultrasound (CEUS) with MRI image fusion for monitoring focal therapy of prostate cancer with high intensity focused ultrasound (HIFU)1. *Clin Hemorheol Microcirc* 2018;69(1-2):93-100.
[PUBMED](#) | [CROSSREF](#)
14. Harary M, Segar DJ, Huang KT, Tafel IJ, Valdes PA, Cosgrove GR. Focused ultrasound in neurosurgery: a historical perspective. *Neurosurg Focus* 2018;44(2):E2.
[PUBMED](#) | [CROSSREF](#)
15. Ishimaru A. *Wave Propagation and Scattering in Random Media*. New York, USA: Wiley; 1999.
16. Laugier P, Haiat G. Introduction to the physics of ultrasound. In: Laugier P, editor. *Bone Quantitative Ultrasound*. Rotterdam, NL: Springer Science+Business Media B.V.; 2011, 29-45.
17. Antich PP, Anderson JA, Ashman RB, Dowdey JE, Gonzales J, Murry RC, et al. Measurement of mechanical properties of bone material in vitro by ultrasound reflection: methodology and comparison with ultrasound transmission. *J Bone Miner Res* 1991;6(4):417-26.
[PUBMED](#) | [CROSSREF](#)
18. Christian E, Yu C, Apuzzo ML. Focused ultrasound: relevant history and prospects for the addition of mechanical energy to the neurosurgical armamentarium. *World Neurosurg* 2014;82(3-4):354-65.
[PUBMED](#) | [CROSSREF](#)
19. Jolesz FA. MRI-guided focused ultrasound surgery. *Annu Rev Med* 2009;60(1):417-30.
[PUBMED](#) | [CROSSREF](#)
20. McDannold N, Clement GT, Black P, Jolesz F, Hynynen K. Transcranial magnetic resonance imaging- guided focused ultrasound surgery of brain tumors: initial findings in 3 patients. *Neurosurgery* 2010;66(2):323-32.
[PUBMED](#) | [CROSSREF](#)
21. Tempany CM, McDannold NJ, Hynynen K, Jolesz FA. Focused ultrasound surgery in oncology: overview and principles. *Radiology* 2011;259(1):39-56.
[PUBMED](#) | [CROSSREF](#)
22. Hynynen K, Vykhodtseva NI, Chung AH, Sorrentino V, Colucci V, Jolesz FA. Thermal effects of focused ultrasound on the brain: determination with MR imaging. *Radiology* 1997;204(1):247-53.
[PUBMED](#) | [CROSSREF](#)
23. Hynynen K, McDannold N, Vykhodtseva N, Jolesz FA. Noninvasive MR imaging-guided focal opening of the blood-brain barrier in rabbits. *Radiology* 2001;220(3):640-6.
[PUBMED](#) | [CROSSREF](#)
24. Hynynen K, McDannold N, Sheikov NA, Jolesz FA, Vykhodtseva N. Local and reversible blood-brain barrier disruption by noninvasive focused ultrasound at frequencies suitable for trans-skull sonications. *Neuroimage* 2005;24(1):12-20.
[PUBMED](#) | [CROSSREF](#)
25. Sheikov N, McDannold N, Vykhodtseva N, Jolesz F, Hynynen K. Cellular mechanisms of the blood-brain barrier opening induced by ultrasound in presence of microbubbles. *Ultrasound Med Biol* 2004;30(7):979-89.
[PUBMED](#) | [CROSSREF](#)
26. Louis ED, Ottman R, Hauser WA. How common is the most common adult movement disorder? estimates of the prevalence of essential tremor throughout the world. *Mov Disord* 1998;13(1):5-10.
[PUBMED](#) | [CROSSREF](#)
27. Louis ED. Essential tremor and the cerebellum. *Handb Clin Neurol* 2018;155:245-58.
[PUBMED](#) | [CROSSREF](#)
28. Muthuraman M, Raethjen J, Koirala N, Anwar AR, Mideksa KG, Elble R, et al. Cerebello-cortical network fingerprints differ between essential, Parkinson's and mimicked tremors. *Brain* 2018;141(6):1770-81.
[PUBMED](#) | [CROSSREF](#)

29. Lipsman N, Schwartz ML, Huang Y, Lee L, Sankar T, Chapman M, et al. MR-guided focused ultrasound thalamotomy for essential tremor: a proof-of-concept study. *Lancet Neurol* 2013;12(5):462-8.
[PUBMED](#) | [CROSSREF](#)
30. Chang WS, Jung HH, Kweon EJ, Zadicario E, Rachmilevitch I, Chang JW. Unilateral magnetic resonance guided focused ultrasound thalamotomy for essential tremor: practices and clinicoradiological outcomes. *J Neurol Neurosurg Psychiatry* 2015;86(3):257-64.
[PUBMED](#) | [CROSSREF](#)
31. Gally MN, Moser D, Rossi F, Pourtehrani P, Magara AE, Kowalski M, et al. Incisionless transcranial MR-guided focused ultrasound in essential tremor: cerebellothalamic tractotomy. *J Ther Ultrasound* 2016;4(1):5.
[PUBMED](#) | [CROSSREF](#)
32. Elias WJ, Lipsman N, Ondo WG, Ghanouni P, Kim YG, Lee W, et al. A randomized trial of focused ultrasound thalamotomy for essential tremor. *N Engl J Med* 2016;375(8):730-9.
[PUBMED](#) | [CROSSREF](#)
33. Mohammed N, Patra D, Nanda A. A meta-analysis of outcomes and complications of magnetic resonance-guided focused ultrasound in the treatment of essential tremor. *Neurosurg Focus* 2018;44(2):E4.
[PUBMED](#) | [CROSSREF](#)
34. Chang JW, Park CK, Lipsman N, Schwartz ML, Ghanouni P, Henderson JM, et al. A prospective trial of magnetic resonance-guided focused ultrasound thalamotomy for essential tremor: results at the 2-year follow-up. *Ann Neurol* 2018;83(1):107-14.
[PUBMED](#) | [CROSSREF](#)
35. Krishna V, Sammartino F, Agrawal P, Changizi BK, Bourekas E, Knopp MV, et al. Prospective tractography-based targeting for improved safety of focused ultrasound thalamotomy. *Neurosurgery* 2018.
[PUBMED](#) | [CROSSREF](#)
36. Tsolaki E, Downes A, Speier W, Elias WJ, Pouratian N. The potential value of probabilistic tractography-based for MR-guided focused ultrasound thalamotomy for essential tremor. *Neuroimage Clin* 2017;17:1019-27.
[PUBMED](#) | [CROSSREF](#)
37. DeLong MR, Wichmann T. Basal ganglia circuits as targets for neuromodulation in Parkinson disease. *JAMA Neurol* 2015;72(11):1354-60.
[PUBMED](#) | [CROSSREF](#)
38. Katz M, Luciano MS, Carlson K, Luo P, Marks WJ Jr, Larson PS, et al. Differential effects of deep brain stimulation target on motor subtypes in Parkinson's disease. *Ann Neurol* 2015;77(4):710-9.
[PUBMED](#) | [CROSSREF](#)
39. Metman LV, Slavin KV. Advances in functional neurosurgery for Parkinson's disease. *Mov Disord* 2015;30(11):1461-70.
[PUBMED](#) | [CROSSREF](#)
40. Magara A, Bühler R, Moser D, Kowalski M, Pourtehrani P, Jeanmonod D. First experience with MR-guided focused ultrasound in the treatment of Parkinson's disease. *J Ther Ultrasound* 2014;2(1):11.
[PUBMED](#) | [CROSSREF](#)
41. Bond AE, Shah BB, Huss DS, Dallapiazza RF, Warren A, Harrison MB, et al. Safety and efficacy of focused ultrasound thalamotomy for patients with medication-refractory, tremor-dominant Parkinson disease: a randomized clinical trial. *JAMA Neurol* 2017;74(12):1412-8.
[PUBMED](#) | [CROSSREF](#)
42. Martínez-Fernández R, Rodríguez-Rojas R, Del Álamo M, Hernández-Fernández F, Pineda-Pardo JA, Dileone M, et al. Focused ultrasound subthalamotomy in patients with asymmetric Parkinson's disease: a pilot study. *Lancet Neurol* 2018;17(1):54-63.
[PUBMED](#) | [CROSSREF](#)
43. Long L, Cai X, Guo R, Wang P, Wu L, Yin T, et al. Treatment of Parkinson's disease in rats by Nrf2 transfection using MRI-guided focused ultrasound delivery of nanomicrobubbles. *Biochem Biophys Res Commun* 2017;482(1):75-80.
[PUBMED](#) | [CROSSREF](#)
44. Lin CY, Hsieh HY, Chen CM, Wu SR, Tsai CH, Huang CY, et al. Non-invasive, neuron-specific gene therapy by focused ultrasound-induced blood-brain barrier opening in Parkinson's disease mouse model. *J Control Release* 2016;235:72-81.
[PUBMED](#) | [CROSSREF](#)
45. Fan CH, Lin CY, Liu HL, Yeh CK. Ultrasound targeted CNS gene delivery for Parkinson's disease treatment. *J Control Release* 2017;261:246-62.
[PUBMED](#) | [CROSSREF](#)
46. Messina G, Islam L, Cordella R, Gambini O, Franzini A. Deep brain stimulation for aggressive behavior and obsessive-compulsive disorder. *J Neurosurg Sci* 2016;60(2):211-7.
[PUBMED](#)

47. Luigjes J, de Kwaasteniet BP, de Koning PP, Oudijn MS, van den Munckhof P, Schuurman PR, et al. Surgery for psychiatric disorders. *World Neurosurg* 2013;80(3-4):31.e17-28.
[PUBMED](#) | [CROSSREF](#)
48. Cleary DR, Ozpinar A, Raslan AM, Ko AL. Deep brain stimulation for psychiatric disorders: where we are now. *Neurosurg Focus* 2015;38(6):E2.
[PUBMED](#) | [CROSSREF](#)
49. Jung HH, Kim SJ, Roh D, Chang JG, Chang WS, Kweon EJ, et al. Bilateral thermal capsulotomy with MR-guided focused ultrasound for patients with treatment-refractory obsessive-compulsive disorder: a proof-of-concept study. *Mol Psychiatry* 2015;20(10):1205-11.
[PUBMED](#) | [CROSSREF](#)
50. Kim SJ, Roh D, Jung HH, Chang WS, Kim CH, Chang JW. A study of novel bilateral thermal capsulotomy with focused ultrasound for treatment-refractory obsessive-compulsive disorder: 2-year follow-up. *J Psychiatry Neurosci* 2018;43(4):170188.
[PUBMED](#)
51. Kim M, Kim CH, Jung HH, Kim SJ, Chang JW. Treatment of major depressive disorder via magnetic resonance-guided focused ultrasound surgery. *Biol Psychiatry* 2018;83(1):e17-8.
[PUBMED](#) | [CROSSREF](#)
52. Tsai SJ. Transcranial focused ultrasound as a possible treatment for major depression. *Med Hypotheses* 2015;84(4):381-3.
[PUBMED](#) | [CROSSREF](#)
53. Woolf CJ, Mannion RJ. Neuropathic pain: aetiology, symptoms, mechanisms, and management. *Lancet* 1999;353(9168):1959-64.
[PUBMED](#) | [CROSSREF](#)
54. Jones RC 3rd, Lawson E, Backonja M. Managing neuropathic pain. *Med Clin North Am* 2016;100(1):151-67.
[PUBMED](#) | [CROSSREF](#)
55. Jeanmonod D, Magnin M, Morel A. Chronic neurogenic pain and the medial thalamotomy. *Schweiz Rundsch Med Prax* 1994;83(23):702-7.
[PUBMED](#)
56. Rasche D, Rinaldi PC, Young RF, Tronnier VM. Deep brain stimulation for the treatment of various chronic pain syndromes. *Neurosurg Focus* 2006;21(6):E8.
[PUBMED](#) | [CROSSREF](#)
57. Young RF, Jacques DS, Rand RW, Copcutt BR. Medial thalamotomy with the Leksell Gamma Knife for treatment of chronic pain. *Acta Neurochir Suppl (Wien)* 1994;62:105-10.
[PUBMED](#) | [CROSSREF](#)
58. Jeanmonod D, Werner B, Morel A, Michels L, Zadicario E, Schiff G, et al. Transcranial magnetic resonance imaging-guided focused ultrasound: noninvasive central lateral thalamotomy for chronic neuropathic pain. *Neurosurg Focus* 2012;32(1):E1.
[PUBMED](#) | [CROSSREF](#)
59. Chen X, Diederich CJ, Wootton JH, Pouliot J, Hsu IC. Optimisation-based thermal treatment planning for catheter-based ultrasound hyperthermia. *Int J Hyperthermia* 2010;26(1):39-55.
[PUBMED](#) | [CROSSREF](#)
60. Cohen-Inbar O, Melmer P, Lee CC, Xu Z, Schlesinger D, Sheehan JP. Leukoencephalopathy in long term brain metastases survivors treated with radiosurgery. *J Neurooncol* 2016;126(2):289-98.
[PUBMED](#) | [CROSSREF](#)
61. Medvid R, Ruiz A, Komotar RJ, Jagid JR, Ivan ME, Quencer RM, et al. Current applications of MRI-guided laser interstitial thermal therapy in the treatment of brain neoplasms and epilepsy: a radiologic and neurosurgical overview. *AJNR Am J Neuroradiol* 2015;36(11):1998-2006.
[PUBMED](#) | [CROSSREF](#)
62. Missios S, Bekelis K, Barnett GH. Renaissance of laser interstitial thermal ablation. *Neurosurg Focus* 2015;38(3):E13.
[PUBMED](#) | [CROSSREF](#)
63. Coluccia D, Fandino J, Schwyzer L, O'Gorman R, Remonda L, Anon J, et al. First noninvasive thermal ablation of a brain tumor with MR-guided focused ultrasound. *J Ther Ultrasound* 2014;2(1):17.
[PUBMED](#) | [CROSSREF](#)
64. Gabathuler R. Approaches to transport therapeutic drugs across the blood-brain barrier to treat brain diseases. *Neurobiol Dis* 2010;37(1):48-57.
[PUBMED](#) | [CROSSREF](#)
65. Lochhead JJ, Thorne RG. Intranasal delivery of biologics to the central nervous system. *Adv Drug Deliv Rev* 2012;64(7):614-28.
[PUBMED](#) | [CROSSREF](#)

66. Bregy A, Shah AH, Diaz MV, Pierce HE, Ames PL, Diaz D, et al. The role of Gliadel wafers in the treatment of high-grade gliomas. *Expert Rev Anticancer Ther* 2013;13(12):1453-61.
[PUBMED](#) | [CROSSREF](#)
67. Kovacs ZI, Kim S, Jikaria N, Qureshi F, Milo B, Lewis BK, et al. Disrupting the blood-brain barrier by focused ultrasound induces sterile inflammation. *Proc Natl Acad Sci U S A* 2017;114(1):E75-84.
[PUBMED](#) | [CROSSREF](#)
68. McDannold N, Arvanitis CD, Vykhodtseva N, Livingstone MS. Temporary disruption of the blood-brain barrier by use of ultrasound and microbubbles: safety and efficacy evaluation in rhesus macaques. *Cancer Res* 2012;72(14):3652-63.
[PUBMED](#) | [CROSSREF](#)
69. Okada K, Kudo N, Niwa K, Yamamoto K. A basic study on sonoporation with microbubbles exposed to pulsed ultrasound. *J Med Ultrason (2001)* 2005;32(1):3-11.
[PUBMED](#) | [CROSSREF](#)
70. Burgess A, Hynynen K. Drug delivery across the blood-brain barrier using focused ultrasound. *Expert Opin Drug Deliv* 2014;11(5):711-21.
[PUBMED](#) | [CROSSREF](#)
71. Thévenot E, Jordão JF, O'Reilly MA, Markham K, Weng YQ, Foust KD, et al. Targeted delivery of self-complementary adeno-associated virus serotype 9 to the brain, using magnetic resonance imaging-guided focused ultrasound. *Hum Gene Ther* 2012;23(11):1144-55.
[PUBMED](#) | [CROSSREF](#)
72. Mei J, Cheng Y, Song Y, Yang Y, Wang F, Liu Y, et al. Experimental study on targeted methotrexate delivery to the rabbit brain via magnetic resonance imaging-guided focused ultrasound. *J Ultrasound Med* 2009;28(7):871-80.
[PUBMED](#) | [CROSSREF](#)
73. Park J, Aryal M, Vykhodtseva N, Zhang YZ, McDannold N. Evaluation of permeability, doxorubicin delivery, and drug retention in a rat brain tumor model after ultrasound-induced blood-tumor barrier disruption. *J Control Release* 2017;250:77-85.
[PUBMED](#) | [CROSSREF](#)
74. Mozaffarian D, Benjamin EJ, Go AS, Arnett DK, Blaha MJ, Cushman M, et al. Executive summary: heart disease and stroke statistics--2016 update: a report from the American Heart Association. *Circulation* 2016;133(4):447-54.
[PUBMED](#) | [CROSSREF](#)
75. Heron M. Deaths: leading causes for 2015. *Natl Vital Stat Rep* 2017;66(5):1-76.
[PUBMED](#)
76. Jayaraman MV, Hussain MS, Abruzzo T, Albani B, Albuquerque FC, Alexander MJ, et al. Embolectomy for stroke with emergent large vessel occlusion (ELVO): report of the Standards and Guidelines Committee of the Society of NeuroInterventional Surgery. *J Neurointerv Surg* 2015;7(5):316-21.
[PUBMED](#) | [CROSSREF](#)
77. Powers WJ, Derdeyn CP, Biller J, Coffey CS, Hoh BL, Jauch EC, et al. 2015 American Heart Association/American Stroke Association Focused Update of the 2013 guidelines for the early management of patients with acute ischemic stroke regarding endovascular treatment: a guideline for healthcare professionals From the American Heart Association/American Stroke Association. *Stroke* 2015;46(10):3020-35.
[PUBMED](#) | [CROSSREF](#)
78. Tsivgoulis G, Safouris A, Katsanos AH, Arthur AS, Alexandrov AV. Mechanical thrombectomy for emergent large vessel occlusion: a critical appraisal of recent randomized controlled clinical trials. *Brain Behav* 2016;6(2):e00418.
[PUBMED](#) | [CROSSREF](#)
79. Ding D, Przybylowski CJ, Starke RM, Sterling Street R, Tyree AE, Webster Crowley R, et al. A minimally invasive anterior skull base approach for evacuation of a basal ganglia hemorrhage. *J Clin Neurosci* 2015;22(11):1816-9.
[PUBMED](#) | [CROSSREF](#)
80. Hemphill JC 3rd, Greenberg SM, Anderson CS, Becker K, Bendok BR, Cushman M, et al. Guidelines for the management of spontaneous intracerebral hemorrhage: a guideline for healthcare professionals from the American Heart Association/American Stroke Association. *Stroke* 2015;46(7):2032-60.
[PUBMED](#) | [CROSSREF](#)
81. Phenix CP, Togtema M, Pichardo S, Zehbe I, Curiel L. High intensity focused ultrasound technology, its scope and applications in therapy and drug delivery. *J Pharm Pharm Sci* 2014;17(1):136-53.
[PUBMED](#) | [CROSSREF](#)
82. Bader KB, Bouchoux G, Holland CK. Sonothrombolysis. *Adv Exp Med Biol* 2016;880:339-62.
[PUBMED](#) | [CROSSREF](#)

83. Chen X, Leeman JE, Wang J, Pacella JJ, Villanueva FS. New insights into mechanisms of sonothrombolysis using ultra-high-speed imaging. *Ultrasound Med Biol* 2014;40(1):258-62.
[PUBMED](#) | [CROSSREF](#)
84. Pajek D, Burgess A, Huang Y, Hynynen K. High-intensity focused ultrasound sonothrombolysis: the use of perfluorocarbon droplets to achieve clot lysis at reduced acoustic power. *Ultrasound Med Biol* 2014;40(9):2151-61.
[PUBMED](#) | [CROSSREF](#)
85. Wright C, Hynynen K, Goertz D. In vitro and in vivo high-intensity focused ultrasound thrombolysis. *Invest Radiol* 2012;47(4):217-25.
[PUBMED](#) | [CROSSREF](#)
86. Westermarck S, Wiksell H, Elmqvist H, Hultenby K, Berglund H. Effect of externally applied focused acoustic energy on clot disruption in vitro. *Clin Sci (Lond)* 1999;97(1):67-71.
[PUBMED](#) | [CROSSREF](#)
87. Rosenschein U, Furman V, Kerner E, Fabian I, Bernheim J, Eshel Y. Ultrasound imaging-guided noninvasive ultrasound thrombolysis: preclinical results. *Circulation* 2000;102(2):238-45.
[PUBMED](#) | [CROSSREF](#)
88. Maxwell AD, Cain CA, Duryea AP, Yuan L, Gurm HS, Xu Z. Noninvasive thrombolysis using pulsed ultrasound cavitation therapy - histotripsy. *Ultrasound Med Biol* 2009;35(12):1982-94.
[PUBMED](#) | [CROSSREF](#)
89. Harnof S, Zibly Z, Hananel A, Monteith S, Grinfeld J, Schiff G, et al. Potential of magnetic resonance-guided focused ultrasound for intracranial hemorrhage: an in vivo feasibility study. *J Stroke Cerebrovasc Dis* 2014;23(6):1585-91.
[PUBMED](#) | [CROSSREF](#)
90. Monteith SJ, Harnof S, Medel R, Popp B, Wintermark M, Lopes MB, et al. Minimally invasive treatment of intracerebral hemorrhage with magnetic resonance-guided focused ultrasound. *J Neurosurg* 2013;118(5):1035-45.
[PUBMED](#) | [CROSSREF](#)
91. Régis J, Rey M, Bartolomei F, Vladyka V, Liscak R, Schröttner O, et al. Gamma knife surgery in mesial temporal lobe epilepsy: a prospective multicenter study. *Epilepsia* 2004;45(5):504-15.
[PUBMED](#) | [CROSSREF](#)
92. Vojtech Z, Vladyka V, Kalina M, Nespor E, Seltenreichová K, Semnická J, et al. The use of radiosurgery for the treatment of mesial temporal lobe epilepsy and long-term results. *Epilepsia* 2009;50(9):2061-71.
[PUBMED](#) | [CROSSREF](#)
93. Malikova H, Vojtech Z, Liscak R, Prochazka T, Vymazal J, Mareckova I, et al. Microsurgical and stereotactic radiofrequency amygdalohippocampectomy for the treatment of mesial temporal lobe epilepsy: different volume reduction, similar clinical seizure control. *Stereotact Funct Neurosurg* 2010;88(1):42-50.
[PUBMED](#) | [CROSSREF](#)
94. Hoppe C, Witt JA, Helmstaedter C, Gasser T, Vatter H, Elger CE. Laser interstitial thermotherapy (LiTT) in epilepsy surgery. *Seizure* 2017;48:45-52.
[PUBMED](#) | [CROSSREF](#)
95. Mueller JK, Ai L, Bansal P, Legon W. Numerical evaluation of the skull for human neuromodulation with transcranial focused ultrasound. *J Neural Eng* 2017;14(6):066012.
[PUBMED](#) | [CROSSREF](#)
96. Chang WS, Jung HH, Zadicario E, Rachmilevitch I, Tlusty T, Vitek S, et al. Factors associated with successful magnetic resonance-guided focused ultrasound treatment: efficiency of acoustic energy delivery through the skull. *J Neurosurg* 2016;124(2):411-6.
[PUBMED](#) | [CROSSREF](#)
97. MacDonell J, Patel N, Rubino S, Ghoshal G, Fischer G, Burdette EC, et al. Magnetic resonance-guided interstitial high-intensity focused ultrasound for brain tumor ablation. *Neurosurg Focus* 2018;44(2):E11.
[PUBMED](#) | [CROSSREF](#)
98. Monteith S, Snell J, Eames M, Kassell NF, Kelly E, Gwinn R. Transcranial magnetic resonance-guided focused ultrasound for temporal lobe epilepsy: a laboratory feasibility study. *J Neurosurg* 2016;125(6):1557-64.
[PUBMED](#) | [CROSSREF](#)
99. Hersh DS, Eisenberg HM. Current and future uses of transcranial focused ultrasound in neurosurgery. *J Neurosurg Sci* 2018;62(2):203-13.
[PUBMED](#)
100. Ghanouni P, Pauly KB, Elias WJ, Henderson J, Sheehan J, Monteith S, et al. Transcranial MRI-guided focused ultrasound: a review of the technologic and neurologic applications. *AJR Am J Roentgenol* 2015;205(1):150-9.
[PUBMED](#) | [CROSSREF](#)

101. Pajek D, Hynynen K. The design of a focused ultrasound transducer array for the treatment of stroke: a simulation study. *Phys Med Biol* 2012;57(15):4951-68.
[PUBMED](#) | [CROSSREF](#)
102. Tsivgoulis G, Eggers J, Ribo M, Perren F, Saqqur M, Rubiera M, et al. Safety and efficacy of ultrasound-enhanced thrombolysis: a comprehensive review and meta-analysis of randomized and nonrandomized studies. *Stroke* 2010;41(2):280-7.
[PUBMED](#) | [CROSSREF](#)