

Extended posterior approach for huge popliteal aneurysm extended to superficial femoral artery

SAGE Open Medical Case Reports
Volume 6: 1–5
© The Author(s) 2018
Reprints and permissions:
sagepub.co.uk/journalsPermissions.nav
DOI: 10.1177/2050313X17752770
journals.sagepub.com/home/sco



Tomoki Cho¹ , Hideyuki Iwaki¹ and Munetaka Masuda²

Abstract

Objectives: Generally, popliteal artery aneurysms have been addressed surgically by a medial, posterior, or lateral approach. We have designed a new posterior approach that exposes the superficial femoral artery and entire popliteal artery without dividing any muscles in a just prone position.

Methods and results: A 72-year old man with huge popliteal aneurysm extended to superficial femoral artery was admitted to our hospital. Surgery was performed due to a high risk of rupture. An S-shaped skin incision was made in the popliteal fossa. We could not expose the proximal side of the giant aneurysm proximal to the foramen of the adductor magnus. We extended the skin incision to the proximal and exfoliated the medial side of semitendinosus muscle. We could expose the superficial femoral artery in this approach like in a medial approach. We could perform the interposition of great saphenous vein.

Conclusion: The advantages of this approach allowed for entire exposure of the popliteal aneurysm in the same patient's position when we perform aneurysmectomy and bypass. It is possible for this approach to provide easy access to the superficial femoral artery proximal to the adductor hiatus and distal below-knee popliteal artery including the tibioperoneal trunk.

Keywords

Posterior approach, popliteal artery aneurysm

Date received: 9 May 2017; accepted: 12 December 2017

Introduction

Generally, popliteal aneurysm has been able to be addressed surgically by a posterior approach only. However, if popliteal aneurysm is huge beyond the adductor hiatus or extending to the tibioperoneal trunk, it is necessary to deal with by additional approach, such as a medial and lateral approach.^{1,2} An operation by means of ligations proximal and distal side of an aneurysm and bypass graft insertion between of an aneurysm is performed by medial approach. But, the sac enlargement or even rupture due to retrograde collateral pathway toward the aneurysm during follow-up period has been reported. Accordingly, we designed a new surgical approach that is able to expose both of the superficial femoral artery (SFA) and entire popliteal aneurysm including distal popliteal artery in an only prone position. We obtained this patient's publication consent.

Case report

A 72-year-old man with swelling and pain from the right mid-thigh to the popliteal fossa was admitted to our hospital. And, he had a symptom of intermittent claudication for several years. His right common femoral artery was palpable, but other arteries below popliteal region were not palpable. The computed tomography revealed right huge thrombosed popliteal aneurysm (maximum transverse diameter of 90 mm,

¹Department of Cardiovascular and Thoracic Surgery, Saiseikai Yokohamashi Nanbu Hospital, Yokohama, Japan

²Department of Surgery, Yokohama City Hospital, Yokohama, Japan

Corresponding Author:

Tomoki Cho, Department of Cardiovascular and Thoracic Surgery, Saiseikai Yokohamashi Nanbu Hospital, 3-2-10 Konandai, Kounan-ku, Yokohama 234-0054, Japan.

Email: tomoggio@kd6.so-net.ne.jp



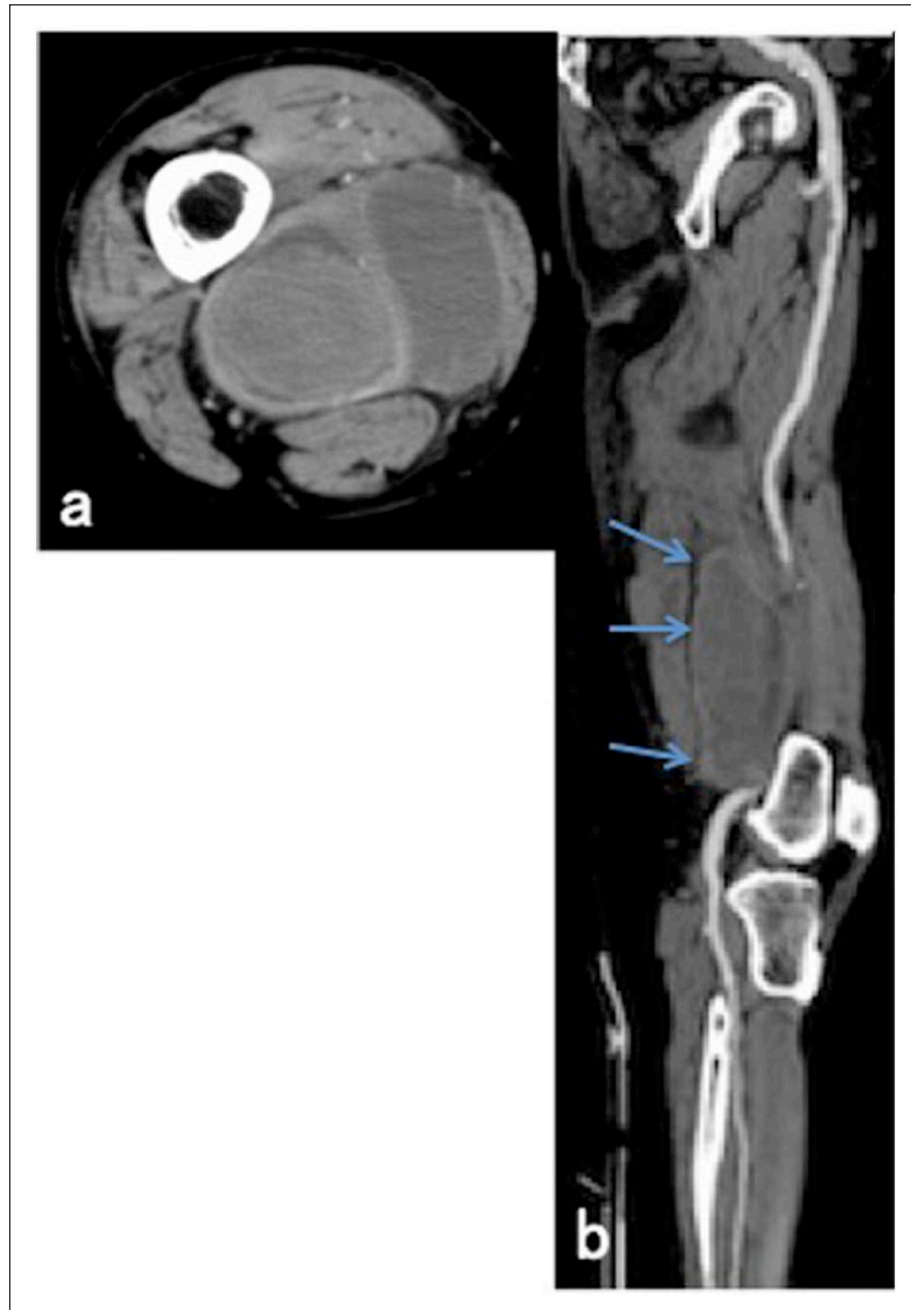


Figure 1. (a) Preoperative enhanced computed tomography showing huge right popliteal aneurysm (maximum transverse diameter of 90 mm). (b) Arrow indicates huge right popliteal aneurysm from mid-thigh to popliteal fossa of right leg (maximum longitudinal diameter of 120 mm). (c) Preoperative enhanced computed tomography showing left popliteal aneurysm (maximum transverse diameter of 50 mm). (d) Arrow indicates left popliteal aneurysm from mid-thigh to popliteal fossa of left leg. (maximum longitudinal diameter of 100 mm).

longitudinal diameter of 120 mm) extending from mid-SFA to middle popliteal arteries (Figure 1(a) and (b)). Basically, we perform an aneurysmectomy and bypass by a usual posterior approach for a popliteal aneurysm. However, as the aneurysm extended to the SFA in the patient, we thought that we cannot expose SFA proximal to a foramen of great adductor magnus in an only posterior approach and that we have to change a patient's position and add a medial approach. So, we produced

the additional method in addition to usual posterior approach to expose entire huge aneurysm including normal arteries proximal and distal sides of the aneurysm.

Operation

At first, the patient was placed in supine position on the operating table. A three skip incisions were made on right thigh to

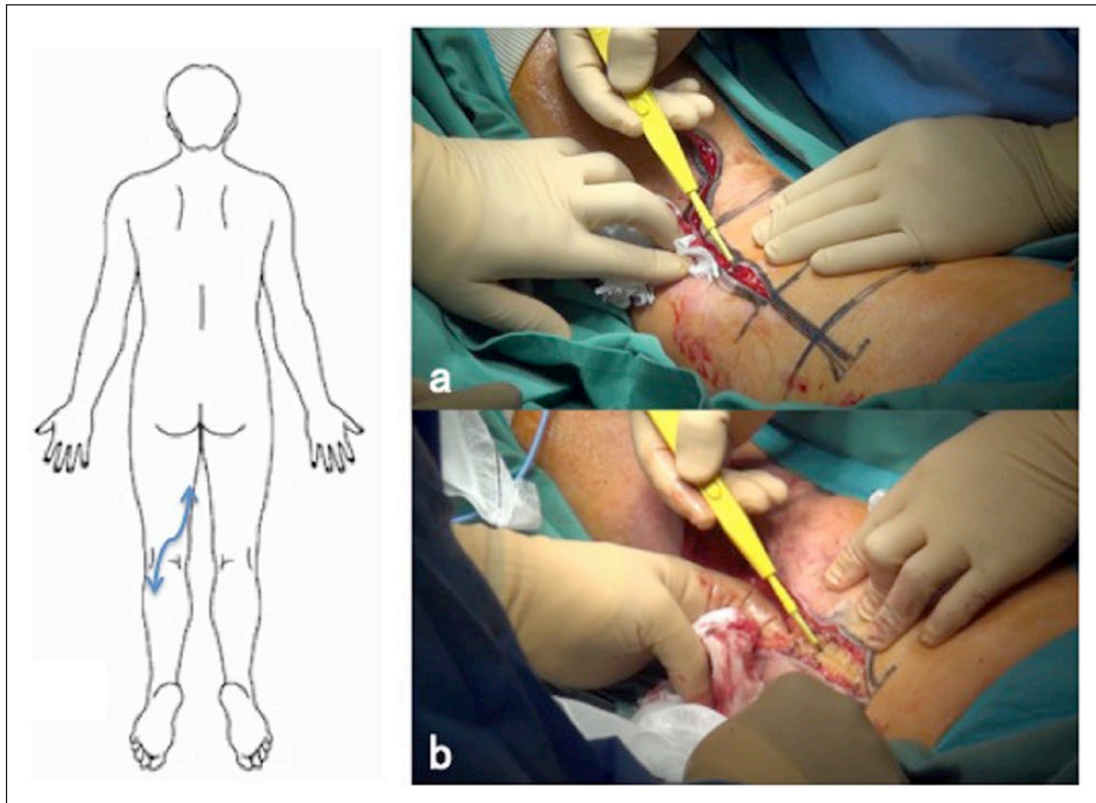


Figure 2. These operative figures for left huge popliteal aneurysm: (a) usual skin incision for posterior approach and (b) extended skin incision for extended posterior approach.

harvest the great saphenous vein (SV). Next, his position was changed to prone position after harvest of the SV. A slight larger S-shaped skin incision than normal posterior approach was made in the center of the popliteal fossa (Figure 2(a)). First, normal below-knee popliteal artery after the aneurysm was exposed easily using normal posterior approach. Next, we began to expose the huge aneurysm along to popliteal artery in order to expose the entire aneurysm. However, we could not expose the entire aneurysm because the proximal side of the aneurysm was much beyond the adductor hiatus. At this time, we had to give up to the exposure of the entire aneurysm from the normal posterior approach. Therefore, we extended the skin incision to the proximal inside of the thigh, such as medial approach at the lower thigh to expose the entire aneurysm including proximal SFA beyond the aneurysm (Figure 2(b)). Normally, it is possible for usual posterior approach to expose popliteal artery up to adductor hiatus from the inside of the semimembranosus muscle and the semitendinosus muscle (Figure 3(a)). However, only the usual posterior approach cannot expose SFA beyond the adductor hiatus. Therefore, we extended the skin incision and exposed SFA beyond the adductor hiatus from the outside of the semimembranosus muscle and the semitendinosus muscle, such as medial approach to expose SFA (Figure 3(b)). Using this method, in addition to the usual posterior approach, we could expose the adductor hiatus easily from extended posterior approach as well as a medial approach, and the SFA of the

proximal side of the aneurysm was easily encircled with a vessel loop (Figure 3(c)). After the patient underwent systemic heparinization, the proximal and distal sites of aneurysm were clamped. The giant aneurysm was made an incision, and the branches from the aneurysm were completely closed. After that, SV graft was sewn in end-to-end fashion to the SFA with 6-0 monofilament running suture. After the proximal anastomosis was completed, the SV graft was placed under tension and tailored to the correct length. Then, distal anastomosis to the popliteal artery was performed with same procedure (Figure 3(d)). Suction drain was placed in the thigh and popliteal space. The wound was easily closed because reconstruction of the muscles was not required and enough space was gotten by complete resection of the huge aneurysm (Figure 3(e)).

The postoperative course was not eventful. The postoperative computed tomography revealed no complications including graft failure, lymphorrhea, and venous insufficiency (Figure 3(f)). We have ever performed popliteal aneurysmectomy and bypass by this approach for four limbs of three patients. For 2 years, all bypass grafts have been patented, and all patients have no intermittent claudication.

Discussion

Surgical approaches for popliteal aneurysm are generally selected either medial approach or posterior approach on

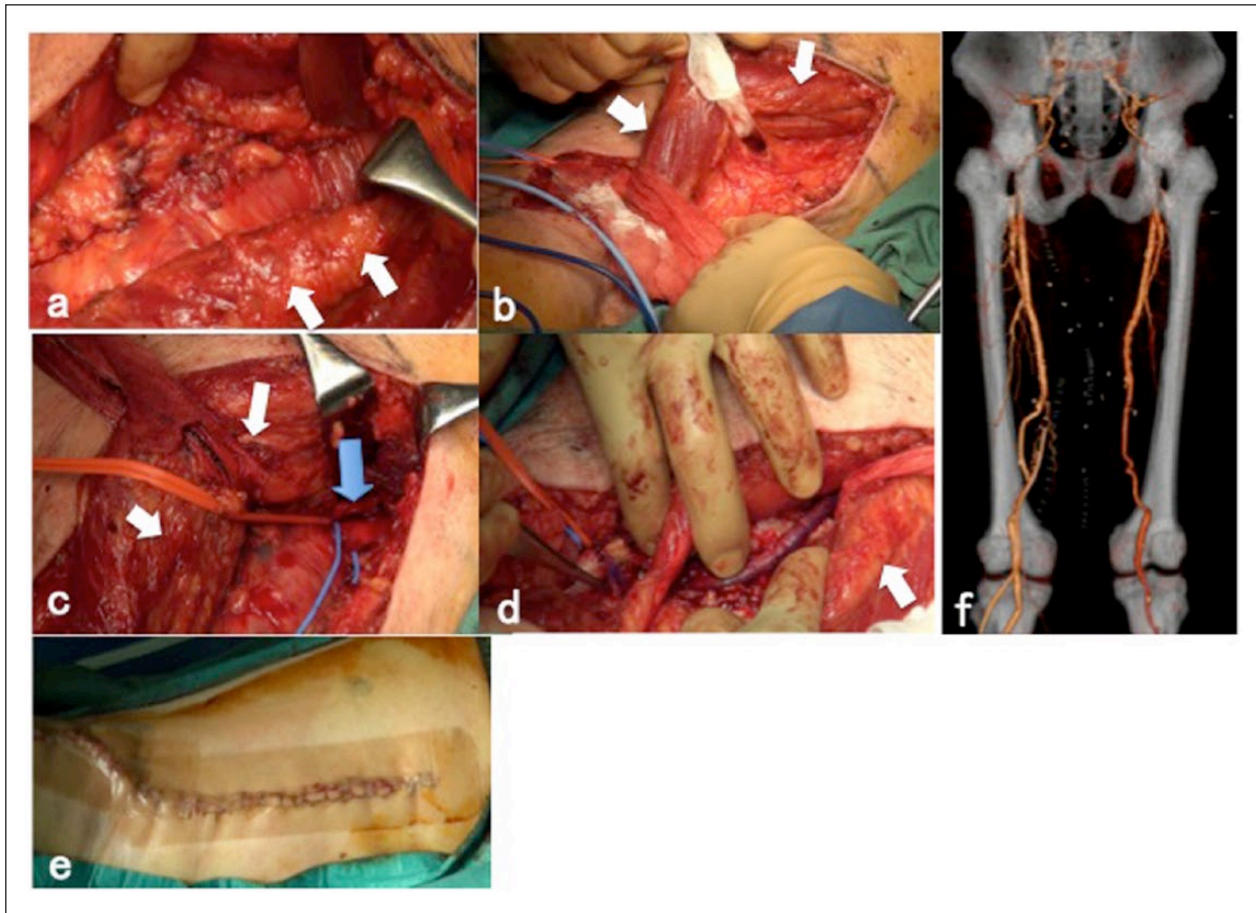


Figure 3. (a) Exposure of proximal popliteal artery using usual posterior approach from the inside of the semimembranosus muscle and the semitendinosus muscle. Entire huge popliteal aneurysm could not be exposed from this approach. White arrow indicates the semimembranosus muscle and the semitendinosus muscle. (b) Exposure for proximal popliteal artery using extended posterior approach from the outside of the semimembranosus muscle and the semitendinosus muscle such as medial approach. (c) Entire huge popliteal aneurysm including proximal SFA beyond adductor hiatus was completely exposed using extended posterior approach. Blue Arrow indicates SFA connected to huge popliteal aneurysm. (d) Replaced SV graft between SFA and distal popliteal artery. (e) Postoperative wound of extended posterior approach. (f) Postoperative enhanced computed tomography showing bilateral saphenous vein graft from superficial femoral artery (SFA) to popliteal artery.

the basis of location of aneurysms. However, when a popliteal aneurysm ranges from SFA to popliteal artery, we cannot expose SFA and entire popliteal artery in an only posterior or medial approach. Then, it is difficult to treat aneurysms completely by each single approach only. We extended a skin incision of the normal posterior approach to the proximal side, and we succeeded in exposure of the entire aneurysm and the SFA proximal to the adductor hiatus using medial approach in addition to usual posterior approach at the just prone position. We named this approach as “Extended posterior approach” because we can get more wide surgical field than usual posterior approach. As the advantages of this approach, we can observe the entire aneurysm including proximal and distal arteries by a single skin incision and a single position, and we can deal with all small branches from the aneurysm under direct vision after dissection of the aneurysm.

Several long-term results of the medial and posterior approach for the treatments of popliteal aneurysms have been reported.^{3–5} Generally, popliteal aneurysm was remaining by treated with exclusion method and bypass jumped the aneurysm by separate two median approaches of above and below knee. An excluded aneurysm can be transmitted to systemic pressure from persistent retrograde flow through small branches from an aneurysm. As the result, an aneurysm will be growth and rupture. Mehta et al.⁶ and Ebaugh et al.⁷ reported that excluded popliteal aneurysms grow in 7%–23 % of the patients after the operation.

Conclusion

This approach is much useful because it provides a good surgical field of entire popliteal aneurysm including proximal and distal arteries of the aneurysm.

Declaration of conflicting interests

The author(s) declared no potential conflicts of interest with respect to the research, authorship, and/or publication of this article.

Ethical approval

Our institution does not require ethical approval for reporting individual cases or case series.

Funding

The author(s) received no financial support for the research, authorship, and/or publication of this article.

Informed consent

Written informed consent was obtained from the patient(s) for their anonymized information to be published in this article.

ORCID iD

Tomoki Cho  <http://orcid.org/0000-0001-9818-8352>

References

1. Szilagyi DE, Whitcomb JG and Smith RF. Anteromedial approach to the popliteal artery for femoropopliteal arterial grafting. *AMA Arch Surg* 1959; 78: 647–651.
2. Esses GE and Johnson WC. The lateral approach to the proximal popliteal artery for popliteal to anterior tibial artery bypass. *J Am Coll Surg* 1994; 178: 77–78.
3. Beath BD and Moore WS. The posterior approach for repair of popliteal artery aneurysms. *J Vasc Surg* 2006; 43: 940–945.
4. Dorigo W, Pulli R, Innocenti AA, et al. A 33-year experience with surgical management of popliteal artery aneurysms. *J Vasc Surg* 2015; 62: 1176–1182.
5. Mazzaccaro D, Carno M, Dallatana R, et al. Comparison of posterior and medial approaches for popliteal artery aneurysms. *J Vasc Surg* 2015; 62: 1512–1520.
6. Mehta M, champagne B, Darling RC 3rd, et al. Outcome of popliteal artery aneurysms after exclusion and bypass: significance of residual patent branches mimicking type II endoleaks. *J Vasc Surg* 2004; 40: 886–890.
7. Ebaugh JL, Morasch MD, Matsumura JS, et al. Fate of excluded popliteal artery aneurysms. *J Vasc Surg* 2003; 37: 954–959.