



Functional Medicine

Chronic Colovesical Fistula Leading to Chronic Urinary Tract Infection Resulting in End-Stage Renal Disease in a Chronic Granulomatous Disease Patient



M.R. Siddiqui^a, T. Sanford^a, A. Nair^a, C.S. Zerbe^b, M.S. Hughes^c, L. Folio^d, Piyush K. Agarwal^{a,*}, S.J. Brancato^e

^a Urologic Oncology Branch, National Cancer Institute, NIH, USA

^b Laboratory of Clinical Infectious Diseases, National Institute of Allergy and Infectious Disease, NIH, USA

^c Surgical Oncology Branch, National Cancer Institute, NIH, USA

^d Radiology and Imaging and Sciences, Clinical Center, National Institutes of Health, USA

^e University of Iowa, USA

ARTICLE INFO

Article history:

Received 14 November 2016

Accepted 6 December 2016

Keywords:

Colovesical fistula

Chronic granulomatous disease

Colitis

Pyelonephritis

Urinary tract infections

Post-renal obstruction

ABSTRACT

A 46-year old man with X-linked chronic granulomatous disease (CGD) being followed at the National Institute of Health with uncontrolled CGD colitis who developed chronic colovesical fistula, and end-stage renal disease (ESRD). Despite aggressive medical management of symptoms with immunomodulators and antibiotic prophylaxis, the chronic colovesical fistula led to chronic pyelonephritis, recurrent urinary tract infections, persistent air in the collecting system and bladder, and post-renal obstruction resulting in renal failure. Patient is now hemodialysis dependent and required diverting loop ileostomy placement. This report highlights multiple potential etiologies of rising serum creatinine in patients with CGD.

Published by Elsevier Inc. This is an open access article under the CC BY-NC-ND license (<http://creativecommons.org/licenses/by-nc-nd/4.0/>).

Introduction

Chronic granulomatous disease is an inherited primary immunodeficiency characterized by defective leukocyte nicotinamide dinucleotide phosphate (NADPH) oxidase resulting in susceptibility to specific bacterial and fungal infections, as well as inflammatory complications. An abnormal inflammatory response in the absence of active infection is seen in the gastrointestinal tract in up to 50% of patients.¹ The propensity is greater in X-linked inherited disease.¹

While gastrointestinal inflammation is common in such patients, only 2 cases of gastrointestinal fistulas in CGD patients have been reported in the literature.² In this report, we describe an unusual case of CGD-related colitis resulting in colovesical fistula leading to the patient developing renal failure.

Case presentation

This is a report of a 46-year old man with a long standing history of X-linked chronic granulomatous disease (CGD) complicated by an aggressive form of CGD-colitis leading to chronic colovesical fistula. His past surgical history includes colovesical fistula repair in 1988, at age 18 years. After the initial repair, his disease was well controlled on medical management with immunomodulators and antibiotics, albeit recently showing evidence of mild bladder wall thickening, some air in the collecting system and bladder, and mild increase in baseline serum creatinine.

About 2 years ago, in 2014, he presented with nocturia, recurrent intermittent pneumaturia, urinary frequency, and acute rise in serum creatinine to 2.3 mg/dL from baseline of 1.24 mg/dL. His urinalysis was positive for leukocyte esterase, nitrites, and 5000 WBC/hpf.

Funding: This research was supported by the Intramural Research Program of the NIH, National Cancer Institute, Center for Cancer Research. This research was also made possible through the NIH Medical Research Scholars Program, a public-private partnership supported jointly by the NIH and generous contributions to the Foundation for the NIH from the Doris Duke Charitable Foundation, the American Association for Dental Research, the Colgate-Palmolive Company, Genentech, and other private donors. For a complete list, visit the foundation website at <http://www.fnih.org>.

* Corresponding author. Bladder Cancer Section, Urologic Oncology Branch, National Cancer Institute, NIH, Building 10, Room 2W-5940, 10 Center Drive, MSC 1210, Bethesda, MD 20892-1210, USA. Fax: +1 301 480 5626.

E-mail address: piyush.agarwal@nih.gov (P.K. Agarwal).

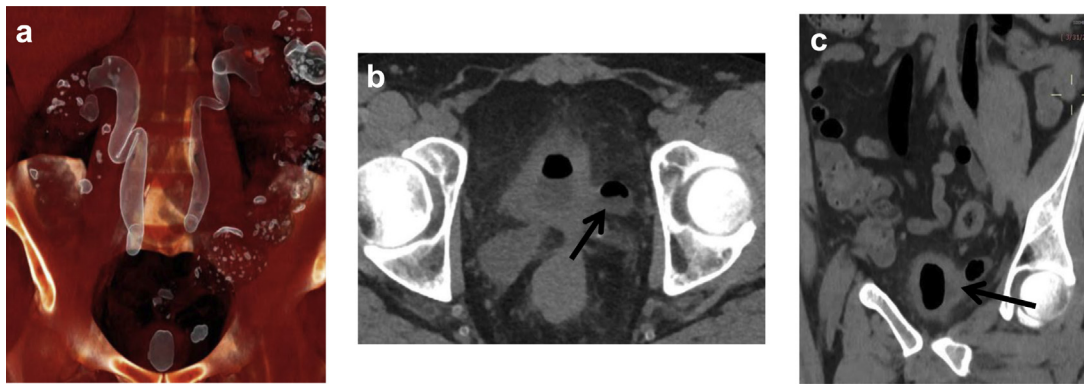


Figure 1. (a) In this coronal Multi Planar Volume Rendered (MPVR) Reformation CT scan, the white highlighted areas represent air in the collecting system. The bladder and ureters all have abnormal amounts of air compared to the expected air seen in the descending and ascending colons. (b) In the axial cross-sectional and coronal views (c), air in the collecting systems is seen once again. In addition, both pictures reveal the likely position of the colovesical fistula between the bladder and colon (marked with black arrows).

His urine culture grew extended spectrum beta-lactamase *E. coli*. The CT scan of the abdomen and pelvis without contrast revealed air in the bladder and within bilateral upper tracts (Fig. 1). Urology was then consulted, and, in conjunction with the primary medical team, the decision was made to pursue conservative medical management with increased fluid intake, prednisone, amoxicillin/clavulanic acid, and ciprofloxacin.

Over the course of the next 2 years, the patient developed chronic pyelonephritis with recurrent episodes of urinary tract infections often complicated by acute kidney injury from dehydration, requiring aggressive management with fluids and antibiotics. He also developed bilateral distal ureteral thickening with waxing/waning proximal hydronephrosis and increasing bladder wall thickening. Changes in renal parenchyma were also noted on serial abdominal imaging including increased bilateral echogenicity and renal cortical irregularity. Progressively increasing amounts of air in the collecting system and bladder were noted on these images as well.

During this period, he received aggressive medical management with various combinations of immunomodulators and prophylactic antibiotics, including prednisone, azathioprine, vedolizumab, posaconazole, and ciprofloxacin. However, his renal function continued to deteriorate, eventually turning into end-stage renal disease, requiring hemodialysis. He ultimately underwent a diverting loop ileostomy to address his recurrent urinary tract infections and chronic pyelonephritis. He remains stable without improvement in renal function since the procedure.

Discussion

Here we present a unique case of a patient with chronic granulomatous disease complicated by an aggressive CGD-related colitis causing chronic colovesical fistula and the development of post-renal obstruction, ultimately leading to the development of renal failure. The etiology of renal failure in this patient is likely a combination of two processes: post-renal obstruction and chronic pyelonephritis with recurrent episodes of urinary tract infections.

A progressive increase in bladder wall thickness and distal ureteral thickening combined with bilateral hydronephrosis strongly suggest a significant contribution of post-renal obstruction to the development of renal failure. This obstruction is likely further exacerbated by chronic accumulation of air in the collecting system and bladder. While it is difficult to know the underlying cause of post-renal obstruction, we speculate that it might be the result of

chronic inflammation from longstanding infection in the setting of CGD, which has been reported to cause granulomatous changes due to dysfunctional inflammatory response.³

It has also been reported that patients with CGD can have recurrent urinary tract infections.³ This likely happened in our patient especially given his longstanding colovesical fistula and clinical history of chronic and recurrent urinary tract infections. The structural damage to kidneys from these infections are evident by bilateral structural changes seen on serial abdominal imaging – increased renal echogenicity and renal cortical irregularity.⁴ The damage is likely further facilitated by recurrent episodes of pre-renal acute kidney injuries from dehydration in the setting acute urinary tract infections, which is known to significantly increase the risk of developing chronic kidney disease.⁵

Conclusion

This is a case report of a patient with chronically uncontrolled Chronic granulomatous disease (CGD) complicated by aggressive form of CGD-related colitis which can give rise to longstanding colovesical fistula leading to development of chronic pyelonephritis and recurrent urinary tract infections. In patients with CGD and rising serum creatinine, both obstructive processes as well as chronic infections should be considered in the differential diagnosis.

Conflict of interest

None.

References

- Alvarez-Downing MM, Kamal N, Inchauste SM, et al. The role of surgery in the management of patients with refractory chronic granulomatous disease colitis. *Dis Colon Rectum*. 2013;56(5):609–614. <http://dx.doi.org/10.1097/DCR.0b013e3182781504>.
- Gopal Lakshmi, Forbes Joanne, Uzel Gulbu, et al. Gastrointestinal fistulae in chronic granulomatous disease. *J Pediatr*. 2009;48(suppl 2):1–6. <http://dx.doi.org/10.1097/MPG.0b013e3181a15ae8.Screening>.
- Walther MM, Malech H, Berman A, et al. The urological manifestations of chronic granulomatous disease. *J Urol*. 1992;147(5):1314–1318. <http://www.ncbi.nlm.nih.gov/pubmed/1569675>. Accessed 14 September 2016.
- Craig W, Wagner BJ, Mark D. Pyelonephritis: radiologic-pathologic review. *RadioGraphics*. 2008;28:255–277.
- Chawla LS, Eggers PW, Star RA, Kimmel PL. Acute kidney injury and chronic kidney disease as interconnected syndromes. *N Engl J Med*. 2014;371(1):58–66. <http://dx.doi.org/10.1056/NEJMra1214243>.