



## Original Research Article

Cardio-protective effect of *Cocculus hirsutus* in experimental hypertension in ratsS.M. Gunjegaonkar <sup>a,\*</sup>, V.R. Khakal <sup>b</sup>, A.A. Joshi <sup>a</sup>, S.L. Nargund <sup>b</sup>, S.D. Shinde <sup>c</sup>, N.S. Khan <sup>a</sup><sup>a</sup> ASPM's K. T. Patil College of Pharmacy, Siddharth Nagar, Barshi Road, Osmanabad, 413 501, Maharashtra, India<sup>b</sup> Nargund College of Pharmacy 2nd Main Dattatreyanagar, 100FET Ring Road, Banashankari 3rd Stage Bangalore, 560 085, Karnataka, India<sup>c</sup> Shri. R. D. Bhakt College of Pharmacy, Department of Pharmacology, Jalna, 431203, Maharashtra, India

## ARTICLE INFO

## Article history:

Received 31 January 2022

Received in revised form

26 September 2022

Accepted 29 September 2022

Available online xxx

## Keywords:

*Cocculus hirsutus*

Coronary artery ligation

Acute renal hypertension

Cardioprotection

Antioxidant activity

Hypercholesterolemia

## ABSTRACT

**Background:** Ayurvedic derived medicines are most promising and effective in the treatment of several cardiovascular diseases. *Cocculus hirsutus* (CH) has been reported for broad spectrum of activities like anticancer, antidiabetic, antioxidant, cardiogenic and hypotensive etc.

**Objectives:** The present study aimed to find the cardio-protective effect of CH in experimental hypertension in rats.

**Materials and methods:** For acute renal hypertension, CH animals were pre-treated with CH-1 (250 mg/kg) and CH-2 (500 mg/kg) p. o. for 14 days. On the 15th day, hypertension was induced by renal occlusion and the mean arterial blood pressure (MABP) was recorded. For CAL pretreatment of CH-1 and CH-2 was given for 7 days on the 8th day animals were operated on for ligation. The MABP and the time of onset of ventricular tachycardia (VT), premature ventricular systole (PVS) were recorded. For induction of hypercholesterolemia, animals were fed with a high cholesterol diet (CD) with CH-1 and CH-2 for 21 days. The antioxidant potential of CH was done using the assay of superoxide dismutase (SOD), catalase (CAT), glutathione (GSH), and glutathione peroxidase (GPx).

**Results:** CH treatment significantly decreases the MABP, the onset of VT and PVS. The histology show intact cardiac muscle with minimum necrosis and inflammation. CH treatment shows significant decrease in cholesterol, triglycerides, and glucose while HDL levels are significantly increased. The aortic section of CH-treated animals shows the intact layers of the artery, normal thickness and restoration of antioxidant enzymatic activity.

**Conclusion:** The study shows significant cardio protective effect of CH in experimental animals.

© 2022 The Authors. Published by Elsevier B.V. on behalf of Institute of Transdisciplinary Health Sciences and Technology and World Ayurveda Foundation. This is an open access article under the CC BY-NC-ND license (<http://creativecommons.org/licenses/by-nc-nd/4.0/>).

**Abbreviations:** Atr, Atorvastatin; CAL, Coronary artery ligation; CAT, Catalase; CD, Cholesterol diet; CVDs, Cardiovascular diseases; DTNB 5, 5'-dithiobis (2-nitrobenzoic acid); GPx, Glutathione peroxidase; GSH, glutathione; GSSG, glutathione disulfide; H<sub>2</sub>O<sub>2</sub>, Hydrogen peroxide; HDL, High density lipoprotein; LDL, Low density lipoprotein; MABP, Mean arterial blood pressure; MI, Myocardial infarction; NADPH, Nicotinamide adenine dinucleotide phosphate; PVS, Premature ventricular systole; RAS, Renin-angiotensin system; ROS, Reactive oxygen species; SOD, superoxide dismutase; VLDL, Very low-density lipoprotein; VT, Ventricular tachycardia.

\* Corresponding author. Department of Pharmacology, ASPM's K. T. Patil College of Pharmacy, Siddharth Nagar, Barshi Road, Osmanabad- 413 501, Maharashtra, India.

E-mail: [gunjeshiv@gmail.com](mailto:gunjeshiv@gmail.com)

Peer review under responsibility of Transdisciplinary University, Bangalore.

<https://doi.org/10.1016/j.jaim.2022.100652>

0975-9476/© 2022 The Authors. Published by Elsevier B.V. on behalf of Institute of Transdisciplinary Health Sciences and Technology and World Ayurveda Foundation. This is an open access article under the CC BY-NC-ND license (<http://creativecommons.org/licenses/by-nc-nd/4.0/>).

## 1. Introduction

Plant-derived medicines have a significant role in the treatment of several life-threatening diseases including diabetes, cancer, cardiovascular diseases, arthritis, etc [1]. Currently, researchers are keenly interested in herbal medicines for their potent clinical applications [2]. Ayurveda has advocated several benefits of *Cocculus hirsutus*. CH (L.) (Menispermaceae) is a perennial creeper widely distributed in Asia and Africa, certainly in tropical and subtropical zones [3]. CH is being used traditionally in several countries as a folk remedy for different health issues. Ethnic people from South Asia use CH leaf paste for its head-cooling effect [3]. To relieve heat, the plant juice is blended with some mineral oil and applied to the body [4]. The plant juice is rubbed into the navel region to relieve abdominal discomfort and bloody feces [5]. Plant juice is used for

skin diseases and urine disorders [3]. Leaves are also used in the management of leucorrhoea, fever, and acute gonorrhoea [3,4]. Leaves and stems are used for conjunctivitis and other eye-related disorders [6]. The stem is used for stomach disorders, dysentery, diarrhea, etc. It is also useful as a hypotensive, cardiogenic, and spasmolytic agent [6,7]. The current scientific literature advocates the hepatoprotective activity of CH leaf aqueous extract against bile duct ligation-induced liver necrosis [3,8]. In view of activities of CH reported in ayurvedic literature current study was carried out to investigate cardio-protective effect in experimental animals. Cardioprotective activities can be studied using validated experimental animals models. Goldblatt's pioneering work in 1934 established the first experimental animal (dogs) model of one-sided occlusion of the renal artery (2K1C model) [9], which was later replicated in rats and rabbits [10]. In animals like rats, rabbits, dogs, pigs, monkeys, and mice, partial blockage of the renal artery causes a significant increase in hypertension [10]. The studies advocated that rats develop experimental hypertension more easily than other animals by clipping and diet methods [9,10]. Clipping of the renal artery usually causes endothelial dysfunction, cardiac hypertrophy, and an associated increase in blood pressure [9]. Myocardial infarction (MI) can be induced in experimental animals to screen for the potential effect of the investigational compound. CAL has been shown in studies to induce MI and associated pathological changes in rats, which are similar to clinical MI caused by coronary artery occlusion [11]. The CAL leads to ventricular remodeling resulting in infarction expansion followed by the hypertrophy process. The main indicators used to assess MI are the transverse area of the cardiac myocyte directly related to the degree of cardiac hypertrophy [12]. Existing studies and data show that diet-induced hyperlipidemia develops coronary atherosclerosis and interferes with cardiac functioning. The induction of hyperlipidemia and associated cardiovascular complications can be studied using experimental animals [13]. Administration of high CD leads to hyperlipidemia characterized by raised levels cholesterol, triglycerides, and phospholipids. Hypercholesterolemia is a common complication of impaired or faulty clearance, as well as the liver's uncontrolled production of very low-density lipoprotein (VLDL) and low-density lipoprotein (LDL). Atherosclerosis leads to cardiovascular diseases, such as coronary heart disease [9–11]. The current pharmacotherapy of cardiovascular diseases mainly consists of calcium channel blockers, angiotensin converting enzyme inhibitors, statins, angiotensin receptor blockers, diuretics,  $\beta$ -blockers, etc. Chronic consumption of these drugs is associated with altered cardiac cell physiology and rhythm, palpitation, hypotension, disturbed electrolyte imbalance, lipid profile, etc. Given the limitations of current cardiovascular disease pharmacotherapy, there is a need to seek out promising alternatives with minimal side effects and maximum therapeutic potential. From all this background knowledge, the present investigation aimed to demonstrate the potential CH effect against acute renal hypertension, CAL, and hypercholesterolemia-induced cardiovascular changes in experimental animals and illustrate the possible underlying mechanism.

## 2. Materials and methods

### 2.1. Experimental animals

Biogen, Attibele, Bangalore, provided male Wistar rats weighing 250–400 g (110 numbers). Animals were kept in polypropylene cages in the standard laboratory conditions ( $25^{\circ}\text{C} \pm 2^{\circ}\text{C}$ ). The cycle of light and dark was maintained during the study. Pellet food and water were freely available to the animals. Prior permission was taken for animal experimentation from Institutional Animal Ethical

Committee (IAEC) of Nargund College of Pharmacy, Bangalore (IAEC/NCP/11/10).

### 2.2. Plant material

The plant, *C. hirsutus* (CH), was collected from the manganahalli hilly region of Bangalore. Dr. Shiddamallayya N. of the National Ayurveda Dietetics Research Institute in Bangalore certified the plant material. (SMPU/NADRI/BNG/2010-11/512).

### 2.3. Extraction methodology

About 1 kg of air-dried CH leaves were crushed and defatted with petroleum ether for 8 h in the soxhlet apparatus. Following filtering, the residue was extracted using the soxhlet apparatus with a series of solvents: petroleum ether, chloroform, ethanol, and methanol (40 cycles each). The leftover marc was macerated for seven days to yield the aqueous extract. The mixture was evaporated at  $60\text{--}70^{\circ}\text{C}$  under reduced pressure in a rotary evaporator. The manufactured product was allowed to air dry before being stored in a sealed container. In comparison to the dry starting material, the extract yield was 20%.

### 2.4. Preliminary phytochemical investigation

The preliminary phytochemical investigation of CH was carried out for secondary metabolites such as tannins, saponins, sterols, triterpenes, alkaloids, flavonoids, protein/amino acids, carbohydrates and glycosides etc.

### 2.5. Chemicals

The reagents and chemicals utilized in the experiments were of analytical grade and high purity. Cholesterol (SD fine-chem. Ltd), Cholic acid (LobaChemie Pvt. Ltd.), atorvastatin, and heparin vials (Sigma Life Science) (Gland Pharma Pvt. Ltd.) was used for the current study.

### 2.6. Acute oral toxicity study

An acute oral toxicity study for CH was performed according to Organization for Economic Co-operation and Development (OECD) guidelines - 423. Albino Wistar rats weighing between 150 and 200 gms were selected by a random sampling method. Each group had 6 animals and was kept fasted for 12 h with free access to water only. After fasting period animals were administered orally with test extract at a dose of 1000, 2000, 3000, 4000, and 5000 mg/kg. The mortality, behavioral changes, and normalized intake of food and water were monitored for the next 74 h [14].

### 2.7. Acute renal hypertension

The animals were anesthetized by IP injection of 1.25 gm/kg urethane and then operated to clip a bull-dog clamp (B-Martin) on the left renal artery, as described previously [15,16]. The renal artery was occluded for 3–4 h. The trachea was cannulated to a mechanical ventilator to provide artificial respiration (MQ 232INCO). A pressure transducer was fitted to a cannula in the left carotid artery to monitor systolic and diastolic blood pressure (T-301, Pt-2655). An external right jugular vein was cannulated to administer the CH i.v. (25 and 50 mg/kg). Cannulae were filled with heparinized saline solution to prevent blood clotting during cannulation. The renal arterial clip was removed once stable blood pressure measurements were achieved, causing the animals to develop hypertension. At the 0<sup>th</sup>, 5<sup>th</sup>, 15<sup>th</sup>, 30<sup>th</sup>, and 60<sup>th</sup> minutes,

the MABP was measured. The rats were placed into four groups, each with ten rats. The groups were as follows: the control group did not receive treatment; the vehicle group is subjected to acute hypertension and receives the vehicle. CH-1-treated animals were given a 14-day pre-treatment of CH 250 mg/kg (p.o.). On the 15th day, acute hypertension was induced and CH (25 mg/kg) was injected. i.v.; CH-2-treated animals were given a 14-day pre-treatment with CH 500 mg/kg (p.o.). Acute hypertension was induced on the 15th day, and CH (50 mg/kg) was given. i.v.

## 2.8. CAL

CAL was carried out by referring to the previously described methods [16,17]. Urethane 1.25 gm/kg was injected intraperitoneally to anesthetize the animals. The trachea was intubated (M Q 232 INCO) to allow artificial ventilation. A catheter placed into an external right jugular vein was used to give the test chemical. In the common left carotid artery, a pressure transducer was employed to assess peripheral blood pressure (T-301, pt-2655). The left thoracotomy at the fourth intercostal gap expanded the chest. The heart was exteriorized by mild pressure on the chest walls after the pericarp was opened, and a thin silk thread (Ethicon 1.5 metric, 4-0) attached to an atraumatic needle was put around the left coronary artery about 2–3 mm distant from its origin for subsequent ligation. The animal was ventilated with room air at a rate of 54 strokes per minute with a stroke volume of 1.5 ml/100 g body weight. The heart was then returned to its original location in the chest cavity. The test drug (25 and 50 mg/kg) or vehicle was delivered intravenously after an equilibration period of roughly 45 min. The left coronary artery was ligated for 5 min before being re-perfused for 30 min 5 min later. During coronary occlusion and reperfusion, the arterial mean blood pressure was first measured. During coronary occlusion and reperfusion, arrhythmias were examined for onset and the number of animals that developed ventricular tachycardia (VT) and premature ventricular systole (PVS). Histopathological investigations were performed on the myocardial segment. The animals were placed into four groups, each with ten animals. CAL was performed on the animals in the control group. The vehicle was used to administer CAL to the CAL group animals. For 7 days, the CAL + CH-1 group of animals received CH (250 mg/kg) p.o. three times a day. On the eighth day, they were operated on for CAL and given CH (25 mg/kg). The CH (500 mg/kg) p.o. was given to the i.v. CAL + CH-2 group animals three times a day for seven days. On the eighth day, they were operated for CAL and given CH (50 mg/kg) intravenously.

## 2.9. Cholesterol diet-induced hypercholesterolemia

The animals were divided into 5 groups, with 10 rats in each group. The control group received a normal diet; the CD group received a high CD; and the CD + Atorvastatin (Atr) group received a high CD followed by the administration of Atr (10 mg/kg) p.o. CD + CH-1 group animals received high CD followed by administration of CH (250 mg/kg) p. o. CD + CH-2 group animals received high CD followed by administration of CH (500 mg/kg) p. o. The treatment protocol was followed for 21 days, and the anti-atherosclerotic activity was assessed by arterial histopathology and biochemical estimation of blood for lipid profile and glucose levels on the 10th and 21st days, respectively. The high CD has a cholesterol content of 0.5% and a bile salt content of 0.125% [18].

## 2.10. Biochemical investigation

Blood was withdrawn on the 10th and 21st day from retro-orbital route and collected in the Eppendorf tube from all groups

of animals. The blood was allowed to coagulate and subjected to centrifugation for 10 min at 5000g. The serum was separated using micropipettes and estimation of total cholesterol, triglycerides, HDL, LDL, and glucose. The biochemical estimation was performed by the commercial kits (Precucgent Pinnacle Biotechnologies Ltd.) using an semi auto-analyzer. The estimations of lipid and glucose were performed as per the instructions provided by the manufacturer.

## 2.11. Antioxidant enzyme assay

The capacity to block the auto-oxidation of pyrogallol was linked to the measurement of SOD activity by assessing increases in absorbance at 420 nm [19]. Using H<sub>2</sub>O<sub>2</sub> as a substrate, the activity of catalase (CAT) was calculated. At 240 nm, the amount of H<sub>2</sub>O<sub>2</sub> breakdown was measured [20]. The amount of NADPH oxidized by glutathione measured at 340 nm. The oxidizing ability was used to calculate the glutathione peroxidase [20–22]. The GSH activity was evaluated by DTNB (5, 5'-dithiobis (2-nitrobenzoic acid)) reaction with thiol-containing molecules like GSH to produce 2-nitro-5-thiobenzoic acid and glutathione disulfide (GSSG). At a wavelength of 412 nm, spectrophotometer is used to assess the yellow-colored 2-nitro-5-thiobenzoic acid [22].

## 2.12. Statistical analysis

For statistical analysis, the graph-pad prism software was used (Version 9). The one-way analysis of variance (ANOVA) was used to assess the data, followed by Dunnet's multiple comparison tests.  $P < 0.05$  is regarded as significant and is denoted with \*. With  $n = 6/10$ , data are expressed as mean S.D.

## 3. Results

### 3.1. Acute oral toxicity study

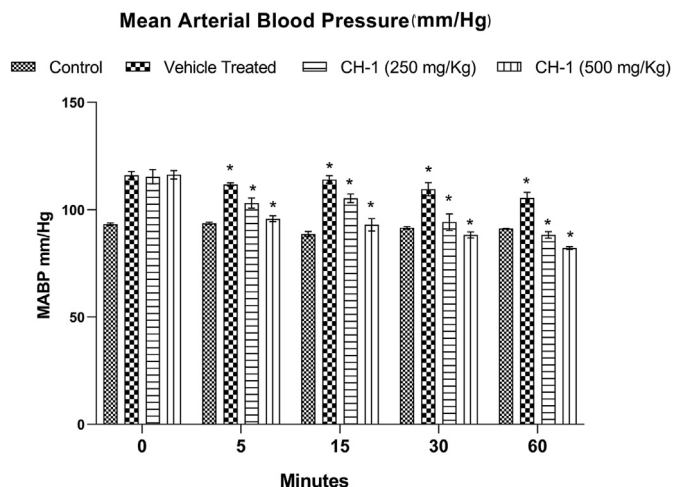
There were no behavioral abnormalities, toxic reactions, or mortality in animals given an ethanol extract of CH leaves. The extract was confirmed to be safe at a level of 5000 mg/kg.

### 3.2. Effect of CH on MABP in acute renal hypertension

At 0 min no significant change ( $P > 0.05$ ) in MABP was seen in any of the animal groups. When compared to a control group, animals treated with a vehicle show substantial increases ( $P < 0.05$ ) in MABP at the intervals of 5, 15, 30, and 60 min. When compared to vehicle-treated group CH-1 and CH-2 treated animals exhibit a significant decrease ( $P < 0.05$ ) in MABP at the time intervals of 5, 15, 30, and 60 min. A dose-dependent maximal reduction in MABP was seen at 60 min (Fig. 1).

### 3.3. Effect of CH on VT and PVS in CAL

No significant ( $P > 0.05$ ) delay in the onset/occurrence of VT and PVS in the vehicle-treated group and CAL group animals was observed. Animals treated with CH-1 and CH-2 shows significantly ( $P < 0.05$ ) reduced in the start of VT and PVS compared to vehicle treated animals. In animals treated with CH-2, protrusion was reduced at the commencement of VT and PVS. There was no significant difference ( $P > 0.05$ ) in the number of PVS in the vehicle-treated group compared to the CAL group during coronary ligation and reperfusion. When compared to vehicle-treated animals, animals given CH-1 and CH-2 have a significantly lower number of PVS after coronary ligation and reperfusion ( $P > 0.05$ ).



**Fig. 1.** Effect of CH on rat MABP in acute renal hypertension. Data were analyzed using one-way ANOVA and Dennett’s t-test. n = 10, \*P < 0.05 is considered as statistically significant. Comparison was made between CAL Vs CAL + Vehicle and CAL + Vehicle Vs CAL + CH-1(250 mg/kg)/CAL + CH-2 (500 mg/kg).

The CH-2 group animals saw the greatest reduction in PVS. At different times, all of the animals acquired VT and PVS (Table 1).

### 3.4. Effect of CH on MABP in CAL

Initially there was no significant difference (P > 0.05) in MABP between all groups. During coronary artery occlusion, a significant increase (P < 0.05) in MABP was observed in CH-2 treated animals when compared against CAL group animals. During reperfusion, a significant change (P < 0.05) in MABP was observed in CH-2 treated animals compared against CAL group animals. No significant (P > 0.05) change in MABP during coronary artery occlusion and reperfusion was noted in CH-1 treated animals when compared against CAL group animals (Table 2).

### 3.5. Effect of CH on lipid profile and glucose in CD

A significant increase (P < 0.05) in total cholesterol, triglyceride, LDL, and glucose levels was observed in the high CD group animals on the 10th and 21st days compared to control group animals. Animals treated with CH-1 and CH-2 showed significant decreases (P < 0.05) in total cholesterol, triglyceride, LDL and glucose levels on the 10th and 21st days compared to CD group animals. HDL is significantly increased (P < 0.05) in CH-1 and CH-2 treated animals. The effect of CH on the lipid profile and glucose level was found to be dose-dependent (Table 3).

**Table 1**  
Effect of CH on VT and PVS in CAL.

Groups	Arrhythmias				
	Onset of VT after CAL (sec)	Onset of PVS after CAL (sec)	% of animal developed VT	No. of PVS during coronary occlusion (5 min)	No. of PVS during reperfusion (30 min)
CAL	5.33 ± 0.88	11 ± 0.57	100%	103.33 ± 4.37	351 ± 5.56
CAL + vehicle	10.33 ± .88 <sup>ns</sup>	15 ± 1.73 <sup>ns</sup>	100%	93 ± 2.64 <sup>ns</sup>	329.66 ± 14.1*
CAL + CH-1	24.66 ± 1.45*	35 ± 1.15*	100%	59.0 ± 2.30*	96.33 ± 2.33*
CAL + CH-2	43.33 ± 2.40*	55.66 ± 0.33*	100%	44.33 ± 1.76*	68.33 ± 2.02*

Data were analyzed using one-way ANOVA and Dennett’s t-test. n = 10, \*P < 0.05 is considered statistically significant. Comparison was made between CAL Vs CAL + Vehicle, CAL + Vehicle Vs CAL + CH-1 (250 mg/kg)/CAL + CH-2 (500 mg/kg).

**Table 2**  
Effect of CH on MABP in CAL.

Groups	MABP (mmHg)		
	Initial	During coronary occlusion (5 min)	During reperfusion (30 min)
CAL	77.22 ± 0.40	92.97 ± 0.49	75.40 ± 5.92
CAL + vehicle	80.06 ± 7.37	99.04 ± 7.04	77.07 ± 8.21
CAL + CH-1	81.44 ± 0.58	126.77 ± 8.20 <sup>ns</sup>	101.27 ± 3.48*
CAL + CH-2	82.22 ± 3.71	139.61 ± 12.0*	145.44 ± 3.87*

Data were analyzed using one-way ANOVA and Dennett’s t-test. n = 10, \*P < 0.05 is considered statistically significant. Comparison was made between CAL Vs CAL + Vehicle, CAL + Vehicle Vs CAL + CH-1(250 mg/kg)/CAL + CH-2(500 mg/kg).

### 3.6. Effect of CH on antioxidant enzymes

The control group animals showed normal blood levels of antioxidant enzymes, whereas animals with CD died showed a significant decrease (P < 0.05) in antioxidant enzyme levels. Animals treated with CH-1 and CH-2 show significant (P < 0.05) restoration in antioxidant enzymes when compared with CD animals. The antioxidant potential of CH is dose-dependent (Table 4) and possesses due to the presence of flavonoids (Table 5).

### 3.7. Histopathological studies

#### 3.7.1. CH effect on myocardial section against CAL

The myocardium section of the CAL animal shows cardiac muscle with intervening fibrovascular septae, normal appearance of cardiocytes, intervening cardiocytes, and scant scattered inflammatory infiltration (Fig. 2-a). The myocardial section of CAL after 5 min shows cardiac muscle with intervening fibrovascular septae, abundant areas of coagulative necrosis, moderate inflammatory infiltration, and extravasation of erythrocytes due to damaged vascular spaces (Fig. 2-b). The myocardial section of CAL after 15 min shows cardiac muscle with intervening fibrovascular septae, areas of severe coagulative necrosis, moderate inflammatory infiltration, and thrombosed vascular spaces (Fig. 2-c). The myocardium section of the vehicle group animals shows cardiac muscle with an intervening fibrovascular septae, arbitral appearance of cardiocytes and coagulative necrosis. Adjacent to these cardiomyocyte thrombosed vascular spaces, moderate inflammatory infiltration was observed (Fig. 2-d). The myocardial section of CH-1 at 15 min after CAL shows cardiac muscle with intervening fibrovascular septae, almost intact arrangement of cardiocytes, mild coagulative necrosis, and inflammatory infiltration (Fig. 2-e). The myocardial section of CH-2 at 15 min after CAL shows cardiac muscle with intervening fibrovascular septae, intact arrangement of cardiocytes, absence of coagulative necrosis, and inflammatory infiltration (Fig. 2-f).

**Table 3**  
Effect of CH on rat lipid profile and glucose in high CD on days 10 and 21.

	Days	Control	CD	CD + Atr	CD + CH-1	CD + CH-2
Glucose	10	91.3 ± 6.7	126.2 ± 6.2*	86.0 ± 4.9*	96.5 ± 6.5*	85.0 ± 5.5*
	21	90.2 ± 3.2	159.5 ± 2.2*	121.3 ± 2.5*	107.0 ± 3.0*	94.0 ± 3.0*
Cholesterol	10	77.7 ± 1.4	119.0 ± 6.0*	75.6 ± 2.4*	82.5 ± 4.5*	76.0 ± 1.5*
	21	81.2 ± 0.8	162.3 ± 6.6*	102.3 ± 6.1*	107.5 ± 2.5*	102.0 ± 2.0*
Triglycerides	10	93.2 ± 0.8	130.1 ± 4.0*	99.5 ± 1.5*	105.5 ± 4.5*	102.0 ± 3.3*
	21	99.8 ± 0.9	180.0 ± 2.2*	128.6 ± 7.0*	119.0 ± 1.0*	111.5 ± 4.5*
HDL	10	49.1 ± 1.0	29.0 ± 2.0*	42.5 ± 1.5*	43.5 ± 1.50*	46.0 ± 2.0*
	21	53.8 ± 1.7	25.6 ± 1.29*	54.5 ± 0.5*	50.5 ± 0.5*	55.0 ± 3.0*
LDL	10	10.0 ± 0.50	64.5 ± 4.9*	13.2 ± 3.6*	23.5 ± 1.10*	14.9 ± 1.1*
	21	7.6 ± 1.1	101.2 ± 7.8*	21.8 ± 7.2*	35.5 ± 2.5*	26.6 ± 4.6*

Data were analyzed using one-way ANOVA and Dennett's t-test. n = 06, \*P < 0.05 is considered as statistically significant. Comparison was made between Control Vs CD and CD Vs CD + Atr/CD + CH-1(250 mg/kg)/CD + CH-2 (500 mg/kg).

**Table 4**  
Effect of CH on antioxidant enzymatic activity.

Group	SOD (U/mg of protein)	CAT (H <sub>2</sub> O <sub>2</sub> /min/mg protein)	GSH (μmol/g of protein)	GPx (nmol/mg of protein)
Control	8.97 ± 1.20	55.66 ± 2.20	6.90 ± 0.89	61.11 ± 2.05
CD	2.05 ± 0.34*	21.05 ± 2.53*	1.88 ± 0.55*	35.03 ± 3.29*
CD + CH-1	4.99 ± 0.62*	41.90 ± 3.12*	4.89 ± 1.11*	40.11 ± 2.55 <sup>ns</sup>
CD + CH-2	5.76 ± 0.86*	46.20 ± 2.50*	5.10 ± 1.28*	52.03 ± 3.89*

Data were analyzed using one-way ANOVA and Dennett's t-test. n = 06, \*P < 0.05 is considered as statistically significant. The comparison was made between Control Vs CD, CD Vs CD + CH-1(250 mg/kg)/CD + CH-2 (500 mg/kg) the experimental setup was repeated twice and all data were averaged.

**Table 5**  
Preliminary phytochemical investigation of CH extracts.

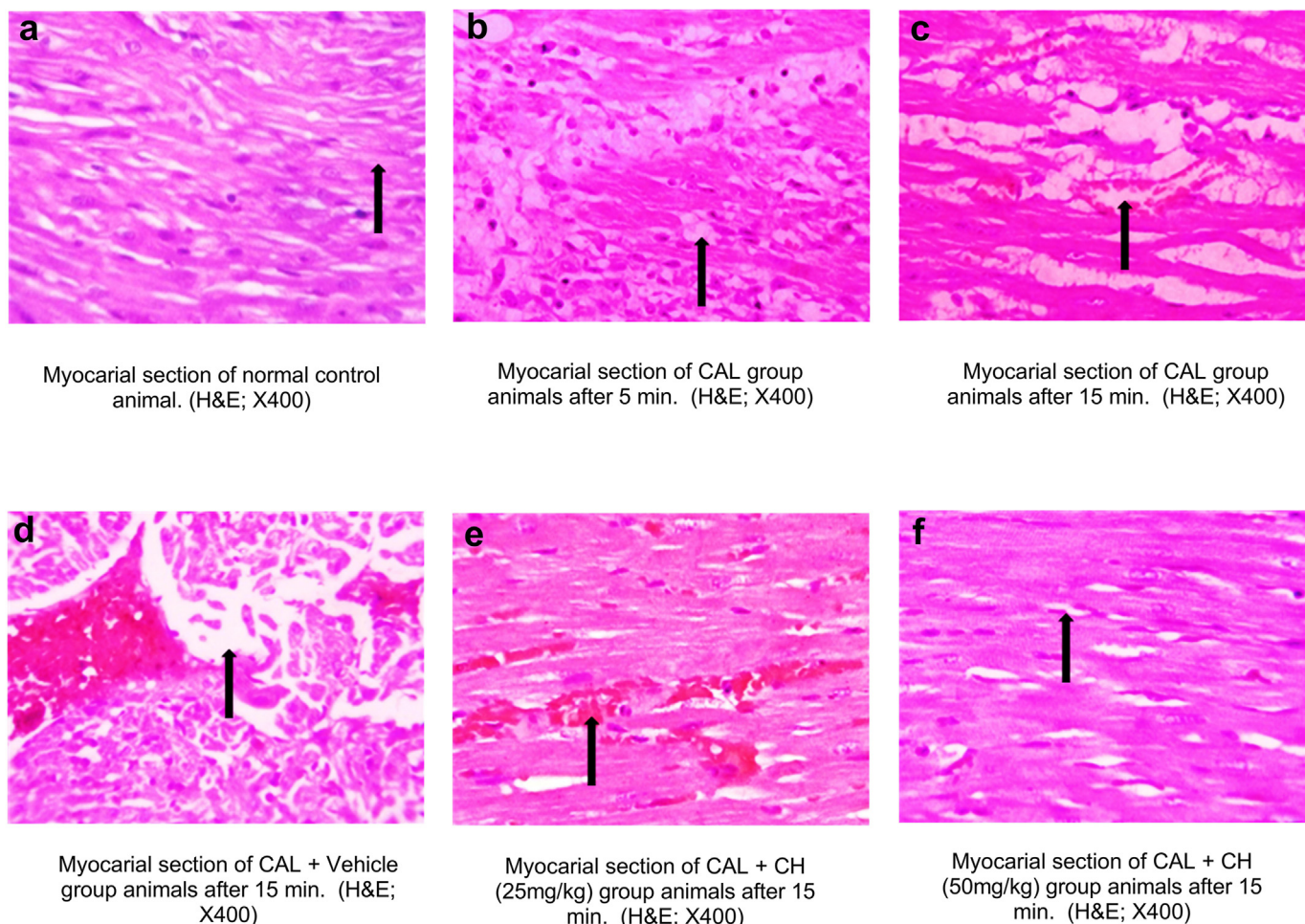
Solvents	Petroleum Ether	Chloroform	Ethanol	Methanol	Water
Test for Alkaloids					
Mayer's Test	+	+	+	-	-
Hager's Test	+	+	+	+	-
Wagner's Test	+	+	+	-	-
Test for Carbohydrate					
Molisch's Test	-	-	+	+	+
Fehling Test	-	-	-	-	-
Benedict's Test	-	-	-	-	-
Test for Steroids					
Salkowski Reaction	+	+	-	-	-
LiebermanBurchards Test	+	+	-	-	-
Test for Glycosides					
Cardiac Glycoside					
Baljet's Test	-	-	+	+	-
Keller-killiani Test	-	-	+	+	-
Anthraquinone Glycosides					
Brontrager's Test	+	+	-	-	-
Saponin Glycosides					
Foam Test	-	-	-	-	-
Test for Flavonoids					
Lead Acetate Test	-	-	+	+	+
Shinoda Test	-	-	+	+	+
Test for Fat and Oils					
Solubility Test	+	+	-	-	-
Filter Paper Test	+	+	-	-	-
Test for Tannin and Phenolic Compound					
Ferric Chloride Solution Test	-	-	+	+	+
Lead Acetate Solution Test	-	+	+	+	+
Bromine Water Test	-	+	+	+	+
Test for Protein					
Biuret Test	-	-	-	-	-
Test for Amino Acid					
Ninhydrin Test	-	-	-	-	-
Test for Gums and Mucilage's					
Hydrolyse Test (Gums)	-	-	-	-	-
Ruthenium Red Test (Mucilage)	-	-	-	-	-

### 3.7.2. CH effect on aortic section against hypercholesteremia

The aortic section of high CD animals on the 10th day shows the intact layers of the aorta except for disruption of the endothelial lining. Lipid containing elongated smooth muscle cells and foamy

macrophage aggregation was observed in the tunica intima and media with a thickness of 53.25 μm (Fig. 3-a). The aortic section of CD animals on the 21st day showed provoked hypercholesteremia and cholesterol clefts were observed with a thickness of tunica

### CH effect on myocardial section against CAL



**Fig. 2.** CH effect on myocardial section against CAL.

a. Myocardial section of normal control; b and c. Myocardial section of CAL after 5 and 15 min; d. Myocardial section of CAL + Vehicle; e. Myocardial section of CAL + CH-1 after 15 min; f. Myocardial section of CAL + CH-2 after 15 min.

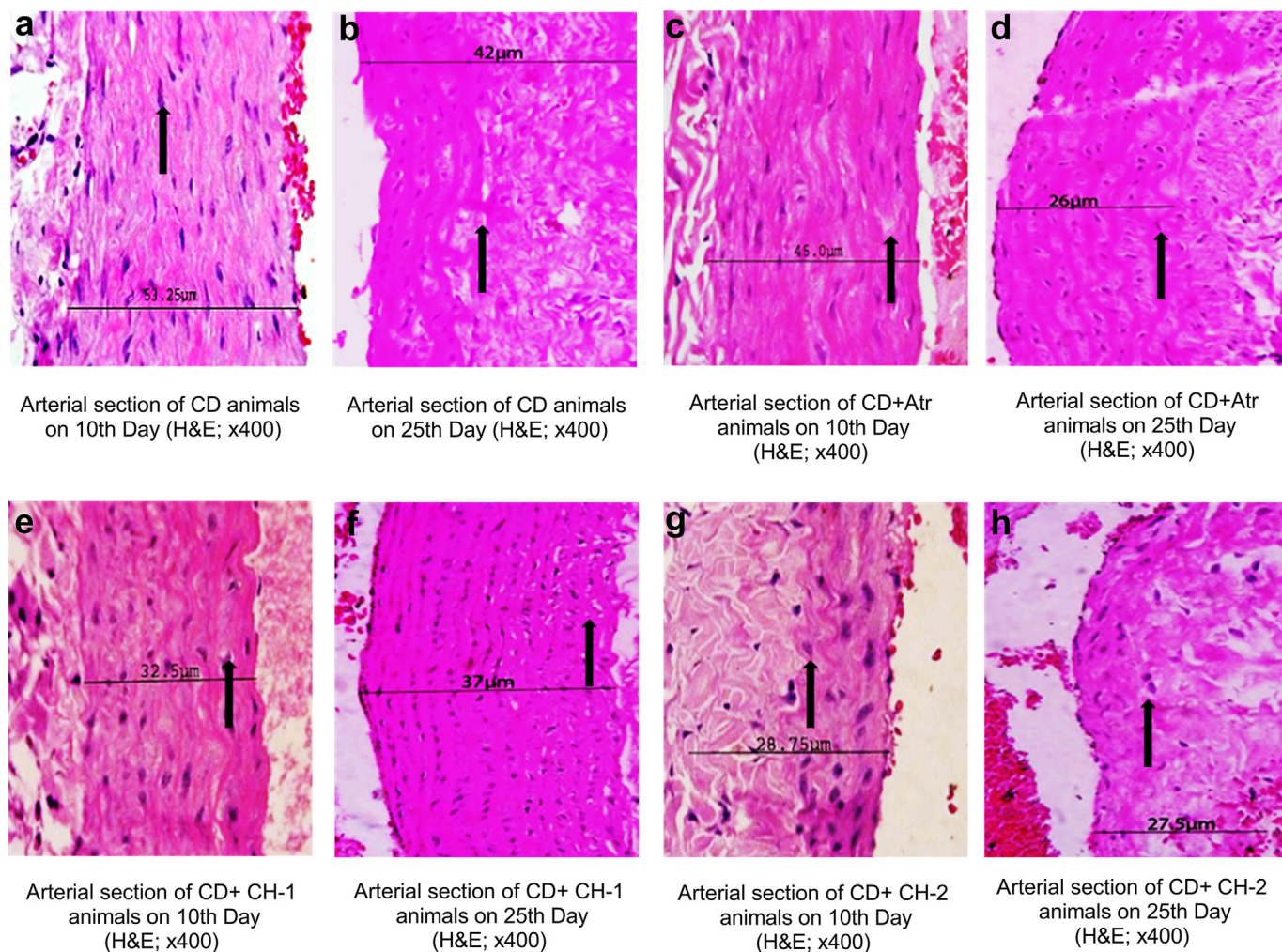
intima-media thickness of 42  $\mu\text{m}$  (Fig. 3-b). The aortic section of the high CD + Atr animal on the 10th and 21st days shows the intact appearance of layers of the artery. The tunica intima, tunica media, and tunica adventitia appear within normal limits. The tunica intima-media thickness was observed at 45  $\mu\text{m}$  and 26  $\mu\text{m}$  on days 10 and 21, respectively (Fig. 3-c and d). The aortic section of the high CD + CH-1 animal on the 10th day shows the intact appearance of layers of the artery. A few aggregates of lipid-containing spindle-shaped cells between the tunica intima and tunica media were observed. The tunica adventitia appears within normal limits (Fig. 3-e). On the 21st day few aggregates of foamy macrophages between the tunica intima and tunica media were observed (Fig. 3-f). The tunica intima-media thickness was observed at 32.5  $\mu\text{m}$  and 37  $\mu\text{m}$  on days 10 and 21, respectively (Fig. 3-e and f). The aortic section of high CD + CH-2 animals on the 10th and 21st day shows the intact appearance of layers of the artery. The tunica intima, tunica media, and tunica adventitia appear within normal limits. The tunica intima-media thickness was observed at 28.75  $\mu\text{m}$  and 27.5  $\mu\text{m}$  on days 10 and 21, respectively (Fig. 3-g and h).

#### 4. Discussion

Cardiovascular diseases (CVDs) are the leading cause of death globally. It was reported that about 17.9 million people died due to

CVDs in the year 2019, contributing to about 32% of all global deaths. The most important causes of death are heart attack and stroke, which prevail in developing and developed countries [22]. Raised systemic arterial pressures have been linked with augmented cardiovascular disease and mortality, including heart failure, myocardial infarction, and stroke [23]. The current pharmacotherapy deals to combat hypertension include drugs acting on the RAS (Renin-angiotensin system), anti-adrenergic, diuretics, calcium channel blockers, etc. The chronic treatment of these drugs is associated with severe side effects and themselves provokes the disease's conditions. The major side effects include hypotension, disturbed water-electrolyte balance, arrhythmia, sexual dysfunction, depression etc. [24,25]. Considering the same researchers is continuously searching for a better choice of drugs with greater efficacy and minimum side effects. Plant sources are always the centre of attraction and the researcher's box of mystic to search for new potent molecules for various clinical ailments, including CVDs [26]. Experimental hypertension in animals can be induced by several invasive and non-invasive methods. One of them demonstrating is acute renal occlusion-induced hypertension [10,16]. In addition 2 kidneys-1 clip hypertension model is also commonly used to produce acute hypertension in experimental animals. The renal damage and associated cardiac dysfunction depend on the duration of clipping and clip size. The stenosis of the renal artery

**CH Effect on aortic section against hypercholesteremia**



**Fig. 3.** CH Effect on aortic section against hypercholesteremia. a. Arterial section of CD on 10th day; b. Arterial section of CD on 25th day; c. Arterial section of CD + Atr on 10th day; d. Arterial section of CD + Atr on 25th day; e. Arterial section of CD + CH-1 on 10th day; f. Arterial section of CD + CH-1 on 25th day; g. Arterial section of CD + CH-2 on 10th day; h. Arterial section of CD + CH-2 on 25th day.

leads to cardiac hypertrophy, increases in cardiac size, hypertrophy of the kidneys, endothelial dysfunction, and increased systemic pressure [16]. In the 2K1C condition, the renin released into the renal vein from the collateral kidney causes elevated activity and demonstrates enhanced arterial pressure [27]. In the current investigation, an increase in blood pressure was noted in the animals operated on for acute renal occlusion. Whereas animals treated with CH showed significant reeducation in blood pressure when compared to untreated animals. The decrease in blood pressure may be due to CH ability to minimizing the rennin activity or its activation [3]. Ischemia and ventricular fibrillation can be produced in experimental animals by clamping the left coronary artery for 20 min followed by unclamping and reperfusion. The cardiac changes during reperfusion are observed, and mitigation of these changes indicates the efficacy of the test compound [28]. After ligation, the onset and number of occurrences of VT and PVS were observed in CAL animals during occlusion and reperfusion. The onset of acute MI is accompanied by an immediate increase in electrical unsteadiness and, in many cases, lethal VT [27,28]. Significant alterations in infarct size and histological changes have occurred following coronary occlusion [27–29]. The current study found that CH treatment delays the onset and number of VT and

PVS, although histological studies found the least amount of cardiocyte injury and necrosis. The current effect could be due to cardiotoxic activity of CH [3]. Hypercholesterolemia is a major contributor for the development and progression of atherosclerosis and is directly linked to CVD [18]. The modern lifestyle, reduced physical activity, and high cholesterol diet increases the risk of CVD. In hypercholesterolemia the lipid metabolic activities are greatly altered which contributes for atherosclerosis and CVD's [18]. Several studies have advocated that a reduction in total cholesterol and LDL will reduce atherosclerosis and further risk of hypercholesterolemia and CVD. A high cholesterol diet causes enhanced production of reactive oxygen species (ROS), and increased lipid peroxidation results in damage to important organs, including the cardiovascular system [30]. In the current study we found that high CD causes a significant increase in bad cholesterol and glucose levels while decreasing good cholesterol, arterial lumen narrowing, and subsequent atherosclerosis. The CH showed significant antilipidemic and antihyperglycemic activity in experimental animals. preliminary phytochemical studies have revealed that CH are high in steroids, alkaloids, glycosides, flavonoids, tannins, and saponins. The alkaloids like trilobine, isotrilobine, coclaurine, and magnoflorine and flavonoids, mainly rutin,

liquiritin, and quercetin, are responsible for CH's antidiabetic and antihyperlipidemic activity [3,31–33]. High cholesterol mostly harms the liver, owing to unregulated lipid metabolism and a disrupted natural antioxidant enzyme system (CAT, SOD, GSH, and GPx). Generally, the formed free radicals are eliminated through the antioxidant enzymes. However, the uncontrolled production of ROS leads to oxidative stress and associated organ damage. The pathological contribution of ROS has been extensively studied in diabetes, metabolic disorders, and associated cardiomyopathy [34]. The clinical benefits of antioxidant therapy in the manifestation of pathological progress of diseases like diabetes, atherosclerosis, and associated CVD have been successfully proposed [34]. The underlying mechanism of CH's protective effect could be free radical scavenging activity and the restoration of endogenous antioxidant enzyme. This further correlates with encountering the pathological contribution of ROS in CVD. Further study is needed to identify the specific components of CH that are responsible for the cardio-protective activity and to establish the molecular level mechanism.

## 5. Conclusion

From the current investigation, it is concluded that CH shows a significant cardio-protective effect in experimental hypertension-induced animals. CH treatment significantly reduces the MABP in acute renal hypertension and VT and PVS in CAL animals. CH treatment reduced glucose, cholesterol, LDL, and triglycerides while HDL is significantly increased. The histopathological investigation shows the prominent protective effect of CH on an aortic and myocardial section of the animal. The CH significantly restores the antioxidant enzyme activity as compared to the disease group. Further investigations are needed to explore the potent role of CH at the molecular level and its signaling mechanism.

## Funding

The current study was not funded by any government or non-government organization/Institution.

## Declaration of interest statement

None.

## Acknowledgments

The authors are thankful to the management of Nargund College of Pharmacy, Bangalore and ASPM's K. T. Patil College of Pharmacy, Osmanabad for providing the necessary facilities to carry out the research work.

## References

- [1] Jain S, Buttar HS, Chintameneni M, Kaur G. Prevention of cardiovascular diseases with anti-inflammatory and anti-oxidant nutraceuticals and herbal products: an overview of pre-clinical and clinical studies. *Recent Pat Inflamm Allergy Drug Discov* 2018;12(2):145–57.
- [2] Patwardhan B, Vaidya AD, Chorghade M. Ayurveda and natural products drug discovery. *Curr Sci* 2004;25:789–99.
- [3] Logesh R, Das N, Adhikari-Devkota A, Devkota HP. *Cocculus hirsutus* (L.) W. Theob. (Menispermaceae): a review on traditional uses, phytochemistry and pharmacological activities. *Medicine (Baltim)* 2020;7(11):69. <https://doi.org/10.3390/medicines7110069>.
- [4] Bedi SJ. Ethnobotany of the ratan mahal Hills, Gujarat, India. *Econ Bot* 1978 1;32(3):278–84.
- [5] Coelho-Ferreira M. Medicinal knowledge and plant utilization in an Amazonian coastal community of Marudá, Pará State (Brazil). *J Ethnopharmacol* 2009 29;126(1):159–75.
- [6] Hasan A, Shaown MS, Ripa RJ, Khatun A, Khan MA, Akter MS, et al. Ethno-medicinal plants of two villages in Natore district, Bangladesh. *Am-Eur J Sustain Agr*. 2013;7:282–9.
- [7] Hemadri K, Rao SS. Leucorrhoea and menorrhagia: Tribal medicine. *Ancient Sci Life* 1983;3(1):40.
- [8] Ahmad VU, Iqbal S. Haiderine, a new isoquinoline alkaloid from *Cocculus hirsutus*. *Nat Prod Lett* 1993 1;2(2):105–9. <https://doi.org/10.1080/10575639308043793>.
- [9] Goldblatt H, Lynch J, Hanzal RF, Summerville WW. Studies on experimental hypertension I. The production of persistent elevation of systolic blood pressure by means of renal ischemia. *J Exp Med* 1934;59(3):347–79. <https://doi.org/10.1084/jem.59.3.347>.
- [10] Pickering GW, Prinzmetal M. Experimental hypertension of renal origin in the rabbit. *Clin Sci* 1938;3(357):1937–8.
- [11] Selye H, Stone H. Pathogenesis of the cardiovascular and renal changes which usually accompany malignant hypertension. *J Urol* 1946;56(4):399–419. [https://doi.org/10.1016/S0022-5347\(17\)69823-9](https://doi.org/10.1016/S0022-5347(17)69823-9).
- [12] Shao MJ, Wang SR, Zhao MJ, Lv XL, Xu H, Li L, et al. The effects of velvet antler of deer on cardiac functions of rats with heart failure following myocardial infarction. *Evid base Compl Alternative Med* 2012. <https://doi.org/10.1155/2012/825056>.
- [13] Bai WW, Xing YF, Wang B, Lu XT, Wang YB, Sun YY, et al. Tongxinluo improves cardiac function and ameliorates ventricular remodeling in mice model of myocardial infarction through enhancing angiogenesis. Evidence-based complementary and alternative medicine. 2013. <https://doi.org/10.1155/2013/813247>.
- [14] Walum E. Acute oral toxicity. *Environ Health Perspect* 1998;106(2):497–503. <https://doi.org/10.1289/ehp.98106497>.
- [15] Badyal DK, Lata H, Dadhich AP. Animal models of hypertension and effect of drugs. *Indian J Pharmacol* 2003;35(6):349–62.
- [16] Vogel GH, Vogel WH, Scholkens BA, Sandows J, Muller G, Vogel WF. *Drug discovery & evaluation pharmacological assay*. 2nd ed. Berlin: Springer-Verlag Berlin Heidelberg; 2002. p. 217–8.
- [17] Clark C, Foreman MI, Kane KA, McDonald FM, Parratt JR. Coronary artery ligation in anesthetized rats as a method for the production of experimental dysrhythmias and for the determination of infarct size. *J Pharmacol Methods* 1980;3(4):357–68. [https://doi.org/10.1016/0160-5402\(80\)90077-7](https://doi.org/10.1016/0160-5402(80)90077-7).
- [18] Matos SL, Paula HD, Pedrosa ML, Santos RC, Oliveira EL, Chianca Júnior DA, et al. Dietary models for inducing hypercholesterolemia in rats. *Braz Arch Biol Technol* 2005;48:203–9. <https://doi.org/10.1590/S1516-89132005000200006>.
- [19] Nam JH, Jung HJ, Choi J, Lee KT, Park HJ. The anti-gastroprothemic and anti-rheumatic effect of niga-ichigosome F1 and 23-hydroxytropane acid isolated from the unripe fruits of *Rubus coreanus* in a rat model. *Biol Pharm Bull* 2006;29(5):967–70. <https://doi.org/10.1248/bpb.29.967>.
- [20] Umar S, Mishra NK, Pal K, Sajad M, Ansari MM, Ahmad S, et al. Protective effect of rutin in attenuation of collagen-induced arthritis in Wistar rat by inhibiting inflammation and oxidative stress. *Indian J Rheumatol* 2012;7(4):191–8. <https://doi.org/10.1016/j.injr.2012.09.001>.
- [21] Arulmozhi S, Mazumder PM, Sathiyarayanan L, Ashok P. Anti-arthritis and antioxidant activity of leaves of *Alstonia scholaris* Linn. R. Br. *European Journal of Integrative Medicine* 2011;3(2):83–90. <https://doi.org/10.1016/j.eujim.2011.04.019>.
- [22] Sarrafzadegan N, Mohammadifard N. Cardiovascular disease in Iran in the last 40 years: prevalence, mortality, morbidity, challenges and strategies for cardiovascular prevention. *Arch Iran Med* 2019;22(4):204–10.
- [23] Rosas-Peralta M, Jiménez-Genchi GM. New challenges for hypertension treatment. *Arch Med Res* 2018;49(8):548–57. <https://doi.org/10.1016/j.arcmed.2018.11.005>.
- [24] Olowofela AO, Isah AO. A profile of adverse effects of antihypertensive medicines in a tertiary care clinic in Nigeria. *Ann Afr Med* 2017;16(3):114. [https://doi.org/10.4103/aam.aam\\_6\\_17](https://doi.org/10.4103/aam.aam_6_17).
- [25] Husserli FE, Messerli FH. Adverse effects of antihypertensive drugs. *Drugs* 1981;22(3):188–210.
- [26] Kwan CY. Vascular effects of selected antihypertensive drugs derived from traditional medicinal herbs. *Clin Exp Pharmacol Physiol* 1995;22:297–9. <https://doi.org/10.1111/j.1440-1681.1995.tb02925.x>.
- [27] Textor SC. Renal arterial disease and hypertension. *Med Clin* 2017;101(1):65. <https://doi.org/10.1016/j.mcna.2016.08.010>.
- [28] Opitz CF, Mitchell GF, Pfeffer MA, Pfeffer JM. Arrhythmias and death after coronary artery occlusion in the rat: continuous telemetric ECG monitoring in conscious, untethered rats. *Circulation* 1995;92(2):253–61. <https://doi.org/10.1161/01.CIR.92.2.253>.
- [29] Abdelhalim MA. The potential influence of high cholesterol diet-induced oxidative stress on composition and properties of red blood cells in rabbits. *Afr J Microbiol Res* 2010;4(9):836–43. <https://doi.org/10.5897/AJMR.9000701>.
- [30] Panda N, Mishra B, Kar NR, Panigrahi SP, Dash RN, Gangopadhyay A. Phytochemical constituent and its pharmacological application of various Types of chemical compounds present in *Cocculus hirsutus* (L.) diels. *Journal of Positive School Psychology* 2022;6(8):992–1000.
- [31] Badole S, Patel N, Bodhankar S, Jain B, Bhardwaj S. Antihyperglycemic activity of aqueous extract of leaves of *Cocculus hirsutus* (L.) Diels in alloxan-induced diabetic mice. *Indian J Pharmacol* 2006;38(1):49–53.
- [32] Satyanarayana K, Mangathayaru V, Sreekanth J, Venkateswarlu V, Kokate CK. Studies on hypoglycemic and cardiotoxic effects of roots of *Cocculus hirsutus*. *Indian J Pharmaceut Sci* 2001;63(1):30–4.
- [33] Cai LU, Kang YJ. Oxidative stress and diabetic cardiomyopathy. *Cardiovasc Toxicol* 2001;1(3):181–93. CT:1:3:181.
- [34] Meagher E, Rader DJ. Antioxidant therapy and atherosclerosis: animal and human studies. *Trends Cardiovasc Med* 2001;11(3–4):162–5. [https://doi.org/10.1016/S1050-1738\(01\)00105-0](https://doi.org/10.1016/S1050-1738(01)00105-0).