

Case Report

DOI: 10.22114/ajem.v0i0.87

An Interesting Case of Isolated Pancreatic Transection Following Blunt Abdominal Trauma in Emergency DepartmentDevendra Richhariya^{1*}, Vivekanshu Verm^{1*}, Yatin Mehta²

1. Department of Emergency & Trauma Care, Medanta-The Medicity, Gurugram, India.

2. Institute of Critical Care & Anesthesiology, Medanta-The Medicity, Gurugram, India.

*Corresponding author: Devendra Richhariya; Email: drdev10@yahoo.in

Published online: 2018-04-30

Abstract

Introduction: Traumatic injury to the pancreas is not common, but if the diagnosis is delayed or misdiagnosed in the emergency department (ED), the condition is associated with high morbidity and mortality and raises a question about the quality of emergency care. Here, we describe a rare case of blunt abdominal trauma resulted in isolated pancreas injury.

Case presentation: A 25-year-old young male came to our emergency room (ER) in a conscious, anxious state from a nearby town with a history of roadside trauma. Further investigations revealed an isolated pancreatic injury due to trauma with no other major injuries, which occurred due to a sudden high-speed impact of the steering wheel to the epigastrium of a driver while driving the car, severely compressing the pancreas between the backbone and steering wheel. The patient was admitted to the intensive care unit for close observation and monitoring. He was managed conservatively on intravenous fluids, antibiotics, analgesics, and vasopressors. He was discharged after five days in a hemodynamically stable and afebrile condition, on a normal diet.

Conclusion: Isolated pancreatic injury following blunt abdominal trauma is rare, and the symptoms are difficult to analyze early due to its retroperitoneal anatomy. Early detection and early intervention are important in the ED, and if left unrecognized, could result in a poor outcome.

Key words: Case reports; Disease management; Pancreas; Wounds, nonpenetrating

Cite this article as: Richhariya D, Verm V, Mehta Y. An Interesting Case of Isolated Pancreatic Transection Following blunt Abdominal Trauma in Emergency Department. Adv J Emerg Med. 2018;2(4): e48.

INTRODUCTION

Traumatic injury to the pancreas can be due to blunt or penetrating trauma. Blunt trauma rarely causes isolated injury to the pancreas because of its retroperitoneal location and produces very minimal signs and symptoms which in turn makes the diagnosis a challenging task. Because misdiagnosis and delay in treatment may causes widespread inflammatory and hemorrhagic changes and worsens the situation and prognosis (1). Here, we describe a rare case of blunt abdominal trauma resulted in isolated pancreas injury.

CASE PRESENTATION

A 25-year-old young male came to our emergency department (ED) in a conscious, anxious state from a nearby town with a history of roadside trauma, a head-on collision while driving a car without wearing the seatbelt, one hour back. The patient complained of a headache, chest pain, and had a bleeding wound on the forehead. On general examination, the patient was conscious, oriented, cooperative, and slight restless, with a pale look.

His blood pressure (BP) was 90/60 mmHg, pulse rate (PR) 120/min, blood oxygen saturation 92%, respiratory rate (RR) 20/min, and capillary refill time was 2 seconds. There was no history of loss of consciousness, seizure, vomiting, or ear bleed.

Primary survey

A- Airway: It was patent and cervical spine protected; B- Breathing: There is not any distress and oxygen delivered via face mask; C- Circulation: Patient had hypotension and tachycardia, so one-liter bolus of normal saline administered intravenously; D- Disability: He was alert, moving all limbs; E- Exposure: reddish-blue discoloration over the epigastrium was seen, tenderness, and guarding present were also present.

Secondary Survey

Head: There was a lacerated bleeding wound (2^{cm} × 1^{cm} × scalp deep) on the forehead with pain and tenderness; Neck: There was not any tenderness and his power was 5/5 in all the four limbs; Chest: It was clear to auscultation bilaterally. there was tenderness in the lower chest. Heart

sounds of S1S2 were audible, and there were no additional sounds; Abdomen: There were multiple small round reddish-blue bruises in the epigastrium of diameter 2 cm, with underlying tenderness, guarding, and rigidity; Back: log roll examination was performed. No abnormalities detected; Limbs: there was an abrasion 2^{cm} × 1^{cm} on right hand.

Following differential diagnosis of the state of shock in the ED were considered: neurogenic shock, head injury due to rapid deceleration impact during a head-on collision; spinal shock, cervical spine injury due to rapid deceleration impact during a head-on collision; hemorrhagic shock, due to blunt chest trauma due to steering wheel impact injury.

Investigations

Blood Glucose = 136 mg/dl; arterial blood gases: pH = 7.35, pO₂ = 110, pCO₂ = 35, HCO₃ = 18; Hb = 11 gm%; Electrocardiogram (ECG) showed sinus tachycardia; bedside echocardiography showed no regional wall motion abnormalities, no tamponade, ejection fraction (EF) = 60%. Portable chest X-ray and pelvis X-ray showed no abnormalities. The whole body computed tomography (CT) trauma protocol was followed in view of the trauma with hypotension, that consists of a non-contrast head CT followed by a multi-detector CT that includes an intravenous, contrast-enhanced scan of the chest, abdomen, up to the pelvis. The findings of the whole body CT scan were as follows: no significant abnormality detected on noncontrast CT of the head and face, and whole-spine and contrast-enhanced chest CT; Whereas contrast-enhanced CT of abdomen showed hypodense linear area within the head and body of the pancreas with free fluid in the peri-pancreatic region and also in adjacent

retroperitoneum space suggestive of pancreatic transection with retroperitoneal hematoma (figure 1).

Course of treatment in the hospital

Given the above findings, the patient was admitted to the intensive care unit (ICU) by the gastrointestinal (GI) surgery team for close observation and monitoring. He was managed conservatively on intravenous fluids, antibiotics, analgesics, and vasopressors. The forehead wound was sutured, and it healed well. He showed gradual improvement and was shifted to the ward after two days. He was discharged after five days in a hemodynamically stable and afebrile condition, on a normal diet.

DISCUSSIONS

Blunt trauma to abdomen causes pancreatic injury in about 3%–5% cases. Most of the time, this happens in the young and sportsmen and during road traffic accident. Rarely, the pancreas gets injured by penetrating trauma, and the incidence is only 1%–2%. An isolated pancreatic transection is a rarest of the rare case to occur by sudden high-speed impact of steering wheel to the epigastrium while driving a car, compressing the pancreas between the backbone and steering wheel. Whatever the mechanism, isolated pancreatic injury is rare because the pancreas is surrounded by multiple susceptible structures (2). In this case, the direct impact to the epigastric region caused the neck of the pancreas to be crushed against the spine. Since the pancreas is a retroperitoneal structure, the signs and symptoms were minimum.

Ultrasound is not the investigation of choice in these patients, as liver and spleen injuries may be missed in 25% cases, and pancreatic mesenteric and gut injuries may be missed in almost all cases. The initial investigation of choice in these patients is a multidetector contrast-enhanced CT scan because of its high sensitivity and specificity (3). Peripancreatic hematoma, fluid in the lesser sac or retroperitoneum, and thickening of the anterior Gerota's fascia can be detected, and decision for surgical intervention can be taken early. The patient can be kept under close observation and managed conservatively only if a small contusion is present whereas peritonitis or hemodynamic instability are indications for immediate surgery (4).

The management also depends on the anatomic location of the injury, involvement of major duct, and extent of the parenchymal damage. Pancreatic injuries, if not treated early, are associated with a

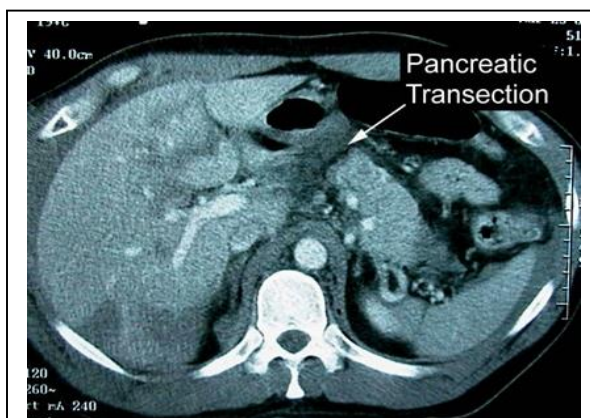


Figure 6: Axial contrast-enhanced computed tomography of patient's abdomen showing pancreatic transection with retroperitoneal hematoma

mortality rate of 15%–20%, mainly due to massive hemorrhage. Pseudocyst, fistula, or abscess sepsis is responsible for delayed mortality. A pancreatic neck injury may be associated with injuries to the portal vein, splenic vein, and inferior vena cava. Pancreatic duct injury must be carefully looked for. Pancreatic duct injuries can be evaluated by magnetic resonance cholangiopancreatography (MRCP) (5). The specific signs of pancreatic injury are a laceration, fluid separating the splenic vein from the pancreas, and transection or fracture. More than 50% of the pancreatic thickness is involved in deep lacerations (6).

CONCLUSIONS

Isolated pancreatic injury following blunt abdominal trauma is rare, and the symptoms are difficult to analyze early due to its retroperitoneal anatomy. Early detection and early intervention are important in the ED, and if left unrecognized, could result in a poor outcome.

REFERENCES

1. Lin BC, Chen RJ, Fang JF, Hsu YP, Kao YC, Kao JL. Management of blunt major pancreatic injury. *J Trauma*. 2004;56(4):774-8.
2. Subramanian A, Dente CJ, Feliciano DV. The management of pancreatic trauma in the modern era. *Surg Clin North Am*. 2007;87(6):1515-32, x.
3. Potoka DA, Gaines BA, Leppaniemi A, Peitzman AB. Management of blunt pancreatic trauma: what's new? *Eur J Trauma Emerg Surg*. 2015;41(3):239-50.
4. Olah A, Issekutz A, Haulik L, Makay R. Pancreatic transection from blunt abdominal trauma: early versus delayed diagnosis and surgical management. *Dig Surg*. 2003;20(5):408-14.
5. Laser A, Kufera JA, Bruns BR, Sliker CW, Tesoriero RB, Scalea TM, et al. Initial screening test for blunt cerebrovascular injury: Validity assessment of whole-body computed tomography. *Surgery*. 2015;158(3):627-35.
6. Richhariya D. *Textbook of Emergency & Trauma Care*. 1st ed: Jaypee Publishers; 2018.

ACKNOWLEDGMENTS

We acknowledge hard work of all the doctors and nursing staff of the Emergency and trauma care department of Medanta the Medicity Gurugram India. We express our thanks to staff who were involved in the management of these cases.

AUTHORS' CONTRIBUTION

All the authors fulfil the criteria of authorship based on the recommendations of the International Committee of Medical Journal Editors. Corresponding author is an Editor in Chief of Text book of Emergency & Trauma Care.

CONFLICTS OF INTEREST

The authors have no conflicts of interest to report. Any conflicts that the editor considers relevant to the content of the manuscript have been disclosed.

FUNDING

No funding from any source was received or used for this case report.