




Dosimetric Comparison of Helical Tomotherapy and Intensity-Modulated Proton Therapy in Hippocampus- and Scalp-Sparing Whole Brain Radiotherapy

Technology in Cancer Research & Treatment
Volume 20: 1-7
© The Author(s) 2021
Article reuse guidelines:
sagepub.com/journals-permissions
DOI: 10.1177/15330338211060170
journals.sagepub.com/home/tct


Taiki Takaoka, MD, PhD¹ , Natsuo Tomita, MD, PhD² ,
Tomoki Mizuno, MD², Shingo Hashimoto, MD, PhD²,
Takahiro Tsuchiya, RTT², Masashi Tomida, RTT¹,
and Takeshi Yanagi, MD, PhD¹

Abstract

Objective: Cognitive decline and alopecia after radiotherapy are challenging problems. We aimed to compare whole brain radiotherapy (WBRT) plans reducing radiation dose to the hippocampus and scalp between helical tomotherapy (HT) and intensity-modulated proton therapy (IMPT). **Methods:** We conducted a planning study of WBRT for 10 patients. The clinical target volume was defined as the whole brain excluding the hippocampus avoidance (HA) region. The prescribed dose was 30 Gy in 10 fractions to cover 95% of the target. Constraint goals were defined for the target and organs at risk (OAR). **Results:** Both techniques met the dose constraints for the target and OAR. However, the coverage of the target (dose covering 95% [D95%] and 98% [D98%] of the volume) were better in IMPT than HT (HT vs IMPT: D95%, 29.9 Gy vs 30.0 Gy, $P < .001$; D98%, 26.7 Gy vs 28.1 Gy, $P = .002$). The homogeneity and conformity of the target were also better in IMPT than HT (HT vs IMPT: homogeneity index, 1.50 vs 1.28, $P < .001$; conformity index, 1.30 vs 1.14, $P < .001$). IMPT reduced the D100% of the hippocampus by 59% (HT vs IMPT: 9.3 Gy vs 3.8 Gy, $P < .001$) and reduced the Dmean of the hippocampus by 37% (HT vs IMPT: 11.1 Gy vs 7.0 Gy, $P < .001$) compared with HT. The scalp IMPT reduced the percentage of the volume receiving at least 20 Gy (V20Gy) and V10Gy compared with HT (HT vs IMPT: V20Gy, 56.7% vs 6.6%, $P < .001$; V10Gy, 90.5% vs 37.1%, $P < .001$). **Conclusion:** Both techniques provided acceptable target dose coverage. Especially, IMPT achieved excellent hippocampus- and scalp-sparing. HA-WBRT using IMPT is a promising treatment to prevent cognitive decline and alopecia.

Keywords

IMPT, tomotherapy, alopecia, hippocampus, cognitive decline

Abbreviations

CI, conformity index; CT, computed tomography; CTV, clinical target volume; Dmax, maximum dose; Dmean, mean dose; DVH, dose-volume histogram; 95, 98, 100% dose to 2, 95, 98, 100% volume of the target or organs at risk; GTV, gross tumor volume; HA, hippocampus avoidance; HI, homogeneity index; HT, helical tomotherapy; IMPT, intensity-modulated proton therapy; IMRT, intensity-modulated radiation therapy; MRI, magnetic resonance imaging; OAR, organs at risk; PTV, planning target volume;

¹ Narita Memorial Proton Center, Toyohashi, Aichi, Japan

² Nagoya City University Graduate School of Medical Sciences, Nagoya, Aichi, Japan

Corresponding Author:

Natsuo Tomita, MD, PhD, Department of Radiology, Nagoya City University Graduate School of Medical Sciences, 1 Kawasumi, Mizuho-cho, Mizuho-ku, Nagoya, Aichi, 467-8601, Japan.

Email: c051728@yahoo.co.jp



QOL, quality of life; SRT, stereotactic radiation therapy; V10, 20, 24 Gy, percentage of the volume receiving at least 10, 20, 24 Gy; WBRT, whole brain radiotherapy.

Received: August 11, 2021; Revised: October 25, 2021; Accepted: October 27, 2021.

Introduction

Whole brain radiotherapy (WBRT) remains the standard treatment modality for patients with brain metastases because it palliates symptoms, improves intracranial control, and reduces central nervous system death.¹⁻³ However, 10 to 20% of patients with brain metastases after WBRT develop clinical cognitive decline. Advances in systemic chemotherapy including immunotherapy have prolonged the survival time of the patients with distant metastasis. Thus, cognitive decline due to WBRT is a serious problem.^{1,4-6} A prospective observational study of patients with benign or low-grade brain tumors treated with fractionated stereotactic radiation therapy (SRT) reported a relationship between dose to the bilateral hippocampi and likelihood of long-term memory impairment.⁷ To overcome this problem, a hippocampus avoidance (HA) technique for reducing the radiation dose to the hippocampus in WBRT has been developed.⁸ Intensity-modulated radiation therapy (IMRT) with HA technique delivers therapeutic doses to the whole brain (WB). NRG CC001, a prospective multi-institutional randomized phase III trial, investigated the role of WBRT plus memantine with or without HA technique in brain metastases to validate the hypothesis that conformal avoidance of the hippocampal neural stem cells using IMRT improves cognitive outcomes.⁹ HA-WBRT plus memantine preserved cognitive function and patient-reported symptoms, with no difference in intracranial control and survival time. Thus, HA-WBRT is a novel and promising treatment for brain metastases.

Radiation-induced alopecia after WBRT has a significant negative impact on patients' quality of life (QOL).^{10,11} A dose response relationship between the follicle and the occurrence of permanent alopecia after cranial irradiation was reported.¹² A recent study has provided new constraints for the scalp for IMRT that may help in reducing the probability of hair-loss.¹³ Helical tomotherapy (HT) is an excellent treatment for delivering IMRT.^{14,15} In recent years, proton therapy has gradually spread and intensity-modulated proton therapy (IMPT) enables an excellent dose distribution.¹⁶ Our hypothesis was that IMPT could achieve comparable target coverage and hippocampus- and scalp-avoidance compared with IMRT. To investigate this hypothesis, HA-WBRT plans using HT and IMPT were generated and a planning study comparing dosimetric data of the two techniques was conducted.

Methods

Patients

This study was approved by the institutional review board (Nagoya City University Hospital Ethics Committee, approval number: 60-21-0045), with waivers for informed consent. We selected 10

consecutive patients with brain metastases previously treated with SRT. They were not selected in any particular way that might influence the results of the study. All plans for this pilot study were not actual clinical treatment plans. This study conformed to the Strengthening the Reporting of Observational Studies in Epidemiology guidelines.¹⁷ We had de-identified patient information not to be ascertained in any way.

Treatment Volumes and Normal Structures

A shell was used for immobilization in a supine position. Computed tomography (CT) images were acquired with a 1.25 mm slice thickness. The patients underwent three-dimensional spoiled gradient-recalled axial magnetic resonance imaging (MRI) scans with axial T2-weighted and three-directional gadolinium contrast-enhanced T1-weighted sequence acquisitions with 1.0 mm slice thickness (thin-slice MRI). The CT simulation and MRI images were fused semi-automatically, and the target and the organs at risk (OAR) were contoured using the RayStation treatment planning system (RaySearch Medical Laboratories AB, Stockholm, Sweden).

The contouring and planning directives were generated based on the previous studies.^{8,9} The gross tumor volume (GTV) was not defined. The clinical target volume (CTV) included the WB parenchyma, subarachnoid space, meninges, and excluded the HA region. For both the HT and IMPT plans, no margin between CTV and the planning target volume (PTV) was defined. The hippocampus was manually contoured using fused thin-slice MRI. The HA region was defined with a 5-mm margin around the hippocampus. The scalp was defined as the tissue with thickness of 5 mm underlying the skin up to the outer of the skull. It was auto contoured expanding the head contour by 5 mm medially and the skull was subtracted. In general, scalp extends from the superior nuchal lines and occipital turbulences to the supraorbital foramen. Therefore, the forehead area was manually modified. The OAR included the hippocampus, scalp, chiasm, optic nerves, and eyes.

Prescribed Dose and Planning Goal

The prescribed dose was 30 Gy in 10 fractions to cover 95% of the WB target. The grid size for calculation was 2.0 × 2.0 mm for both plans. Dose-volume histogram (DVH) was used to reduce the dose to the OAR as low as achievable, while target coverage was maintained. IMPT plans were optimized assuming a relative biological effectiveness of 1.1 and the same goals for HT plans were used. The modified dose constraints of the NRG CC001 trial were used for this study

Table 1. Dose Constraints for Target and Organs at Risk.

Structure	Parameter	Constraint Goal
WB target	D98%	>25 Gy
	D95%	= 100%
	D2%	<37.5 Gy
Hippocampus	Dmax	<16 Gy
	D100%	<9 Gy
Scalp	V20Gy	<50%
	V10Gy	<80%
Optic nerves, chiasm	Dmax	<33 Gy
Eyes	Dmax	<33 Gy

Abbreviations: WB, whole brain; Dmax, maximum dose; D2%, D95%, D98%, D100%, dose to 2%, 95%, 98%, 100% volume of the target or organs at risk; V10, 20Gy, percentage of the volume receiving at least 10 or 20 Gy.

(Table 1).⁹ Deviations from the constraint goal were allowed for the dose constraint for the scalp. In addition, dose to 100% of the hippocampus (D100%) not exceeding 10 Gy and maximal hippocampal dose (Dmax) not exceeding 17 Gy were considered acceptable deviations according to a prior study.¹⁸

HT and IMPT Planning

HT plans were generated using a 6-MV X-ray beam machine dedicated to IMRT (Radixact X9, Accuray, Sunnyvale, USA). The superposition dose calculation algorithm was used in the treatment planning workstation (Precision, Accuray, Sunnyvale, USA). A field width, pitch, and normal modulation factor were 2.5 cm, 0.287, and 2.0, respectively.

IMPT plans were generated using a compact proton beam machine dedicated to pencil beam scanning. (Proteus® One, Ion Beam Applications S.A., Belgium). The Monte Carlo dose calculation algorithm was used in the RayStation. One noncoplanar and four coplanar beams were used considering the target coverage and the dose reductions of OARs. A setup robustness of ± 2 mm was used and the range uncertainty of $\pm 3.5\%$ was assumed. The methods of robust setting and worst-case evaluation were previously described in detail.¹⁶

Comparison of Dose-Volume Indices

The evaluated dosimetric parameters of the WB target were D2%, D95%, D98%, mean dose (Dmean), homogeneity index (HI), and conformity index (CI). The evaluated dosimetric parameters of all OARs were Dmax. In the analysis of hippocampus, D100% and Dmean were added. In the analysis of scalp, V20Gy (percentage of the volume receiving at least 20 Gy), V10Gy, and Dmean were added, respectively. HI was defined as a value calculating D1% divided by D99%.¹⁹ The definition of CI was previously described in detail.¹⁶ Differences of dosimetric parameters between the two techniques were analyzed by Student's t-test. Statistical analyses were carried out with EZR,²⁰ a graphical user interface for R Version 3.4.1 (The R Foundation for Statistical Computing, Vienna, Austria). $P < .05$ was considered to indicate a significant difference.

Results

Target Coverage, Homogeneity, and Conformity

The median volume of the WB target was 1486 cm³ (range, 1158-1601 cm³). The median volume of hippocampus, HA region, scalp was 3.95 cm³ (range, 2.50-4.37 cm³), 26.6 cm³ (range, 20.3-28.0 cm³), and 321 cm³ (range, 238-388 cm³), respectively. A representative example of dose distribution is shown in Figure 1. The results of quantitative analysis of the WB target in the two techniques are shown in Table 2. DVH comparison of the WB target between HT and IMPT is shown in Figure 2A. The D2% (HT vs IMPT: 35.2 ± 0.2 Gy vs 33.8 ± 0.91 Gy, $P = .001$), D95% (HT vs IMPT: 29.9 ± 0.07 Gy vs 30.0 ± 0.05 Gy, $P < .001$), D98% (HT vs IMPT: $26.7.1 \pm 0.95$ Gy vs 28.1 ± 0.34 Gy, $P = .002$) and Dmean (HT vs IMPT: 32.8 ± 0.13 Gy vs 32.0 ± 0.60 Gy, $P = .008$) were all significantly better in IMPT than HT. The HI (HT vs IMPT: 1.50 ± 0.07 vs 1.28 ± 0.05 , $P < .001$) and CI (HT vs IMPT: 1.30 ± 0.09 vs 1.14 ± 0.02 , $P < .001$) were significantly better in IMPT than HT.

OAR Sparing

The dose to the OAR of the two techniques is shown in Table 3. DVH comparison of the hippocampus (Figure 2B) and scalp (Figure 2C) between HT and IMPT is shown in Figure 2B and 2C. The D100% (HT vs IMPT: 9.3 ± 0.57 Gy vs $3.8 \pm$

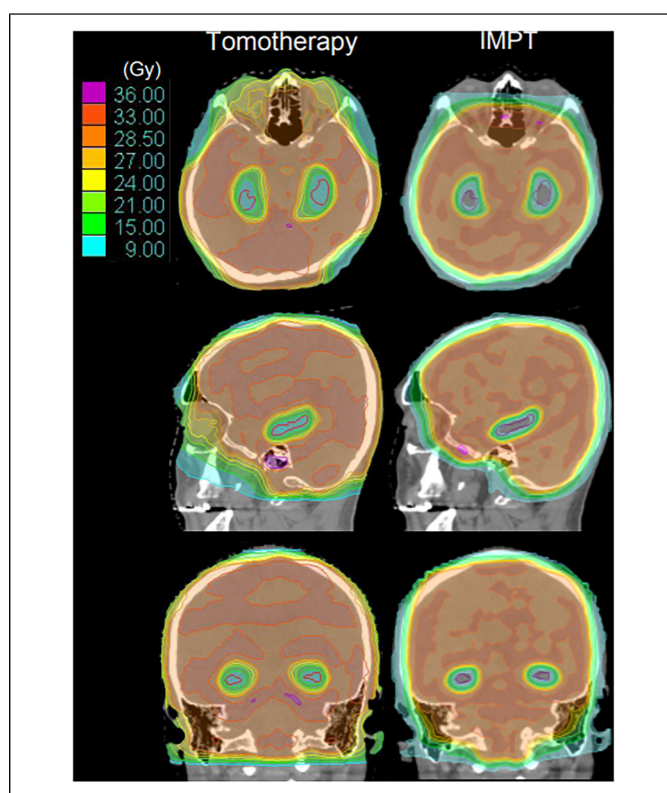


Figure 1. A representative example of dose distribution in the transverse, sagittal, and coronal planes.

0.41 Gy, $P < .001$) and Dmean (HT vs IMPT: 11.1 ± 0.51 Gy vs 7.0 ± 0.26 Gy, $P < .001$) of hippocampus were significantly reduced in IMPT compared with HT. The V20Gy (HT vs IMPT: $56.7 \pm 13.4\%$ vs $6.6 \pm 1.9\%$, $P < .001$), V10Gy (HT vs IMPT: $90.5 \pm 3.7\%$ vs $37.1 \pm 3.6\%$, $P < .001$) and Dmean (HT vs IMPT: 19.9 ± 1.9 Gy vs 10.0 ± 0.5 Gy, $P < .001$) of the scalp were significantly reduced in IMPT compared with HT.

Discussion

This was the first pilot study comparing IMRT and IMPT for HA-WBRT. WBRT is the standard treatment modality for patients with brain metastases. However, cognitive decline after WBRT is a serious problem. Clinical studies reported that a low radiation dose to the hippocampus induced cognitive decline.²¹ Radiation-induced cognitive decline was also confirmed *in vivo*.^{22,23} Although the mechanism of radiation-induced cognitive decline is complicated, apoptosis in the neurogenesis zone is considered an important cause.^{24,25} Single-dose radiation at 2 to 10 Gy induced dose-dependent apoptosis in the neurogenesis zone of the hippocampus *in vivo*.²⁵ Accordingly, reducing the low radiation dose to the hippocampus is essential to prevent cognitive decline. A phase II trial reported that HA-WBRT preserved memory function and QOL.¹⁸ A randomized phase III trial (NRG CC001)

demonstrated that HA-WBRT plus memantine (a neuroprotective agent) significantly reduced cognitive decline compared with WBRT plus memantine, while no differences were observed in intracranial progression-free survival and overall survival.⁹ In assessing organ at risk dose volume analysis score, per protocol and acceptable variation cases were 237 (91.5%) of the HA-WBRT plus memantine arm ($n = 261$). In contrast, a randomized phase III trial (NCT 01780675) did not demonstrate a reduction of cognitive decline between HA-WBRT and WBRT for prophylactic cranial irradiation of small cell lung cancer.²⁶ In NCT 01780675, a dose of 6 Gy to the hippocampus without neuroprotective agents may have been too high to prevent the neuron cell death. So far, the role of HA-WBRT using photons without neuroprotective agents in reducing cognitive decline is controversial. However, HA-WBRT has a potential to replace the standard technique of WBRT for brain metastases.

Proton therapy using pencil beam scanning improves the target coverage, homogeneity, conformity, and irradiated regions of normal tissues compared with IMRT and proton therapy using traditional passive scattering.²⁷ Furthermore, proton therapy reduces the radiation dose to normal tissues.²⁸ In the present study, D2%, D95%, D98%, Dmean, HI, and CI of the target were significantly improved in IMPT than HT. Moreover, the D100% and Dmean of the hippocampus were significantly reduced in IMPT (HT vs IMPT: D100%, 9.3 Gy vs 3.8 Gy, $P < .001$; Dmean, 11.1 Gy vs 7.0 Gy, $P < .001$). Thus, HA-WBRT using IMPT has a superiority of reducing low radiation dose to the hippocampus over HA-WBRT using HT. In the previous study, the Dmax of hippocampus was higher in 9-field IMRT than HT (HT vs IMRT: 12.8 Gy vs 15.3 Gy, $P = .001$).⁸ In the present study, the Dmax of hippocampus was slightly higher in IMPT than HT (HT vs IMPT: 14.7 Gy vs 15.4 Gy, $P = .013$). A similar tendency of Dmax was observed and the optimization in IMPT should be done carefully.

In recent years, the QOL of patients with cancer has been an increasing concern. Hair loss due to chemotherapy and radiotherapy has a significant negative impact on QOL, even if temporarily.^{29,30} Therefore, several studies were conducted to prevent radiation-induced alopecia. Although the tolerance

Table 2. Target Coverage, Homogeneity, and Conformity.

Parameter	HT		IMPT		P-value
	Mean	SD	Mean	SD	
D2% (Gy)	35.2	.42	33.8	.91	.001
D95% (Gy)	29.9	.07	30.0	.05	< .001
D98% (Gy)	26.7	.95	28.1	.34	.002
Dmean (Gy)	32.8	.13	32.0	.60	.008
HI	1.50	.07	1.28	.05	< .001
CI	1.30	.09	1.14	.02	< .001

Abbreviations: CI, conformity index; D2, D95%, D98%, dose to 2%, 95%, 98% volume of the target; Dmean, mean dose to the target; HI, homogeneity index; HT, helical tomotherapy; IMPT, intensity-modulated proton therapy; SD, standard deviation.

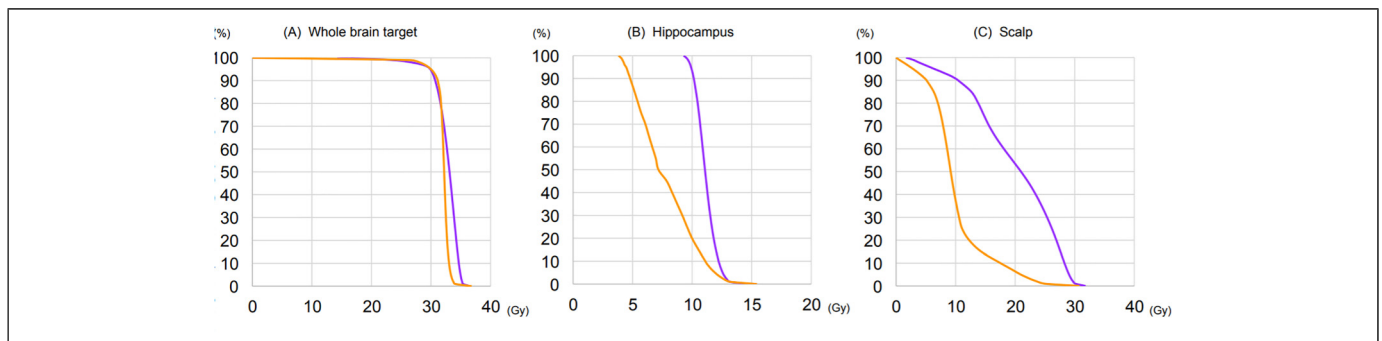


Figure 2. Purple lines represent helical tomotherapy. Orange lines represent intensity-modulated proton therapy. A: Dose-volume histogram of the whole brain target. B: Dose-volume histogram of the hippocampus. C: Dose-volume histogram of the scalp.

Table 3. Dose to Organs at Risk.

Structure Parameter	HT		IMPT		P-value	
	Mean	SD	Mean	SD		
Hippocampus	Dmax (Gy)	14.7	.67	15.4	.15	.013
	D100% (Gy)	9.3	.57	3.8	.41	<.001
	Dmean (Gy)	11.1	.51	7.0	.26	<.001
Scalp	Dmax (Gy)	31.7	1.7	30.8	2.0	<.001
	V20Gy (%)	56.7	13.4	6.6	1.9	<.001
	V10Gy (%)	90.5	3.7	37.1	3.6	<.001
	Dmean (Gy)	19.9	1.9	10.0	.5	<.001
Optic nerves	Dmax (Gy)	30.2	1.1	32.8	.2	<.001
Chiasm	Dmax (Gy)	31.8	1.2	32.8	.2	.029
Right eye	Dmax (Gy)	32.0	2.5	26.7	2.7	<.001
Left eye	Dmax (Gy)	31.8	2.3	26.7	2.7	<.001

Abbreviations: Dmax, maximum dose; Dmean, mean dose; D100%, dose to 100% volume of organs at risk; HT, helical tomotherapy; IMPT, intensity-modulated proton therapy; SD, standard deviation; V10, 20Gy, percentage of the volume receiving at least 10 or 20 Gy.

dose to the hair follicles was unclear, previous studies reported the estimated tolerance dose to the scalp for preventing alopecia. A dosimetric analysis of six patients preserving the hairs after WBRT using IMRT reported that the mean dose and V24Gy were 16.3 Gy and 9.0 cm³.³¹ Studies of scalp dose analysis related to WBRT were summarized in Table 4.³¹⁻³⁴ Although the DVH comparison among different studies should be done carefully because the definition of scalp was slightly different for each study, a mean dose of 10.0 Gy and V24Gy of 5.4 cm³ in HA-WBRT using IMPT were a favorable outcome. It was reported that skull thickness varies with age, and significant aging-related reduction of skull thickness was observed in females.³⁵ The reduction of skull thickness means the clinical target is more closed to the scalp. Scalp-sparing WBRT using IMPT may be more useful for elderly female patients. A psychological study demonstrated that chemotherapy-induced alopecia dramatically worsened QOL in women with breast cancer.³⁶ Considering this outcome, preventing radiation-induced alopecia may be meaningful for women with brain metastases from breast cancer. Also, the application to cranio-spinal treatment may be beneficial. Further studies are needed to establish which patients benefit the most by the use of scalp-sparing WBRT. In general,

Table 4. Studies of Scalp Dose Analysis Related to Whole Brain Radiotherapy.

Author	n	Pathology	Treatment	Prescribed Dose	Rate of Decrease in Scalp Dose
Mahadevan et al ³¹	6	metastases	11-field IMRT	30 Gy/10fxs	46%, mean dose 16.3 Gy
Mancini et al ³²	9	metastases	4-field IMRT	37.5 Gy/15fxs	62%, mean dose 14.3 Gy
			7-field IMRT		58%, mean dose 15.6 Gy
			13-field IMRT		61%, mean dose 14.5 Gy
Kao et al ³³	17	metastases	VMAT	37.5 Gy/15fxs	54%, mean dose 17.2 Gy
De Puyseleir et al ³⁴	10	metastases	3-field IMRT	20 Gy/5fxs	56%, mean dose 16.4 Gy
			VMAT		37%, mean dose 12.6 Gy

Abbreviations: IMRT, intensity-modulated radiation therapy; VMAT, volumetric-modulated arc therapy; fxs, fractions. Note: Rate of decrease in scalp dose was calculated by subtracting the prescribed dose with the scalp mean dose and then divided it with the prescribed dose.

proton therapy is not employed in palliative treatment at present; however, the benefit of keeping QOL should be considered in future treatment strategies.

This study had several limitations. First, it was a preliminary study and the number of cases was small. Second, the comparison among other IMRT techniques such as volumetric modulated arc therapy and fixed-field IMRT was not conducted. Third, the correlations between the dose constraints for hippocampus and scalp and the reductions of symptoms have not yet been fully proven.

Conclusions

In conclusion, both techniques provided acceptable target dose coverage with sufficient hippocampus- and scalp-sparing. Especially, HA-WBRT using IMPT is a promising treatment to prevent cognitive decline and alopecia. Additional dosimetric and clinical studies are required to prove the feasibility and efficacy of HA-WBRT using IMPT.

Ethics Statement

This study was performed after approval by the institutional review board of Nagoya City University Graduate School of Medical Sciences (approval number: 60-21-0045). The requirement for written informed consent was waived due to the retrospective nature of this study in line with the Ethical Guidelines for Medical and Health Research Involving Human Subjects in our country. Therefore, its content was disclosed in the form of opt-out on our website.

Ethics Statement

This study was approval by the institutional review board (Nagoya City University Hospital Ethics Committee, approval number: 60-21-0045), with waivers for informed consent according to the Ethical Guidelines for Medical and Health Research Involving Human Subjects in Japan. Instead of informed consent, we disclosed this study in the form of opt-out on our webpage.


Declaration of Conflicting Interests


The author(s) declared no potential conflicts of interest with respect to the research, authorship, and/or publication of this article.

Funding

The author(s) disclosed receipt of the following financial support for the research, authorship, and/or publication of this article: This work was supported by the Japan Society for the Promotion of Science (JSPS) KAKENHI (grant number Grant Number 19K08183).

ORCID iDs

Taiki Takaoka  <https://orcid.org/0000-0002-2667-8923>

Natsuo Tomita  <https://orcid.org/0000-0003-4601-0119>

References

- Brown PD, Ahluwalia MS, Khan OH, Asher AL, Wefel JS, Gondi V. Whole-brain radiotherapy for brain metastases: evolution or revolution? *J Clin Oncol*. 2018;36(5):483-491.
- Aoyama H, Shirato H, Tago M, et al. Stereotactic radiosurgery plus whole-brain radiation therapy versus stereotactic radiosurgery alone for treatment of brain metastases: a randomized controlled trial. *JAMA*. 2006;295(21):2483-2491.
- Aoyama H, Tago M, Shirato H, et al. Japanese radiation oncology study group I: stereotactic radiosurgery with or without whole-brain radiotherapy for brain metastases: secondary analysis of the JROSG 99-1 randomized clinical trial. *JAMA Oncol*. 2015;1(4):457-464.
- Kayama T, Sato S, Sakurada K, et al. Effects of surgery with salvage stereotactic radiosurgery versus surgery with whole-brain radiation therapy in patients with one to four brain metastases (JCOG0504): a phase III, noninferiority, randomized controlled trial. *J Clin Oncol*. 2018;36(33):3282-3289.
- Taphoorn MJ, Klein M. Cognitive deficits in adult patients with brain tumours. *Lancet Neurol*. 2004;3(3):159-168.
- Chang EL, Wefel JS, Hess KR, et al. Neurocognition in patients with brain metastases treated with radiosurgery or radiosurgery plus whole-brain irradiation: a randomised controlled trial. *Lancet Oncol*. 2009;10(11):1037-1044.
- Gondi V, Hermann BP, Mehta MP, Tome WA. Hippocampal dosimetry predicts neurocognitive function impairment after fractionated stereotactic radiotherapy for benign or low-grade adult brain tumors. *Int J Radiat Oncol Biol Phys*. 2012;83(4):e487-e493.
- Gondi V, Tolakanahalli R, Mehta MP, et al. Hippocampal-sparing whole-brain radiotherapy: a “how-to” technique using helical tomotherapy and linear accelerator-based intensity-modulated radiotherapy. *Int J Radiat Oncol Biol Phys*. 2010;78(4):1244-1252.
- Brown PD, Gondi V, Pugh S, et al. Hippocampal avoidance during whole-brain radiotherapy plus memantine for patients with brain metastases: phase III trial NRG oncology CC001. *J Clin Oncol*. 2020;38(10):1019-1029.
- Steinmann D, Paelecke-Habermann Y, Geinitz H, et al. Prospective evaluation of quality of life effects in patients undergoing palliative radiotherapy for brain metastases. *BMC Cancer*. 2012;12(283).
- Gerrard GE, Prestwich RJ, Edwards A, et al. Investigating the palliative efficacy of whole-brain radiotherapy for patients with multiple-brain metastases and poor prognostic features. *Clin Oncol (R Coll Radiol)*. 2003;15(7):422-428.
- Lawenda BD, Gagne HM, Gierga DP, et al. Permanent alopecia after cranial irradiation: dose-response relationship. *Int J Radiat Oncol Biol Phys*. 2004;60(3):879-887.
- Scoccianti S, Simontacchi G, Greto D, et al. Dosimetric predictors of acute and chronic alopecia in primary brain cancer patients treated with volumetric modulated arc therapy. *Front Oncol*. 2020;10:467.
- Ito M, Kodaira T, Tachibana H, et al. Clinical results of definitive chemoradiotherapy for cervical esophageal cancer: comparison of failure pattern and toxicities between intensity-modulated radiotherapy and 3-dimensional conformal radiotherapy. *Head Neck*. 2017;39(12):2406-2415.
- Tomita N, Kodaira T, Tachibana H, et al. A comparison of radiation treatment plans using IMRT with helical tomotherapy and 3D conformal radiotherapy for nasal natural killer/T-cell lymphoma. *Br J Radiol*. 2009;82(981):756-763.
- Mizuno T, Tomita N, Takaoka T, et al. Dosimetric comparison of helical tomotherapy, volumetric-modulated arc therapy, and intensity-modulated proton therapy for angiosarcoma of the scalp. *Technol Cancer Res Treat*. 2021;20, 15330338 20985866.
- von Elm E, Altman DG, Egger M, et al. The strengthening the reporting of observational studies in epidemiology (STROBE) statement: guidelines for reporting observational studies. *Ann Intern Med*. 2007;147(8):573-577.
- Gondi V, Pugh SL, Tome WA, et al. Preservation of memory with conformal avoidance of the hippocampal neural stem-cell compartment during whole-brain radiotherapy for brain metastases (RTOG 0933): a phase II multi-institutional trial. *J Clin Oncol*. 2014;32(34):3810-3816.
- Lee TF, Chao PJ, Wang CY, et al. Dosimetric comparison of helical tomotherapy and dynamic conformal arc therapy in stereotactic radiosurgery for vestibular schwannomas. *Med Dosim*. 2011;36(1):62-70.
- Kanda Y. Investigation of the freely available easy-to-use software ‘EZR’ for medical statistics. *Bone Marrow Transplant*. 2013;48(3):452-458.
- Monje ML, Mizumatsu S, Fike JR, et al. Irradiation induces neural precursor-cell dysfunction. *Nat Med*. 2002;8(9):955-962.
- Yoneoka Y, Satoh M, Akiyama K, Sano K, Fujii Y, Tanaka R. An experimental study of radiation-induced cognitive dysfunction in an adult rat model. *Br J Radiol*. 1999;72(864):1196-1201.
- Shi L, Linville MC, Iversen E, et al. Maintenance of white matter integrity in a rat model of radiation-induced cognitive impairment. *J Neurol Sci*. 2009;285(1-2):178-184.
- Rola R, Raber J, Rizk A, et al. Radiation-induced impairment of hippocampal neurogenesis is associated with cognitive deficits in young mice. *Exp Neurol*. 2004;188(2):316-330.
- Mizumatsu S, Monje ML, Morhardt DR, Rola R, Palmer TD, Fike JR. Extreme sensitivity of adult neurogenesis to low doses of X-irradiation. *Cancer Res*. 2003;63(14):4021-4027.
- Belderbos JSA, De Ruysscher DKM, De Jaeger K, et al. Phase 3 randomized trial of prophylactic cranial irradiation with or without hippocampus avoidance in SCLC (NCT01780675). *J Thorac Oncol*. 2021;16(5):840-849.

27. Iwata H, Toshito T, Hayashi K, et al. Proton therapy for non-squamous cell carcinoma of the head and neck: planning comparison and toxicity. *J Radiat Res.* 2019;60(5):612-621.
28. Hashimoto S, Shibamoto Y, Iwata H, et al. Whole-pelvic radiotherapy with spot-scanning proton beams for uterine cervical cancer: a planning study. *J Radiat Res.* 2016;57(5):524-532.
29. Freites-Martinez A, Chan D, Sibaud V, et al. Assessment of quality of life and treatment outcomes of patients with persistent postchemotherapy alopecia. *JAMA Dermatol.* 2019;155(6):724-728.
30. Bitterlich C, Vordermark D. Analysis of health-related quality of life in patients with brain tumors prior and subsequent to radiotherapy. *Oncol Lett.* 2017;14(2):1841-1846.
31. Mahadevan A, Sampson C, LaRosa S, et al. Dosimetric analysis of the alopecia preventing effect of hippocampus sparing whole brain radiation therapy. *Radiat Oncol.* 2015;10:245.
32. Mancini BR, Wilkinson JB, Kim LH, et al. Intensity-modulated radiation therapy or volumetric-modulated arc therapy to reduce alopecia, xerostomia, and otitis after whole brain radiation therapy for brain metastases: a planning analysis. *J Rad Oncol.* 2013;2(2):177-183.
33. Kao J, Darakchiev B, Conboy L, et al. Tumor directed, scalp sparing intensity modulated whole brain radiotherapy for brain metastases. *Technol Cancer Res Treat.* 2015;14:547-555.
34. De Puyssseleir A, Van De Velde J, Speleers B, et al. Hair-sparing whole brain radiotherapy with volumetric arc therapy in patients treated for brain metastases: dosimetric and clinical results of a phase II trial. *Radiat Oncol.* 2014;9:170.
35. Lillie EM, Urban JE, Lynch SK, Weaver AA, Stitzel JD. Evaluation of skull cortical thickness changes with age and sex from computed tomography scans. *J Bone Miner Res.* 2016;31(2):299-307.
36. Choi EK, Kim I-R, Chang O, et al. Impact of chemotherapy-induced alopecia distress on body image, psychosocial well-being, and depression in breast cancer patients. *Psychooncology.* 2014;23(10):1103-1110.