

ORIGINAL RESEARCH

Treatment of buccal mucosal carcinomas: A survey amongst head and neck surgeons in the Netherlands

Carleen M. E. M. Adriaansens MSc, MD  | Rob Noorlag MD, DDS, PhD |
Remco de Bree MD, PhD | Robert J. J. van Es MD, DDS, PhD

Department of Head and Neck Surgical
Oncology, University Medical Center Utrecht,
Utrecht, the Netherlands

Correspondence

Carleen M. E. M. Adriaansens, Department of
Head and Neck Surgical Oncology, University
Medical Center Utrecht, Heidelberglaan
100, 3584 CX Utrecht, the Netherlands.
Email: c.m.e.m.adriaansens-2@umcutrecht.nl

Funding information

KWF Kankerbestrijding, Grant/Award Number:
13577

[Correction added on June 9, 2023, after initial
online publication: Levels of Evidence have
been revised in this version.]

Abstract

Objective: Currently, there is no up-to-date guideline for the treatment of buccal mucosal squamous cell carcinoma (BMSCC) in the Netherlands. A questionnaire was used to investigate the opinions of Dutch head and neck surgeons on BMSCC of the cheek treatment.

Methods: A questionnaire was sent to all 91 head and neck surgeons in the Netherlands. Their opinions on surgical tumor-free margins, through-and-through defects, and indications for local adjuvant therapy were questioned.

Results: The response rate was 51%. To prevent a through-and-through defect, 67% of the surgeons would accept a deep clinical (macroscopic) margin of ≤ 5 mm. The less adverse histological characteristics a tumor has, the less consensus there is amongst the surgeons for local adjuvant treatment in case of close margins.

Conclusion: There is no consensus amongst Dutch head and neck surgeons about the optimal treatment for BMSCC of the cheek. There are different opinions on acceptable resection margins, indications for a through-and-through defect, and indications for adjuvant treatment. BMSCC of the cheek treatment should be more uniform and less surgeon dependent.

Level of evidence: N/A

KEYWORDS

buccal mucosal squamous cell carcinoma, head and neck surgeon, questionnaire, through-and-through defect, ultrasound

1 | INTRODUCTION

According to the tumor-nodes-metastasis (TNM) classification, the oral cavity can be subdivided into the buccal mucosa, the upper- and lower gum, the hard palate, the oral tongue, and the floor of mouth.¹ The buccal mucosal subsite can be further subdivided into the mucosa of the upper and lower lips, the cheek mucosa, the retromolar areas, and the upper and lower bucco-alveolar sulci.¹ Squamous cell

carcinoma of the buccal mucosa (BMSCC) is considered to be an aggressive tumor with a poorer prognosis compared to other oral subsites and with a relatively high locoregional failure rate.²⁻⁴

In patients with oral squamous cell carcinoma without lymph node metastasis, the most important prognostic factor is a tumor-free margin.⁵ According to the Royal College of Pathologists, histological tumor-free margins of < 1 mm are considered “involved”, 1–5 mm “close”, and > 5 mm “clear”.⁶ Involved margins are reported in

This is an open access article under the terms of the [Creative Commons Attribution-NonCommercial-NoDerivs](https://creativecommons.org/licenses/by-nc-nd/4.0/) License, which permits use and distribution in any medium, provided the original work is properly cited, the use is non-commercial and no modifications or adaptations are made.

© 2023 The Authors. *Laryngoscope Investigative Otolaryngology* published by Wiley Periodicals LLC on behalf of The Triological Society.

20%–41% of the BMSCC patients.^{7–10} Most of these involved margins are located in the deep resection plane.¹¹ This could be explained by the desire of the surgeon to preserve the facial skin and prevent an orocutaneous defect, or the attempt to prevent damage to facial nerves and muscles.⁵

The Netherlands has a long history of national guidelines for head and neck cancers. At this moment there is no specific guideline for the treatment of BMSCC.¹² The aim of this study is to gain more insight into the current BMSCC of the cheek treatment approaches in the Netherlands. Therefore, we created a questionnaire to investigate the opinion of Dutch head and neck surgeons about surgical tumor-free margins, through-and-through defects, and indications for local adjuvant therapy.

2 | MATERIALS AND METHODS

2.1 | Design

A cross-sectional study in all 14 Dutch centers for head and neck oncology was performed. An online questionnaire was developed with Microsoft Forms. The email addresses of all 91 head and neck surgeons in the Netherlands were obtained, and a link to the online questionnaire was sent by email. Institutional review board approval was not necessary for this research, because there were no patients involved.

2.2 | Questionnaire development and content

The questionnaire was developed by one research physician in collaboration with two maxillofacial surgeons, of which one specialized in head and neck oncology, and one otorhinolaryngologist specialized in head and neck oncology. Another two head and neck surgeons piloted the questionnaire. Based upon their comments the questionnaire was adjusted before it was sent to all head and neck surgeons in the Netherlands, being either maxillofacial surgeons or otorhinolaryngologists. The questionnaire was in Dutch and consisted of 23 questions (for the version translated to English: see Appendix S1). The following topics were discussed: the experience of the surgeon, the exposure to BMSCC of the cheek, their view on macroscopic- and microscopic margins, local adjuvant treatment indications, and the use of intraoperative ultrasound (US).

2.3 | Study group

The questionnaire was sent to obtain more information about the differences in surgical approach between head and neck surgeons in the Netherlands. All questions were related to BMSCCs of the cheek, unless otherwise stated. The surgeons had 2 months to fill out the questionnaire. Two reminders were sent to the non-responders within those 2 months. Liu et al. mentioned, head and neck surgeons should perform a minimum of 20 oral squamous cell carcinoma cases

yearly.¹³ Since 10% of these carcinomas is a BMSCC, surgeon volume was classified as <2 or ≥2 BMSCC of the cheek surgeries a year.^{14,15} Surgeon experience was classified categorically according to number of years since starting their head and neck oncology fellowship (<10 and ≥10 years), based on a surgeon experience study in colorectal surgery.¹⁶ The number of free flaps per center were divided into low to medium volume (0–30/year) and high volume (>30/year).¹⁷

2.4 | Data analysis

Differences within the group of responders were analyzed by a one-sample binomial test. The differences between years of experience, through-and-through defect hesitance, and the surgeon characteristics (background, years of experience, surgeon volume, or volume of free-flaps per center) were calculated with a Pearson chi-square, unless the expected count was <5, then a fisher's exact test was used. For calculating the difference in deep margin acceptance, a McNemar test was used. The answers from the questionnaire “hesitant to get a through-and-through defect due to morbidity and lower recurrence chance” and “hesitant to get a through-and-through defect due to morbidity and less morbidity after radiotherapy”, were combined to “hesitant to get a through-and-through defect due to morbidity”. The median and interquartile range (IQR) were noted. Results were considered significant if $p < .05$.

3 | RESULTS

The questionnaire was sent to 91 head and neck surgeons in all seven university medical centers (UMCs) and seven general hospitals (GHs) pursuing head and neck surgery in the Netherlands. Of these, 53 (58%) were otorhinolaryngologists, 37 (41%) maxillofacial surgeons, and 1 (1%) a general surgeon. There were 46 responses, resulting in a response rate of 51%. Significantly more maxillofacial head and neck surgeons ($n = 27$, 73%) responded, compared to otorhinolaryngologist head and neck surgeons ($n = 19$, 36%, $p = .01$). The response of one surgeon was missing to the questions about surgeon volume, number of BMSCC of the cheek cases treated yearly per center, and free flaps volume per center. Within the group of responders, there were no differences between years of experience and background (maxillofacial surgery or otorhinolaryngology; $p = .45$, Figure 1A), surgeon volume ($p = .09$, Figure 1B), or volume of free flaps per center per year ($p = .74$, Figure 1C). The maxillofacial head and neck surgeons estimated to operate on a median of 4.5 (IQR 4.8) patients with BMSCC of the cheek per surgeon per year and the otolaryngologist head and neck surgeons on a median of two (IQR 3.0) patients per surgeon per year, which would result in approximately 160 BMSCC of the cheek patients per year, in the group of responders. The head and neck surgeons in the UMCs and GHs reported that their departments have a median of 10 (IQR 13.3) and 5 (IQR 3.9) BMSCC of the cheek patients per center per year respectively, resulting in an estimated incidence of BMSCC of 7.5 patients per center per year and 105 patients in 14 centers.

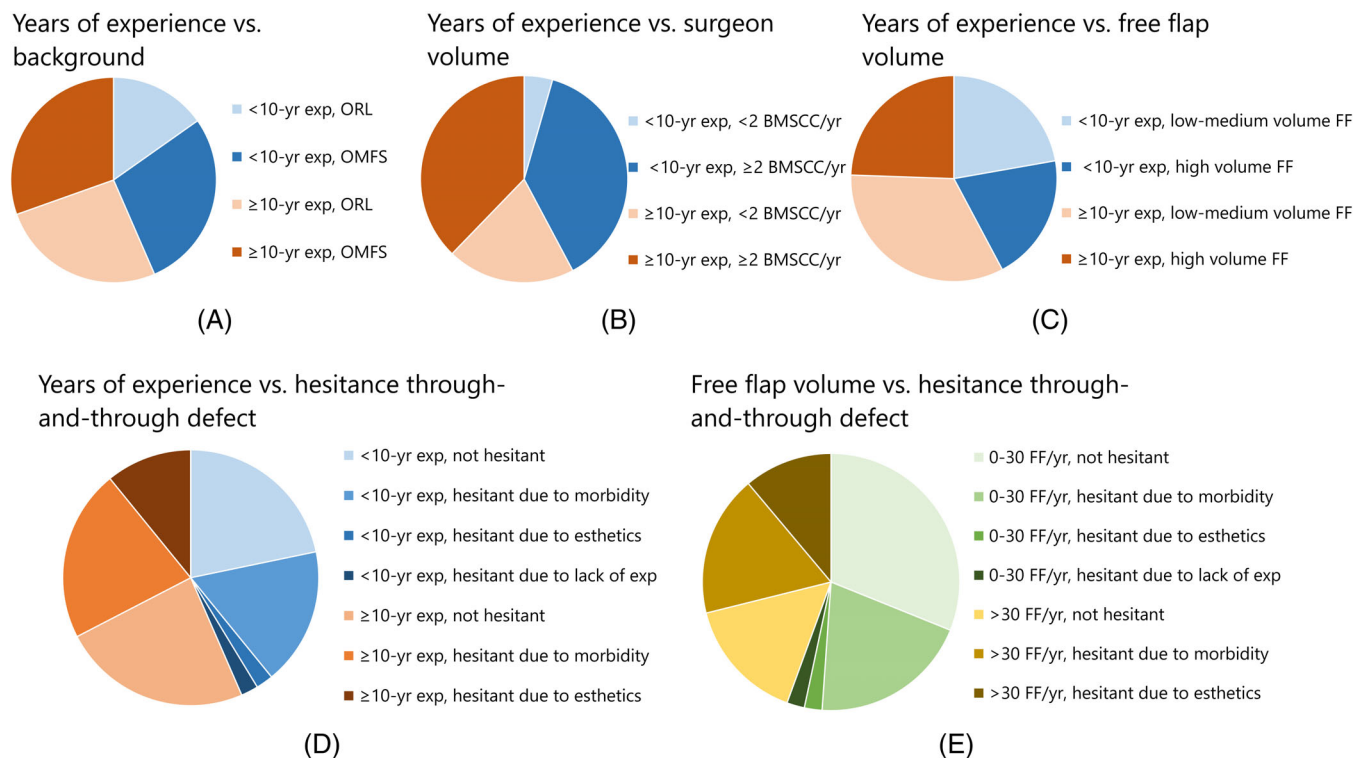


FIGURE 1 The blue shades indicate <10 years of experience, the orange shades indicate ≥10 years of experience as a head and neck surgeon (A–D). The green shades indicate 0–30 free flap reconstructions per center per year and the yellow shades indicate >30 free flap reconstructions per center per year (E). BMSCC, buccal mucosal squamous cell carcinoma; exp, experience; FF, free-flap; OMFS, oral maxillofacial surgeon; ORL, otorhinolaryngologist; vs, versus; yr, year.

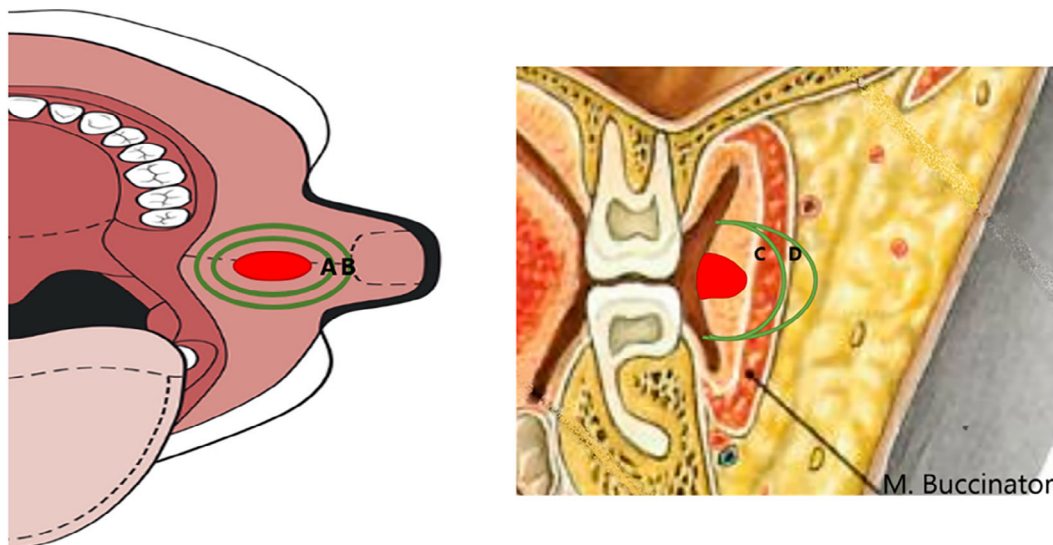


FIGURE 2 Case study 1: a 55-year-old woman with a proven BMSCC in her left cheek, presents herself to your outpatient clinic. She never smoked and drinks three glasses of alcohol a day. She classified as ASA2 by the anesthetist. On physical examination you see an ulcer in the left cheek, measuring 3 cm by 1.5 cm, separated from the jaw and sub cutis. The radiological tumor thickness is 4 mm. The distance from the tumor to the skin is estimated to be 15 mm. All surgical options were discussed preoperatively. A schematic illustration of the location and depth of invasion of this tumor (red dot) is shown. (A) Mucosal margin of 5 mm, or (B) mucosal margin of 10 mm. (C) Deep margin of 5 mm, into the m. buccinator, or (D) deep margin of 10 mm, through the m. buccinator.

When the head and neck surgeons were asked what clinical (macroscopic) tumor-free deep resection margin they would accept to prevent a through-and-through defect, 31 (67%) would accept a tumor-

free margin ≤5 mm, 6 (13%) accept a tumor-free margin between 6 and 9 mm, and 9 (20%) would make a through-and-through defect if the tumor-free margin would be <10 mm. To measure this tumor-free

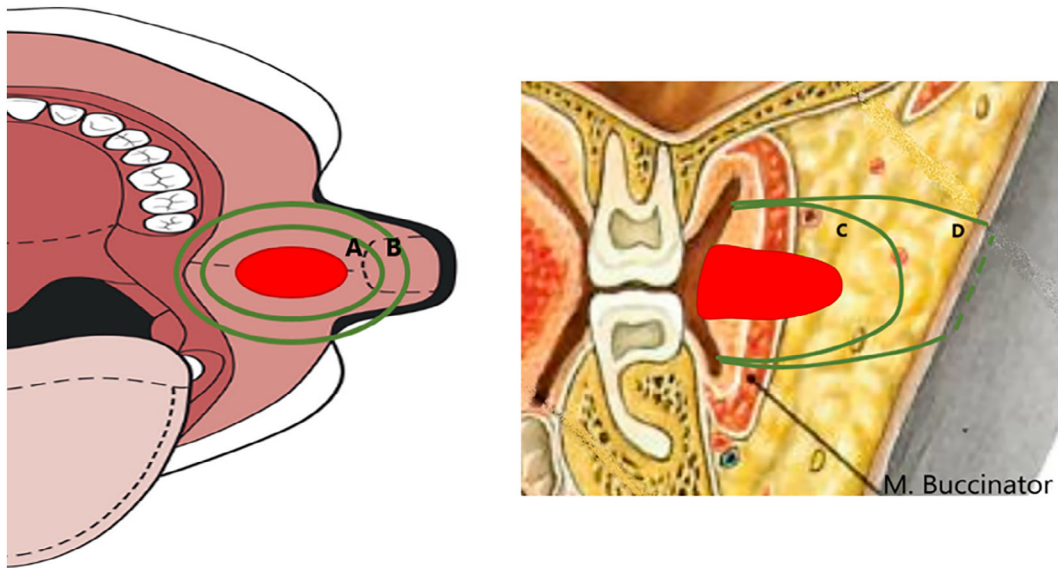


FIGURE 3 Case study 2: a 55-year-old woman with a proven BMSCC in her left cheek, presents herself to your outpatient clinic. She never smoked and drinks three glasses of alcohol a day. She classified as ASA2 by the anesthetist. On physical examination you see an ulcer in the left cheek, measuring 4 cm by 3 cm, separated from the jaw and sub cutis. The radiological tumor thickness is 13 mm. The distance from the tumor to the skin is estimated to be 8 mm. All surgical options were discussed preoperatively. A schematic illustration of the location and depth of invasion of this tumor (red dot) is shown. (A) mucosal margin of 5 mm, or (B) mucosal margin of 10 mm. (C) Deep margin of 5 mm, preserve skin, or (D) deep margin of 10 mm, through-and-through defect.

margin, 40 of the 46 (87%) surgeons would like to use intraoperative US. Thirty-five (76%) of the head and neck surgeons believe that >3 mm tissue layer is necessary to preserve the skin and prevent a through-and-through defect, while the other 11 (24%) surgeons believe that ≤ 3 mm tissue layer is sufficient between the skin and buccal defect. Of all surgeons, 25 (54%) would hesitate to make a through-and-through defect because of the associated high morbidity, worse esthetic outcomes, or lack of experience. Twenty-one (46%) surgeons said not to hesitate with making a through-and-through defect. Hesitant or not hesitant was not significantly associated with background ($p = .31$), the head and neck surgeon's years of experience ($p = .60$, Figure 1D), number of free-flaps per year ($p = .16$, Figure 1E), nor surgeon volume ($p = .43$).

The above-mentioned results were combined in two case studies (Figures 2 and 3).

Case study 1 described a BMSCC of the cheek cT2-tumor of 3×1.5 cm with a radiological distance to the skin of 15 mm and a radiological tumor thickness of 4 mm. Thirty-nine (85%) of the surgeons would resect the tumor with a mucosal margin of 10 mm and a deep margin of 10 mm. Six (13%) would go for a clinical (macroscopic) tumor-free margin of 5 mm at the deep resection plane in combination with 10 mm mucosal margins, and one (2%) would opt for a mucosal and deep margin of 5 mm.

Case study 2 was about a BMSCC of the cheek cT3-tumor of 4×3 cm with a radiological tumor thickness of 13 mm with a distance to the skin of 8 mm. Of the nine (20%) head and neck surgeons who would always make a through-and-through defect to obtain ≥ 10 mm macroscopic tumor-free margins, all choose to resect the tumor with 10 mm tumor-free margin, resulting in a through-and-

through defect. Furthermore, of the 31 (67%) head and neck surgeons who said they would accept a deep margin of ≤ 5 mm to prevent a through-and-through defect, 12 (39%) nevertheless choose to resect the tumor with 10 mm tumor-free margin and thus create a through-and-through defect (Table 1). Nine of these 12 surgeons wanted >3 mm tissue between the skin and the surgical defect, possibly explaining their choice for a through-and-through defect. Of the 35 surgeons who wanted >3 mm tissue layer between the skin and the defect, 17 (49%) choose for a 5 mm deep margin with thus ≤ 3 mm tissue between the defect and the skin (Table 1). Furthermore, three (7%) head and neck surgeons compromised (i.e., macroscopic <10 mm resection margin) both the mucosal and deep margins, 19 (41%) compromised only the deep margin, and none of the surgeons only compromised the mucosal margin. Of the 22 surgeons that compromised the deep margin, 4 (18%) initially said not to hesitate in making a through-and-through defect, 13 (59%) said to hesitate due to high morbidity, and 5 (23%) said to hesitate due to worse esthetic outcomes. When the results of case study 1 were compared to case study 2, significantly more head and neck surgeons accepted a clinical (macroscopic) tumor-free margin of 5 mm in the deep plane in case study 2, namely 22 of 46 (48%), compared to the seven of 46 (15%) in case study 1 ($p = .001$).

Moreover, in case of a BMSCC that grows into the sub cutis, 54.4% of the head and neck surgeon would do an immediate re-resection (without frozen section analysis) during the initial surgery if they suspect an involved deep margin, 32.6% would do frozen section analysis and depending on the result do a re-resection, 6.5% would wait for the definitive histological results and do a re-resection in a second operation, and 6.5% would wait

TABLE 1 Comparison of answers of head and neck surgeons on deep margins.

Separate questions ↓	The questions combined in case report 2		
	5 mm deep margin (3 mm tissue to skin remaining)	10 mm deep margin (creation through-and-through defect)	Total number of surgeons
Minimal macroscopic margin to prevent through-and-through defect			
≤5 mm	19	12	31
6–9 mm	3	3	6
≥10 mm	0	9	9
Minimal tissue between defect and skin			
≤3 mm	5	6	11
>3 mm	17	18	35

for the histological results and give postoperative radiotherapy in case of a definitive involved margin.

If a BMSCC grows at 2 mm from the mandibular alveolar border without bone invasion on preoperative radiology 67% would accept an inadequate margin and only remove the periosteum, and 33% would perform a marginal mandibular resection.

3.1 | Adjuvant treatment

All surgeons would give adjuvant treatment to a patient with a pT2 tumor without adverse histopathological features, if the histological margin proved to be involved (<1 mm). In case of close tumor-free margins, adjuvant therapy would be given by: 37 (80%) if ≤2 mm, 29 (63%) if ≤3 mm, 15 (33%) if ≤4 mm and 10 (22%) if <5 mm (median: margin of 3 mm, IQR: 2 mm). In case of a pT2 tumor with two adverse histopathological features, adjuvant therapy would be given by all surgeons in case of ≤2 mm tumor-free margin, 43 (93%) if ≤3 mm, 40 (87%) if ≤4 mm, and 37 (80%) if <5 mm (median: margin of 5 mm, IQR: 0).

4 | DISCUSSION

The incidence of oral cavity cancer in the Netherlands was 5.9/100.000 patients in 2022.¹⁸ Since 10% of the oral cavity carcinomas is a BMSCC, there are around 100 new patients with a BMSCC per year.^{14,15,19} The median incidence of BMSCC of the cheek estimated by head and neck surgeons was 7.5 patients per center. Since there are 14 centers, this would result in 105 new BMSCC of the cheek patients in the Netherlands per year, which is in line with the estimated incidence of 100 patients. If we assume that only the surgeons who operate on BMSCC patients responded, the number of operations on BMSCC of the cheek patients is still higher, namely 160 per year. This overestimation can only partially be explained by two surgeons operating on one patient, particularly in case of an extensive reconstruction. Another possibility could be the necessity for resections due to involved or close tumor-free margins. A recent retrospective study in our center showed involved margins in 38%, and

close tumor-free margins in 51% of the patients, resulting in a re-resection in 16.5% of the patients.²⁰ Furthermore, overestimation by the surgeons of the number of procedures they executed, could also play a role.²¹

When the results of case study 1 were compared to case study 2, significantly more head and neck surgeons accepted a clinical (macroscopic) tumor-free margin of 5 mm in the deep plane in case study 2, namely 48%, compared to 15% in case study 1 ($p = .001$), if the consequence of 10 mm tumor-free margin was a through-and-through defect. However, they would not reduce the mucosal margins. This indicates that in general, the head and neck surgeons are more likely to compromise the deep margin. Prior and during fixation of the specimen the tumor-free margins can shrink up to 21%–72%.^{5,9,22,23} Excessive shrinkage of BMSCC margins will probably lead to more “close” (1–5 mm) and “involved” (<1 mm) margins in the deep plane, because there was less surrounding tissue resected in the first place. This is in line with literature. Some authors even published deep margin involvement in up to 100% in BMSCCs.¹¹ However, the answers between head and neck surgeons, but also within one head and neck surgeon when faced with the choice for through-and-through defect varied, indicating that there is no clear indication when to create a through-and-through defect.

Our current guideline for adjuvant radiotherapy in oral carcinomas advises adjuvant treatment if there is an involved margin, and suggests considering it if three or more of the following characteristics are present: T3/4 tumor, close tumor-free margins, perineural growth, vascular invasion or non-cohesive growth. Close tumor-free margins are an arbitrary parameter and head and neck surgeons have different opinions about the need for adjuvant treatment considering close tumor-free margins. If there were no negative growth characteristics, the surgeons had different opinions on the minimal tumor-free margin to start adjuvant treatment (median: 3 mm margin, IQR: 2 mm). The head and neck surgeons were more conclusive about the minimal tumor-free margin to start adjuvant treatment when two negative growth characteristics were present (median: margin of 5 mm, IQR: 0).

The consideration whether or not to create a through-and-through defect of the cheek is not included in Dutch guidelines. There is only little information on clinical consequences of through-and-through defects considering morbidity and survival.²⁴ Some studies

investigated surgical techniques considering through-and-through defects in BMSCC related to either its resection or the reconstruction.^{3,25-27} However, most studies examined extensive defects and none investigated small through-and-through defects with only reconstruction of the inside of the cheek and primary closure of the outside skin.

The advised amount of tissue between the defect in the cheek and the skin is 3 mm, to preserve the subdermal plexus.²⁸ Liao et al., therefore made a through-and-through defect in case the distance between the skin and the tumor on imaging is <13 mm, which resulted in margins of ≤ 4 mm in only 11 of the 230 (5%) patients with skin excision, compared to 13 of the 101 (13%) patients without skin excision.²⁸ However, this was researched in a Areca nut chewing area and therefore, may not be representative for the western world since Areca nut related BMSCC is assumed to be a clinicopathological different type of disease.²⁹ Fifty-four percent of the Dutch head and

neck surgeons are reluctant to make a through-and-through defect. To optimize the balance between adequate resection margins and morbidity, an innovative surgical technique for BMSCC of the cheek removal is warranted.

US has the potential to aid in the surgical planning and resection of BMSCCs of the cheek and 87% of the surgeons would like to use intraoperative US.^{30,31} The deep border of the tumor can be visualized by US of the cheek's skin. There, the distance from the tumor-border to the skin can be measured and the area where this is less than 13 mm (10 mm tumor-free margin + 3 mm skin) can be drawn upon the skin of the cheek. The surgeon can slightly adjust the points, so the excision can be made along the relaxed facial tension lines to reduce postoperative scarring.³² The surgeon starts intraorally with the tumor resection, aiming for the points on the skin, and an intraoral US guides the resection.³⁰ In case of a cone shaped tumor, the created through-and-through defect may be smaller as compared to the

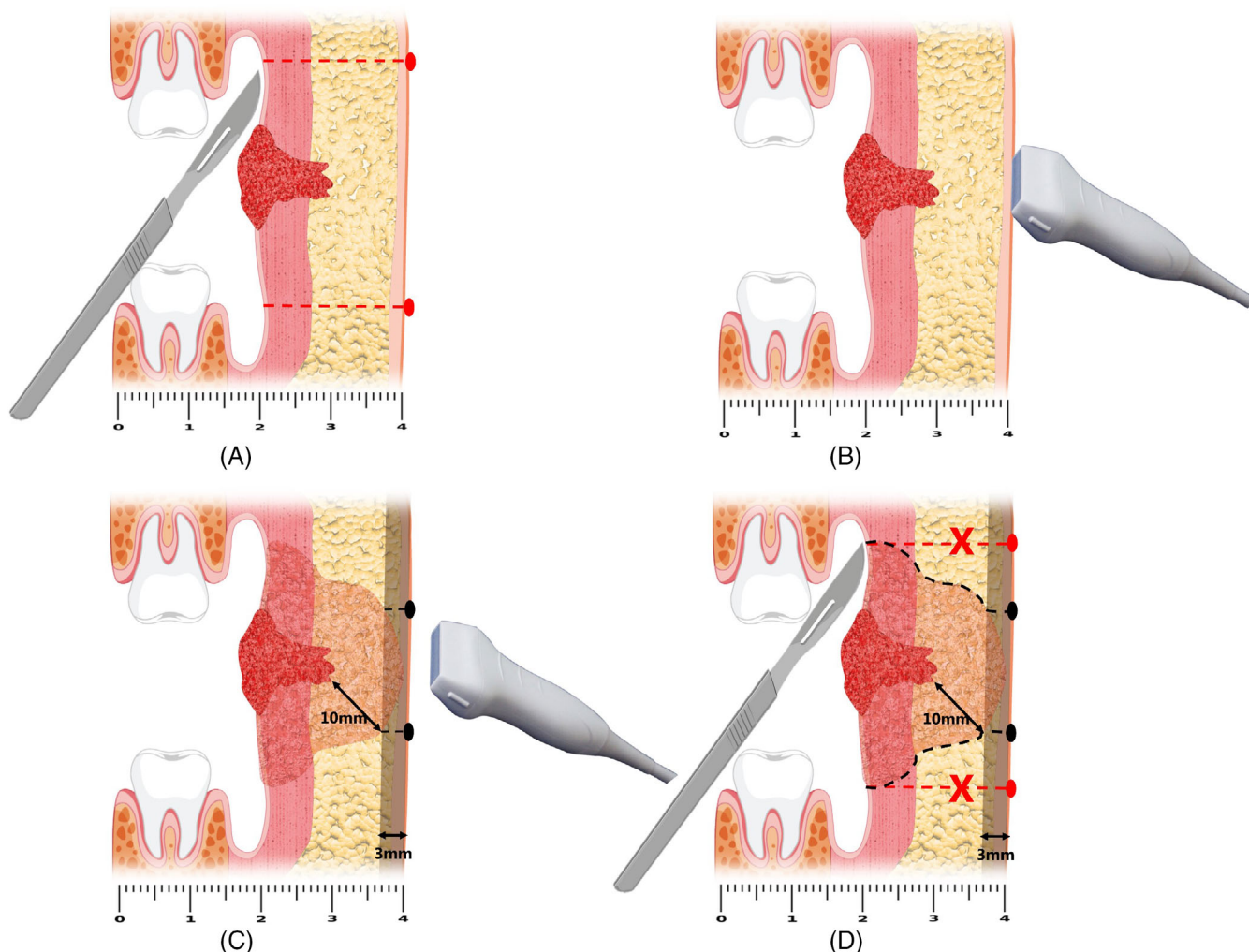


FIGURE 4 The current method for through-and-through defect creation resulting in extensive loss of skin, between the red dotted lines (A). The steps for through-and-through defect resection of a BMSCC of the cheek by the proposed theoretical surgical technique (B–D). First the BMSCC is identified by US on the skin of the cheek (B). Then, the points where the distance from the tumor to the skin is less than 13 mm are marked (C). Intraoperatively, the surgeon cuts towards these marks on the skin, black dotted lines (D). An intraoral US can guide the resection. BMSCC, buccal mucosa squamous cell carcinoma; US, ultrasound.

current through-and-through defect techniques,³³ since only the skin near the deepest point of invasion is resected. If the skin defect has a diameter of less than about 40 mm, primary closure can be considered,³⁴ particularly in the elderly population, due to the laxity of the aging cheek.³⁵ Any local flap can be considered if the skin defect is 3–6 cm.³² The intraoral defect can be closed with a local flap or free flap, depending on the size of the defect (Figure 4). This suggested US-guided surgical technique from both in- and outside the cheek, for the resection of BMSCC, may offer a more objective evaluation for through-and-through defect creation. However, there is no clinical data to support this technique yet.

5 | CONCLUSION

Based on a questionnaire amongst head and neck surgeons in the Netherlands, we conclude that there is no consensus about the best surgical treatment for BMSCC of the cheek. Head and neck surgeons have different opinions on acceptable clinical (macroscopic) tumor-free margins and different indications for either the creation of a through-and-through defect or adjuvant treatment. Information about morbidity after through-and-through defects and a guideline for the head and neck surgeon on how to treat BMSCC of the cheek is lacking.

ACKNOWLEDGMENTS

We would like to thank Johannes Rijken, head and neck surgeon at UMC Utrecht and Reinoud Klijn, head and neck surgeon at Medical Spectrum Twente for piloting and improving the questionnaire. We would also like to thank all the head and neck surgeons in the Netherlands who participated in this research by replying to the questionnaire.

FUNDING INFORMATION

This work was supported by KWF, the Dutch Cancer Society, grant number: 13577.

CONFLICT OF INTEREST STATEMENT

None declared.

ORCID

Carleen M. E. M. Adriaansens  <https://orcid.org/0000-0002-2577-5561>

REFERENCES

- Brierley JD, Gospodarowicz MK, Wittekind C. *Skin tumours. TNM Classification of Malignant Tumours*. John Wiley & Sons; 2017.
- Lin CS, Jen YM, Cheng MF, et al. Squamous cell carcinoma of the buccal mucosa: an aggressive cancer requiring multimodality treatment. *Head Neck*. 2006;28(2):150-157. doi:10.1002/hed.20303
- Ota Y, Aoki T, Karakida K, et al. Determination of deep surgical margin based on anatomical architecture for local control of squamous cell carcinoma of the buccal mucosa. *Oral Oncol*. 2009;45(7):605-609. doi:10.1016/j.oraloncology.2008.08.010
- Factor O, Su W, Lazarev S, et al. Rapid in-field failures following adjuvant radiation for buccal squamous cell carcinoma. *Laryngoscope*. 2020;130(2):413-417. doi:10.1002/lary.27996
- Kerker FA, Adler W, Brunner K, et al. Correction to: anatomical locations in the oral cavity where surgical resections of oral squamous cell carcinomas are associated with a close or positive margin—a retrospective study. *Clin Oral Investig*. 2018;22(4):1625–1630. *Clin Oral Investig*. 2019;23(1):509. doi:10.1007/s00784-018-2781-7
- Helliwell T, Woolgar JA. *Standards and minimum datasets for reporting common cancers. Minimum Dataset for Head and Neck Histopathology Reports*. The Royal College of Pathologists; 1998.
- Brinkman D, Callanan D, O'Shea R, Jawad H, Feeley L, Sheahan P. Impact of 3 mm margin on risk of recurrence and survival in oral cancer. *Oral Oncol*. 2020;110:104883. doi:10.1016/j.oraloncology.2020.104883
- Hakim SG, von Bialy R, Falougy M, et al. Impact of stratified resection margin classification on local tumor control and survival in patients with oral squamous cell carcinoma. *J Surg Oncol*. 2021;124(8):1284-1295. doi:10.1002/jso.26655
- El-Fol HA, Noman SA, Beheiri MG, Khalil AM, Kamel MM. Significance of post-resection tissue shrinkage on surgical margins of oral squamous cell carcinoma. *J Craniomaxillofac Surg*. 2015;43(4):475-482. doi:10.1016/j.jcms.2015.01.009
- Robinson EM, Lam AS, Solomon I, et al. Trends in positive surgical margins in cT1-T2 oral cavity squamous cell carcinoma. *Laryngoscope*. 2022;132(10):1962-1970. doi:10.1002/lary.30033
- Woolgar JA, Triantafyllou A. A histopathological appraisal of surgical margins in oral and oropharyngeal cancer resection specimens. *Oral Oncol*. 2005;41(10):1034-1043. doi:10.1016/j.oraloncology.2005.06.008
- Nederlandse vereniging voor Keel-Neus-Oorheekunde en Heelkunde van het Hoofd-Halsgebied. *Hoofd-halstumoren*. Richtlijndatabase; 2012.
- Liu T, David M, Ellis O, et al. Treatment for oral squamous cell carcinoma: impact of surgeon volume on survival. *Oral Oncol*. 2019;96:60-65. doi:10.1016/j.oraloncology.2019.06.030
- Jan JC, Hsu WH, Liu SA, et al. Prognostic factors in patients with buccal squamous cell carcinoma: 10-year experience. *J Oral Maxillofac Surg*. 2011;69(2):396-404. doi:10.1016/j.joms.2010.05.017
- Diaz EM, Holsinger FC, Zuniga ER, Roberts DB, Sorensen DM. Squamous cell carcinoma of the buccal mucosa: one institution's experience with 119 previously untreated patients. *Head Neck*. 2003;25(4):267-273. doi:10.1002/hed.10221
- Holm T, Johansson H, Cedermark B, Ekelund G, Rutqvist LE. Influence of hospital- and surgeon-related factors on outcome after treatment of rectal cancer with or without preoperative radiotherapy. *Br J Surg*. 1997;84(5):657-663. doi:10.1002/bjs.1800840520
- Lin CS, Lee HC, Lin CT, Lin HC. The association between surgeon case volume and hospitalization costs in free flap oral cancer reconstruction operations. *Plast Reconstr Surg*. 2008;122(1):133-139. doi:10.1097/PRS.0b013e3181773d71
- Integraal kankercentrum Nederland. 2023. <https://www.ikn.nl/nkr-cijfers>
- Camilon PR, Stokes WA, Fuller CW, Nguyen SA, Lentsch EJ. Does buccal cancer have worse prognosis than other oral cavity cancers? *Laryngoscope*. 2014;124(6):1386-1391. doi:10.1002/lary.24496
- Adriaansens CMEM, Noorlag R, Visscher WP, de Bree R, Breimer GE, van Es RJJ. A closer look at the resection margins of buccal mucosa cancer: their influence on local recurrence free survival. *Head Neck*. 2023;45:983-992. doi:10.1002/hed.27322
- Bengtson BP. Complications, reoperations, and revisions in breast augmentation. *Clin Plast Surg*. 2009;36(1):139-156. doi:10.1016/j.cps.2008.08.002
- Mistry RC, Qureshi SS, Kumaran C. Post-resection mucosal margin shrinkage in oral cancer: quantification and significance. *J Surg Oncol*. 2005;91(2):131-133. doi:10.1002/jso.20285

23. Cheng A, Cox D, Schmidt BL. Oral squamous cell carcinoma margin discrepancy after resection and pathologic processing. *J Oral Maxillofac Surg*. 2008;66(3):523-529. doi:10.1016/j.joms.2007.08.040
24. Deconde A, Miller ME, Palla B, et al. Squamous cell carcinoma of buccal mucosa: a 40-year review. *Am J Otolaryngol Head Neck Med Surg*. 2012;33(6):673-677. doi:10.1016/j.amjoto.2012.04.006
25. Yokoo S, Tahara S, Tsuji Y, et al. Functional and aesthetic reconstruction of full-thickness cheek, oral commissure and vermilion. *J Craniomaxillofac Surg*. 2001;29(6):344-350. doi:10.1054/jcms.2001.0249
26. Chen WL, Wang Y, Zhou B, Liao JK, Chen R. Comparison of the reconstruction of through-and-through cheek defects involving the labial commissure following tumor resection using four types of local and pedicle flaps. *Head Face Med*. 2019;15(1):12. doi:10.1186/s13005-019-0196-6
27. Song D, Li Z, Zhou X, et al. Effectiveness of bipaddled anterolateral thigh perforator flap in repair of through-and-through maxillofacial defect after oral cancer ablation. *Zhongguo Xiu Fu Chong Jian Wai Ke Za Zhi*. 2018;32(5):607-611. doi:10.7507/1002-1892.201708110
28. Liao CT, Huang SF, Chen IH, et al. When does skin excision allow the achievement of an adequate local control rate in patients with squamous cell carcinoma involving the buccal mucosa? *Ann Surg Oncol*. 2008;15(8):2187-2194. doi:10.1245/s10434-008-9980-4
29. Chaturvedi P, Vaishampayan SS, Nair S, et al. Oral squamous cell carcinoma arising in background of oral submucous fibrosis: a clinicopathologically distinct disease. *Head Neck*. 2013;35(10):1404-1409. doi:10.1002/hed.23143
30. Adriaansens CMEM, de Koning KJ, de Bree R, et al. Ultrasound-guided resection for squamous cell carcinoma of the buccal mucosa: a feasibility study. *Head Neck*. 2022;45:647-657. doi:10.1002/hed.27281
31. Klein Nulent TJW, Noorlag R, van Cann EM, et al. Intraoral ultrasonography to measure tumor thickness of oral cancer: a systematic review and meta-analysis. *Oral Oncol*. 2018;77:29-36. doi:10.1016/j.oraloncology.2017.12.007
32. Heller L, Cole P, Kaufman Y. Cheek reconstruction: current concepts in managing facial soft tissue loss. *Semin Plast Surg*. 2008;22(4):294-305. doi:10.1055/s-0028-1095888
33. Ng SY, Songra AK, Hutchison IL. Novel use of ultrasound-guided surface marking of head and neck tumors invading facial skin. *Oral Surg Oral Med Oral Pathol Oral Radiol Endodontol*. 2006;101(4):499-504. doi:10.1016/j.tripleo.2005.05.076
34. Qiao C, Zou Y, Qiu Y, Lin X. A simple approach for the repair of intermediate-to-large cheek defects. *Ann Plast Surg*. 2019;83(4S):S77-S81. doi:10.1097/SAP.0000000000002091
35. Soliman S, Hatem DA, Hollier LH, Thornton JF. The rationale for direct linear closure of facial Mohs' defects. *Plast Reconstr Surg*. 2011;127(1):142-149. doi:10.1097/PRS.0b013e3181f95978

SUPPORTING INFORMATION

Additional supporting information can be found online in the Supporting Information section at the end of this article.

How to cite this article: Adriaansens CMEM, Noorlag R, de Bree R, van Es RJJ. Treatment of buccal mucosal carcinomas: A survey amongst head and neck surgeons in the Netherlands. *Laryngoscope Investigative Otolaryngology*. 2023;8(4):857-864. doi:10.1002/lio2.1081