

Surgical results of chronic thromboembolic pulmonary endarterectomy in our recently developed program

Yakın zamanda geliştirdiğimiz program ile kronik tromboembolik pulmoner endarterektominin cerrahi sonuçları

Gökçen Orhan¹, Hüseyin Kuplay¹, Nehir Selçuk¹, Sena Sert², Özlem Yıldırım²

¹Department of Cardiovascular Surgery, Siyami Ersek Thoracic and Cardiovascular Surgery Training and Research Hospital, Istanbul, Turkey

²Department of Cardiology, Siyami Ersek Thoracic and Cardiovascular Surgery Training and Research Hospital, Istanbul, Turkey

ABSTRACT

Background: In this case series, we aimed to present our diagnostic workup, surgical management, and results of the patients who underwent pulmonary endarterectomy.

Methods: In this case series, a total of 26 patients (8 males, 18 females; median age: 58 years; range, 34 to 67 years) who were evaluated by a multidisciplinary team and were diagnosed with chronic thromboembolic pulmonary hypertension who underwent pulmonary endarterectomy in our clinic between November 2015 and December 2019 were included. Pulmonary endarterectomy procedure was performed in all cases under cardiopulmonary bypass and total circulatory arrest. The results of the procedures were analyzed retrospectively.

Results: Perioperative complications were observed in seven patients (26.9%) and in-hospital mortality rate caused by perioperative complications was 15.38%. At one-year of postoperative follow-up, the mean systolic pulmonary artery pressure decreased from 78±22 mmHg to 41±20 mmHg, pulmonary vascular resistance decreased from 698±10 dyn·s·cm⁻⁵ to 235±10 dyn·s·cm⁻⁵, 6-min walk distance increased from 345±10 m to 460±10 m and, arterial oxygen saturation increased from 85±3.5% to 95±4%. New York Heart Association functional class improvement from Class III-IV to Class I-II was observed in most patients, and one-year mortality rate was 19.23%.

Conclusion: We suggest that patients diagnosed chronic thromboembolic pulmonary hypertension should be referred to cardiac surgery centers for pulmonary thromboendarterectomy, early before irreversible arteriopathy occurs.

Keywords: Chronic thromboembolic pulmonary hypertension, pulmonary embolism, pulmonary thromboendarterectomy.

ÖZ

Amaç: Bu olgu serisinde, tanı yöntemimiz, cerrahi tedavi ve pulmoner endarterektomi yapılan hastaların sonuçları sunuldu.

Çalışma planı: Bu olgu serisine Kasım 2015 - Aralık 2019 tarihleri arasında kliniğimizde multidisipliner bir ekip tarafından değerlendirilen ve kronik tromboembolik pulmoner hipertansiyon tanısı konulan toplam 26 hasta dahil edildi. Tüm olgularda pulmoner endarterektomi işlemi kardiyopulmoner baypas altında ve total sirkülatuar arrest uygulayarak yapıldı. İşlem sonuçları retrospektif olarak incelendi.

Bulgular: Yedi hastada (%26.9) perioperatif komplikasyon görüldü ve perioperatif komplikasyonlara bağlı hastane mortalitesi %15.38 idi. Ameliyat sonrası takibin birinci yılında, ortalama sistolik pulmoner arter basıncı 78±22 mmHg'den 41±20 mmHg'ye, pulmoner vasküler direnç 698±10 dyn·s·cm⁻⁵'den 235±10 dyn·s·cm⁻⁵'ye düşerken, 6 dakikalık yürüme testi mesafesi 345±10 m'den 460±10 m'ye ve arteriyel oksijen saturasyonu %85±3.5'ten %95±4'e yükseldi. Hastaların birçoğunda New York Kalp Derneği fonksiyonel sınıfta III-IV'ten sınıf I-II'ye iyileşme gözlemlendi ve bir yıllık ölüm oranı %19.23 idi.

Sonuç: Kronik tromboembolik pulmoner hipertansiyon tanısı konan hastalar, kalıcı arteriopati gelişmeden, pulmoner tromboendarterektomi ameliyatı için cerrahi merkezlere erken dönemde yönlendirilmeleri ve deneyimli bir ekip tarafından değerlendirilerek tedavi edilmeleri gerektiği görüşünderiz.

Anahtar sözcükler: Kronik tromboembolik pulmoner hipertansiyon, pulmoner emboli, pulmoner tromboendarterektomi.

Received: December 21, 2020 Accepted: May 30, 2021 Published online: July 26, 2021

Correspondence: Nehir Selçuk, MD, Dr. Siyami Ersek Göğüs ve Kalp Damar Cerrahisi Eğitim ve Araştırma Hastanesi, Kalp ve Damar Cerrahisi Kliniği, 34668 Üsküdar, İstanbul, Türkiye. Tel: +90 506 - 882 07 75 e-mail: ummunehir@hotmail.com

Cite this article as:

Orhan G, Kuplay H, Selçuk N, Sert S, Yıldırım Ö. Surgical results of chronic thromboembolic pulmonary endarterectomy in our recently developed program. Turk Gogus Kalp Dama 2021;29(3):295-303

©2021 All right reserved by the Turkish Society of Cardiovascular Surgery.

This is an open access article under the terms of the Creative Commons Attribution-NonCommercial License, which permits use, distribution and reproduction in any medium, provided the original work is properly cited and is not used for commercial purposes (<http://creativecommons.org/licenses/by-nc/4.0/>).

Acute pulmonary embolism is a significant cause of morbidity and mortality.^[1,2] One to five in every 1,000 patients of acute pulmonary embolism suffer from chronic thromboembolic pulmonary artery occlusion, a frequent of undissolved embolic debris, recurrent embolism, or both.^[3,4] It may result in the development of chronic thromboembolic pulmonary hypertension (CTEPH) with a minimum 40 to 60% occlusion of the major pulmonary arteries.

There is a persistent increase in pulmonary vascular disease, leading to right ventricular dysfunction, and right heart failure. Depending on the severity of pulmonary occlusion and the progression of microvascular disease in patent pulmonary arteries, the manifestation of symptoms may be delayed for months or years. Prognosis is poor for untreated or undiagnosed patients due to non-specific symptoms.^[5] Mean pulmonary artery pressure threshold for poor prognosis is 25 mmHg.^[6]

Pulmonary endarterectomy (PEA) and pulmonary thromboendarterectomy (PTE) are highly efficient and potentially curative gold-standard treatment options.^[7-9] Early mortality of PEA is acceptably low with the support of a multidisciplinary CTEPH team and surgical experience, and early mortality of PEA is acceptably low, as well. Long-term survival and quality of life after PEA are quite satisfactory.^[10]

In the present study, we aimed to present our diagnostic workup, surgical management, and results of the patients who underwent PEA.

PATIENTS AND METHODS

This single-center, retrospective study was conducted at Siyami Ersek Thoracic and Cardiovascular Surgery Training and Research Hospital, Department of Cardiovascular Surgery between November 2015 and December 2019, when the PEA program was first initiated in our institution. Medical records of patients were reviewed retrospectively. Surgical patient selection for PEA was made by a multidisciplinary team after the first evaluation by the preoperative CTEPH outpatient clinic. Our decision algorithm is shown in Figure 1.

Among patients referred to our pulmonary hypertension clinic, patients with moderate or high probability of pulmonary embolism and over 18 years of age were selected. Patients who were eligible and willing to operation were selected as candidates for PEA. Finally, a total of 26 patients (8 males, 18 females; median age: 58 years; range, 34 to 67 years) were included. Decision of surgery was made according to severity of symptoms and worsening of the pulmonary hemodynamic. Candidates for surgery were usually patients with severe symptoms during daily activities;

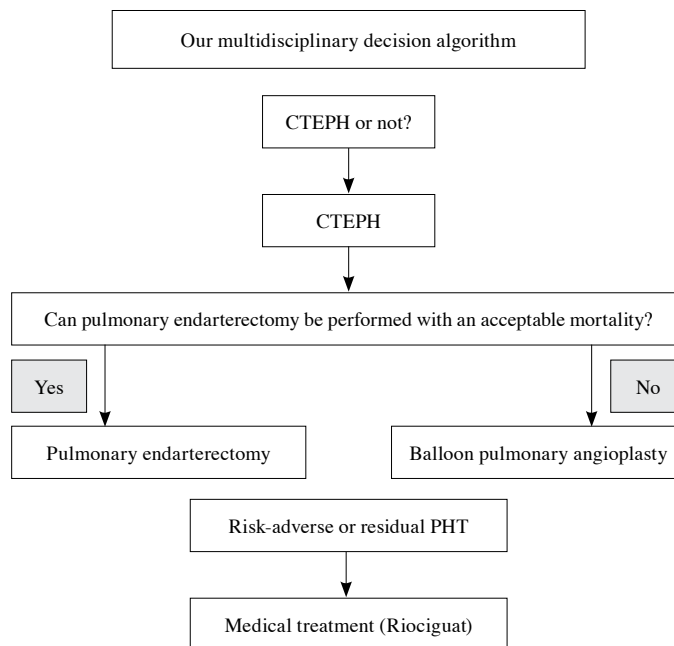


Figure 1. Our hospital decision algorithm.

CTEPH: Chronic thromboembolic pulmonary hypertension; PHT: Pulmonary hypertension.

suffering from dyspnea during minimal exercise or even at rest New York Heart Association (NYHA) Class III-IV. Diagnosis of pulmonary hypertension was confirmed with right heart catheterization (RHC). Coronary angiography and echocardiography studies were performed in all patients to investigate additional cardiac pathologies. The 6-Minute Walk Test (6MWT) was applied to all the patients. In our institution, patients are tested on a walking track in length of 60 m for each round, their fastest walking performance and walking distances are recorded pre- and postoperatively. The patient selection algorithm in our CTEPH clinic is shown in Figure 2.

A written informed consent was obtained from each patient. The study protocol was approved by the Siyami Ersek Thoracic and Cardiovascular Surgery Training and Research Hospital Ethics Committee (date/No: 25.12.2020/28001928-604.01.01). The study was conducted in accordance with the principles of the Declaration of Helsinki.

Surgical technique

The main goals of surgery are to maintain pulmonary perfusion and ventilation/perfusion balance, to reduce right ventricular afterload, and to prevent secondary vasculopathies. The surgical techniques and modifications required to achieve

these results at an acceptable risk of surgery are defined by the San Diego Group and are implemented in many CTEPH clinical centers.^[7] The operation is performed under cardiopulmonary bypass (CPB) and deep hypothermia using intermittent total circulation arrest (TCA) techniques. Preserving a bloodless surgical site is very important for correct and effective endarterectomy. The operation is limited not only to pulmonary embolectomy of the thrombus material, but also to a true endarterectomy that removes the neointimal and medial layers of the vessel along the organized fibrous material. In our clinic, the operation is performed under these conditions. The procedure is carried out under intermittent TCA. First, the right pulmonary artery is reached and cut longitudinally between the ascending aorta and superior vena cava. The correct plan is reached and endarterectomy is performed from the proximal to the distal of the vessel. Once the larger thrombotic material is removed, the correct endarterectomy plan is obtained. Endarterectomy of the distal part of the veins is performed every 20-min TCA period. Endarterectomy specimens are traced circumferentially in each lobe until reaching the segmental and subsegmental branches (Figure 2). After the right pulmonary artery incision is closed, endarterectomy is applied to the left pulmonary artery after reperfusion. Cardiopulmonary

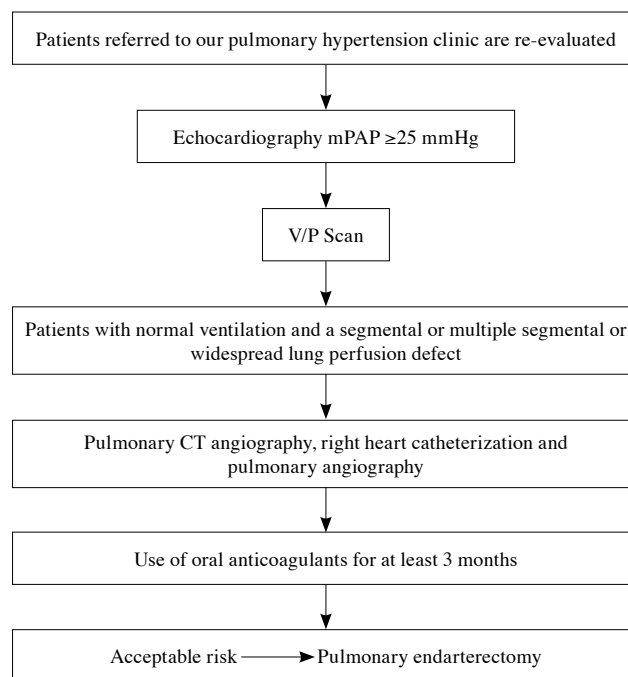


Figure 2. Patient selection criteria.

PAP: Pulmonary artery pressure; CT: Computed tomography.

Table 1. Demographic and clinical characteristics of patients

	n	%	Median	Min-Max
Age (year)			58	34-67
Sex				
Female	18	69.23		
Male	8	30.76		
Body mass index (kg/m ²)			26.5	24.2-30.5
History of VTE	24	92.3		
History of PE	20	76.9		
Comorbidities				
Hypertension	2	7.6		
Diabetes mellitus	1	3.8		
COPD	2	7.6		
CAD	1	3.8		
ASD	2	7.6		
Severe tricuspid regurgitation	1	3.8		
Cancer	2	7.6		
Cystic hydatid disease	2	7.6		

VTE: Venous thromboembolism; PE: Pulmonary embolism; COPD: Chronic obstructive pulmonary disease; CAD: Coronary artery disease; ASD: Atrial septal defect.

bypass is reinitiated and the left pulmonary artery cut is repaired. After reheating, weaning is done carefully from CPB.

Statistical analysis

Statistical analysis was performed using the STATA for Macintosh version 12.0 software (STATA Corp., College Station, TX, USA). Descriptive data were expressed in mean ± standard deviation (SD), median (min-max), or

number and frequency. The Fisher's exact test was used to compare categorical data, while the Student t-test was used to compare continuous variables. A *p* value of <0.05 was considered statistically significant.

RESULTS

The majority of the patients (n=22/84.6%) were suffering from dyspnea. Twenty of the patients were in NYHA Class IV and six of them were in Class III.

Table 2. Pre- and postoperative hemodynamic parameters

	Preoperative		Postoperative		<i>p</i>
	n	Mean±SD	n	Mean±SD	
LVEF (%)		55.5±7		57.5±5	NS
Right ventricular diameter (mm)		5.5±1.2		5.2±0.8	NS
TAPSE (mm)		15.2±3		16.5±3	NS
RVS velocity (cm/sn)		8±1.5		9.5±1.2	NS
PAP (systolic) mmHg		78±22		41±20	≤0.05
PVR dyn.s./cm-5		698±10		235±10	≤0.05
Oxygen saturation (%)		85±3.5		95±4	≤0.05
6-Minute Walk Test (m)		345±10		460±10	≤0.05
NYHA Class I	-		7		
NYHA Class II	-		11		
NYHA Class III	6		-		
NYHA Class IV	20		-		

SD: Standard deviation; LVEF: Left ventricular ejection fraction; TAPSE: Tricuspid annular plane systolic excursion; RVS: Right ventricular systolic; PAP: Pulmonary artery pressure; PVR: Pulmonary vascular resistance; NYHA: New York Heart Association; NS: Not significant.

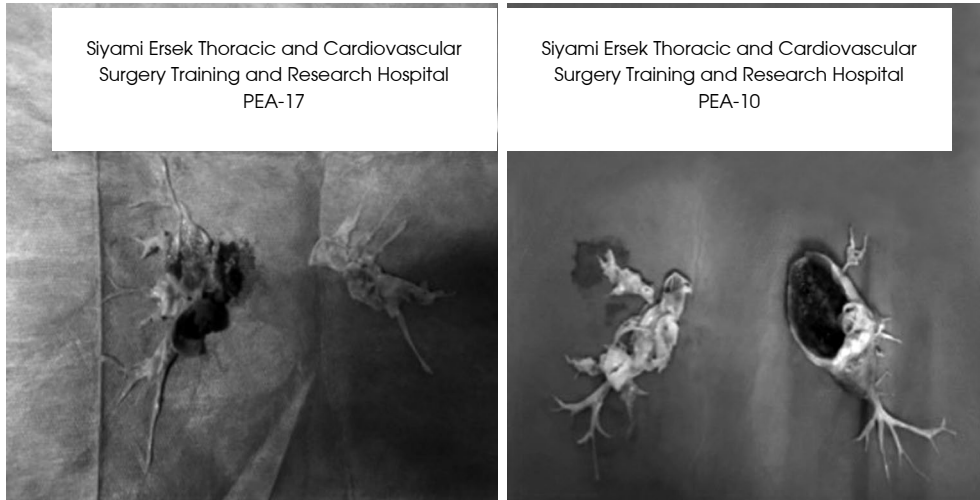


Figure 3. Pulmonary endarterectomy materials.

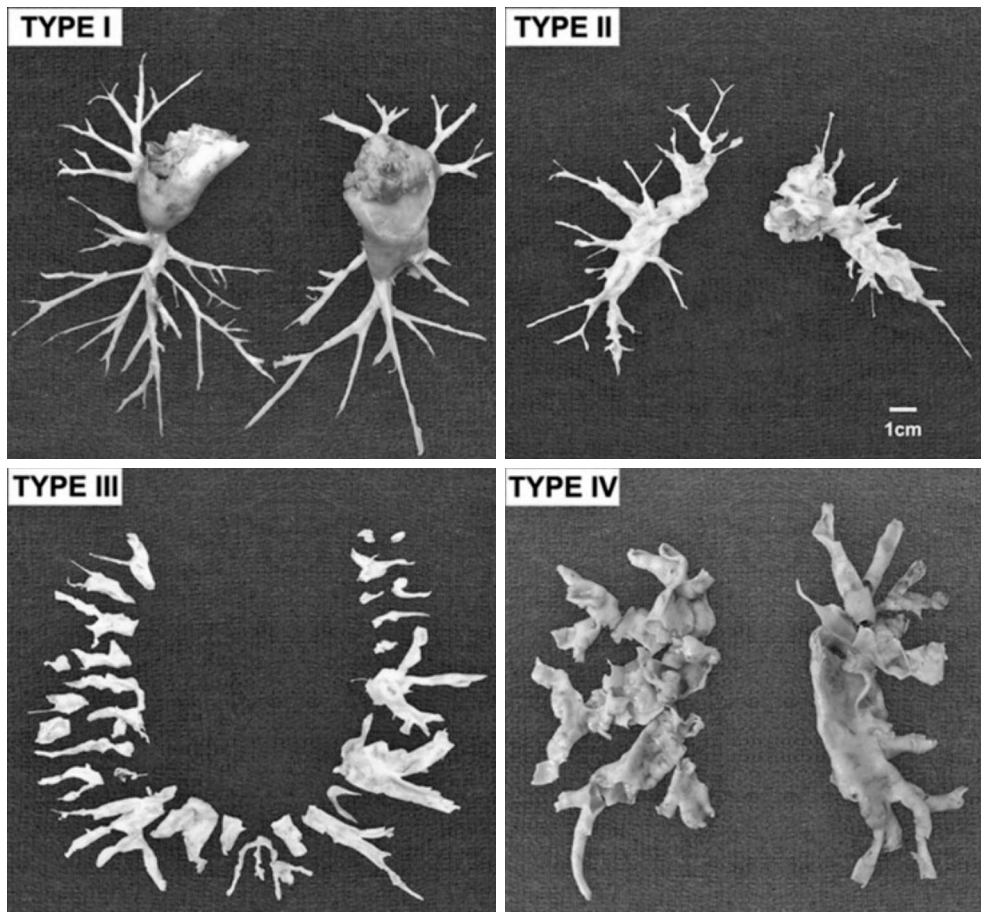


Figure 4. Jamieson classification of pulmonary thromboendarterectomy (ref: <https://www.ahajournals.org/doi/10.1161/CIRCULATIONAHA.114.009309>).

University of California-San Diego surgical classification (Jamieson) of pulmonary endarterectomy specimens. In type 1 disease: major-vessel clot is present and readily visible on opening the pulmonary artery. In type II disease: no major-vessel thrombus is present, but there is evidence of thickened intima with webs in the lobar branches. In contrast, in type III disease: very distal disease, confined only to segmental and subsegmental branches, is encountered. Type IV disease refers to a very small subgroup of patients in whom despite a complete surgical exploration and intimectomy of the vascular tree, there is no evidence of thromboembolic material.

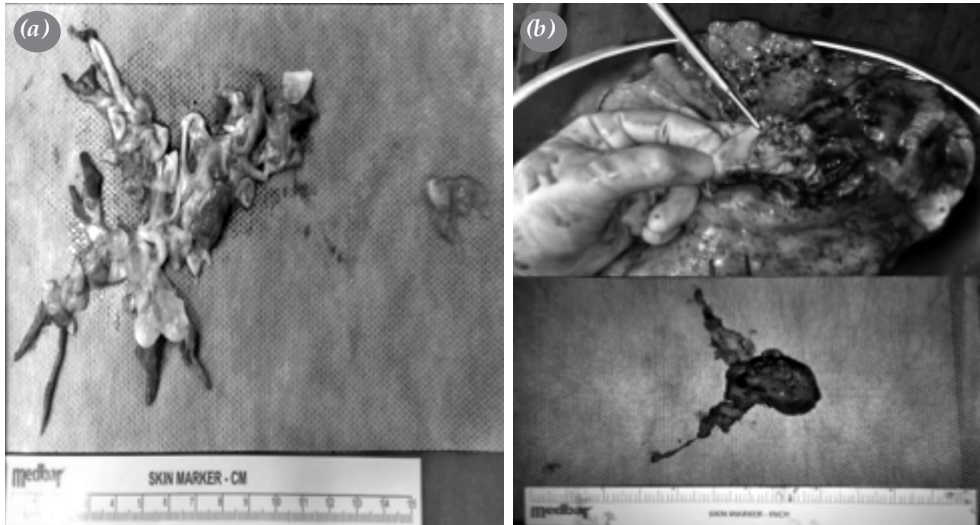


Figure 5. (a) Intrapulmonary hydatid cyst, (b) adenocarcinoma removed in left pulmonary arterial right pneumonectomy patient.

Preoperative pulmonary artery pressure and pulmonary vascular resistance measured via RHC were higher than normal values. Oxygen saturation levels and 6-MWT results were lower than normal values (Tables 1 and 2).

Among patients, 22 of them were solely diagnosed with CTEPH, five of them were Type 2, seven of them were Type 3, and three were Type 4 (Figure 3).

Etiology of CTEPH was cystic hydatid disease in two patients and a neoplasm in two patients. One

of the patients with a neoplasm, adenocarcinoma of the lung, underwent right-sided pneumonectomy. The patient had chronic thrombus occluding left superior and left middle lobar arteries, which were removed by PTE. The second case of a neoplasm, bilateral angiosarcoma invading pulmonary arteries, was also operated (Figure 4).

Two patients underwent atrial septal defect (ASD) closure and one patient tricuspid ring annuloplasty (TRA) procedure. Operation variables and

Table 3. Operative data and postoperative complications

	n	%	Mean±SD	p
Operative data (min)				
Cardiopulmonary bypass time			290±50	NS
Cross clamp time			142±20	NS
TCA			24±6	NS
Postoperative complications				
Persistent pulmonary hypertension	5	19.2		
Reperfusion edema	2	7.6		
Pulmonary hemorrhage	1	3.8		
Bleeding revision	2	7.6		
Late sternal closure	2	7.6		
Multiorgan failure	1	3.8		
Hemofiltration	3	11.5		
Right heart failure	3	11.5		
Need ECLS	5	19.2		
Operative mortality	5	19.2		

TCA: Total circulatory arrest time; ECLS: Extracorporeal life support; NS: Not significant.

postoperative complications of the patients are shown in Table 3.

There was no mortality within 72 h in the intra- and early postoperative period. Two patients died after 72 h. One of them had pulmonary cystic hydatid disease and died of anaphylactic shock. The other died from pulmonary hemorrhage.

Preoperative echocardiography showed poor right ventricular function in five patients. Only three of them needed extracorporeal life support (ECLS).

Overall, ECLS was needed in 19.2% (5/26) of the patients. Two of these patients were due to reperfusion injury and the other three were due to right heart failure. One of the patients supported with extracorporeal membrane oxygenation (ECMO) died from multiorgan failure. Four patients with ECLS were successfully weaned and discharged.

Mortality was seen in one patient within the first postoperative month and another patient at three months. These patients suffered from angiosarcoma and lung adenocarcinoma, respectively. In the long-term follow-up, no mortality was observed.

Operative mortality was seen in five patients (19.23%) in the first year. Late postoperative mortality was not observed. Active surveillance and periodical follow-up of 19 patients continued at the end of the study cut-off date. Two of our patients were lost to follow-up.

During postoperative follow-up, NYHA functional classification, 6-MWT, N-terminal pro-brain natriuretic peptide, tricuspid annular plane systolic excursion, right ventricular systolic velocity, fractional area change (FAC) and right ventricular (RV) area were evaluated. All patients followed were in the NYHA Class I-II.

Only five of 19 patients were still treated with riociguat. Lifelong direct oral anticoagulant or vitamin K antagonist was prescribed postoperatively to all patients.

DISCUSSION

Since 1973, the 6th World Symposium on Pulmonary Hypertension (6WSPH) papers summarize future needs through the studies conducted and the efforts of various working groups working on different aspects of pulmonary hypertension.^[11] A total of 124 experts participated in the 6WSPH and these experts were divided into 13 working groups. The CTEPH Working Group discussed the latest diagnosis and treatment methods in this rapidly developing field.^[12]

As the new definition of chronic thromboembolic disease (CTED), the presence of CTEPH-like symptoms and perfusion defects at rest, excluding pulmonary hypertension (excluding the development of hemodynamically pulmonary hypertension), was accepted. The CTEPH treatment recommendations should not be applied yet in CTED, as additional prospective studies are needed on this subject. Although pulmonary angiography is accepted as the gold standard in evaluating vascular morphology in CTEPH, developments in non-invasive diagnostic methods are promising.

Computed tomography pulmonary angiography is currently used frequently in evaluating the operability of patients. Pulmonary endarterectomy is a treatment option for these patients, and the decision of operability should be evaluated by a multidisciplinary CTEPH team, including a PEA surgeon, a pulmonary hypertension specialist, balloon pulmonary angioplasty specialist, and a radiologist. Medical treatment has also an important role in improving symptoms and hemodynamic parameters.^[13]

Clinical manifestations of CTEPH are usually insidious, and disease progression is slow until symptoms become more severe and right heart failure occurs.^[14] Most of the patients do not have a history of venous thrombosis or acute pulmonary embolism; therefore, the diagnosis of thromboembolic pulmonary hypertension may be difficult and is often overlooked. Moreover, this clinical situation and the existence of the curative surgical option are not widely known. Typical symptoms of dyspnea are present with physical exercise and improve with rest.

In addition to chest pain during exercise, hemoptysis and syncope are common problems observed at the late period of CTEPH due to advanced pulmonary hypertension and right heart failure. Pulmonary vascular disease should be considered for dyspnea with unclear etiology, as all symptoms of CTEPH are non-specific.

Postoperative care, hemodynamic and ventilation management for postoperative PEA patients can be difficult.^[15,16] Management of extracorporeal circulation, ischemia, hypothermia, and TCA are critical issues in the intraoperative management. Residual thrombotic material is the most important problem. Residual thrombotic material induces right ventricular dysfunction after cross-clamping and ischemia. The major problem of postoperative care is reperfusion edema of the lung seen in the endarterectomized segments. Maintaining sufficient right ventricular function, organ perfusion, renal function, adequate oxygenation, and preventing

pulmonary artery re-occlusion are the mainstays of the postoperative care.^[17] Measurement of cardiac flow, mixed venous oxygen saturation, and arterial blood gas samplings are beneficial for monitoring adequate ventilation and perfusion.

Tricuspid valve repair is not necessary, since tricuspid insufficiency usually recovers during the following days of the successful PEA. One patient in our series underwent TRA procedure due to structural tricuspid valve insufficiency seen during the preoperative assessment. Recovery of the tricuspid valve function was seen in other patients during routine follow-up. Correction of all cardiac pathologies such as ASD repair and TRA procedures were done during the re-heating phase of the operation.

One of the most common complications after PEA is reperfusion edema of the lung parenchyma occurring in 5 to 20% of patients.^[18] After PEA, varying degrees of reperfusion edema can be observed. In uncomplicated cases, supportive therapy with mechanical ventilation and diuretics is sufficient. However, in complex cases with persistent respiratory failure, ECLS may be required.

In some cases, patients suffer from residual pulmonary hypertension, which is typically limited to the early postoperative period and can be seen in patients with good surgical outcomes due to reperfusion edema as previously described, or in patients with extensive peripheral and microvascular disease. In case of microvascular disease, fibrotic thrombus cannot be surgically removed, as it is located distally in small-caliber vessels. These conditions may be challenging to identify before surgery^[19] and may cause acute cardiorespiratory deterioration along with surgical trauma and reperfusion edema. In all these cases, in addition to different degrees of respiratory failure, right ventricular failure may accompany.

Endobronchial/parenchymal bleeding is the most critical (and often fatal) serious complication.^[20] In all these cases, medical treatment may be insufficient and temporary ECLS should be considered. When conventional medical and respiratory support is not sufficient to stabilize patients, ECLS is a good option to interrupt the vicious circle of increased PVR, hypoxia, and right ventricular failure. In our study, two patients were supported with veno-arterial (VA)-ECMO due to oxygenation insufficiency due to reperfusion injury, the other three patients were supported with VA-ECMO due to right ventricular failure. In these patients, cardiac function and certain right ventricular function may be a critical factor for

survival. The patients who needed ECMO had poor preoperative right ventricular function in our study. Implantation was mainly in the operating room before or immediately after weaning from CPB, and central cannulation was used. The mean duration of ECMO was 6 ± 2 days.

As the authors, we are the executive team of the heart transplant and mechanical assist device operations in our institution, and we are highly experienced in using cardiac assist devices and ECMO. Therefore, we have no hesitation in using short-term assist devices or ECMO support to prevent postoperative organ dysfunction. It is an advantage for us to be able to make decisions quickly and implement them in a timely manner.

The novel coronavirus 2019 (COVID-19) pandemic has emerged unexpectedly as a global healthcare crisis. In this context, one of the most difficult patient populations to manage is CTEPH patients. Many reports focusing on basically protecting patients and healthcare providers have been published during the pandemic. However, data on the management of CTEPH patients are still lacking.^[21] Since the first day of the pandemic, medical treatment has been applied to our patients during follow-up in our institution. Of note, our multidisciplinary CTEPH team prefers to postpone PEA, since it is not possible to predict the course of the pandemic and there would be a shortage of mechanical ventilators and the increasing need for ECMO.

Since we are a newly established center, the number of patients and follow-up times are low. Suspended due to the COVID pandemic. We are in an effort to increase our case series in order to present the results more meaningfully. Our CTEPH program will continue to be developed with a larger number of cases.

In conclusion, the gold standard treatment for chronic thromboembolic pulmonary hypertension is surgery which provides hemodynamical and functional recovery and improvement of life expectancy. Our highly experienced chronic thromboembolic pulmonary hypertension team consisting of cardiologists, heart and thoracic surgeons, anesthesiologists, and intensive care team successfully and confidently performs these operations. We recommend that patients diagnosed with chronic thromboembolic pulmonary hypertension should be referred to centers where a multidisciplinary team is available to evaluate them for pulmonary thromboendarterectomy in the early period, before irreversible arteriopathy occurs.

Declaration of conflicting interests

The authors declared no conflicts of interest with respect to the authorship and/or publication of this article.

Funding

The authors received no financial support for the research and/or authorship of this article.

REFERENCES

1. Pengo V, Lensing AW, Prins MH, Marchiori A, Davidson BL, Tiozzo F, et al. Incidence of chronic thromboembolic pulmonary hypertension after pulmonary embolism. *N Engl J Med* 2004;350:2257-64.
2. Hoepfer MM, Mayer E, Simonneau G, Rubin LJ. Chronic thromboembolic pulmonary hypertension. *Circulation* 2006;113:2011-20.
3. Moser KM, Auger WR, Fedullo PF. Chronic major-vessel thromboembolic pulmonary hypertension. *Circulation* 1990;81:1735-43.
4. Jamieson SW, Kapelanski DP. Pulmonary endarterectomy. *Curr Probl Surg* 2000;37:165-252.
5. Riedel M, Stanek V, Widimsky J, Prerovsky I. Longterm follow-up of patients with pulmonary thromboembolism. Late prognosis and evolution of hemodynamic and respiratory data. *Chest* 1982;81:151-8.
6. Lewczuk J, Piszko P, Jagas J, Porada A, Wójciak S, Sobkowicz B, et al. Prognostic factors in medically treated patients with chronic pulmonary embolism. *Chest* 2001;119:818-23.
7. Jamieson SW, Kapelanski DP, Sakakibara N, Manecke GR, Thistlethwaite PA, Kerr KM, et al. Pulmonary endarterectomy: Experience and lessons learned in 1,500 cases. *Ann Thorac Surg* 2003;76:1457-62.
8. Darteville P, Fadel E, Mussot S, Chapelier A, Hervé P, de Perrot M, et al. Chronic thromboembolic pulmonary hypertension. *Eur Respir J* 2004;23:637-48.
9. Mayer E, Kramm T, Dahm M, Moersig W, Eberle B, Düber C, et al. Early results of pulmonary thromboendarterectomy in chronic thromboembolic pulmonary hypertension. *Z Kardiol* 1997;86:920-7.
10. Kramm T, Mayer E, Dahm M, Guth S, Menzel T, Pitton M, et al. Long-term results after thromboendarterectomy for chronic pulmonary embolism. *Eur J Cardiothorac Surg* 1999;15:579-83.
11. Galiè N, Simonneau G. The Fifth World Symposium on Pulmonary Hypertension. *J Am Coll Cardiol* 2013;62(25 Suppl):D1-3.
12. Kim NH, Delcroix M, Jais X, Madani MM, Matsubara H, Mayer E, et al. Chronic thromboembolic pulmonary hypertension. *Eur Respir J* 2019;53:1801915.
13. Rosenkranz S, Diller GP, Dumitrescu D, Ewert R, Ghofrani HA, Grünig E, et al. Hemodynamic definition of pulmonary hypertension: Commentary on the proposed change by the 6th World Symposium on Pulmonary Hypertension. *Dtsch Med Wochenschr* 2019;144:1367-72.
14. Fedullo PF, Auger WR, Kerr KM, Rubin LJ. Chronic thromboembolic pulmonary hypertension. *N Engl J Med* 2001;345:1465-72.
15. Fedullo PF, Auger WR, Dembitsky WP. Postoperative management of the patient undergoing pulmonary thromboendarterectomy. *Semin Thorac Cardiovasc Surg* 1999;11:172-8.
16. Kramm T, Eberle B, Krummenauer F, Guth S, Oelert H, Mayer E. Inhaled iloprost in patients with chronic thromboembolic pulmonary hypertension: Effects before and after pulmonary thromboendarterectomy. *Ann Thorac Surg* 2003;76:711-8.
17. Klepetko W, Mayer E, Sandoval J, Trulock EP, Vachiery JL, Darteville P, et al. Interventional and surgical modalities of treatment for pulmonary arterial hypertension. *J Am Coll Cardiol* 2004;43(12 Suppl S):73S-80S.
18. Thistlethwaite PA, Madani MM, Kemp AD, Hartley M, Auger WR, Jamieson SW. Venovenous extracorporeal life support after pulmonary endarterectomy: Indications, techniques, and outcomes. *Ann Thorac Surg* 2006;82:2139-45.
19. Galiè N, Kim NH. Pulmonary microvascular disease in chronic thromboembolic pulmonary hypertension. *Proc Am Thorac Soc* 2006;3:571-6.
20. Morsolini M, Azzaretti A, Orlandoni G, D'Armini AM. Airway bleeding during pulmonary endarterectomy: The "bubbles" technique. *J Thorac Cardiovasc Surg* 2013;145:1409-10.
21. Akay T, Sade LE, Bozbaş Ş, Hekimoğlu K, Okyay K, Gültekin B, et al. How to deal with chronic thromboembolic pulmonary arterial hypertension (CTEPH) during the COVID-19 pandemic: Too many gray zones to be considered. *Turk J Vasc Surg* 2021;30:70-6.