



Case report

Trapped lung secondary to cardiomegaly in a 78 year-old male with congestive heart failure

Amy H. Amabile ^{a,*}, Susan D. Moffatt-Bruce ^b, Robert M. DePhilip ^a^a Division of Anatomy, The Ohio State University, Columbus, OH, USA^b Department of Surgery, The Ohio State University, Columbus, OH, USA

ARTICLE INFO

Article history:

Received 30 October 2015

Received in revised form

3 March 2016

Accepted 6 March 2016

Keywords:

Trapped lung

Cardiomegaly

Fibrothorax

Hydropneumothorax

Pleural effusion

Thoracentesis

ABSTRACT

Although the etiologies of both trapped lung and cardiomegaly are well-established, co-presentation of the two conditions, and possible interactions between them, are much rarer. Here we describe the case of 78 year-old male found to have both cardiomegaly and trapped lung, with a cause of death of congestive heart failure and subsequent cardiac arrest. This case prompted consideration of possible interactions between the two conditions. Issues related to decision-making for imaging and clinical interventions are also discussed.

© 2016 The Authors. Published by Elsevier Ltd. This is an open access article under the CC BY-NC-ND license (<http://creativecommons.org/licenses/by-nc-nd/4.0/>).

1. Introduction

A trapped lung, or fibrothorax, is a shrunken lung surrounded by a cortex of fibrotic visceral pleura. This fibrotic peel prevents inflation of the lung, and is typically caused by a chronic inflammatory process leading to uncontrolled fibrin deposition. Although it is a known sequela of recurrent pleural effusion, other disease processes, such as malignant or metastatic visceral pleural disease, can also lead to trapped lung [1,10,14,18]. Cardiomegaly is defined as an increase in heart size caused by ventricular hypertrophy or chamber dilation such that the ratio of heart diameter to maximum thorax diameter, measured transversely, is greater than 0.5 [24]; [25].

Although neither trapped lung nor cardiomegaly is considered unusual, simultaneous presentation of both conditions, or a causal connection between them, is virtually unmentioned in the literature. Furthermore, both conditions can be difficult to diagnose with a plain chest radiograph, which is the most common imaging ordered for patients with dyspnea. Failure to recognize and identify trapped lung can lead to unnecessary interventions such as repeated thoracenteses, or can delay more appropriate interventions such as surgical decortication.

2. Case report

During routine dissection of a 78 year-old male cadaver we found a trapped left lung and enlarged heart almost completely occupying the left pleural cavity (Fig. 1). The subject's past medical history included congestive heart failure (CHF), chronic pleural effusion with prior thoracenteses, atrial fibrillation, non-sustained ventricular tachycardia, stage III kidney disease, hypertension, chronic anemia, cardiac pacemaker placement, and hydrocephalus with ventriculoperitoneal shunt placement. Cause of death was given as cardiac arrest and CHF.

One week prior to death, our subject was admitted to the hospital with complaints of shortness of breath and diffuse edema, and was given primary diagnoses of anasarca and CHF exacerbation. At that time his vital signs were normal, and he required 2 L of oxygen by nasal cannula to maintain an oxygen saturation of 95%. Multiple chest radiographs taken during that hospital stay (Fig. 2) showed "persistent subtotal opacification of the left hemithorax," and "massive left pleural effusion with minimal aeration of the left lung [and] at least mild cardiomegaly." The subject then underwent thoracentesis to remove the fluid in his left hemithorax, and a repeat radiograph showed "persistent opacification" of the left hemithorax, and noted that "cardiac and mediastinal contours are difficult to evaluate due to adjacent opacification."

At the time of our dissection, the subject's right lung appeared

* Corresponding author. Division of Anatomy, The Ohio State University, 279 Hamilton Hall, 1645 Neil Avenue, Columbus, OH 43210, USA.

E-mail address: amabile.3@osu.edu (A.H. Amabile).

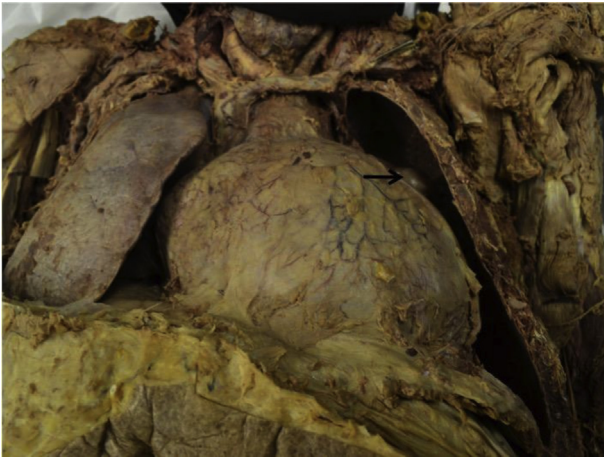

Fig. 1. Anterior view of lungs and pericardial sac after removal of the anterior chest wall. Note the tip of superior lobe of left lung protruding over the left contour of the heart (arrow).

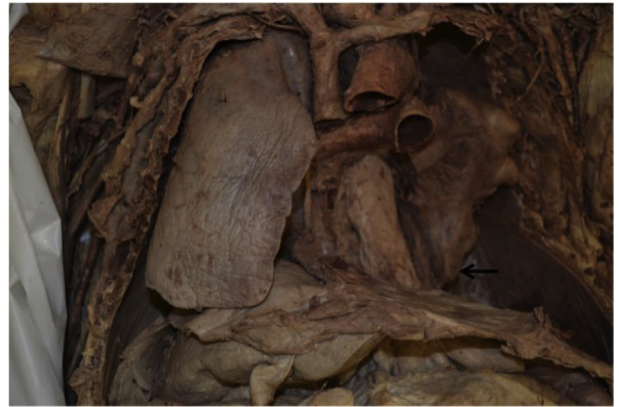

Fig. 3. Anterior view of the chest after removal of the heart, showing deformed and fibrotic left lung. Note diminutive left lower lobe (arrow).

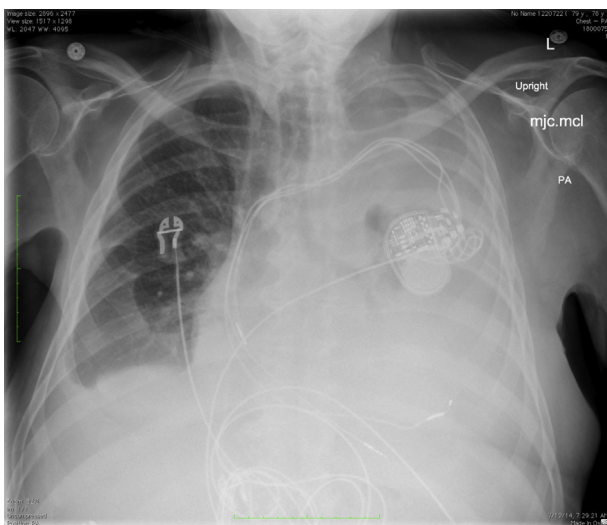


Fig. 2. Chest radiograph taken during the week before death. Note opacification in left pleural cavity which limits visualization of the heart contours and the trapped lung.




Fig. 4. Heart opened to show hypertrophy of ventricular walls and interventricular septum.

normal in dimensions and gross appearance. The left lung was deformed, and markedly diminished compared with the right lung, particularly in the lower lobe (Fig. 3). The thickness of the cortex around the lung varied from 0.5 to 1.5 mm. Subject presented with cardiomegaly, with a cardiothoracic ratio of 0.54. The right ventricular wall, interventricular septum and left ventricular wall measured 240%, 255%, and 326% of values for healthy adults, respectively (Fig. 4), indicating substantial biventricular hypertrophy [11,15]. Comparing ventricular wall thickness values can be challenging because norms are based on end-diastolic measurements, and significant regional variations exist in the thickness of any individual ventricle [5]. Wall thickness has been shown to be greatest during systole; however, the maximum differences in ventricular thickness measured at diastole and systole have been reported to average less than 62% [23]. Given this fact, the measurements in the present subject would appear to represent substantial hypertrophy regardless of the cardiac phase at the time of death.

3. Discussion

3.1. Etiology and clinical course of trapped lung and cardiomegaly

Trapped lung causes a hydropneumothorax, with both fluid and air present in the pleural cavity. Signs and symptoms of trapped lung include shortness of breath, an absence of breath sounds on the affected side and, in some cases, hypoxemia [1,8]. Diagnosis is made by clinical exam, chest xray and computed tomography (CT). Analysis of the pleural fluid is done to differentiate malignant from inflammatory or infectious processes. Although ultrasound guidance can greatly enhance the accuracy of thoracentesis for pleural effusion, it is not considered a reliable imaging modality to identify a trapped lung [7]; [18].

Chronic pleural effusion is a known cause of trapped lung. In the early stages of pleural effusion, before the development of the fibrotic cortex, lung expansion is limited only by the pleural fluid build-up separating visceral from parietal pleura. Thus, when the fluid is removed by thoracentesis, the lung is able to fully re-expand. Over time, however, the thickening fibrotic coat on the visceral pleura prevents the re-expansion of the lung, even after

fluid has been drained [1]. The time frame for development of trapped lung is unknown, and in many cases, individuals with trapped lung are asymptomatic and the condition remains undiagnosed [14]. In cases where a patient is symptomatic, decortication, i.e. surgical removal of the fibrotic cortex, is the standard of care if the patient is considered a good surgical candidate ([1,14].

Chronic pleural effusion is caused most commonly by cancer, followed by left heart failure and pneumonia. There have, however, been a small number of reported cases of pleural effusion caused by isolated right ventricular failure [16,17]. The underlying mechanism of pleural effusion caused by left ventricular failure results from increased pulmonary capillary pressure creating an increased pressure gradient, leading to movement of fluid from the capillaries into the pulmonary interstitial space, then across the visceral pleural membrane into the pleural space [9,16].

Cardiomegaly results either from chamber dilation or, as seen in the present subject, hypertrophy of one or both ventricles [22,25]. Ventricular hypertrophy has been shown to be a sequela of chronic, uncontrolled hypertension, although recent research has shown mutations in the gene coding for sarcomeric proteins to also be an important cause of hypertrophic cardiomyopathy [6,21,22]. Arterial hypertension causes increased afterload, and the left ventricular hypertrophic response. This hypertrophy ultimately leads to reduced compliance of the left ventricle and subsequent decreased end diastolic volumes, and thus to CHF [22] [3]. Right ventricular hypertrophy, which was also seen in the present subject, results from a chronic increase in afterload due to pulmonary hypertension, often caused by prior left heart failure [19].

We have found only one reference to the co-presentation of cardiomegaly and trapped lung in the literature. Our literature search methodology included database searches of PubMed and Web of Science, and identical search results were obtained for all keywords for both databases. Using the keywords of cardiomegaly, trapped lung, fibrothorax, and heart failure, in various combinations, yielded one article by Ref. [4]. In this article, the authors reported on a case of cardiomegaly and right sided heart failure, associated with fibrothorax, in a 57 year-old woman, who had reportedly been asymptomatic since the likely onset of right lung collapse 39 years prior. The patient was treated with surgical decortication, and had transient improvement in pulmonary function tests, although she died of heart failure three years later.

3.2. Evidence of a reciprocal effect between trapped lung and cardiomegaly

Was the presence of both a trapped lung and enlarged heart in the present subject a coincidence, or was there some sort of causation? Although no direct causal connection has been established between the two conditions, analogies can be found in the literature.

For example, right ventricular ejection fraction has been shown to decrease after pneumonectomy or major pulmonary resection due to lung cancer. This lower ejection fraction is the result of an increase in afterload due to the missing pulmonary vascular bed of the missing or resected lung. Increased afterload is known to cause right ventricular hypertrophy and ultimately right heart failure [13]. It is possible that the small and non-functioning left trapped lung in the present subject led to a similarly increased afterload and thus compensatory right ventricular hypertrophy.

Conversely, the increased size of the subject's heart may have contributed to the collapse of his left lung. It has been shown that increased heart size will cause compression of the left lung, and cardiomegaly is significantly correlated with decreased left lower lobe ventilation, particularly in the supine position [2,20]. Neves et al. [12] studied the effect of increased heart weight in 17 patients

undergoing coronary artery bypass grafting. Post-surgical edema and other mechanisms caused an average 32% increase in post-surgical heart weight. Using CT scans they were able to measure pre- and post-surgical volumes and masses of both the heart and lungs, and measure the pressure of individual cardiac segments on adjacent lung segments. One day after surgery, they found increases of 75% and 45% in the pressure of the heart on the left and right lower lobes, respectively; and significantly decreased gas volumes in those lobes. They hypothesize that this pressure of heart on lung plays an important role in the post-surgical atelectasis commonly seen after open heart surgery. The present subject showed grossly decreased size in his left lower lobe (Fig. 3) that is consistent with the above-described mechanism.

3.3. Clinical considerations

Our subject had three chest radiographs in the final week before his death, in order to monitor his pleural effusion before and after thoracentesis. Visualization of a trapped lung would require CT scanning [14]. Yet given the subject's clinical presentation and end-stage progression of his CHF it is highly unlikely that further interventions for trapped lung, if it had been identified, would have been recommended, as surgical decortication is a very invasive procedure that requires good cardiopulmonary reserve.

Our subject may have benefitted, however, from earlier identification of his trapped lung in prior years as he was being treated for pleural effusion. Early identification may have offered additional treatment options, and also would have prevented the cost, discomfort and risks of repeat thoracentesis. Thoracentesis is not recommended in the case of trapped lung, as the pleural cavity will immediately refill due to the negative pleural pressure [14]. Greater awareness, and a higher overall index of suspicion among clinicians for the presence of trapped lung and its sequelae, would lead to more routine use of CT scans in similar cases, and likely overall improved, and potentially more efficient, patient care.

4. Financial disclosure and conflict of interest

We affirm that we have no financial affiliation (including research funding) or involvement with any commercial organization that has a direct financial interest in any matter included in this manuscript. Nor do we have any other personal or professional conflict of interest related to this manuscript.

Acknowledgments

The authors thank our donor, and his family, who generously allowed his body to be donated to the Ohio State University Body Donor Program, and without whom this research would not be possible. We also thank Melody Barton, Michelle Whitmer and Mark Whitmer for their efforts in the day-to-day management of the Body Donor Program; and John H. Bolte IV, PhD for his technical assistance with the dissection.

References

- [1] J. Albores, T. Wang, Images in clinical medicine, Trapped Lung. *N. Engl. J. Med.* 372 (2015) e25.
- [2] M.S. Alexander, R.N. Arnot, J.P. Lavender, Left lower lobe ventilation and its relation to cardiomegaly and posture, *Br. Med. J.* 299 (1989) 94.
- [3] B. Bozorgnia, P.J. Mather, Current management of heart failure: when to refer to heart failure specialist and when hospice is the best option, *Med. Clin. North Am.* 99 (2015) 863–876.
- [4] Y.C. Chee, S.C. Poh, Unilateral calcified fibrothorax with cor pulmonale: failure to improve with decortication, *Singap. Med. J.* 24 (1983) 63–65.
- [5] S.J. Dong, J.H. MacGregor, A.P. Crawley, E. McVeigh, I. Belenkie, E.R. Smith, J.V. Tyberg, R. Beyar, Left ventricular wall thickness and regional systolic

- function in patients with hypertrophic cardiomyopathy. A three-dimensional tagged magnetic resonance imaging study, *Circulation* 90 (1994) 1200–1209.
- [6] M.H. Drazner, The progression of hypertensive heart disease, *Circulation* 123 (2011) 327–334.
- [7] D. Feller-Kopman, Therapeutic thoracentesis: the role of ultrasound and pleural manometry, *Curr. Opin. Pulm. Med.* 13 (2007) 312–318.
- [8] K. Liew, P. Stride, Trapped lung, *Intern Med. J.* 42 (2012) 217.
- [9] G. Miserocchi, Physiology and pathophysiology of pleural fluid turnover, *Eur. Respir. J.* 10 (1997) 219–225.
- [10] S.E. Mutsaers, C.M. Prele, A.R. Brody, S. Idell, Pathogenesis of pleural fibrosis, *Respirology* 9 (2004) 428–440.
- [11] Y. Nagata, T. Konno, N. Fujino, A. Hodatsu, A. Nomura, K. Hayashi, H. Nakamura, M.A. Kawashiri, M. Yamagishi, Right ventricular hypertrophy is associated with cardiovascular events in hypertrophic cardiomyopathy: evidence from study with magnetic resonance imaging, *Can. J. Cardiol.* 31 (2015) 702–708.
- [12] F.H. Neves, M.J. Carmona, J.O. Auler Jr., R.R. Rodrigues, J.J. Rouby, L.M. Malbouisson, Cardiac compression of lung lower lobes after coronary artery bypass graft with cardiopulmonary bypass, *PLoS One* 8 (2013) e78643.
- [13] M. Okada, T. Ota, M. Okada, H. Matsuda, K. Okada, N. Ishii, Right ventricular dysfunction after major pulmonary resection, *J. Thorac. Cardiovasc Surg.* 108 (1994) 503–511.
- [14] M.F. Pereyra, L. Ferreiro, L. Valdes, Unexpandable lung, *Arch. Bronconeumol* 49 (2013) 63–69.
- [15] S. Pfaffenberger, P. Bartko, A. Graf, E. Pernicka, J. Babayev, E. Lolic, D. Bonderman, H. Baumgartner, G. Maurer, J. Mascherbauer, Size matters! Impact of age, sex, height, and weight on the normal heart size, *Circ. Cardiovasc Imaging* 6 (2013) 1073–1079.
- [16] J.M. Porcel, Pleural effusions from congestive heart failure, *Semin. Respir. Crit. Care Med.* 31 (2010) 689–697.
- [17] J.M. Porcel, A. Esquerda, M. Vives, S. Bielsa, Etiology of pleural effusions: analysis of more than 3,000 consecutive thoracenteses, *Arch. Bronconeumol* 50 (2014) 161–165.
- [18] S. Rathinam, D.A. Waller, Pleurectomy decortication in the treatment of the “trapped lung” in benign and malignant pleural effusions, *Thorac. Surg. Clin.* 23 (2013) 51–61.
- [19] J.J. Ryan, S.L. Archer, The right ventricle in pulmonary arterial hypertension: disorders of metabolism, angiogenesis and adrenergic signaling in right ventricular failure, *Circ. Res.* 115 (2014) 176–188.
- [20] R.H. Secker-Walker, M.M. Toban, J.E. Ho, Patterns of regional ventilation in patients with cardiomegaly or left heart failure, *J. Nucl. Med.* 22 (1981) 212–218.
- [21] H. Sisakian, Cardiomyopathies: evolution of pathogenesis concepts and potential for new therapies, *World J. Cardiol.* 6 (2014) 478–494.
- [22] J.A. Spudich, Hypertrophic and dilated cardiomyopathy: four decades of basic research on muscle lead to potential therapeutic approaches to these devastating genetic diseases, *Biophys. J.* 106 (2014) 1236–1249.
- [23] B.L. Troy, J. Pombo, C.E. Rackley, Measurement of left ventricular wall thickness and mass by echocardiography, *Circulation* 45 (1972) 602–611.
- [24] Ungerleider HE, Gubner R. Evaluation of heart size measurements. *Am. Heart J.* 24:494–510.
- [25] S. Winkhofer, N. Berger, T. Ruder, M. Elliott, P. Stolzmann, M. Thali, H. Alkadhi, G. Ampanozi, Cardiothoracic ratio in postmortem computed tomography: reliability and threshold for the diagnosis of cardiomegaly, *Forensic Sci. Med. Pathol.* 10 (2014) 44–49.